

Ultrasonographic Study of Cause and Prevalence of Neural Tube Defects in Various Socio-Economic Groups of Jharkhand, India.

Dr Rakesh Kumar Vidrohi¹ Dr Aradhana Sanga²

¹(Tutor, Department of Anatomy, Rajendra Institute Of Medical Sciences, Ranchi University, India)

²(Assistant Professor, Department of Anatomy, Mahatama Gandhi Memorial Medical College, Kolhan University, India)

Corresponding Author: Dr Aradhana Sanga

Abstract

Introduction : Neurulation (Formation and closure of neural tube) when incomplete results in a tubular structure defect with openings in spinal cord and brain early in human development resulting in neural tube defects (NTD). These may be open or closed types.

Objectives: Analytical study of incidence and associated causes of NTD in Jharkhand population.

Material and method: After Ethical committee clearance 2000 patients were examined by ultrasonography, age ranging between 18-35 in their 1st and second trimester of pregnancy.

Result: Total 30 cases of NTD were found with 15 cases of anencephaly. Prevalence was higher in cases belonging to low socioeconomic group, residing in hilly areas and primigravida (18-25 years).

Conclusion: 30 NTD cases (1.5%) all of open type were found among 2000 sample size. Among these 15-anencephaly, 1- acrania, 2-exencephaly, 3- meningocele, 3-meningoencephalocele, 2- meningomyelocele and 2- spina bifida were found. During analysis of causes 25 among the cases did not take folic acid during pregnancy, from 24 cases from rural area 15 belonged to hilly areas, low socioeconomic group with between age of 18-25 were found to be 25 and 18 among cases respectively.

Date of Submission: 04-10-2019

Date of Acceptance: 21-10-2019

I. Introduction

Neural tube defects (NTDs) are one of the most common birth defects, occurring in approximately one in 1,000 live births. A neural tube defect is a failure of closure of neural tube resulting in opening in spinal cord or brain that occurs very early in human development. After completion of neurulation the central nervous system is represented by a closed tubular structure with a narrow caudal portion, the spinal cord, and a much broader cephalic portion, characterized by a number of dilations, the brain vesicles. When the neural tube is not closed completely, a neural tube defect develops.

There are two types of NTDs^[1] open, which are more common, and closed. Open Neural Tube Defects occur when the brain and/or spinal cord are exposed at birth through a defect in the skull or vertebrae (back bones). Examples of open Neural Tube Defects are anencephaly, acrania, exencephaly, meningocele, meningoencephalocele, meningomyelocele and spina bifida (cystica, occulta). Rarer types of Neural Tube Defects are called closed Neural Tube Defects. Closed Neural Tube Defects occur when the spinal defect is covered by skin. Common examples of closed Neural Tube Defects are lipomyelomeningocele, lipomeningocele and tethered cord.

Folate is required for production and maintenance of new cells, for DNA synthesis and RNA synthesis. Folate is needed to carry one carbon groups for methylation and nucleic acid synthesis. It has been hypothesized that the early human embryo may be particularly vulnerable to folate deficiency due to differences of the functional enzymes in this pathway during embryogenesis

Central nervous system malformations are the second most frequent category of congenital anomaly after congenital heart disease

Ultrasound scan can reliably detect many of the structural abnormalities (birth defect of the body) of the baby. Structural abnormalities which can be detected included **hydrocephalous** (swelling of head with excessive fluid), **anencephaly** (absence of brain), **spina bifida** (defect in spine), **meningocele**, **meningoencephalocele**, **meningomyelocele** etc

HoneinMA^[2] et al found that folate treatment before conceptions to prevent recurrence of neural tube defects reduced the occurrence and concluded that folic acid supplementation might be a cheap, safe and effective method.

NaktsuT^[3] *etal* found that NT closure in human embryos initiates at multiple sites. The sites being 1)the future cervical region that is widely accepted as an initiation site of neural tube closure 2)the mesencephalic–rhombencephalic boundary 3) present at the rostral end of the neural groove over the prosencephalon and the second closure initiating at the site B proceeds bidirectionally

Jennifer Ann Makelarski^[4] *etal* found that Alcohol and occupational pesticides exposure on the development of Neural Tube Defects was positively associated with spina bifida

Van Allen^[5] *etal.* (1993) proposed a multisite NT closure model in which five closure sites exist in the NT of human embryos.

The study was conducted to study the incidence of Neural Tube Defects with reference to factors like socio-economic status, age of the patients and geographical area and its association with folic acid and B12 supplement, with in Jharkhand state for better understanding of etiopathogenesis and ultrasonographic findings of NTD in the region.

II. Material And Method

The above study was conducted in the Department of Anatomy in collaboration with Department of Radio-diagnosis at Rajendra Institute of Medical Sciences, Ranchi (RIMS). Screening of 2000 patients with age ranging from 18-35 in the first and second trimester was done for the diagnosis of NTD.

History taking

Was done regarding intake of folic acid and vitamin B12, socio-economic status (low, middle and high), topographical area to which the patient belonged and Parity and age of the patients.

Examination by USG

Established findings recorded

- In the first trimester- By 8weeks on transvaginal ultrasound, the brain cavities appear as large cystic spaces within the head.
- In Acrania only a thin layer covers the brain and an abnormally shaped cephalic pole. The amount of brain tissue present varied.
- In exencephaly, there is still a large portion of brain tissue present but the covering membrane is no longer visible. The head appears smaller than the trunk and in cross section there is marked dorsal protrusion of the cerebrum producing an asymmetrical shape to the cranial pole. Exencephaly progresses to anencephaly so Ultrasound diagnosis is made by demonstration of absence of cranial vault and cerebral hemisphere.
- An encephalocele is a bony defect in the skull midline, with accompanying protrusion of intracranial contents. There may be protrusion of the meninges alone (meningocele) or the meninges and brain (meningoencephalocele).
- Ultrasound diagnosis of ventriculomegaly based on the demonstration of dilated lateral ventricles. From 9 weeks of gestation the outline of the lateral ventricle, choroid plexus and midline echo can be visualized. The ratio of the lateral ventricle to hemisphere diameter decrease with gestation throughout the first trimester. Ventriculomegaly more commonly develops and may be visualized after 14weeks of gestation.
- Spina bifida, the spine will be seen as two echogenic parallel line from 7weeks gestation on TVS. Three ossification centers are present from 9 week Ossification of spine should be seen clearly in the cervical vertebrae at 11weeks and echogenicity gradually increases down the spine until the lumbosacral region is visualized at 13 weeks.

The neural tube normally closes by 6weeks gestation and failure of this process result in spina bifida. In the second trimester the typical ultrasound features are scalloping of the frontal (lemon shaped head), a smaller biparietal diameter than expected, hanging of the choroid plexuses in the dilated lateral ventricles, a curved shaped to the cerebellum (banana sign) and in irregular defect in the vertebra and overlying skin.

In the present study after history taking and USG examination the data obtained was analyzed using statistical diagrams.

III. Result

Out of the study sample 30 cases were found to have NTD.

TABLE – 1 showing different types of NTD out of total 2000 patients.

Sl. No.	Type of NTDs	No of cases
1	Anencephaly	15
2	Acrania	1
3	Exencephaly	2
4	Meningocele	5
5	Meningoencephalocele	3
6	Meningomyelocele	2
7	Spina bifida	2

Chart 2 chart 3

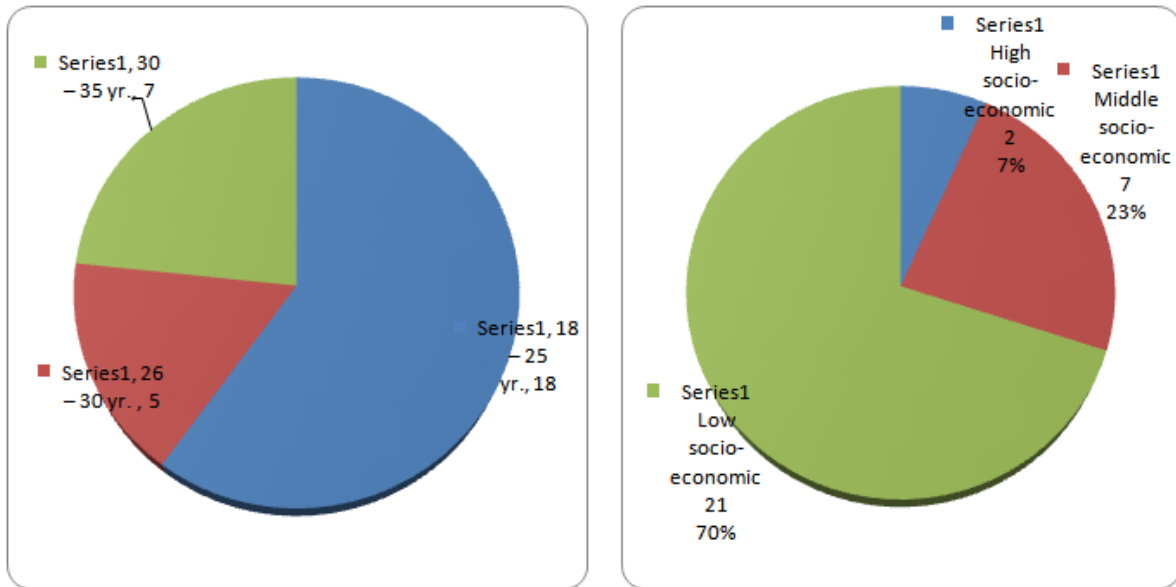


Chart 2: Relation of NTD's with age

Chart 3: Relation of NTD with different type of socioeconomic group of patients

Chart 4 chart 5

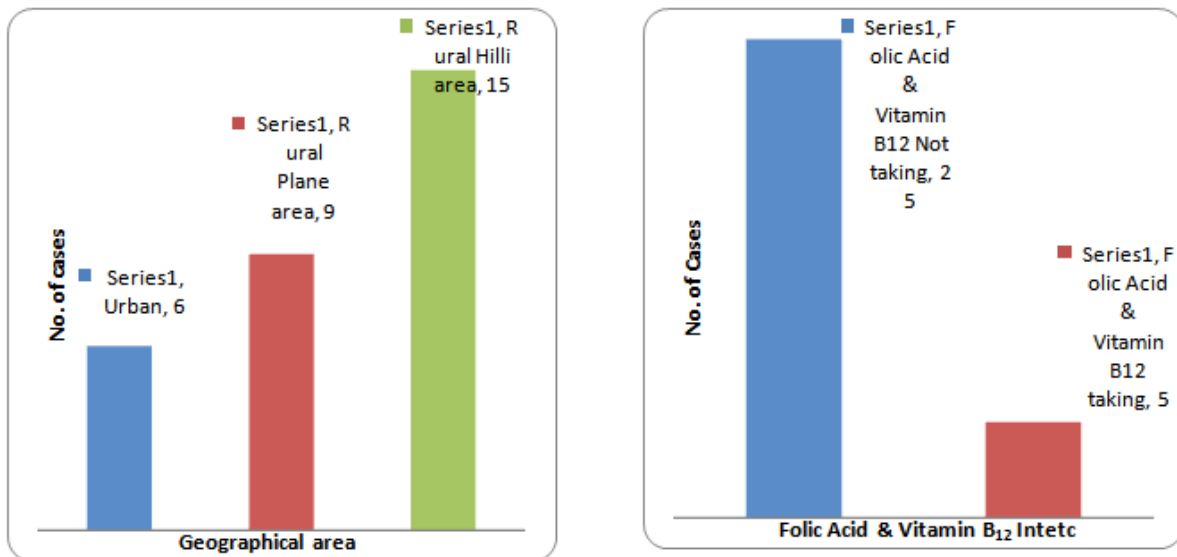


Chart 4: relation of different NTDs in different geographical areas of Jharkhand

Chart 5: relation of NTDs with intake of Folic acid and Vit B12.

TABLE 6: showing % and number out of total patients examined and total cases of various types of NTDs found in the study

Sl. No.	Types of NTD	Percentage of total patients examined (2000)	Number of cases of each NTDs	Percentage of each NTDs out of total cases (30)
1	Anencephaly	50%	7.5	0.75
2	Acrania	3.33%	0.5	0.05
3	Exencephaly	6.67%	1	0.1
4	Meningocele	16.66%	2.5	0.25
5	Meningoencephalocele	10%	1.5	0.15
6	Meningomyelocele	6.66%	1	0.1
7	Spina bifida	6.66%	1	0.1

IV. Discussion

The neural tube defect a common congenital defect has been researched by a number of workers have come to a conclusion that intake of folic acid and vitamin B12 helps in prevention of Neural Tube Defects and now a days it is prescribed as a routine to all of the mother for antenatal check up in first trimester.

- Jennifer Ann Makelarski^{[3], [6],[7][8]}, in their study found the incidence of NTDs to be 1 in 1000 ,2 in 1000 and 2 in 1000 patients respectively compared to 15 in 1000 patients in the present study. The higher incidence may be due to the fact that the study has been done in Rajendra Institute of Medical Sciences which is a prime hospital of Jharkhand state and tertiary referral centre. She found that maternal reports of alcohol exposure (depending upon the dose and types of alcohol consumed) and exposure of occupational pesticides, insecticides, fungicides and herbicides is positively associated with the spina bifida similarly in present study, out of 30 NTDs cases, in 5 cases the mother was taking folic acid and vitamin B12, it means other causes also responsible for NTDs. It may be due to association of alcohol consumption and exposure of pesticides, insecticides, fungicides and herbicides.
- According to Honein MA^[1]etal 60 women were allocated before conception to take 4mg of folic acid one month before and during early pregnancy and 44 complied with these instructions. 51 women were allocated to placebo group. Thus there were no recurrence among those who received supplementation and 6 among the placebo group. The result shows that folic acid supplementation might be a cheap, safe and effective method of primary prevention of neural tube defects. Similarly Laurance KM^[9]etal, Olsen SF^[10]etalalso justified a similar finding. In the present study out of 30 cases of neural tube defects 25 cases were not taking folic acid and vitamin B12. This justifies the result of Honein MA.
- NTDs commonly seen in low socio-economic groups as emphasised by GrewalJ^{[11][14]}etal.the middle/high socio-economic groups. Out of 30 cases 21 case found in low socio-economic groups. No previous works on incidence of neural tube defects in relation to socio-economic status of the patients has been done.
- In geographical area, rural hilly area is more affected than the urban and plane rural areas found by Bhandri S^[12]etalandWassemen CR^{etal}^[13]Out of 30 cases24 case found in rural area in our study, among 24 cases of rural area 15 case found in hilly region only rest of 6 case found in urban area. No previous records have been found I this relation. In present it has been found that the NTDs are more common in hilly region of rural area.
- Primigravida are more affected as found by MdSaleem^{[14][15]}etalwomenof age groups 18-25 yrs. are more affected. Out of 30 cases 15 case are present in age groups 18-25 yrs and only 5 cases present in age group 26-30 yrs rest of 7 cases present in age group 30-35 yrs of pregnant mothers. In present it has been found that neural tube defects are more common in primigravida of age group 18-25 yrs.

V. Conclusion

The present study conducted at Rajendra Institute of Medical Sciences, Ranchi concluded that .Out of 2000 patients only 1.5% patients have NTDs.Out of 30 cases, 50% of anencephaly, 3.33% of acrania,6.67% each of exencephaly meningomyelocele and spina bifida,16.66% of meningocele and 10% of meningoencephalocele,

Out of 30 cases, 5 cases taking folic acid and vitamin B12 developed NTDs indicating the role of associated factors also. 15 cases of NTDs residing in hilly region indicated more folic acid deficiency in hilly region of rural areas. 21 cases in low socio-economic groups could be due to ignorance about taking folic acid and vit B12. 18 cases of NTDs in the mothers of age group 18-25 years, it indicates neural tube defects more common in younger age group.

More than one type of neural tube defects was found in single case (anencephaly associated with meningocele and meningoencephalocele, Spina bifida associated with meningocele and meningomyelocele).

References

- [1]. Anthony VD Antoni. Ankle and foot, In :Standing S (ed)41st.Grey's Anatomy,The anatomical basis of clinical practice. Elsevier Churchill Livingstone:2016:1424-1426.
- [2]. Honein MA, Paulozzi LJ, Mathews TJ, et al: Impact of folic acid fortification of the US food supply on the occurrence of neural tube defects. JAMA 2001;285:2981-2986.
- [3]. NakatsuT,UwabeC,Shiota K; Neural tube closure in humans initiates at multiple sites:evidence from human embryos and implications for the pathogenesis of neural tube defects.AnatEmbryol (Berl)2000 Jun;201(6):455-66.
- [4]. Jennifer AM, Paul AR, LixianS,Richard SO and the National Birth Defects Prevention Study;Periconceptional Maternal Alcohol Consumption and Neural Tube Defects : Birth defects research. PartA,Clinical And molecular teratology:2013 March; 97(3)152-60.
- [5]. Van Allen MI,Kalousek DK, Chernoff GF etal;Evidence for multi-site closure of the neural tubes in humans:Am J Med Genet.1993 Oct;47(5):723-43
- [6]. Blumenfeld Z, Siegler E, Bronshtein M: The early diagnosis of neural tube defects: PrenatDiagn 1993;13:863-871
- [7]. Bronshtein M, Zimmer EZ: Transvaginalsonographic follow-up on the formation of fetalcephalocele at 13-19 weeks' gestation.;ObstetGynecol 1991; 78: 528-530.
- [8]. Bhargava R, Hammond DI, Benzie RJ, et al: Prenatal demonstration of a cervical myelocystocele. Prenatdiag 1992;653-659.

- [9]. Laurance KM, James N, Miller M, et al: I Double-blind randomized controlled trial of folate treatment before conception to prevent recurrence of neural tube defects. *Br Med J* 1981;282:1509-1511.
- [10]. Olsen SF, Knudsen VK; Folic acid for the prevention of neural tube defects:the Danish experience:*Food Nutr Bull.*2008 Jun;29(2):S205-9.
- [11]. Grewal J, Carmichael SL, Song J, Shaw GM: Neural tube defects:an analysis of neighbourhood-and individual- level socio-economic characteristics.*PaediatrPerinat Epidemiol.*2009 March;23(3):116-24.
- [12]. BhandariS,Sayami JT, Ricky Raj K.C and Megha Raj Banjara: Prevalence of congenital defects including selected neural tube defects in Nepal: results from a health survey; *BCM Paediatrics* (2015):15:133.
- [13]. Wasserman CR, Shaw GM, Selvin S, Gould JB, Syme SL: Socioeconomic status,neighbourhood social conditions and neural tube defects :*American Journal of Public Health*;01 Nov 1998,88(11):1674-80.
- [14]. MdSaleem,Ali M, Hussain Q, Mallik AR, Mahmood R:Prevalance and associated Risk factors for Neural Tube Defect in patients in SheikhZayed Hospital Rahim Yar Khan: *PJMHS* 4(3)July-Sept 2003:197-202.
- [15]. Biggio JR Jr, Owen J, Wenstrom KD, Oakes WJ: can prenatal ultrasound findingspredict ambulatory status in the fetuses with open spina bifida. *Am J ObstetGynecol* 2001; 185:1016-1020.

Dr Rakesh Kumar Vidrohi. "Ultrasonographic Study of Cause and Prevalence of Neural Tube Defects in Various Socio-Economic Groups of Jharkhand, India." *IOSR Journal of Dental and Medical Sciences (IOSR-JDMS)*, vol. 18, no. 10, 2019, pp01-05.