

Visual outcomes following retropupillary iris-claw lens implantation

Dr. Ram Swaroop Harsolia Associate Professor
Dr. Pushplata Verma Resident, Dr. Sanjeev K Nainiwal Professor & Head
Dr. Rakesh Porwal Sr. Professor, Dr. Rakesh K Chahar Resident
Dr. Akshay Sarraf Sr. Resident

Department of Ophthalmology J L N Medical college & Hospital, Ajmer (Rajasthan)
India

Corresponding Author: Dr. Sanjeev K Nainiwal Professor & Head

Abstract

Purpose: To evaluate the technique, visual and safety outcomes of retropupillary iris-claw lens implantation in aphakic eyes.

Method: All aphakic patients with inadequate capsular support with well defined iris were included. Prospective study was conducted from November 2018 to August 2019 in Ophthalmology department of J.L.N Medical College Ajmer. Surgery was done in two clinical settings in the form of primary implantation at time of cataract extraction surgery and other secondary implantation (who were already aphakic due to any cause).

Results: Of the total 30 patients, 10 patients implanted primarily due to capsular rent or weakness of zonular support unmanageable by putting in ciliary sulcus and 20 were secondarily implanted who were already aphakic. At 6 months follow up very few complications noted. In 4 patients ovalization of pupil was noted, whereas high IOP observed only in 1 patient. In 2 patients severe inflammation in the form of AC cells was noted in 1st month and decentered IOL was noted in only 2 patients. Most of the patients shown very good refractive outcome with minimum astigmatic error.

Conclusion: This study suggests that retropupillary iris claw lens insertion is beneficial in aphakia, which is easy and fast method ensuring good refractive outcomes. This surgical procedure has the advantages of a posterior chamber implantation with a low intraoperative and postoperative risk profile.

Keywords: Aphakia, Retropupillary iris claw lens, Secondary IOL.

Date of Submission: 25-09-2019

Date of Acceptance: 14-10-2019

I. Introduction

The development of intraocular surgical technique of refractive correction in aphakic eyes has been observed in last few years. In the bag implantation of the IOL is the basic standard of care in cataract surgeries. The lens is ideally placed in the capsular bag (1). This may not be possible in eyes with inadequate posterior capsular support and weakness of lens zonules. Aphakia is commonly the result of complications arising from cataract surgery. The most common risk factors of intraoperative complication are weakness of zonular fibers mostly due to **pseudoexfoliation syndrome (PEX)** or trauma. Despite a lack of capsular support, when the implantation of intraocular lens (IOL) into the ciliary sulcus is unmanageable, it is still possible to achieve satisfactory refraction. There are many possibilities to provide acceptable refraction in such eyes by implanting IOL in the anterior or posterior chamber during primary or secondary operation. The location of the IOL implantation and its method of fixation determine complexity of the surgery and potential side effects.

AC-IOL-Placement of IOL in the anterior chamber (AC-IOL) is technically easy and fast but such location can harm corneal endothelium and structures of the anterior chamber angle. Complications connected with AC-IOL are endothelial cell loss leading to pseudophakic bullous keratopathy, uveitis, uveitis-glaucoma-hyphema syndrome, chronic macular edema, angle structure damage, formation of peripheral anterior synechiae, fibrosis of haptics into the angle, pupillary block, and hyphema. (2,3,4)

Scleral-fixated IOLs (SF-IOLs) are affordable and readily available. The IOL is located in natural position, near the focal point of the eye and far from corneal endothelium and structures of the angle. Different variants of scleral fixation procedure are proposed, but they all are characterized by difficult intraocular manipulation and time consuming surgery. Potential degradation of sutures and its interaction with sclera may be associated with suture erosion in the long term. Knot exposure may result in an increased incidence of endophthalmitis. Other possible complications include tilt and decentration of the IOL, open angle glaucoma, suprachoroidal hemorrhage, and retinal detachment[5,6]. Although it was demonstrated that secondary SF-IOL implantation is associated with less early postoperative complications than primary AC-IOL. There were no long term differences in the visual outcomes and complication profiles.[5]

The iris-claw lens method was invented by Worst in 1980 in order to correct the refraction in aphakic eyes [6]. The principle of the lens fixation has remained unchanged for 30 years. As the decrease of endothelial cell density is observed [5], in order to avoid complications characteristic of the presence of an IOL in the anterior chamber, the technique of posterior fixation of iris-claw lenses was proposed by Amer[7] and later modified by Mohr et al. [8]. This technique preserves the natural anatomy of the eye. The popularization of this implantation technique has been observed recently. Its implantation is technically easy, less time consuming and affordable.

The aim of this study, therefore, was to analyze the results of iris-claw IOL retropupillary implantation during primary and secondary surgery.

II. Materials and Method

This study was carried out at our tertiary eye care centre in central Rajasthan, India.

Aphakic patients attending ophthalmology OPD at J.L.N Medical College and Hospital, Ajmer between January 2018 to March 2019 who were operated primary or secondary iris claw IOL implantation having deficient or absence of capsular support were included in the study.

It was a prospective study.

Sample Size contained 30 cases of aphakia which fulfill the inclusion and exclusion criteria were taken for retropupillary iris claw implantation.

All patients were routinely fully informed about the risk and benefits of the surgery and the written consent was obtained.

Inclusion criteria-

1. Primary Operation in which local conditions did not allow for intracapsular or sulcus IOL implantation during cataract surgery.
2. Secondary Operation- subjects with aphakia after previous cataract surgery without IOL implantation and subluxated IOL.

Causes of Aphakia	
Causes	No. of Patients
Aphakia due to subluxated IOL	3
Aphakia due to previous cataract surgery(ICCE,ECCE without capsular support)	17
PCIOL implantation not possible due to any complication at the time of surgery (primary)	10

The decision regarding the choice of IOL and timing of IOL surgery was based on the discretion of the surgeon.

Exclusion criteria-

1. Rubeosis iridis.
2. Aniridia or near total iris defects.
3. Proliferative diabetic retinopathy or any condition warranting vitreoretinal surgery in the near future.

Preoperatively work up

Etiology of aphakia was found and previous eye surgery status was noted. All the patients were examined for BCVA (Snellan chart), IOP (Goldmann applanation tonometer), keratometry and refraction. Anterior segment slit lamp examination and fundus examination to see any fundus pathology was performed. In cases with fundus pathology, OCT was done.

Biometry-Preoperative biometrical data from all patients were measured with A-scan. The SRK2/T formula was used as calculation formula (ACD-Const: 4.21, A-Constant is modified on the basis of AL). Biometry was done using the parameters for RPICL and the choice of IOL was decided intraoperatively as per the clinical discretion of the surgeon.

Surgical Technique-All operations were performed by experienced surgeon. Because of the variety of cases and preexisting pathologies, the surgical procedures differed and were individually modified. Anterior vitrectomy, removal of remnants of the capsule, and removal of IOL were performed if necessary. For IOL implantation a corneal or sclerocorneal tunnel was used. In most cases the existing cataract operation tunnel was extended to 5.5 mm. creation of two small corneal paracentesis at 3 and 9 o'clock, injection of intracameral pilocarpine followed by viscoelastic substance in to anterior chamber, insertion the IOL through corneo scleral tunnel into anterior chamber in reversed position (convex side down) and moved with special tweezers through the iris to posterior chamber. With a help of the second instrument (spatula) haptics were attached to the iris in 3 and 9 o'clock position, enclavation of midperipheral iris between the claw haptics with small spatula by applying gentle pressure. Suture applied at corneo scleral tunnel if needed. Injection gentamycin and dexamethasone was given subconjunctively at the end of surgery.

Types of outcome measurements-

- 1-Shape of pupil
- 2.Intraocular pressure
- 3.Inflammatory reaction-AC cells
- 4.Visual outcome with refractive error
- 5.Decentered IOL
- 6.Atrophy of iris
- 7.CME
- 8.Retinal detachment

III. Results

Total, 30 eyes in 30 patients were analysed. 10 patients were females and 20 were males. Their age ranged from 20 to 70 years, with mean of 50.5 years. Follow-up ranged from 1 to 6 months. Of the 30 eyes, 20 (66%) achieved a final visual acuity (6/12 or more) better than the pre-operative best recorded visual acuity.

A total of 9 eyes (30%) achieved a final acuity equal to that measured pre-operatively (6/18 to 6/36), and only 1 eye (3.3%) ended up with a poorer final acuity because of developing postoperative secondary glaucoma. There were no intra-operative complications in this case series. Two cases of iridocyclitis and one case of raised IOP was noted and were managed successfully. No cases of post-operative hypotony were reported, all cases measured intra-ocular pressures within the normal range at final follow-up except one.

Post operative complications and abnormalities noted are-

Ovalization of pupil-	4 Patients
Decentered IOL-	2 patients
Inflammatory cells in AC	2 patient
Raised IOP	1 Patient
Atrophy of iris	1 patient
Retinal detachment	None
CME	None

During post-operative follow up-

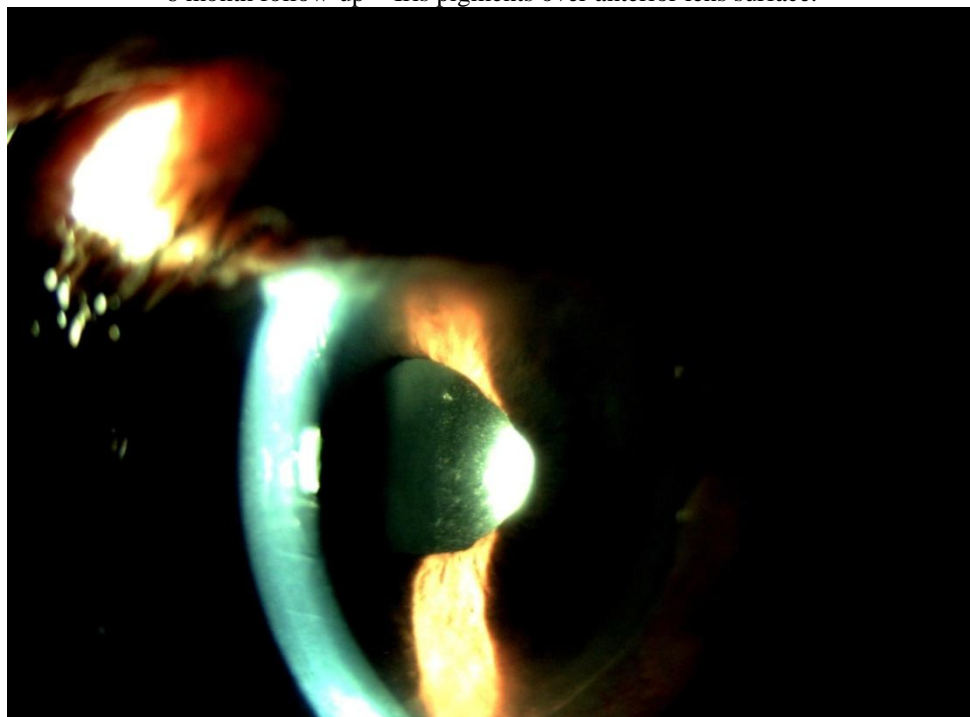
Follow up done in the form of visual acuity, IOP measurement, fundus examination to see macular edema, slit lamp examination to see any inflammatory reaction or IOL stability, status of iris and refraction.

The ovalization of the pupil was the most common finding and it was observed in 4 eyes (13.0%). In one eye iris atrophy (3.4%) noted. Only in one eye IOL decentration was observed. There was no significant difference in IOP at the end of the observation period of the eyes with and without complications except one. Intraocular pressure (IOP) was measured during every visit. In comparison to preoperative IOP postoperative IOP was not significantly changed at the end of the observation period.

Vision at 6 month follow up-

Best corrected visual acuity	No.of patients	Refractive correction	Remarks
Up to 6/60	1	Up to 1.00D cylindrical correction	Raised IOP
6/36 to 6/18	9	Up to 2.50D cylindrical correction	2 cases with iris pigments on IOL and 2 cases with decentered IOL.
6/12 to 6/6	20	Up to 0.75D cylindrical	

6 month follow-up - Iris pigments over anterior lens surface.



6 months follow up - ovalization of pupil



IV. Discussion

The aim of study in aphakic patients is to achieve acceptable refractive and visual outcomes in patients with insufficient capsular support. Retropupillary Iris Claw IOL is a vaulted convex–concave design of 5mm optic with an overall diameter of 8.5mm, including the haptics. The haptics are designed as claws, which grasp the immobile part of the peripheral iris thus avoiding the difficulties in pupil dilation .

Retropupillary localization, due to increased distance from corneal endothelium and angle structures, has protective significance for endothelium and IOP rise, which is especially important for PEX and glaucoma patients. Intraocular pressure were observed, whereas after anterior fixation of iris-claw IOL IOP tended to rise . Implantation of iris-claw IOL onto anterior surface of the iris led to the reduction of endothelial cell density by 9.78% within 3 years and upto12.35% within 5 years resulting in corneal decompensation in 1.7% within 2 years . The most common complication in this study was ovalization of the iris. It had no influence on postoperative BCVA. A comparable frequency of ovalization of the iris was observed in other studies . (3,4)

Most manipulations during retropupillary iris fixation are performed in the anterior chamber where haptics are more controllable and can be easily observed. Even then retropupillary iris-claw IOL implantation is quite an easy technique, resulting in twice as short as operating time and significantly shorter time in aphakic cases in comparison to scleral fixated-IOL.

In general, the implantation of the lens into the posterior chamber behind the iris plane seems to better respect the anatomy of the eye. However, the sclera-sutured posterior chamber lens implantation has some disadvantages. In addition to early complications, such as vitreous bleeding, choroidal hemorrhage, and initial intraocular pressure fluctuation, the main risks are retinal detachment and chronic macular edema which might be caused by vitreous traction.

The implantation of an iris-claw lens behind the iris plane combines the advantages of a posterior chamber lens and a short operation time as well as an easy operation technique.

V. Conclusions

Retropupillary iris-claw IOL combines the ease of anterior chamber IOL implantation with optical and physiological advantages of posterior IOL location, ensuring good refractive outcome and a low risk of complication. With careful wound construction surgery does not require suturing, which can reduce generated astigmatism. This type of IOL implantation is beneficial in all aphakic patients with contraindications for anterior chamber implant because of glaucoma or endothelial abnormality. The most common abnormalities after retropupillary iris-claw IOL implantation are ovalization and atrophy of the iris, which have no influence on visual or refractive outcomes. This surgical procedure has the advantages of a posterior chamber implantation with a low intraoperative and postoperative risk profile.

References

- [1]. C. Evereklioglu, H. Er, N. A. Bekir, M. Borazan, and F. Zorlu, "Comparison of secondary implantation of flexible open loop anterior chamber and scleral-fixated posterior chamber intraocular lenses," *Journal of Cataract and Refractive Surgery*, vol.29,no.2,pp.301–308,2003.
- [2]. J. Gonnermann, M. K. J. Klamann, A.-K. Maier et al., "Visual outcome and complications after posterior iris-claw aphakic intraocular lens implantation," *Journal of Cataract and Refractive Surgery*, vol.38,no.12,pp.2139–2143,2012.
- [3]. M. Schallenberg, D. Dekowski, A. Hahn, T. Laube, K.-P. Steuhl, and D. Meller, "Aphakia correction with retropupillary fixated iris-claw lens (Artisan)—long-term results," *Clinical Ophthalmology*, vol.8,pp.137–141,2013.
- [4]. Sawada T, Kimura W, Kimura T, et al. Long-term follow-up of primary anterior chamber intraocular lens implantation. *J Cataract Refract Surg*. 1998;24(11):1515–1520. [[PubMed](#)] [[Google Scholar](#)]
- [5]. L. Drolsum, "Long-term follow-up of secondary flexible, open loop, anterior chamber intraocular lenses," *Journal of Cataract and Refractive Surgery*, vol.29,no.3,pp.498–503,2003. [3] T. C. Y. Chan, J. K. M. Lam, V. Jhanji, and E. Y. M. Li, "Comparison of outcomes of primary anterior chamber versus secondary scleral-fixated intraocular lens implantation in complicated cataract surgeries," *American Journal of Ophthalmology*, vol.159,no.2,pp.221–226.e2,2015.
- [6]. J. G. Worst, "Iris claw lens," *American Intra-Ocular Implant Society Journal*, vol.6,no.2,pp.166–167,1980.
- [7]. L. Amar, "Posterior chamber iris claw lens," *American Intra Ocular Implant Society Journal*, vol.6,no.1,p.27,1980.

- [8]. A.Mohr,F.Hengerer,andC.Eckardt,“Retropupillary fixation of the iris claw lens in aphakia. 1 year outcome of a new implantation techniques,”*DerOphthalmologe*,vol.99,no.7,pp. 580–583,2002.*Journal of Ophthalmology*

Dr. Sanjeev K Nainiwal. “Visual outcomes following retropupillary iris-claw lens implantation.” *IOSR Journal of Dental and Medical Sciences (IOSR-JDMS)*, vol. 18, no. 10, 2019, pp 31-36.