

## Role of MRFistulogram in Preoperative Assessment of Anorectal Fistulas and Its Correlation with Intraoperative Findings.

Dr.X. Infant Pushpa Venisha<sup>1</sup>, Dr.Subhashree Chandrasekaran<sup>2</sup>,  
Dr. Murali Nanjundan<sup>3</sup>

1-3(Department Of Radiodiagnosis, Coimbatore Medical College, Tamilnadu, India)

Corresponding Author: Dr.X. Infant Pushpa Venisha

---

### Abstract

#### Aims and Objectives

The aim of the study is to evaluate the role of MR FISTULOGRAM in preoperative assessment of anorectal fistulas and to correlate MR findings with intra operative findings. Additionally, the usefulness of contrast study and 3DT1 FAT SAT sequences are also evaluated.

#### Materials and Methods

This was a hospital based prospective observational study done in 60 patients who were diagnosed to have perianal fistula clinically and referred for MR fistulogram to our department during one year period from June 2016 to June 2017. The patients were subjected to MR fistulogram using 1.5- Tesla unit system. The following were assessed: type of fistula, position of internal opening, grading of fistula by St. James's University Hospital MRI Classification and the accuracy of MRI findings was correlated with intra operative findings.

#### Results

The most prevalent type of fistula was intersphincteric type followed by transsphincteric type. Contrast study was indispensable for identification of secondary tracts and abscesses. Our study showed sensitivity and specificity of 100% and 100% for abscesses and 80% and 100% for secondary tracts. According to St. James's University Hospital Classification, Grade I fistulas were the commonest followed by grade III fistulas. Fistulotomy was done in about 52 patients which correlated well with the MRI findings for grades 3 to 5. Correlation between surgical and MRI findings was significant with a "p value" of 0.008. 3D T1 FAT SAT sequence proved to be time saving and easily interpreted by the surgeons.

#### Conclusion

Perianal fistulas present with numerous complications like secondary tracts and abscess cavities. Incomplete evaluation of these complications can result in residual and recurrent disease. Also, to prevent injury to external sphincter and resultant fecal incontinence, it is necessary to establish the relationship of sphincter with the fistulous tracts. MRI satisfies all these needs of surgeons and helps in planning of surgery.

**Key words:** perianal fistula, fistulogram.

---

Date of Submission: 21-09-2019

Date of Acceptance: 10-10-2019

---

### I. Introduction

A fistula is defined as an abnormal connection between 2 structures or organs or between an organ and the surface of the body. Its prevalence is about 0.01% and young men are commonly affected. Detailed understanding of anorectal anatomy is needed for identification and management of anorectal fistulas. Park's and St James University Hospital classification are used, of which the latter gives better details of perianal fistulas.

#### 1.1 Materials and Methods

This was a hospital based prospective observational study conducted from June 2016 to July 2017. Around 60 patients, who were diagnosed to have perianal fistula clinically and referred for MR fistulogram to the Department of Radiology, Coimbatore Medical College Hospital, Coimbatore were included in the study. Patients with renal failure, allergic reactions, contraindications for performing MRI and recurrent anorectal fistulas are excluded from the study. Patients were subjected to MR fistulogram using 1.5- Tesla unit system. The contrast used was gadolinium DTPA 0.1mmol/kg at a rate of 1 ml/ second. The following were assessed: type of fistula, position of internal opening, grading of fistula by St. James's University Hospital MRI Classification and the accuracy of MRI findings was correlated with intraoperative findings.

MRI SEQUENCES	NON CONTRAST SCANS		NON CONTRAST FAT SUPPRESSED SCANS		CONTRAST ENHANCED FAT SUPPRESSED SCANS
	T1 W FSE	T2 W FSE	FS T1 W FSE	FS T2 W FSE	
					FS T1 W FSE WITH 3D RECONSTRUCTION
IMAGING PLANE	AXIAL AND CORONAL	SAGITTAL AXIAL CORONAL	AXIAL AND CORONAL	SAGITTAL AXIAL CORONAL	SAGITTAL, AXIAL CORONAL
TR/ TE (m sec)	633/ 11	5040/113	766/ 11	6320/116	500/ 11
FOV	345* 345	346*346	347*347	347*347	300*300
SECTION THICKNESS (mm)	6 mm	6 mm	6 mm	6 mm	6 mm
MATRIX	512*512	512*512	512*512	512*512	512*512

**1.2 Techniques**

The anal canal is tilted forward from the vertical by approximately 45 degree in the sagittal plane .Thus, the routine axial and coronal images are insufficient. It is necessary to obtain oblique axial and coronal images which are oriented orthogonal and parallel to the anal canal respectively.

**II. Results**

Of the total 60 patients, 39 weremales and 21were females. The mostprevalent type of fistula was intersphincteric type(53.33%) followed by transsphincteric type (38.34%).Extrasphincteric type of fistulawas seen in 5 patients (8.33%).The operative findings were wellcorrelating with the study with regard to the site of the openings.In our study, 16 patients had secondarytracts.On contrast study, all of them showed enhancement. Abscesses were identified in 11patients. On contrast study, all the 11 patients showed contrast enhancement that helped indemonstrating the extent of the abscess. This correlation was statisticallysignificant with a “p value” of 0.001. Hence, it couldbe concluded that contrast study is absolutely necessary for assessing thecomplications arising due to perianal fistulas. This was superior to the result given by Maier et al [1] in his study who showed a 84% sensitivity of MRI for the identification of perianal fistulas and abscesses. The better results of our study may be attributed to the use of contrast enhanced imaging. This is inconcordance with the study done by Dariusz et al [2] and M.E. Agha et al.[3]

Perianal fistulas were classified on the basis of StJames’s University Hospital Classification. Grade Ifistulas were the commonest which was found in 20 patients (33.33%) followed by grade III fistulas which was found in 16patients (26.66%). Fistulotomy was done in 52 patients and correlated well with the MRI findings for grades3 to 5. Grade 1 and 2 fistulas showed discrepancies in identification. Four patients who were initially classified under grade I had secondary tracts as an additional per operative finding. Abscess drainage was also done in 5 patients (8.35%) which were also inaccordance with MRI findings.Correlationbetween surgical and MRI findings was significant in our study with a “pvalue” of 0.008. The result obtained (86.78%) was comparable with the result obtained from the previous study conducted by Lunniss et al which reported a concordance rate of 86- 88% between MRI and surgical findings. The sensitivity and specificity of MRI for grade I andII fistulas were in the order of 100%, 91.66% and 78.94%, 100%respectively. For other grades, the sensitivity and specificity were 100%and 100%. 3D T1 FAT SAT sequence proved to be time saving and easily interpreted by the surgeons.

**III. Figures and Tables**

**Table 1: St James Grading**

ST JAMES GRADE	NO OF PATIENTS	PERCENTAGE
I	20	33.33%
II	11	18.33%
III	16	26.66%
IV	8	13.33%
V	5	8.35%

**Table 2: Diagnosis of Secondary Track Using Contrast**

CONTRAST ENHANCEMENT	SECONDARY TRACK	
	PRESENT	ABSENT
PRESENT	16	0
ABSENT	4	40

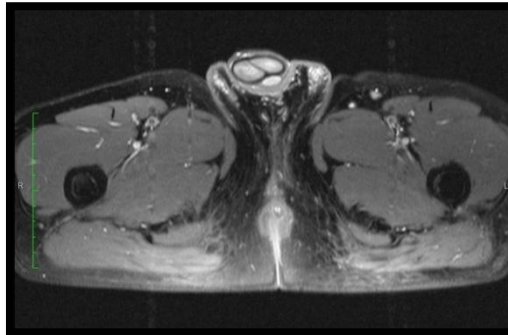
**Table 3: Diagnosis of Abscess Using Contrast**

CONTRAST ENHANCEMENT	ABSCESS	
	PRESENT	ABSENT
PRESENT	11	0
ABSENT	0	49

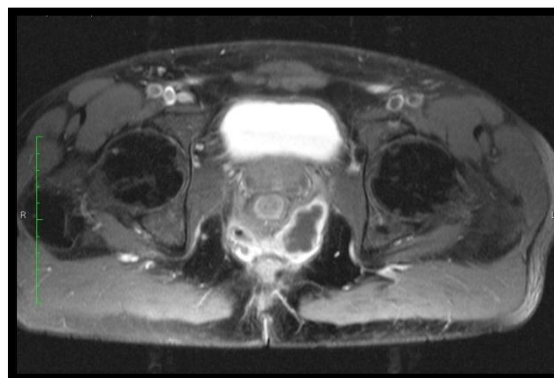
**Table 4: MRI Grading And Surgical Concordance**

ST JAMES GRADE CATEGORY	NO OF PATIENTS GRADED AS PER MRI	NO OF PATIENTS WITH CONCORDANT SURGICAL FINDINGS	NO OF PATIENTS NOT OPERATED	MRI- SURGICAL CONCORDANCE
I	20	15 (4 patients per-operatively categorized as grade II)	1	Sensitivity- 100% Specificity-91.66%
II	11	11	-	Sensitivity- 100% Specificity-100%
III	16	15	1	Sensitivity -100% Specificity- 100%
IV	8	8	-	Sensitivity -100% Specificity- 100%
V	5	4	1	Sensitivity -100% Specificity- 100%

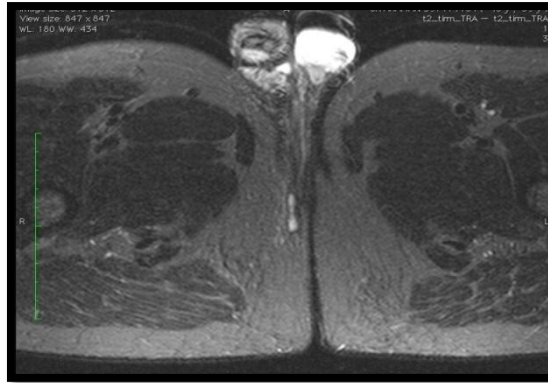
Figures  
St.James University Hospital Classification



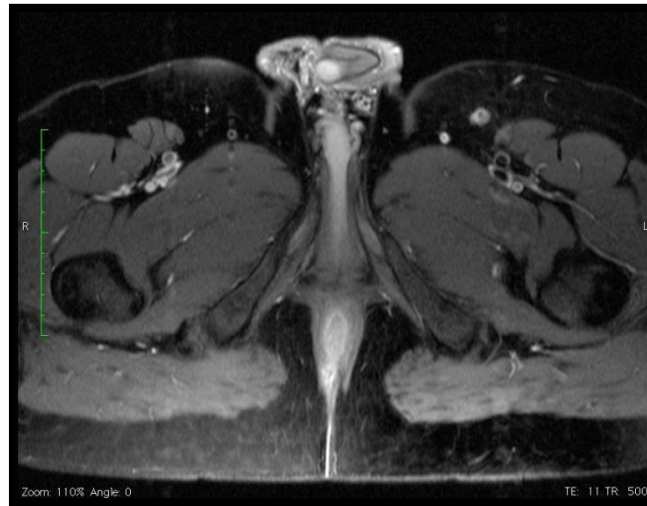**Fig 1 Grade 1:** Simple linear intersphincteric fistula:



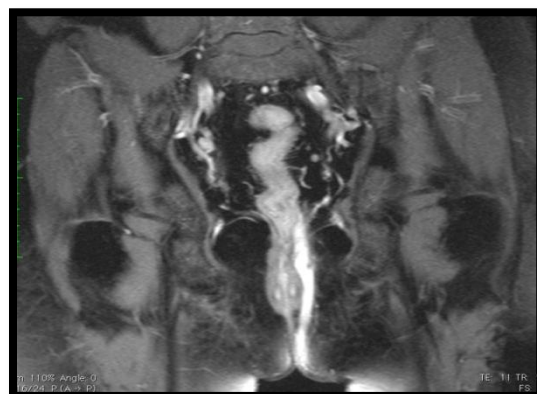
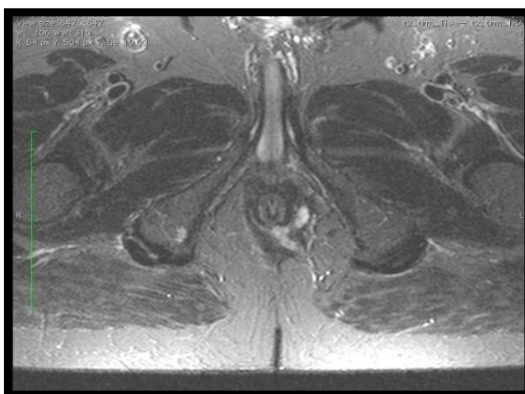
**Fig 2 Grade 2:** Intersphincteric Fistula with Abscess



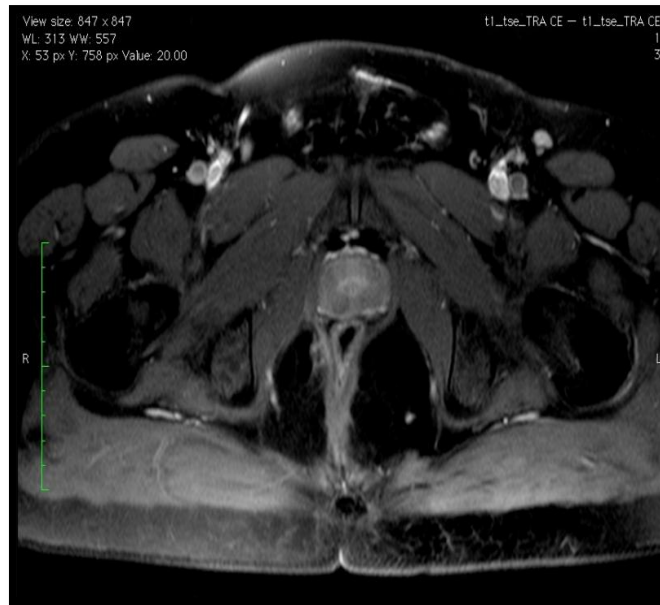
**Fig 3 Grade 2:** Intersphincteric Fistula with Secondary Tracks



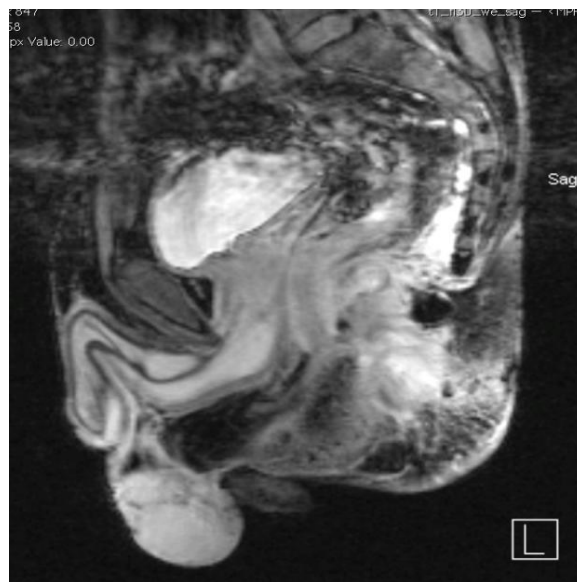
**Fig 4 Grade 3:** Transsphincteric Fistula



**Fig 5 Grade 4:** Transsphincteric Fistula with Abscess/ Secondary Track



**Fig 6 Grade 5: Supralevator&Translevator Disease**



**Fig 7 3D T1 FATSAT contrast enhanced MRI showing abscess**

#### **IV. Discussion**

Idiopathic fistulas arise due to chronic phase of intramuscular anal gland sepsis, which is called the cryptoglandular hypothesis. There are also other causes of perianal fistulas- like Crohn's disease, ulcerative colitis, carcinoma, lymphogranuloma venereum, hydradenitis suppurativa, tuberculosis, trauma during child birth, pelvic infection, pelvic malignancy and radiation therapy. The primary pathology is the obstruction of anal gland leading to secondary abscess formation and then external rupture of the abscess. The most common presenting symptom is discharge from a cutaneous orifice (in 65% of cases) but local pain due to inflammation is also common.

The course of fistula is dependent on the location of the infected anal gland. The internal opening usually lies at the level of dentate line. In most cases, the opening is at the 6 o'clock position. This is because anal glands are most abundant posteriorly. The complications of perianal fistulas include abscess formation, formation of secondary tracts and sepsis. Abscess usually develops along the course of fistulous tracts. Characteristically, the abscesses of intersphincteric fistulas are perianal or encysted within the intersphincteric space. Transsphincteric fistulas are associated with ischioanal fossa abscesses.

#### **4.1 Imaging in perianal fistulas**

There are several imaging modalities in perianal fistula. These include X ray fistulography, endoanal ultrasonography, CT fistulography and MR fistulogram.

#### **4.2 X ray fistulography**

Xrayfistulography was the primitive traditional imaging technique which involves thecannulation of the external fistulous opening and injection of water soluble contrast material into the fistula .The sensitivity ranges from 24- 50%. This method has 3 main disadvantages. The primary tract may not be visualised if they are plugged with pus and debris. Secondary fistulous tracts may not be visualised and internal opening cannot be precisely determined due to absence of definite anatomic landmarks. Sphincter muscle anatomy is not better delineated.

#### **4.3 Endoanal ultrasonography**

Endoanal ultrasonography is a recently emerging modality that has advantage of better delineation of fistulous tract and its relationship with sphincter muscles. [4] ENDO ANAL ULTRASOUND is also helpful for imaging rectal wall. The disadvantages are that the technique is operator dependent, provides limited field of view and absence of imaging in coronal plane. Also infection cannot be distinguished from fibrosis and failure to identify secondary tracts and distant sepsis are its disadvantages. EAUS cannot reveal high pathological lesions like suprasphincteric lesions, subcutaneous lesions, horseshoe type lesions and smaller additional branches. It is useful in assessment of sphincters inpostoperative cases and in smaller interventional procedures like incision and drainage.

#### **4.4 CT fistulography**

CT fistulography may be performed with the contrast media administered rectally and intravenously. The attenuation values for sphincters, levatorani, fibrosed tracts and active fistulas are almost similar, so that it is difficult to differentiate these structures. CTfistulography fails to define subtle fistulas and abscesses due to poor resolution of soft tissue. [5] This could not fulfil the preoperative needs of the surgeon.

#### **4.5 MR imaging of perianal fistulas**

The main aim towards which the treatment is directed iseradication of infection while preserving the anal continence. In order toachieve this, the surgeon needs to know the relationship of the tract toanal sphincter muscles and proper delineation of secondary tracts in orderto prevent recurrence. When the efficacy of endoanal ultrasonography was compared with digital rectal examination and MR imaging in 108 primary fistuloustracts, the proportion of fistulous tracts correctly identified with each modality was 61% with digital rectal examination, 81% with endoanal ultrasonography and 91% with MR imaging. [6] In addition, endoanal ultrasonography aided in correct identification of internal opening in 91% of patients when compared with 97% in patients who underwent MRimaging. So, MRI is the superior imaging technique in all aspects and endoanal ultrasonography is an alternative for identification of internal opening. Lunniss et al reported concordance rate of 86-88% between MRI and surgical findings. [7] Buchanan et al showed that surgery guided by MRI reduced further recurrence by 75% in patients with recurrent anal fistula. [8]

#### **4.6 Normal MRI anatomy**

The external anal sphincter (striated muscle) is seen onMRI as hypointense structure on T1W, T2W and fat suppressed T2Wimages. The internal anal sphincter (smooth muscle) is hypointense onT1W and T2W TSE images and is relatively hyperintense on fat –suppressed T2W images. It shows enhancement in post contrast study.The coronal images show levatorani clearly.The puborectalis ringis seen as thickening of superior fibres of external sphincter. Thepuborectalis superiorly merges with the levator muscles.

#### **4.7 Pathological Appearances in Perianal Fistula**

Unenhanced T1 weighted images give excellent anatomic overview of sphincter complex, levator plate andischiorectal fossa. T2 weighted images provide good contrast betweenhyperintense fluid in track and hypointense fibrous wall of fistula. [9]On gadolinium enhanced fat suppressed T1 weighted images, fistuloustracts, abscess cavities and active granulation tissue show intense enhancement while fluidin the track remains hypointense. Normal anorectal structures do not enhance on contrastadministration except internal anal sphincter and blood vessels.Chronicfistula and scar do not enhance fibrotic tracts appear as linear structureswhich appear hypointense on both T1 and T2 weighted images. STIR sequences provide good fat suppression and inflammatorychanges are better appreciated due to long T1 & T2 relaxation times.STIR images are at times misinterpreted. Sometimes, they fail todemonstrate secondary tracts and small residual abscesses. They mayspuriously show high signal intensity within inactive tracts. Unenhanced T1 weighted images are also

useful in postoperative assessment. Hemorrhage during the immediate postoperative period appears hyperintense and hence can be distinguished from a residual tract which will appear hypo to isointense on T1 images. [10]

#### **4.8 Classification of perianal fistulas**

Parks et al described perianal fistulas in coronal plane according to its relationship with sphincters and course of fistula. Depending on location and course of the primary tract, perianal fistulae have been classified into 4 types.

- Intersphincteric (incidence-60-70%)
- Transsphincteric fistula (incidence 20-30%)
- Suprasphincteric (Uncommon):
- Extrasphincteric (Uncommon)

MR imaging based classification is St James University Hospital Classification, which has 5 grades. It is easy to use as they are based on anatomical landmarks. This classification also considers both primary and secondary fistulous tracts and abscesses in classifying the types of fistulas.

Grade 1: Simple linear intersphincteric fistula

Grade 2: Intersphincteric fistula with abscess or secondary tract:

Grade 3: Transsphincteric fistula

Grade 4: Transsphincteric fistula with abscess or secondary tract within the ischioanal fossa

Grade 5: Supralelevator and translevator disease

#### **4.9 Recent Advances in MR Imaging Evaluation Of Perianal Fistulas:-**

Three dimensional (3D) T2 weighted turbo spin echo (TSE) sequences can provide source data for postprocessing reformation of images into any desired plane. Therefore, a single 3D T2 weighted sequence with postprocessing reformation of images in all the 3 planes can replace the 2D sequences in those planes. The advantage of 3D imaging over 2D imaging includes no operator dependence in image acquisition, coverage of larger volume, ability to acquire thinner sections and reduction in imaging time.

#### **4.10 Implication of classification on patient management:**

It is proven that MR imaging is better than initial surgical exploration in prediction of patient outcome. When St James University Hospital classification was used, grading of fistulas was significantly associated with outcome. Grades 1 & 2 were associated with satisfactory outcome but grades 3 to 5 were associated with unsatisfactory outcome. Classification of fistulas is very important because treatment differs between different types of fistulous tracts. Simple submucosal, intersphincteric or low transsphincteric tracts affecting distal third of anal canal can be treated with fistulotomy alone without affecting the fecal continence. In cases of higher or complex fistulas, maintenance of continence is a problem.

### **V. Conclusion**

Perianal fistula, though an uncommon problem may be chronic and recurrent. It may present with numerous complications like secondary tracks and abscess cavities. Incomplete evaluation of these complications can result in residual and recurrent disease. So, complete preoperative evaluation of perianal fistulas is warranted. Also to prevent the injury to external sphincter and resultant fecal incontinence, it is necessary to establish the relationship of sphincter with the fistulous tracks. MRI satisfies all these needs of surgeons and helps in planning of surgery. Contrast enhanced MRI helps in identification of primary and secondary tracks, complications like abscesses and hence guides the surgeon to plan appropriate treatment strategy. Contrast enhanced MRI can identify active inflammation of tracks. It can also distinguish between scar and granulation tissue. 3D T1 FAT SAT sequence is the best and time saving sequence for imaging perianal fistulas.

### **References**

- [1]. Maier AG, Funovics MA, Kreuzer SH, et al. Evaluation of perianal sepsis: Comparison of anal endosonography and magnetic resonance imaging. *J Magn Reson Imaging*. 2001;14:254-60 [PubMed]
- [2]. Dariusz Waniczek, Tomasz Adamczyk, Jerzy Arendt, Ewa Kluczevska, Ewa Kozłowska-Marek. Usefulness assessment of preoperative MRI fistulography in patients with perianal fistulas. *Pol J Radiol*. 2011 Oct-Dec; 76(4): 40-44.
- [3]. Mahmoud E, Eid M, Mansy H, Matarawy K, Wally M (2013) Preoperative MRI of perianal fistula: Is it really indispensable? Can it be deceptive? *Alexandria Journal of Medicine* 49: 133-144.
- [4]. Van Outryve M, Pelckmans P, Fierens H, Van Maercke Y. Transrectal ultrasonographic examination of the anal sphincter. *Acta Gastroenterol Radiol* 1989;14(4):349-353
- [5]. Guillaumin E, Jeffrey RB Jr, Shea WJ, Asling CW, Goldberg HI. Perirectal inflammatory disease: CT findings. *Radiology* 1986;161(1):153-157

- [6]. Buchanan GN ,Halligan S, Bartram CI ,Williams AB, Tarroni D, Cohen CR. Clinical examination ,endosonography and MR imaging in preoperative assessment of fistula in ano: Comparison with outcome- based reference standard .Radiology 2004;233(3):674-681
- [7]. LunnisPJ ,Amstrong P, Barker PG, Reznik RH, Philips RK. MR imaging of the anal fistula. Lancet .1992; 340:394-6
- [8]. Lunniss PJ, Barker PG, Sultan AH, et al. Magnetic resonance imaging of fistula-in-ano. Dis Colon Rectum. 1994;37(7):708–18. [\[PubMed\]](#)
- [9]. Maier AG, Funovics MA, Kreuzer SH, Herbst F, Wunderlich M, Teleky BK ,et al. Evaluation of perianal sepsis: Comparison of anal sonography and MRI. J MagnReson Imaging .2001;14:254-60.
- [10]. Parks AG, Gordon PH, Hardcastle JD. A classification of fistula in ano Br J Surg.1976;63(1):1-12

Dr.X. Infant Pushpa Venisha. “Role of Mrfistulogram in Preoperative Assessment of Anorectal Fistulas and Its Correlation with Intraoperative Findings.” IOSR Journal of Dental and Medical Sciences (IOSR-JDMS), vol. 18, no. 10, 2019, pp 27-34.