

## A Clinical Study of Darier's Disease in Tertiary Care Hospital

Dr S Karimulla Basha<sup>1</sup>, Dr P Venkata ramana<sup>2</sup>, Dr G Ramesh kumar<sup>3</sup>

<sup>1</sup> Junior resident, Dept of D.V.L., S.V. Medical college, Tirupati

<sup>2</sup> Professor, Dept of D.V.L., S.V. Medical college, Tirupati

<sup>3</sup> Professor and Head, Dept. of D.V.L., S.V. Medical college, Tirupati

Corresponding Author: Dr P Venkata ramana

### Abstract

#### Introduction

Darier's disease is a rare inherited autosomal dominant acantholytic skin disease characterized by brownish keratotic papules predominantly in the seborrheic areas of the body, focal pinpoint to pinhead-sized spots on palms and other non-cutaneous changes like cobblestone-like papules on the palate, nail changes like v-shaped nicking. The disease is often exacerbated in summer.

#### Aims and Objectives

To study clinical, Histo-pathological features and variants of dariers disease

#### Methodology

A prospective observational study was conducted in S.V.R.R.G.G.H., Tirupathi for a period of 1 year. We selected 15 patients of Darier's disease, and detailed clinical and histopathological evaluation was done in all the patients.

#### Results

Age of onset is 0-10 years in 6.6%, 10-20 years in 53.3%, 20-30 years in 26.6%, >30 years in 13.3%. Of 15 cases, 8 were males, and 7 were females. Family history present in 66.6 % of cases. Yellowish-brown papules were the commonest clinical presentation seen in 100% of cases, Hyperkeratotic plaques were seen in 13.3%, Palmar pits seen in 80%, Guttate leukoderma in 6.6%, Nail changes like V-shaped nicking seen in 86.6%, Cobblestone appearance on palate and tongue saw in 60%. The histopathological features are seen were suprabasal acantholysis (80%), acantholytic cells (66.6%) and corps ronds and grains (86.6%).

#### Conclusion

Most of the cases in our study shows classical clinical and histopathological features described in literature except 3 cases, in which one is hyperkeratotic variant and other two are linear variants.

**Key words:** Darier's disease, keratosis follicularis,

Date of Submission: 21-09-2019

Date of Acceptance: 10-10-2019

### I. Introduction

Darier's disease is also known as Darier and white disease as it was independently described by Darier and white in 1889(1). It is also known as keratosis follicularis, but this term appears to be a misnomer as most papules are non follicular in location. It is rare inherited acantholytic skin disease transmitted in autosomal dominant pattern with complete penetrance and variable expression.

It is characterized by brownish keratotic papules predominantly in the seborrheic areas of the body, focal pinpoint to pinhead-sized spots on palms and other non-cutaneous changes like cobblestone-like papules on the palate, nail changes like v-shaped nicking(2-4).

Darier's disease has a worldwide distribution with prevalence between 1 in 30,000 to 1 in 1,00,000 population(1,5) and often affects males and females equally. It is due to mutation in ATPA2A2 gene located at chromosome locus 12q23-24 which encodes sarcoplasmic/endoplasmic reticulum Ca<sup>2+</sup>- ATP (SERCA2) channel which maintains calcium homeostasis of the cell which in turn result in cell differentiation and cell adhesion. Characteristic Histopathological changes in dariers disease are suprabasal cleft with acantholysis and dyskeratosis results in corps ronds and grains. Other non-specific changes are hyperkeratosis, acanthosis, papillomatosis.

### II. Aim and objectives

To study clinical, Histo-pathological features and variants of dariers disease

**III. Material and methods**

**Study design** - Prospective observational study

**Place of study** - S.V.R.R.G.G. hospital, Tirupathi, Andhra Pradesh

**Duration of study** - 1 year [June 2018 to May 2019]

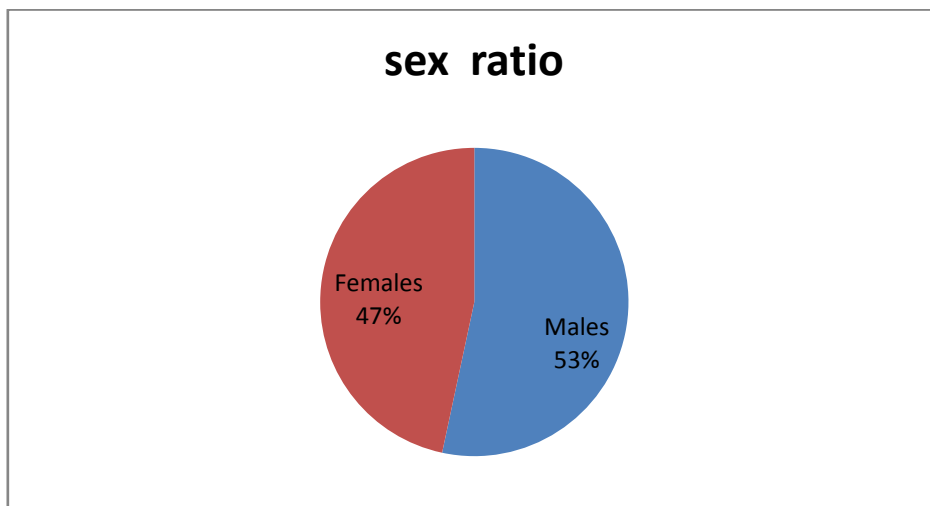
**Methodology;** 15 patients of clinically diagnosed cases of Darier's disease was selected after taking valid written informed consent. Prior to the study, institutional ethical committee permission is taken. A general and cutaneous examination done in all patients. Routine blood investigations like R.B.S., RFT, C.B.C., LFT and urine examination were done. A histopathological examination was done in all patients. Clinical and histopathological features of patients are collected in proforma. Results are tabulated and analyzed.

**IV. Results**

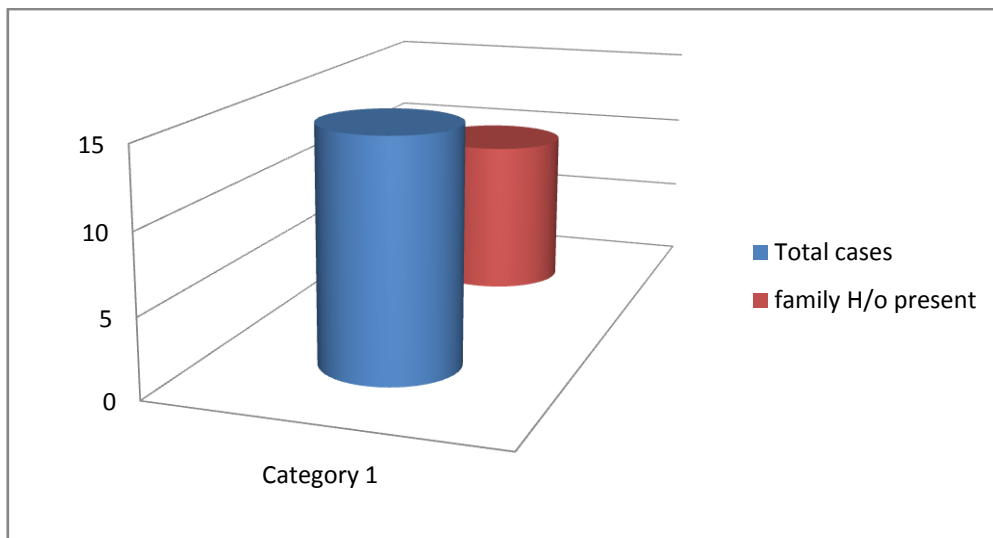
Demographic data are shown in tables 1 and chart 1&2. Clinical features are shown in tables 2,3&4 histopathological changes are shown in table 5 In our study, two types of variants of Darier's disease present, they are linear variant(6) and hyperkeratotic variant.(7)

**Table 1**

Age of onset ( in yrs)	% of patients
0 - 10	6.6
10-20	53.3
20-30	26.6
31-40	6.6
>40	6.6



**Chart 1** showing sex incidence



**Chart 2** showing a history of family members involvement

**Table 2**

Cutaneous changes	Percentage
Yellowish-brown papules	100
Palmar pits	80
Hyperkeratotic plaques	13.3
Guttate leukoderma	6,6

**Table 3**

Sites of involvement	Percentage of cases
Trunk	100
Behind the ears	86.6
Forehead	80
Inguinal region	66.6
Dorsum of hands	86.6

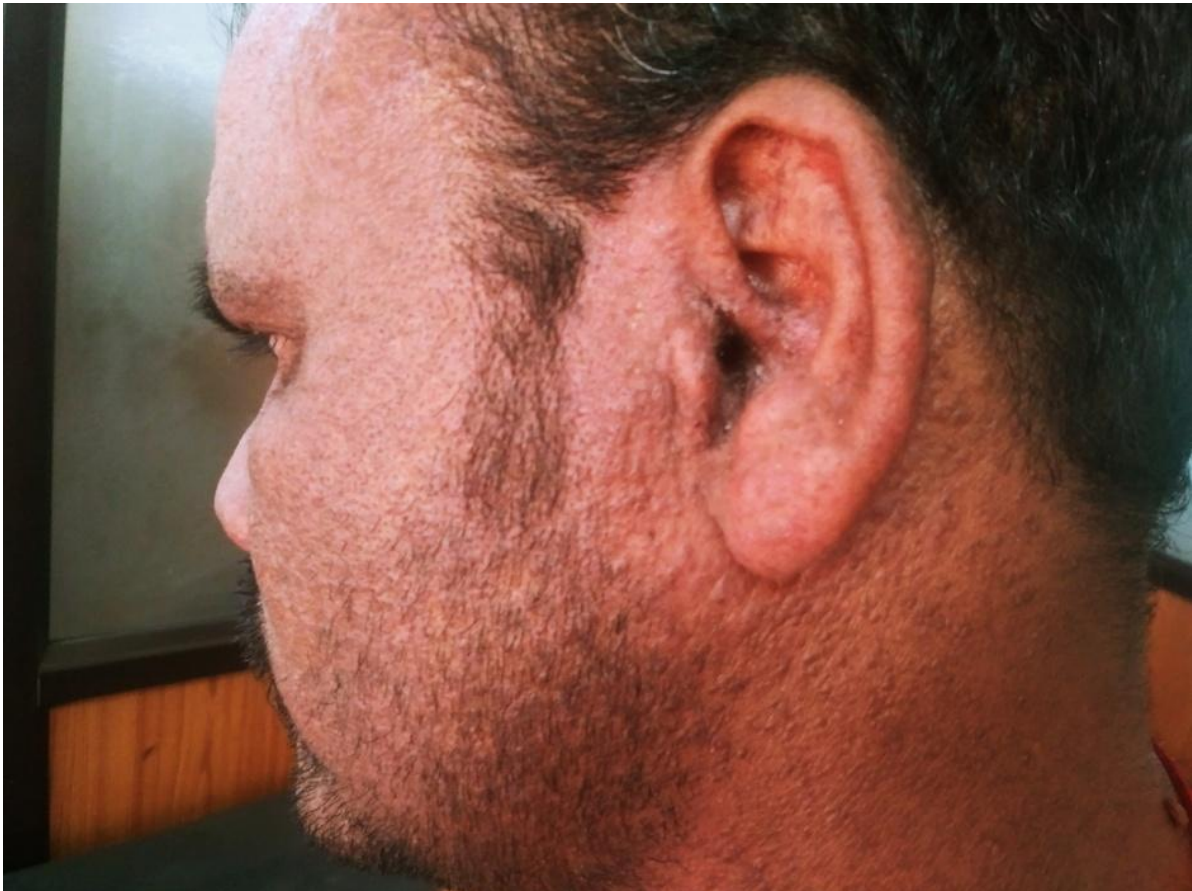**Table 4**

Nail changes	Percentage
V-shaped nicking	86.6
White & Red longitudinal streaks	93.3
Nail dystrophy	13.3

**Cobblestone appearance on tongue and palate are seen in 60 % of cases**

**Table 5**

Histopathological changes	Percentage
Hyperkeratosis	100
Suprabasal acantholysis	80
Acantholytic cells	66.6
Corps ronds & grains	86.6



**Figure showing Greasy brownish papules**

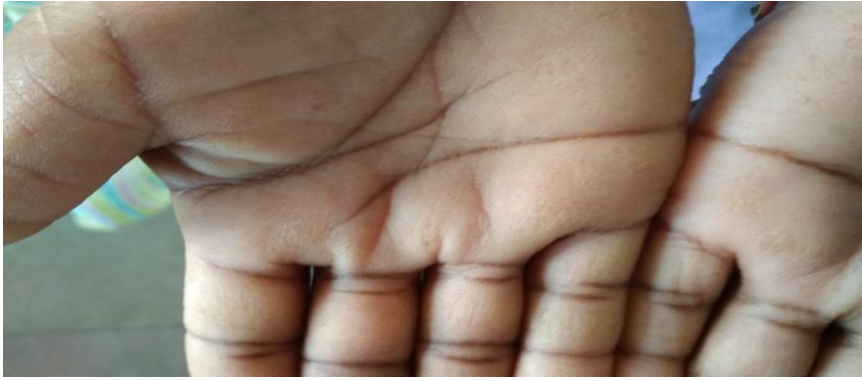

Figure showing palmar pits

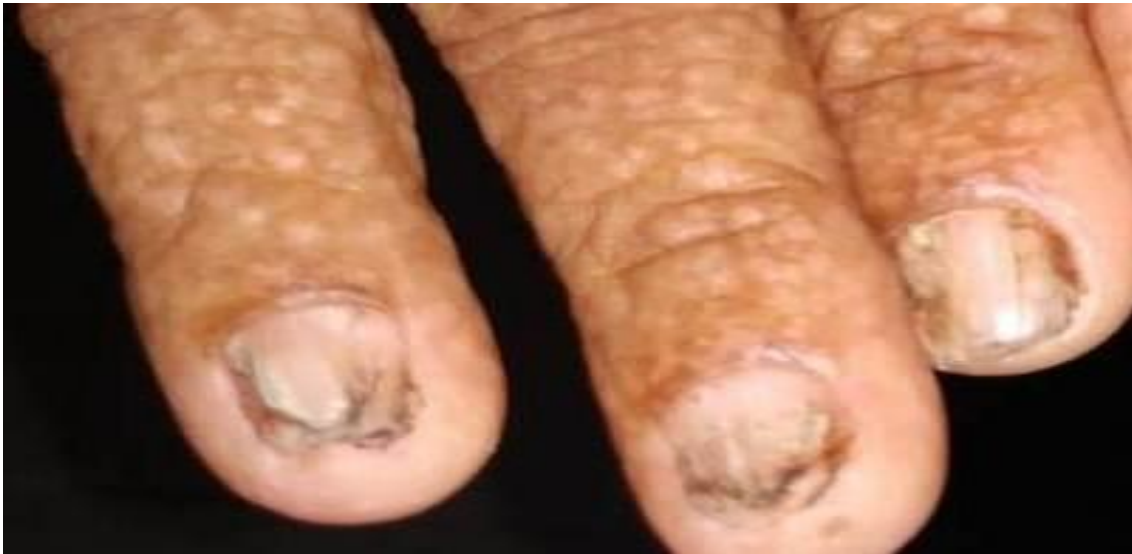

Figure showing Nails appearing dirty with sub-ungual hyperkeratotic material protrude from free edge and Vshaped nicking

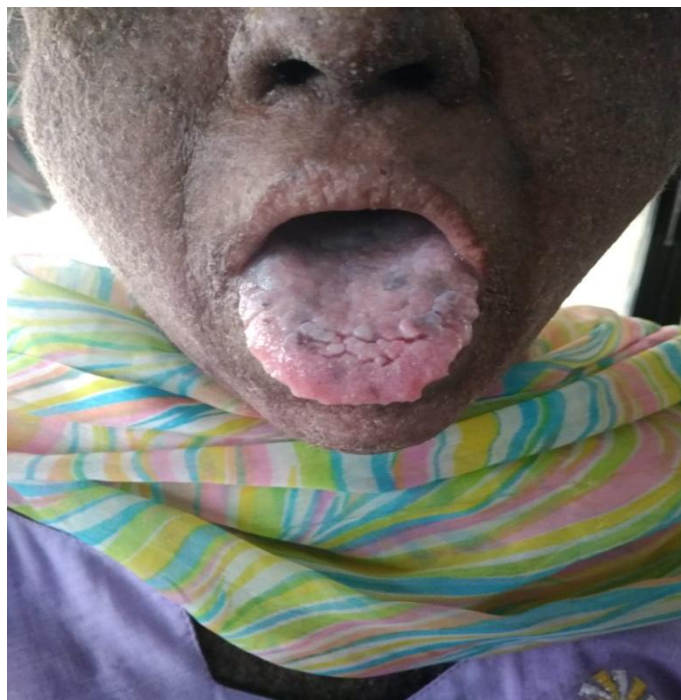


Figure showing fissured and cobblestone appearance of the tongue

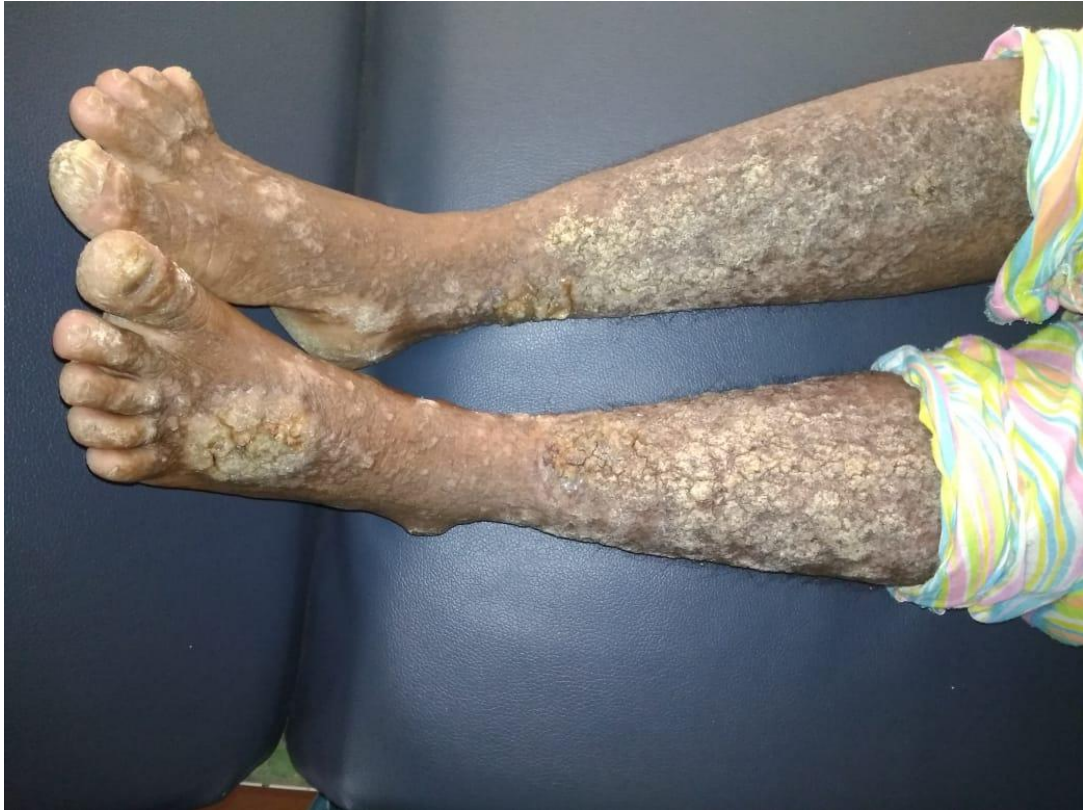

Figure showing Hyperkeratotic plaque over legs

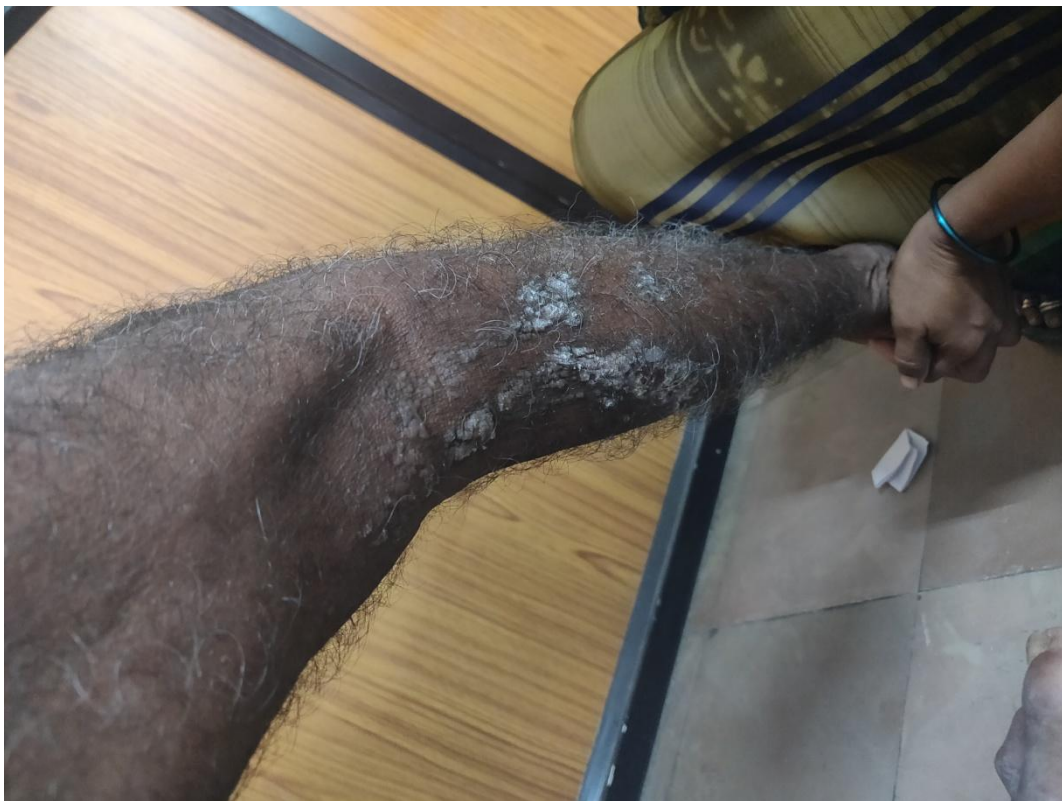

Figure showing warty brown papules over the posterior aspect of the leg

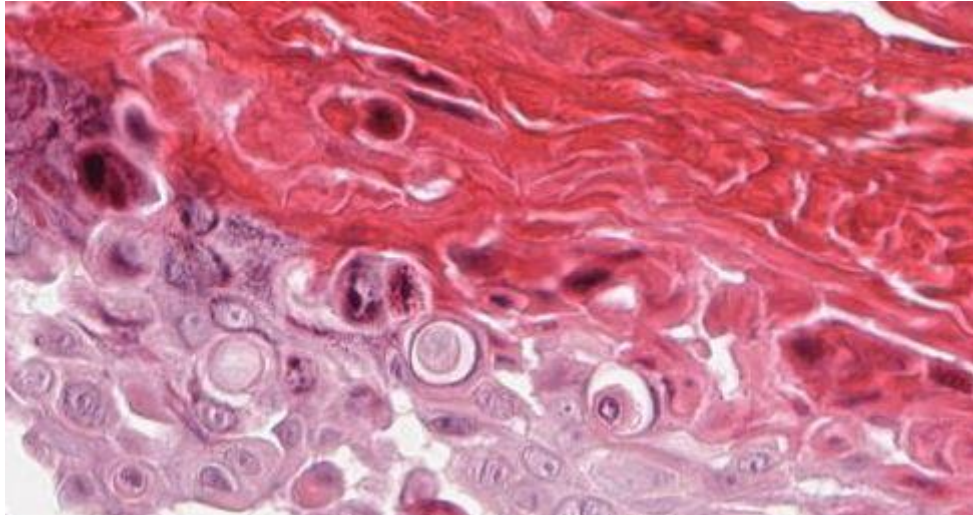


Figure showing corps ronds and grains

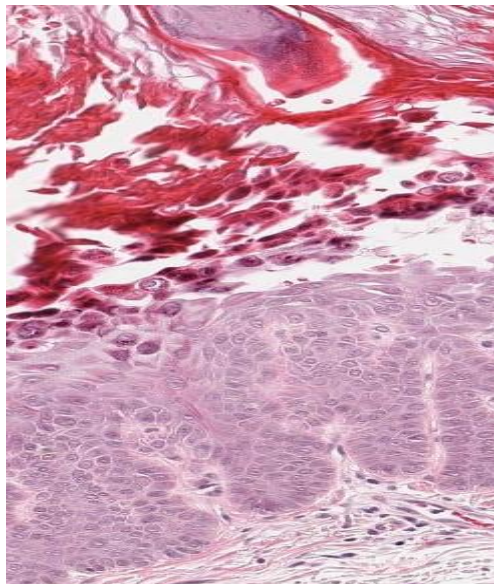


Figure showing supra basal acantholysis

## V. Discussion

In our study, the usual age of onset is between 10 to 20 yrs is 53.3% which is similar to previous studies(2,4). The earliest age of onset, in one case, is 5 yrs.

	Our study	Burge et all(2)	Neerja puri study(4)
The peak age of onset	10-20 yrs	6-20 yrs	10-20 yrs
Male: female ratio	1.14:1	1.2:1	2:1
Family H/o present	66.6%	53%	53.3%

In our study, clinical features recorded are yellowish-brown greasy papules present in 100% cases, palmar pits are present in 80 % of cases and characteristic nail changes like alternate white and red longitudinal streaks in 93.3% case V-shaped nicking seen in 86.6% of cases and cobblestone appearance of palate and tongue seen in 60 % cases. These findings are almost similar in previous studies.(2,4)

Histopathological examination of skin biopsy specimens in our study shows specific changes like suprabasal acantholysis in 80% cases, corps ronds and grains in 86.6% cases which is almost similar to previous studies(1,2,4,8–10)

Darier's disease is often insidious in onset and gradually progressive. Skin lesions Often begin with small groups of keratotic papules in seborrheic areas like the front of the anterior chest, behind ears, hair margins, and posterior side of mid trunk later papules coalesce to form plaques and malodorous papillomatous

growth over flexural sites of the body. Heat, sweat, stress lithium and oral corticosteroids aggravate the disease process.

Differential diagnosis of classical Darier's includes Seborrheic dermatitis, where other sites of involvement like Nail and hand are absent. Erosive/bullous flexural Darier's from Hailey-Hailey disease (other cutaneous sites are not involved) and pemphigus Vulgaris/vegetans (immunofluorescence tests are positive). An acral variant of Darier's disease from acrokeratosis verruciformis of Hopf ( Histology shows church spire pattern of hyperkeratosis).

Clinical variants of Darier's disease are vesiculobullous type(11), hyperkeratotic type, segmental type and comedonal and acral hemorrhagic type(12). In our study One female patient of cornified Darier's disease is presented where hyperkeratotic verrucous plaques present over legs and arms and Two male patients of linear segmental Darier's disease are presented where grouped yellowish-brown papules in linear fashion developed over the right side of the body, and another side of the body is spared

In rare instances, It is associated with neuropsychiatric disorders such as epilepsy, bipolar affective disorder, mental retardation and schizophrenia(2). In our study of 15 patients none of the patients shows associated features.

Darier's disease had a chronic relapsing course and as the age of the patient progresses disease may improve or deteriorate(2,8)

## **VI. Conclusion**

Most of the cases in our study shows classical clinical and histopathological features described in literature except three cases where one hyperkeratotic variant and two linear variants are seen.

### **Declaration of patient consent**

The authors certify that they have obtained all appropriate consent forms. In these form, the patient(s) has/have given his/her/their consent for his/her/their images and other clinical information to be reported in the journal. The patients understand that their names and initials will not be published and due efforts will be made to conceal their identity, but anonymity cannot be guaranteed.

### **Financial support and sponsorship**

Nil

### **Conflicts of interest**

No conflicts of interest

## **References**

- [1]. Cooper SM, Burge SM. Darier's Disease: Epidemiology, Pathophysiology, and Management. *Am J Clin Dermatol.* 2003;4(2):97–105.
- [2]. Burge SM, Wilkinson JD. Darier-White disease: a review of the clinical features in 163 patients. *J Am Acad Dermatol.* 1992;27(1):40–50.
- [3]. Burge SM. Darier's disease, keratins and proteases: a review. *J R Soc Med.* 1989;82(11):673–676.
- [4]. Puri N. A clinical and histopathological study of Darier's disease. :5.
- [5]. Munro CS. The phenotype of Darier's disease: penetrance and expressivity in adults and children. *Br J Dermatol.* 1992;127(2):126–130.
- [6]. Sanderson EA, Killoran CE, Anita P-L, Wilkel CS. Localized Darier's disease in a Blaschkoid distribution: Two cases of phenotypic mosaicism and a review of mosaic Darier's disease. *J Dermatol.* 2007 Nov;34(11):761–4.
- [7]. Katta R, Reed J, Wolf JE. Cornifying Darier's disease. *Int J Dermatol.* 2000 Nov;39(11):844–5.
- [8]. Rand R, Baden HP. Commentary: Darier-White disease. *Arch Dermatol.* 1983;119(1):81–83.
- [9]. BECK JR AL, FINOCCHIO AF, WHITE JP. Darier's disease: a kindred with a large number of cases. *Br J Dermatol.* 1977;97(3):335–339.
- [10]. Inada M, Shimizu H, Yamada S, Sasaki Y, Nishikawa T. Three cases of Darier's disease in a family showing marked heterogeneous clinical severity. *Dermatology.* 1999;198(2):167–170.
- [11]. Telfer NR, Burge SM, Ryan TJ. Vesiculo-bullous Darier's disease. *Br J Dermatol.* 1990;122(6):831–834.
- [12]. Foresman PL, Goldsmith LA, Ginn L, Beck AL. Hemorrhagic Darier's disease. *Arch Dermatol.* 1993;129(4):511–512.

Dr P Venkata ramana. "A Clinical Study of Darier's Disease in Tertiary Care Hospital." *IOSR Journal of Dental and Medical Sciences (IOSR-JDMS)*, vol. 18, no. 10, 2019, pp 06-12.