

## Study of Effects on Anterior Segment Morphometry by Pentacam Evaluation after Small Incision Cataract Surgery

<sup>1</sup>Dr. Sanjeev Kumar Nainiwal Professor & Head, <sup>1</sup>Dr. Rajesh Kumar Saini  
Assistant Professor <sup>2</sup>Dr. Ridhima Sharma MS

<sup>1</sup>Department of Ophthalmology, J. L. N. Medical College & Hospital Ajmer (Rajasthan), India

<sup>2</sup>Shroff Eye Hospital, New Delhi

Corresponding Author: Dr. Rajesh Kumar Saini

Assistant Professor Department of Ophthalmology, J. L. N. Medical College & Hospital Ajmer (Rajasthan),  
India

### Abstract:

**Purpose:** To quantify the effects on the anterior segment morphometry and intraocular pressure (IOP) and timing of prescribing of glasses after uneventful small incision cataract surgery (SICS) with intraocular lens implantation in patients normal individuals.

**Materials and methods:** Study included 93 eyes of 93 patients undergoing small incision cataract surgery, followed by posterior chamber intraocular lens implantations (PC IOL). The Pentacam rotating Scheimpflug camera measured the following changes that occurred in the anterior chamber: depth (ACD), angle (ACA), central corneal thickness (CCT) and astigmatism. Additionally, Goldmann applanation tonometry (corrected with Pentacam based) was used to evaluate intraocular pressure (IOP). All measurements were first taken preoperatively and subsequently at 1<sup>st</sup> weeks, 4<sup>th</sup> weeks and 6<sup>th</sup> weeks postoperatively.

**Results:** When measured at 1, 4 and 6 weeks postoperatively, the mean ACD, and ACA increased in all groups ( $p < 0.0001$ ). Astigmatism significantly showed changes up to 4<sup>th</sup> week ( $P = 0.0017$ ) and insignificant at 6<sup>th</sup> week. The IOP decreased throughout all postoperative periods ( $p < 0.0001$ ).

CCT significantly increased in 1<sup>st</sup> week ( $P < 0.0001$ ) but latter return to near normal 4<sup>th</sup> week ( $P = 0.056$ ) and 6<sup>th</sup> week ( $P = 0.814$ ). We found insignificant postoperative pachymetric changes when compared to the preoperative period ( $p > 0.05$ ).

**Conclusions:** Cataract surgery significantly increased ACD and ACA in all individuals. IOP was significantly decreased after surgery, however, there was insignificant changes of CCT. The astigmatism stabilised at 4th to 6th week so glasses can be prescribed in this period.

**Key words:** ACD, ACA, CCT, SICS, Astigmatism

Date of Submission: 19-09-2019

Date of Acceptance: 07-10-2019

### I. Introduction

Cataract surgery results in a reduction in intraocular pressure (IOP) in eyes with or without glaucoma, and/or ocular hypertension (OHT).[1,2] As a result of extraction of the natural lens and implantation of the intraocular lens (IOL) which is thinner than natural lens, the depth and volume of anterior chamber increases, the angle between cornea and iris widens and the iris moves backward.[3] At the same time, there is increase of endogenous prostaglandin F2 secretion, an inflammatory mediator, causing an increase in uveoscleral outflow of aqueous humor. All these causes may be influential on the reduction of IOP after cataract extraction.

After cataract surgery corneal swelling and scaring start to stabilised after 2 weeks of phacoemulsification cataract surgery, refraction becomes stable after 2 week and can be used to prescribe corrective lenses at that time. This time may latter in small incision of cataract surgery (SICS).

The aim of this study is to evaluate the changes in IOP, anterior chamber depth (ACD), anterior chamber angle (ACA), and central corneal thickness (CCT) and Best time to prescribe glasses after SICS.

### II. Materials and Methods

93 patients with cataract (42 males, 51 females) who were operated between January 2018 and November 2018 were evaluated prospectively. Their mean age was  $61.32 \pm 11.12$  years (standard deviation [SD]) (45–88) years. Full ophthalmological examinations including uncorrected visual acuity, best corrected visual acuity (BCVA), IOP measurements, ACD, ACA, and CCT measurements, slit-lamp biomicroscopy, and fundus examination, were performed preoperatively and postoperatively. IOP measurements were made with

Goldmann Applanation Tonometer (TOPCON), and ACD, ACV, ACA, Astigmatism, CCT with Pentacam (OCULUS).

**Inclusion criteria:** Patients with normal IOP range, uncomplicated cataract undergone SICS with continuous capsulorhexis with IOL implantation in the capsular bag.

**Excluded criteria:** complicated and hyper- mature cataract, previous ocular surgery or intervention, glaucomatous and ocular hypertension and patients on antiglaucoma drugs.

Statistical analyses were performed by using SPSS version 22 program. Data were compared by using paired t-test.  $P < 0.05$  was accepted as significant.

### III. Results

The mean age of the patients was  $62.53 \pm 14.13$  years (range, 15 to 87 years) Preoperative mean BCVA of the patients was  $0.197 \pm 0.084$  (SD), postoperatively at 6<sup>th</sup> week it was  $0.095 \pm 0.141$  (SD) according to the logarithm of the minimum angle of resolution scores. This increase in vision was statistically significant ( $P < 0.0001$ )

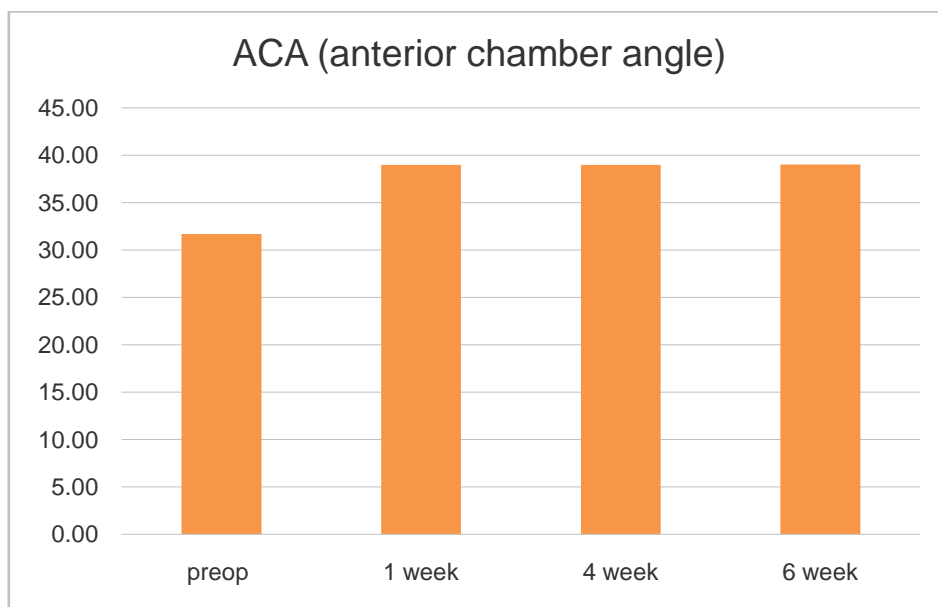
Preoperative mean IOP value was  $17.26 \pm 2.16$  (SD) mmHg, the decrease in IOP values of the 1<sup>st</sup> week  $14.32 \pm 1.98$  (SD) mmHg, 4<sup>th</sup> week  $14.13 \pm 1.63$  (SD) mmHg and 6<sup>th</sup> week  $14.22 \pm 1.72$  (SD) mmHg was statistically significant ( $P=0.0001$ ).

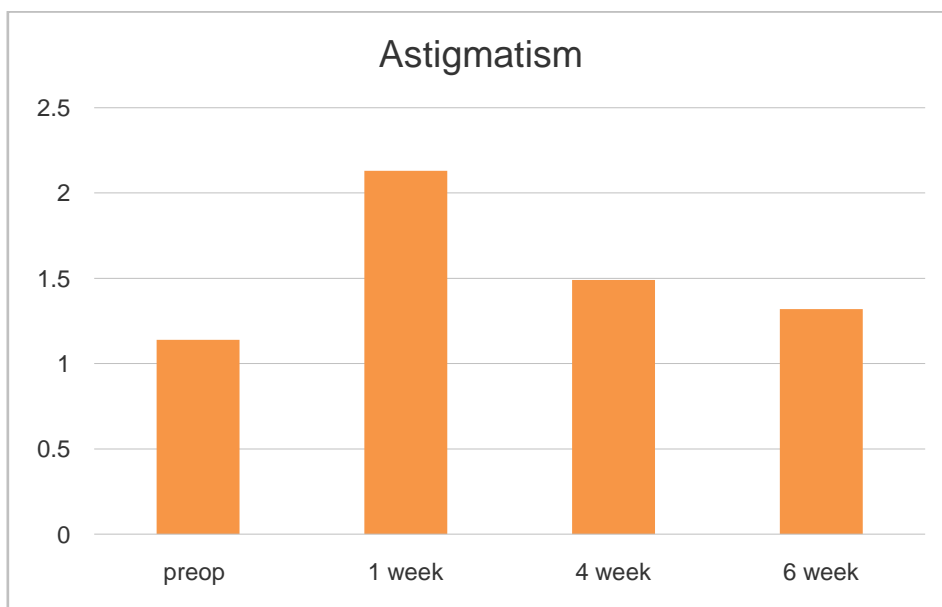
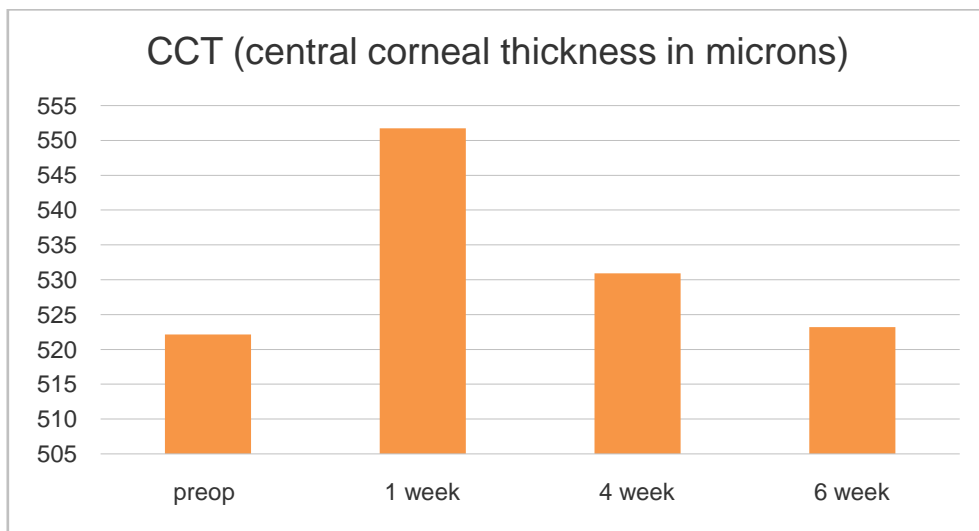
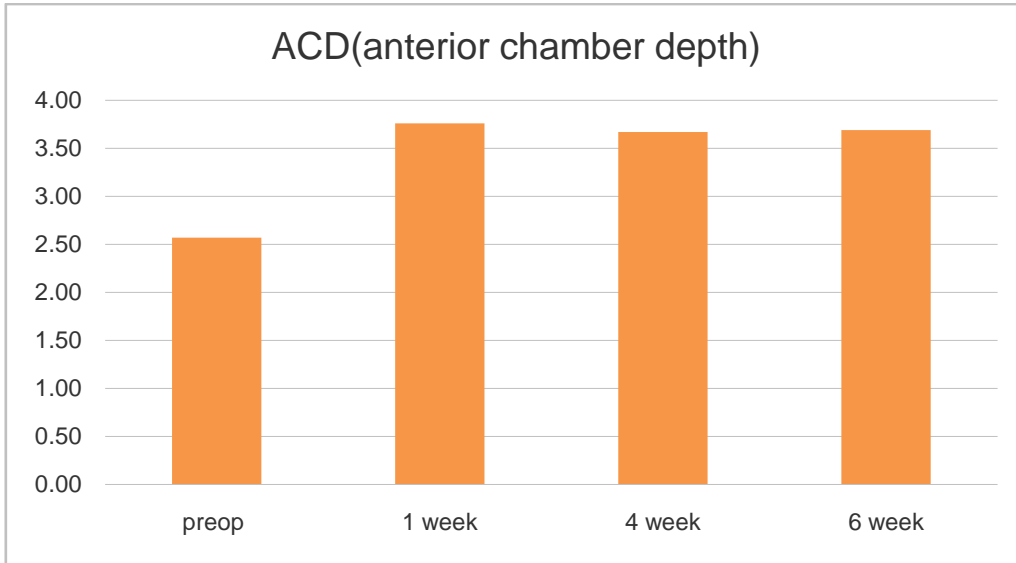
Preoperative mean ACD value was  $2.57 \pm 0.45$  (SD) mm. The increase in ACD values at the 1st week  $3.76 \pm 0.65$  (SD) mm, 4th week  $3.67 \pm 0.58$  (SD) mm and 6th week  $3.70 \pm 0.61$  (SD) mm was statistically significant ( $p=0.0001$ ).

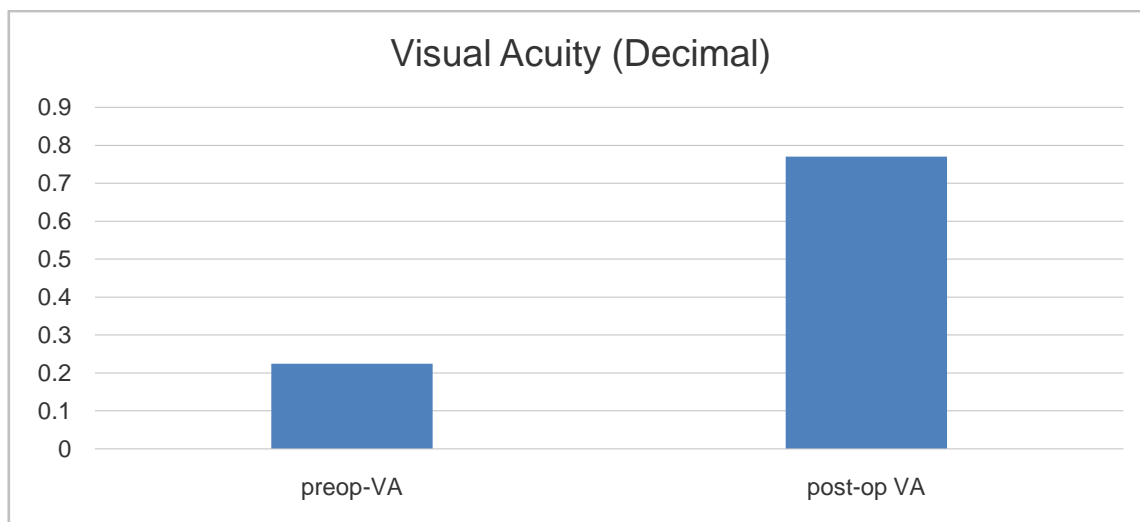
Preoperative mean ACA value was  $31.71 \pm 5.73$ . The increase in ACA values at the 1st week  $38.99 \pm 6.71$  (SD), 4th week  $38.97 \pm 6.50$ (SD) and 6th week  $39.02 \pm 6.51$  (SD) was statistically significant ( $P=0.0001$ ).

Preoperative mean CCT value was  $522.12 \pm 32.17$  (SD) $\mu$ m. The increase in CCT values at 1st week  $551.72 \pm 30.89$  (SD) $\mu$ m was statistically significant ( $p=0.0001$ ) but those of 4<sup>th</sup> week  $530.95 \pm 30.37$  (SD) $\mu$ m and 6<sup>th</sup> week  $523.21 \pm 31.05$  (SD) $\mu$ m were not significant ( $P=0.056$ ;  $P=0.814$  respectively).

Preoperative mean Astigmatism value was  $1.14 \pm 0.82$  (SD) Diopter. **The changes of Astigmatism values** at the 1st week  $2.13 \pm 1.20$  (SD) Diopter and 4th week  $1.49 \pm 0.68$  (SD) Diopter were statistically significant ( $P=0.0001$ ;  $P=0.0017$ ) and 6th week  $1.33 \pm 0.56$  (SD) Diopter was not statistically significant ( $P=0.069$ ). Also changes from 4<sup>th</sup> to 6<sup>th</sup> week was statistically **nonsignificant** ( $P=0.077$ ).







#### IV. Discussion

A few recent clinical studies, based on the use of the PentacamScheimpflug rotating camera, demonstrated that cataract surgery induces a significant deepening of the anterior chamber, opening of the iridocorneal angle and a reduction of IOP. This is apparent in both glaucomatous and non-glaucomatous eyes. **However**, Despite all the studies done so far, the exact IOP reduction mechanism induced by cataract surgery still remains unknown.

In 2000 Hayashi et al. [1] investigated the changes in ACA and ACD, using a Scheimpflug system. The explanation for these alterations is the postoperative backward shift of the iris, caused by the lens extraction with PC IOL implantation, a phenomenon that is greater in eyes with a shallow anterior chamber[3-7]. Posterior shift of the ciliary processes may **also** increase the aqueous humor outflow and cause the IOP to lower.

Dooley et al. [5] and Issa et al. [8] in non-glaucomatous subjects described a novel ratio based on preoperative ACD and IOP as a strong predictor of postoperative IOP reduction. Decrease in IOP is a result of aqueous outflow improvement by decompression or mechanical stretch of the trabecular meshwork and Schelmm's canal [1], resulted from an increased postoperative ACD.

Our results are in agreement with Uçakhan [3], Nonaka et al.[6] Doganay [4] and Dooley et al. [5] respectively, and show that cataract surgery significantly increased the anterior chamber parameters and induce IOP reduction in non-glaucomatous eyes. Our outcomes showed a significant IOP reduction in all patients, both at the 4<sup>th</sup> week (by 3.13 mmHg) and at the 6<sup>th</sup> week (by 3.04 mmHg) after SICS. Also, as with Doganay [4] and Dooley [5], we proved that our subjects had no significant postoperative pachymetric changes compared to the period prior to cataract surgery after 4 weeks of SICS.

However, the present study has certain limitations regarding the accuracy of the Scheimpflug rotating camera visualization of the anterior chamber angle .The light from the Scheimpflug system cannot pass the corneoscleral limbus. Therefore, it cannot visualize and exactly measure the real configuration and structures of the iridocorneal angle [9]. Another disadvantage of our research was that it was short-term, with only upto 6<sup>th</sup> week follow-up of measurements, after cataract surgery.

Caglar C et al [10] and De Juan V et al [11] explain corneal swelling becomes stable 2 weeks after cataract surgery, automated refraction becomes stable after 1 week and can be used to accurately prescribe corrective lenses at that time. Our results demonstrate that uneventful cataract surgery has a positive influence on ACD deepening, ACA widening and IOP reduction. And best time to prescribe corrective lenses is at 4<sup>th</sup> to 6<sup>th</sup> week after small incision cataract surgery (SICS).

#### References

- [1]. Hayashi K, Hayashi H, Nakao F, Hayashi F. Changes in anterior chamber angle width and depth after intraocular lens implantation in eyes with glaucoma. *Ophthalmology* 2000;107:698-703.
- [2]. Shrivastava A, Singh K. The effect of cataract extraction on intraocular pressure. *Curr Opin Ophthalmol* 2010;21:118-22.
- [3]. Uçakhan OO, Ozkan M, Kanpolat A. Anterior chamber parameters measured by the pentacam CES after uneventful phacoemulsification in normotensive eyes. *Acta Ophthalmol* 2009;87:544-8.
- [4]. Doganay S, Bozgul FP, Emre S, Yologlu S (2010) Evaluation of anterior segment parameter changes using the Pentacam after uneventful phacoemulsification. *Acta Ophthalmol* 88: 601-606.
- [5]. Dooley I, Charalampidou S, Malik A, Loughman J, Molloy L, et al. (2010) Changes in intraocular pressure and anterior segment morphometry after uneventful phacoemulsification cataract surgery. *Eye* 24: 519-527.
- [6]. Nonaka A, Kondo T, Kikuchi M, Yamashiro K, Fujihara M, Iwawaki T, et al. Angle widening and alteration of ciliary process configuration after cataract surgery for primary angle closure. *Ophthalmology* 2006;113:437-41.

- [7]. Chang TC, Budenz DL, Liu A, Kim WI, Dang T, Li C, *et al.* Long-term effect of phacoemulsification on intraocular pressure using phakic fellow eye as control. *J Cataract Refract Surg* 2012;38:866-70.
- [8]. Issa SA, Pacheco J, Mahmood U, Nolan J, Beatty S (2005) A novel index for predicting intraocular pressure reduction following cataract surgery. *Br J Ophthalmol* 89: 543-546.
- [9]. Meyer MA, Savitt ML, Kopitas E (1997) The effect of phacoemulsification on aqueous outflow facility. *Ophthalmology* 104: 1221-1227.
- [10]. Caglar CL, Batur M2, Eser E3, Demir H2, Yasar T. The stabilization time of ocular measurements after cataract surgery. *Semin Ophthalmol.* 2017; 32(4): 412-17.
- [11]. De Juan V, Herreras JM, Perez I. Refractive stabilization and corneal swelling after cataract surgery. *Optom Vis Sci.* 2013 Jan; 90(1): 31-6.

Dr. Rajesh Kumar Saini. "Study of Effects on Anterior Segment Morphometry by Pentacam Evaluation after Small Incision Cataract Surgery." *IOSR Journal of Dental and Medical Sciences (IOSR-JDMS)*, vol. 18, no. 10, 2019, pp 01-05.