

Optical Coherence Tomography: A New and Non-Invasive Diagnostic Tool for Chorio-Retinal Disorders.

Dr. (Prof.) Sanjeev K Nainiwal MD, DNB, MNAMS, FIMSA, Dr. Rajesh Kumar Saini MS, Dr. Pooja Jangid Resident, Dr. Akshay Sarraf DNB, Dr. Hemant Sharma Resident Dr. Vijaya Sharma Resident

Vitreo Retinal Services, Department of Ophthalmology, JLN Medical College & Hospital Ajmer (Rajasthan), INDIA

Corresponding Author: Dr. Rajesh Kumar Saini

Assistant Professor Department of Ophthalmology, J. L. N. Medical College & Hospital Ajmer (Rajasthan), India

Date of Submission: 19-09-2019

Date of Acceptance: 07-10-2019

Purpose

Optical coherence tomography (OCT) has revolutionized the clinical practice of ophthalmology. It is a non-invasive imaging technique that provides high resolution, cross-sectional images of the retina, the retinal nerve fiber layer (RNFL) and the optic nerve head. This serves to study the applications of the OCT systems in the diagnosis and management of chorio-retinal diseases.

I. Introduction

It is a non-invasive imaging technique that provides high resolution, cross-sectional images of the retina, the retinal nerve fiber layer (RNFL) and the optic nerve head. With axial resolution in the 5–7 μm range, it provides close to an in-vivo ‘optical biopsy’ of the retina.

PRINCIPLE -

OCT employs light from a broadband light source, which is divided into a reference and a sample beam, to obtain a reflectivity versus depth profile of the retina. The light waves that are backscattered from the retina, interfere with the reference beam, and this interference pattern is used to measure the light echoes versus the depth profile of the tissue *in vivo*^(1,2).

TYPES –

Time-domain detection was the technique employed by commercially available OCT systems such as the Stratus OCT (Carl Zeiss Meditec, Inc, Dublin, CA). Time-domain OCT (TD-OCT) systems featured scan rates of 400 A-scans per second with an axial resolution of 8–10 μm in tissue⁽²⁾.

In 2006, the first commercially available spectral-domain (Fourier domain) OCT (SD-OCT) system was introduced. SD-OCT employs detection of the light echoes simultaneously by measuring the interference spectrum, using an interferometer with a high-speed spectrometer. This technique achieves scan rates of 20 000–52 000 A-scans per second and a resolution of 5–7 μm in tissue^(3,4).

UHR-OCT uses broadband light sources to achieve 3 μm resolution in tissue⁽⁵⁾.

SS-OCT (Swept Source) uses another form of Fourier domain detection to measure light echoes. It employs a tunable frequency swept laser light source, This increases the signal quality in deep tissue by elimination of the sensitivity of a spectrometer to higher frequency modulation as with SD-OCT^(6,7-11), thereby improving the visualization of the choroid.

COLOUR CODING IN OCT SCAN –

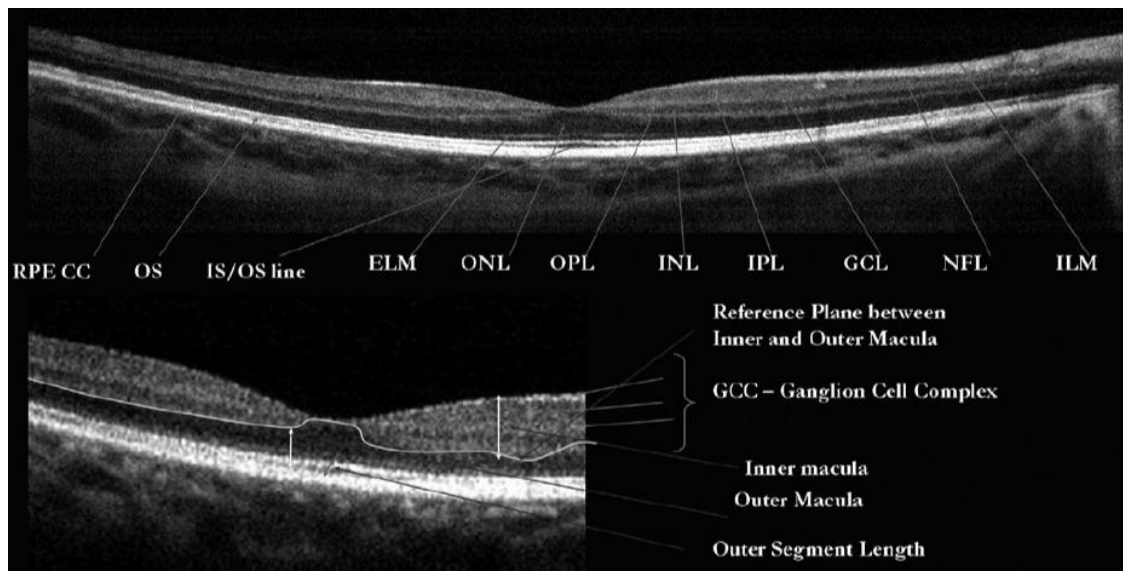
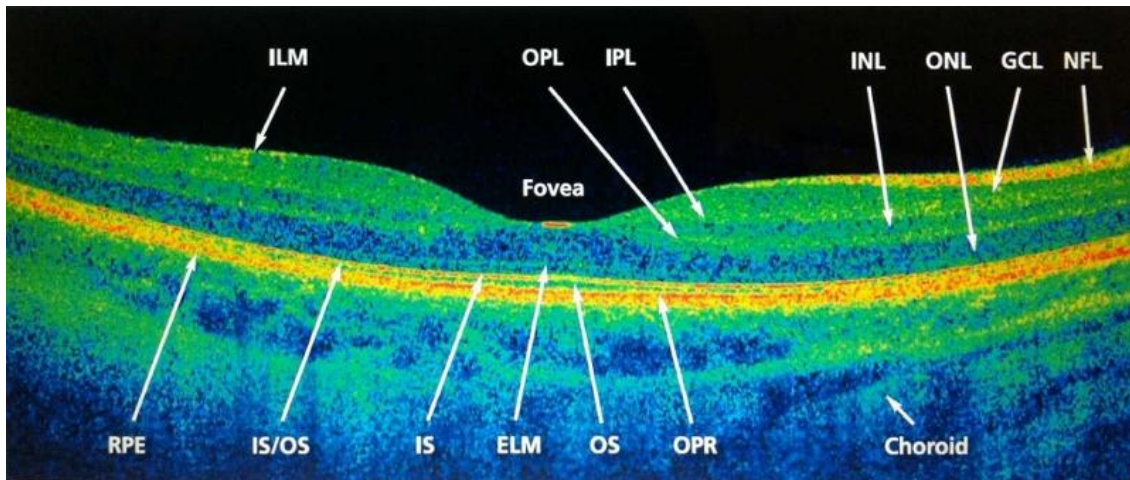
Highly reflective structures are shown in red. Those with low reflectivity are represented by dark colours like black while green represents intermediate reflectivity.

In colour coded macular thickness map, blue colour represents thinner retina while yellow-green represents thicker retina.

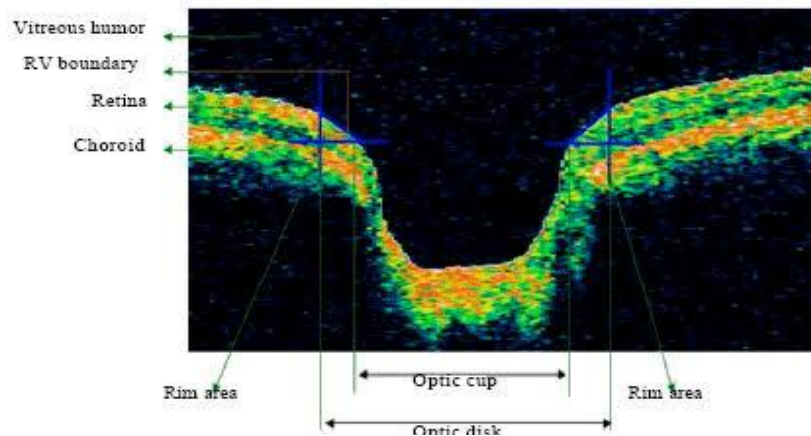
INTERPRETATION OF OCT SCAN -

Vitreous is non reflective and seen as dark space. Vitreoretinal interface is well defined due to contrast between non reflective vitreous and retinal backscattering. Fovea has depression and umbo is seen as central hyper reflective dot within foveola.

Retinal layers – RNFL, RPE- choriocapillaries complex is highly reflective and seen as red layer due to bright scattering. Outer segments of photoreceptors are minimally reflective represented by a darkline just anterior to RPE-choriocapillaries complex. Different intermediate layers of neurosensory retina between dark layer of photoreceptors and red layer of RNFL are seen as alternating layers of moderate and low reflectivity. Choroid, vitreous fluid and blood are minimally reflective and appears black.



In optic disc scan – disc boundaries are defined by termination of choriocapillaries at lamina cribrosa and optic cup is determined by the termination of nerve fibre layer.



While interpreting an OCT scan, always look for following 4 points -

- Appearance of vitreo-retinal interface -
 - normal,
 - any membrane (single/double),
 - attachment (no attachment/[partial/total attachment])
- Foveal contour -
 - normal,
 - obliterated by pulling (due to overlying membrane) or pushing (due to underlying fluid),
 - widened due to foveal thinning,
 - hole whether lamellar or full thickness.
- Any alteration of retinal architecture –
 - normal,
 - Fluid – intraretinal : diffuse, cystoid; subretinal’
 - Exudates,
 - Schisis.
- Any disruption in the RPE-choriocapillaries complex layer –
 - normal
 - bumpy – drusens
 - fusiform thickening – CNVM
 - elevated – definite green line – serous PED
 - indefinite green line – fibrovascular PED
 - no green line – hemorrhagic PED

Hyper-reflective lesions within NSR – Hard exudates, cotton wool spots, microaneurysms, hemorrhage, pigments, fibrin, ERM, drusens, nevi, RPE hyperplasia.

Hypo-reflective lesions are – asteroid hyalosis, vitreous hemorrhage, intraretinal fluid, PED.

APPLICATIONS OF OPTICAL COHERENCE TOMOGRAPHY -

OCT imaging is used extensively for imaging the macula, optic nerve and RNFL, and aids in analyzing the morphology and quantifying changes in various disease states.

For example, the automated retinal thickness measurements provided by the OCT systems are used clinically for the monitoring progression of diseases such as wet age-related macular degeneration (AMD) and macular edema from various causes including diabetes and retinal vein occlusion.

The ability to detect fluid within the retina and the thickness alterations induced by this fluid helps direct clinical decisions regarding treatment⁽¹²⁾. The diagnosis of macular hole and its differentiation between lamellar holes and pseudomacular holes have become straightforward using OCT⁽¹³⁾. In addition, the size and configuration of macular holes, determined by OCT, correlates well with the functional and anatomic outcomes following surgical intervention⁽¹³⁻¹⁶⁾.

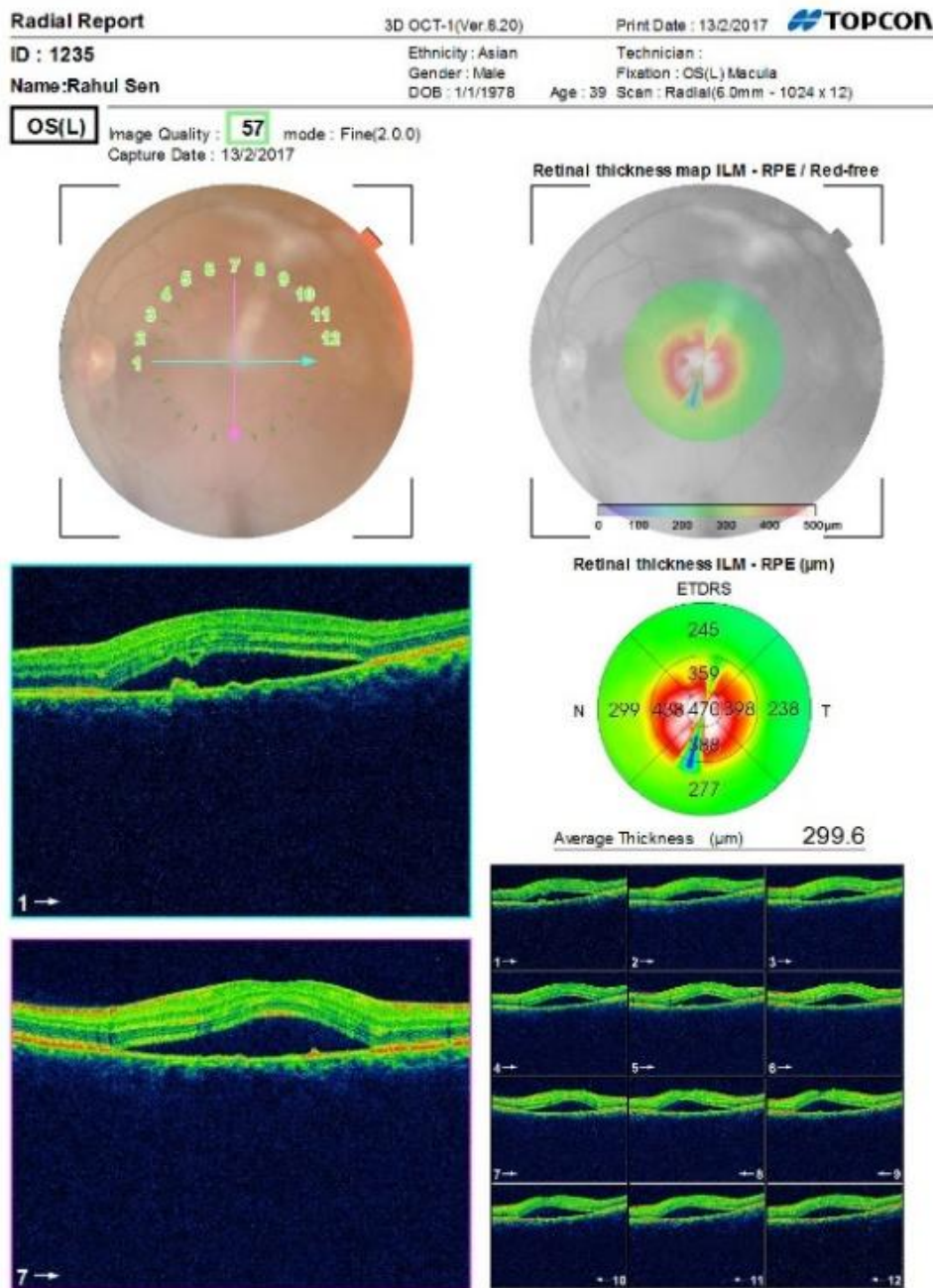
Evaluation of the vitreoretinal interface using OCT is important in the evaluation and treatment of diseases of the vitreomacular interface such as epiretinal membranes and vitreomacular traction⁽¹⁷⁾.

In addition, optic disc morphology and RNFL thickness measurements, using OCT, monitor the progression and helps quantitatively assess the treatment response in patients with glaucoma^(18,19).

Thus OCT is useful in diagnosing, monitoring the progression and response to treatment in -

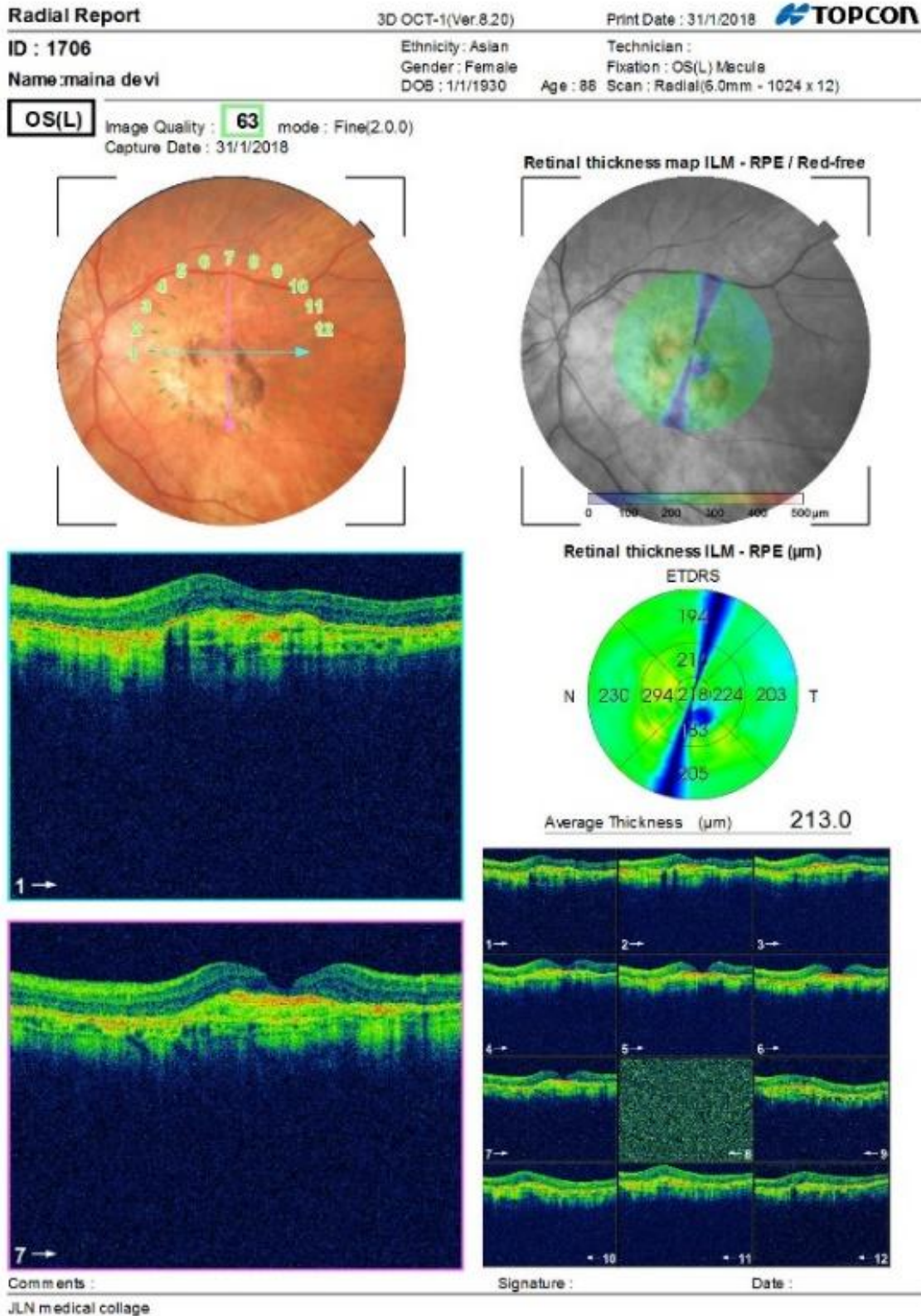
- ✓ Macular hole.
- ✓ Macular pucker.
- ✓ Macular edema.
- ✓ Age related macular degeneration.
- ✓ Glaucoma.
- ✓ Central serous retinopathy.
- ✓ Diabetic retinopathy.
- ✓ Vitreous traction.
- ✓ Epiretinal membranes.

CENTRAL SEROUS RETINOPATHY



CSR is characterized by area of decreased reflectivity (optically empty) between the two highly reflective layers – neurosensory retina and RPE/ choriocapillaries.

CNVM IN WET ARMD

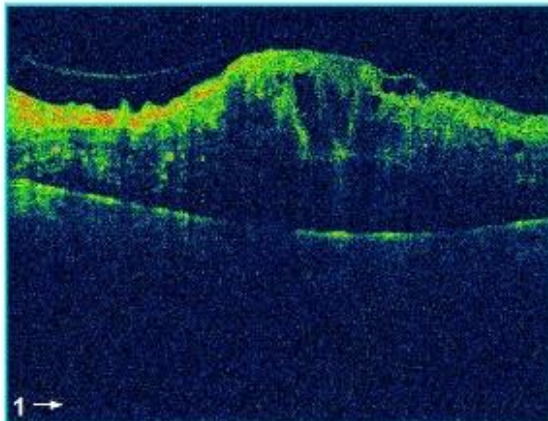
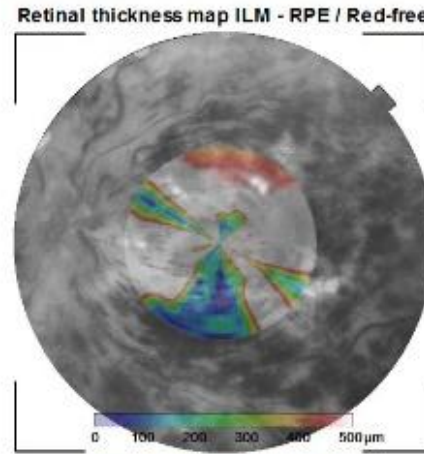
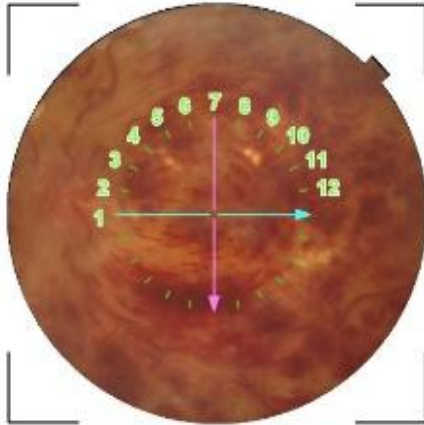


CNVM is characterized by hyper-reflective lesion fusiform in shape, increased intra-retinal thickening and sub-retinal fluid adjacent to the CNVM.

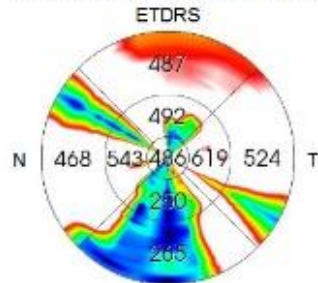
SPONGIFORM MACULAR EDEMA CRVO

Radial Report 3D OCT-1(Ver.8.20) Print Date : 26/2/2017 **TOPCON**
ID : 1262 Ethnicity : Asian Technician :
Name : Munni Devi Gender : Female Fixation : OS(L) Macula
 DOB : 1/1/1965 Age : 52 Scan : Radial(6.0mm - 1024 x 12)

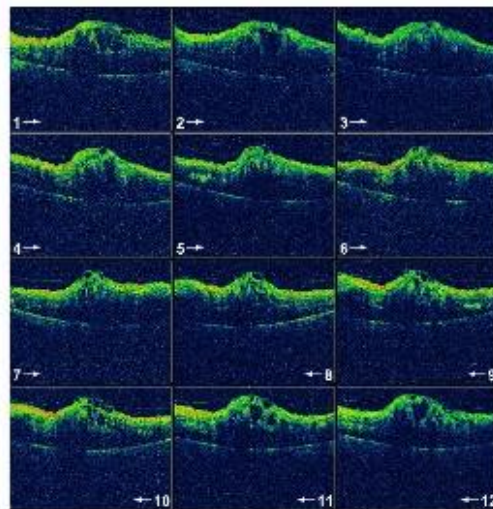
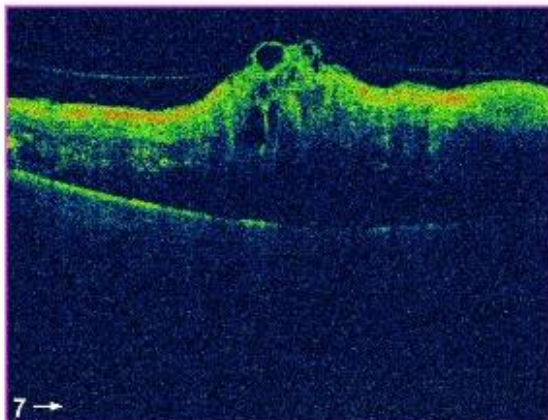
OS(L) Image Quality : **31** mode : Fine(2.0.0)
 Capture Date : 26/2/2017



Retinal thickness ILM - RPE (µm)



Average Thickness (µm) 446.5



Comments :

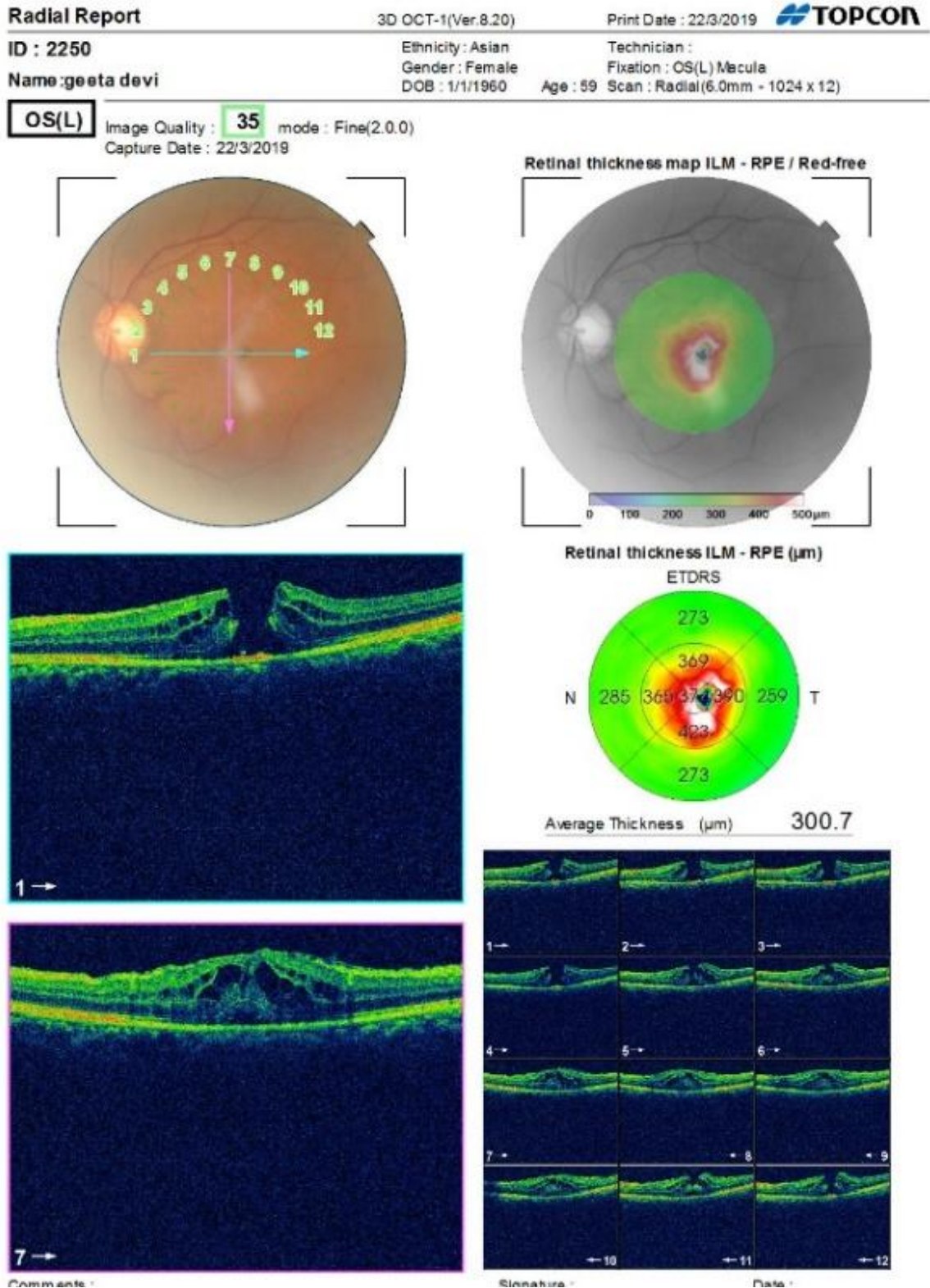
|| Medical college

Signature :

Date :

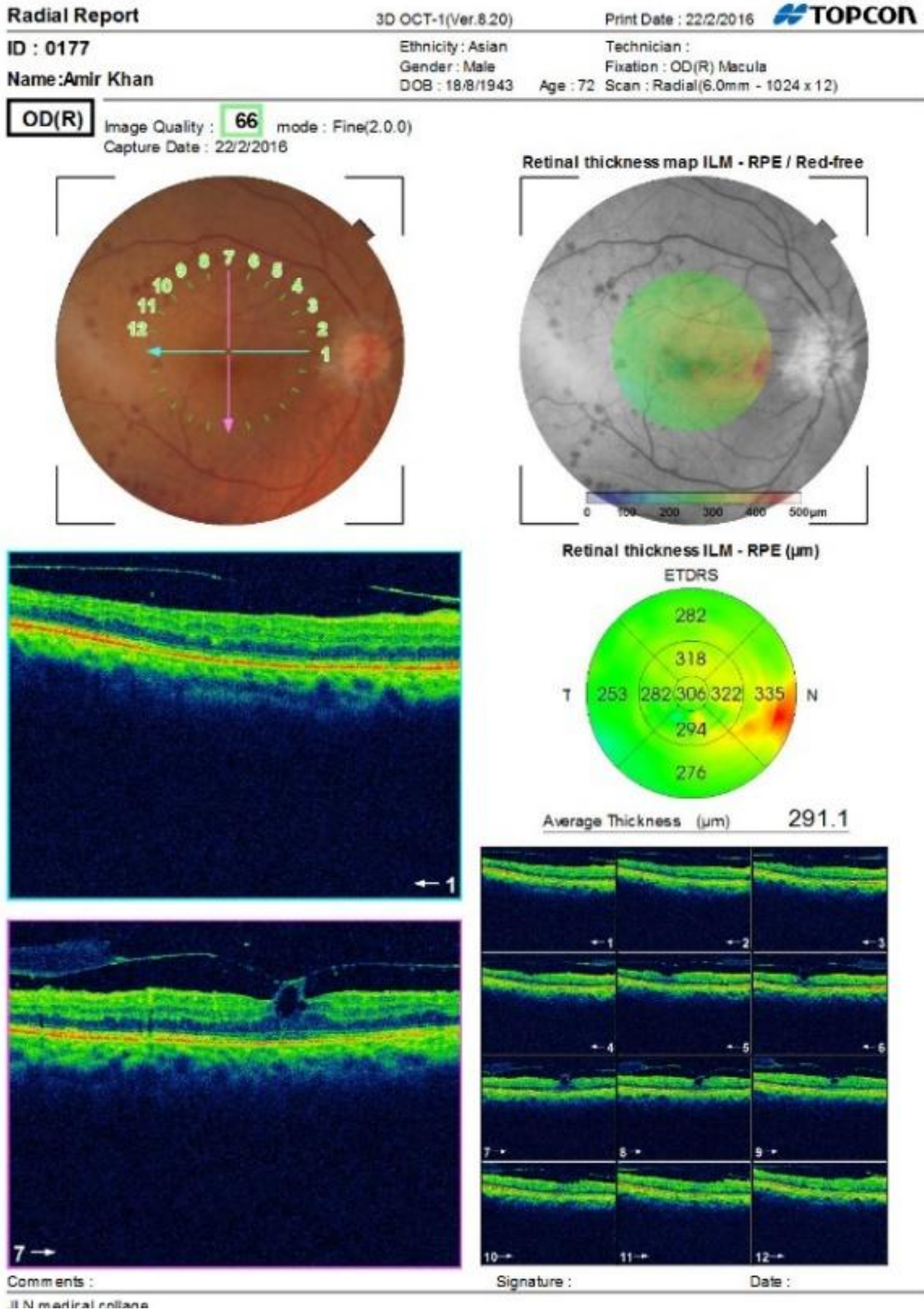
Typically seen as spongy macula with intraretinal areas of decreased reflectivity and round optically clear areas within the neurosensory retina with CRVO diagnosed on fundus examination. Quantative assessment allows monitoring the course.

MACULAR HOLE



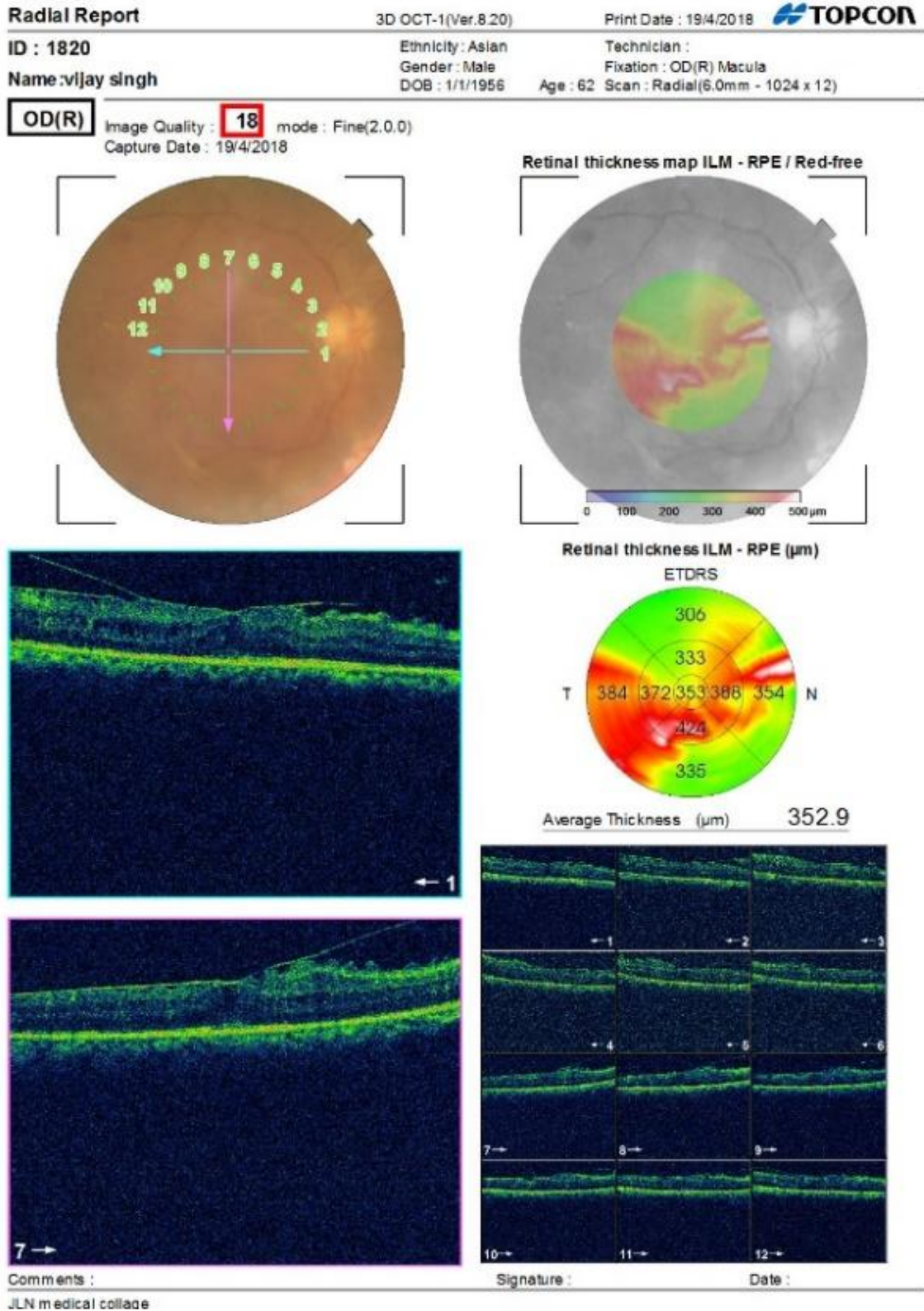
OCT allows confirmation of macular hole & differentiates it from clinically simulating conditions such as lamellar hole & pseudocyst. It is also useful in monitoring the course of the disease and response to surgical intervention.

VITREO-MACULAR TRACTION



OCT showing vitreomacular traction syndrome with foveal cystoid changes involving the inner retina and preservation of outer retinal morphology. It also helps in grading of VMTS.

EPIRETINAL MEMBRANE



ERM is diagnosed on OCT by the presence of a highly reflective diaphanous membrane over the surface of retina. OCT provides information about membrane thickness, cystic changes and its adherence to retinal surface.

DIABETIC MACULAR EDEMA

Radial Report

3D OCT-1(Ver.8.20)

Print Date : 7/8/2018



ID : 1915

Ethnicity : Asian

Technician :

Name : raju ji

Gender : Male

Fixation : OS(L) Macula

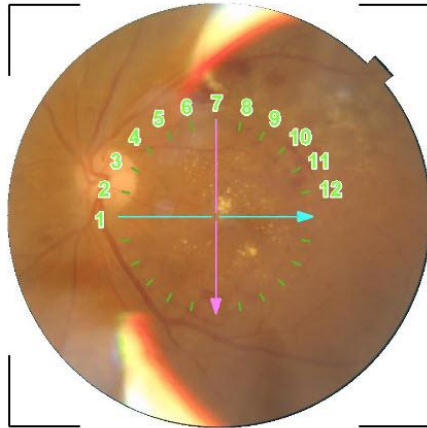
DOB : 1/1/1978

Age : 40 Scan : Radial(6.0mm - 1024 x 12)

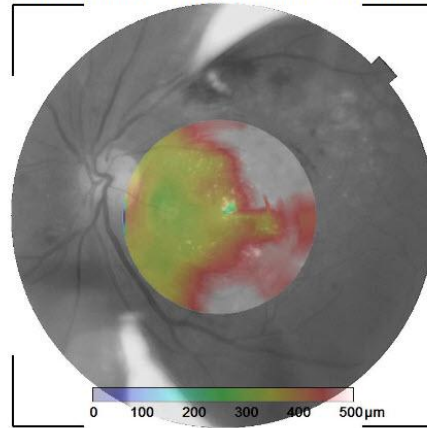
OS(L)

Image Quality : 19 mode : Fine(2.0.0)

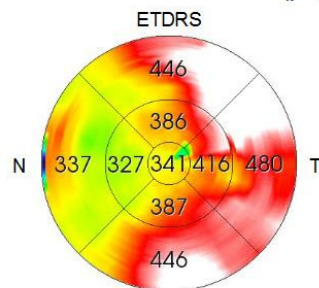
Capture Date : 7/8/2018



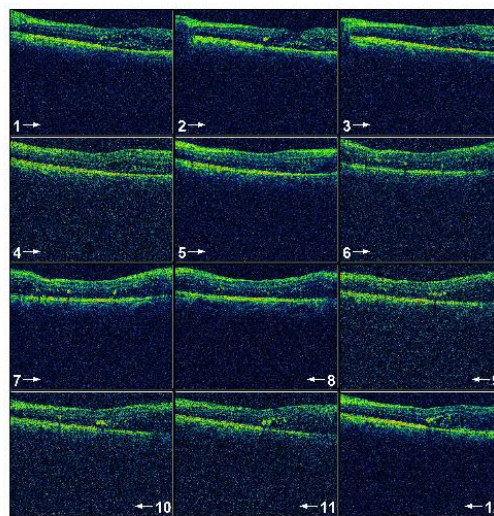
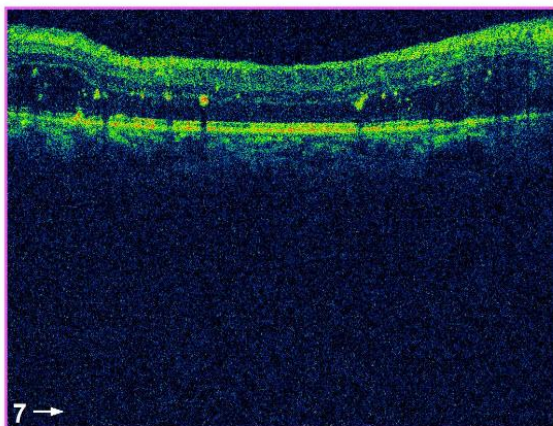
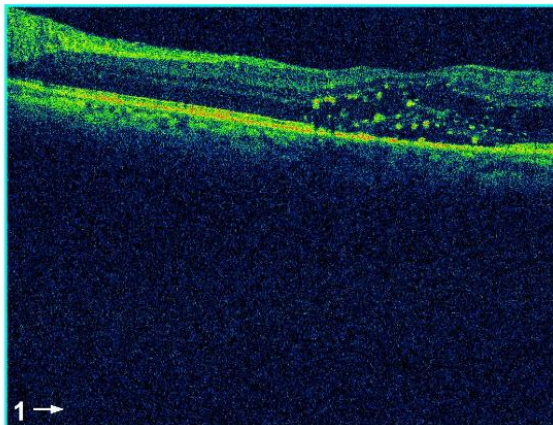
Retinal thickness map ILM - RPE / Red-free



Retinal thickness ILM - RPE (µm)



Average Thickness (µm) 414.0



Comments :

JLN medical collage

Signature :

Date :

Characterized by presence of subretinal fluid and intraretinal fluid along with cystic spaces supported by typical diabetic fundus picture.

MULTIPLE PEDs

Radial Report

3D OCT-1(Ver.8.20)

Print Date : 24/5/2016



ID : 0728

Ethnicity : Asian

Technician :

Name: Hari Kishan

Gender : Male

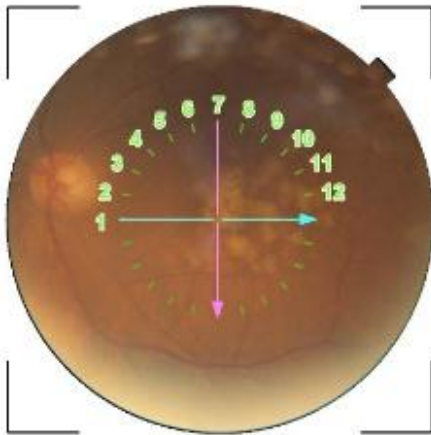
Fixation : OS(L) Macula

DOB : 23/3/1940


Age : 76 Scan : Radial(6.0mm - 1024 x 12)

OS(L)

Image Quality : **48** mode : Fine(2.0.0)
Capture Date : 24/5/2016

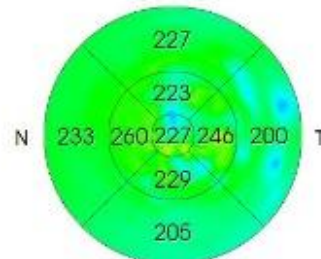

Retinal thickness map ILM - RPE / Red-free

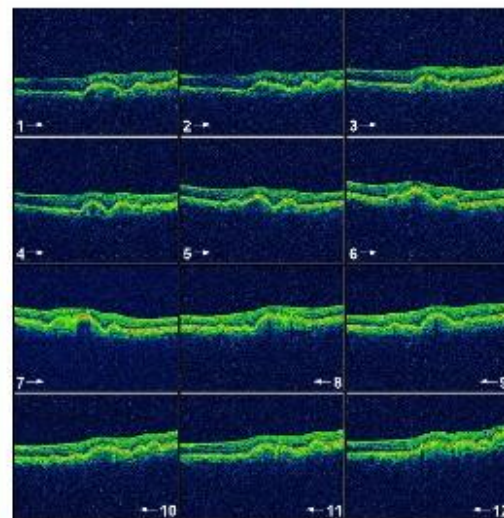
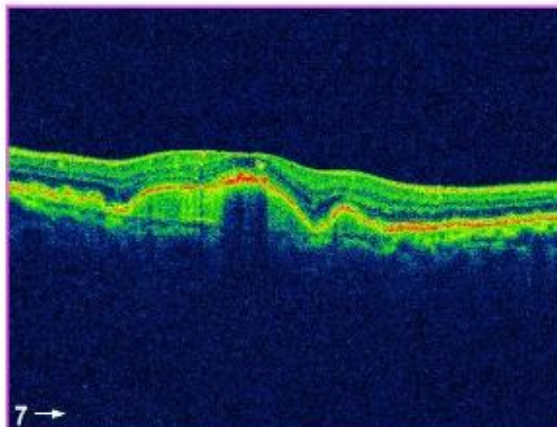
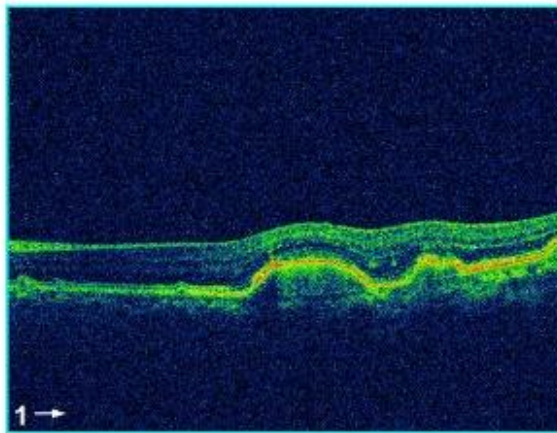


Retinal thickness ILM - RPE (µm)

ETDRS

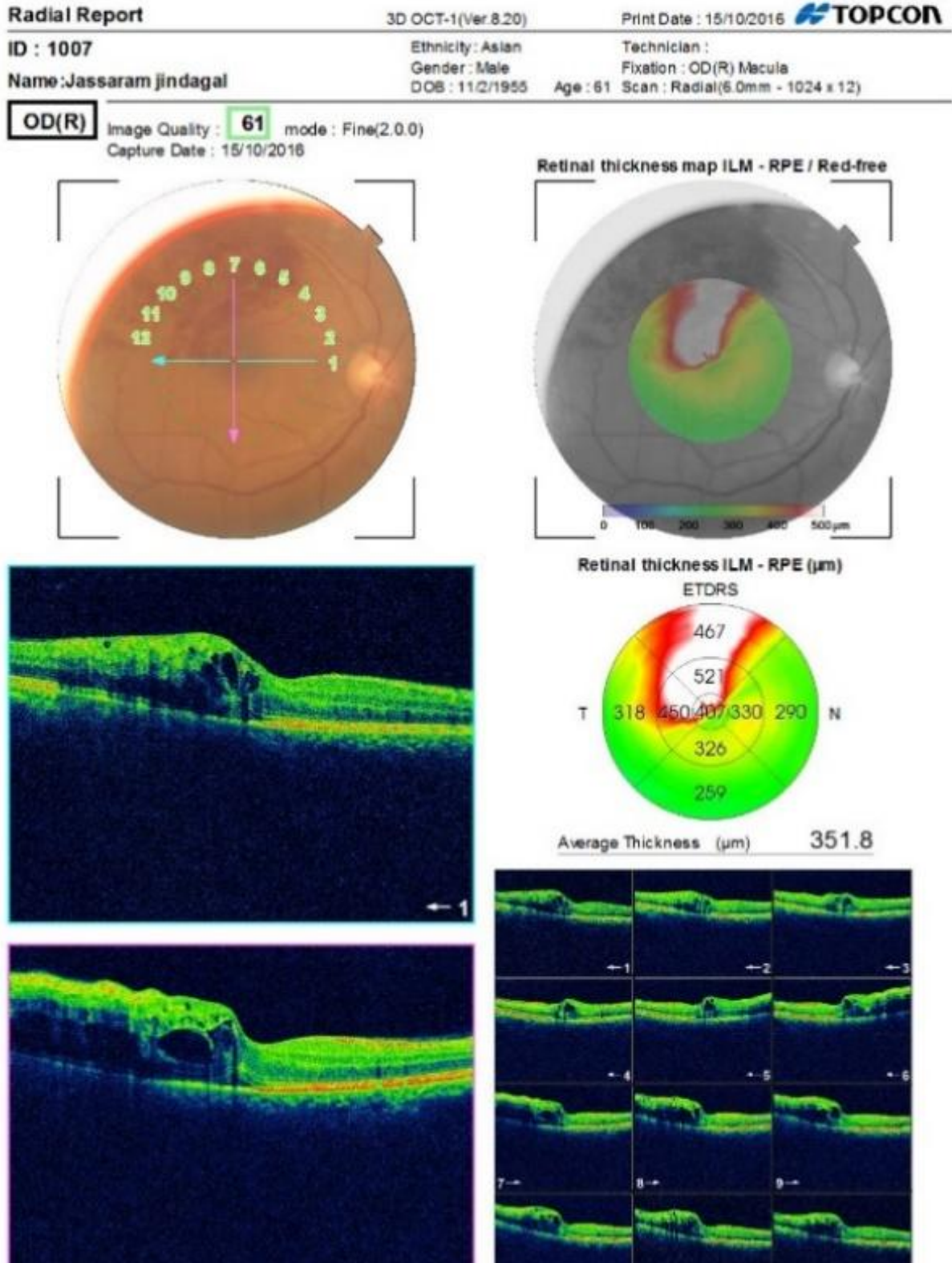


Average Thickness (µm) **221.7**



Drusens seen between the bruch's membrane and the RPE characterized by hyper-reflective bumpy RPE with PEDs.

CME IN BRVO



Characteristic findings of BRVO on OCT are cystoid macular edema, intraretinal hyperreflectivity from hemorrhages, shadowing from edema and hemorrhages, and occasionally subretinal fluid. The edema is typically localized to the involved site.

PED

Radial Report

3D OCT-1(Ver.8.20)

Print Date : 4/6/2019



ID : 2359

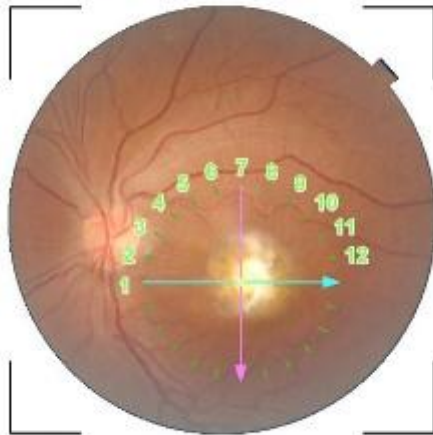
Ethnicity : Asian
Gender : Female
DOB : 1/1/1983

Technician :
Fixation : OS(L) Macula
Age : 36 Scan : Radial(6.0mm - 1024 x 12)

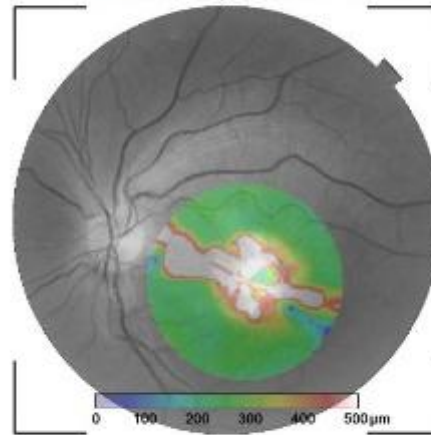
Name : reena devi

OS(L)

Image Quality : **24** mode : Fine(2.0.0)
Capture Date : 4/6/2019

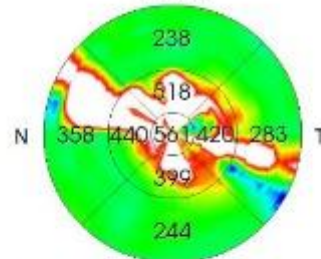


Retinal thickness map ILM - RPE / Red-free

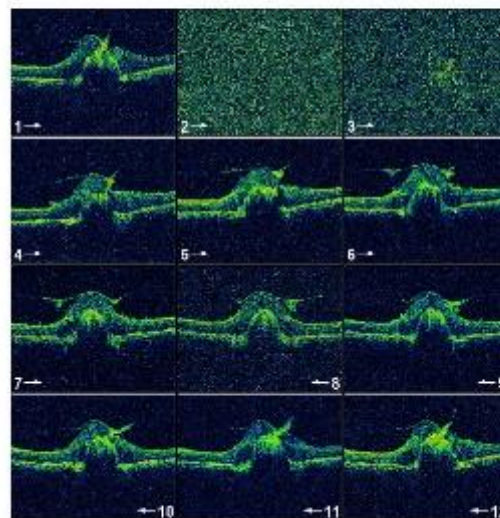
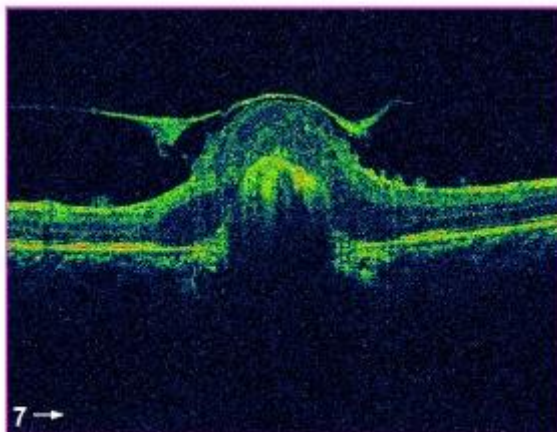
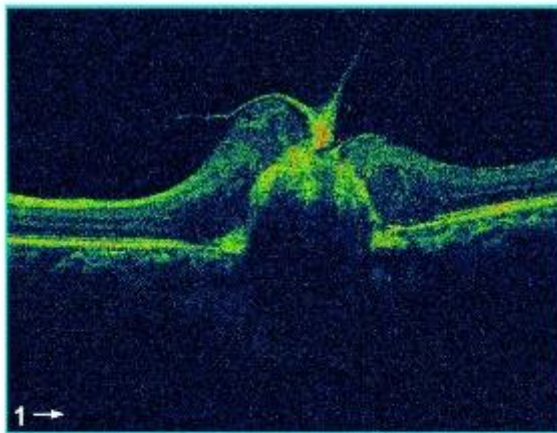


Retinal thickness ILM - RPE (μm)

ETDRS



Average Thickness (μm) **325.1**



Comments :

Signature :

Date :

GLAUCOMA

3D Disc Report w/ Topography

3D OCT-1(Ver.8.20)

Print Date : 11/10/2018 

ID : 2042

Ethnicity : Asian

Technician :

Name:prem devi

Gender: Female

Fixation : OD(R) Disc

DOB : 1/1/1965

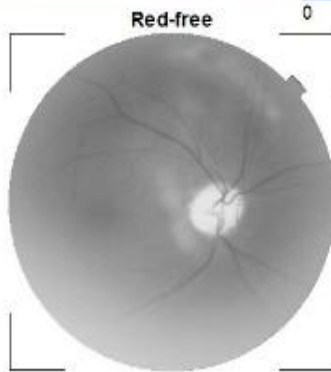
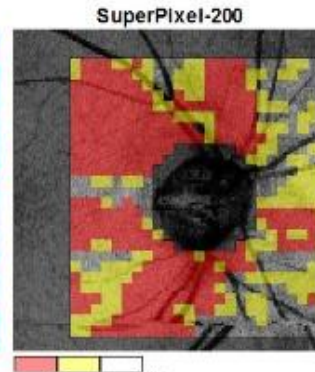

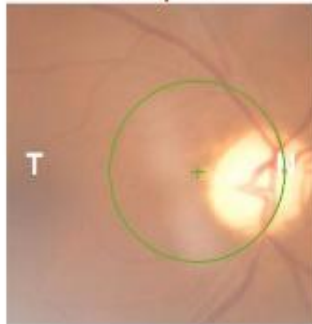
Age : 53 Scan : 3D(6.0 x 6.0mm - 512 x 128)

OD(R)

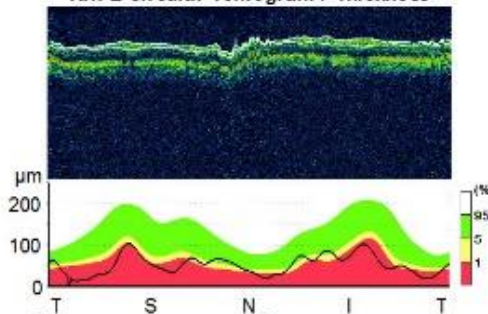
Image Quality : **26** mode : Fine(2.0.0)

Capture Date : 11/10/2018

Color photo

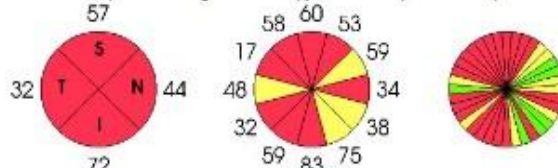


RNFL Circular Tomogram / Thickness



Average thickness RNFL(μm)

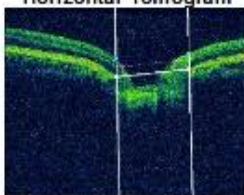
Total Thickness	51
Superior	57
Inferior	72



Disc Topography




Horizontal Tomogram



Disc Area	(mm ²)	2.68
Cup Area	(mm ²)	1.64
Rim Area	(mm ²)	1.04
C/D Area Ratio		0.61
Linear CDR		0.78
Vertical CDR		0.82
Cup Volume	(mm ³)	0.20
Rim Volume	(mm ³)	0.11
Horizontal D.D	(mm)	1.84
Vertical D.D	(mm)	1.89

R/D Ratio



Disc margin — cyan
Cup margin — purple

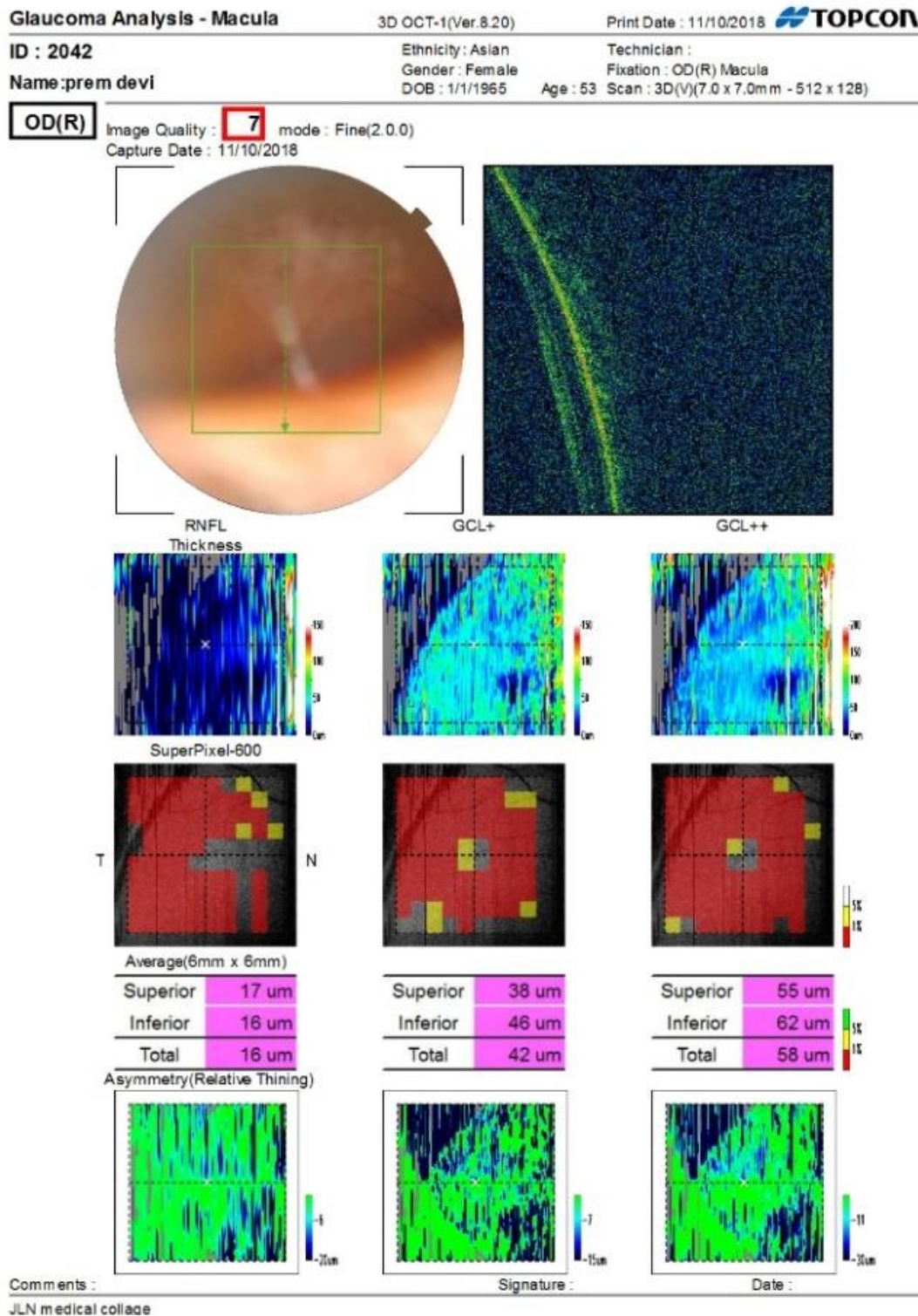
Disc parameters are determined at the reference plane height of 120 microns from the RPE plane in this version.

Comments :

JLN medical collage

Signature :

Date :



Optic disc scan is very useful in diagnosing and monitoring glaucomatous changes. It is also useful in evaluating the RNFL for early (pre-perimetric) glaucoma detection. It provides accurate assessment of size of optic cup, disc area, C:D ratio, volume of the cup.

Other uses Include –

Detection, study and follow up of macular changes in hypotony induced maculopathy after glaucoma and Evaluation of cystoid macular edema after combined cataract and glaucoma surgery.**PDR WITH TRD**

3D Macula Report

3D OCT-1(Ver.8.20)

Print Date : 21/11/2016 **TOPCON**

ID : 1083

Ethnicity : Asian

Technician :

Name : KAMLA DEVI

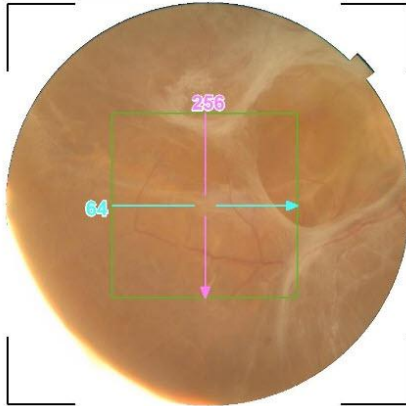
Gender : Female

Fixation : OD(R) Macula

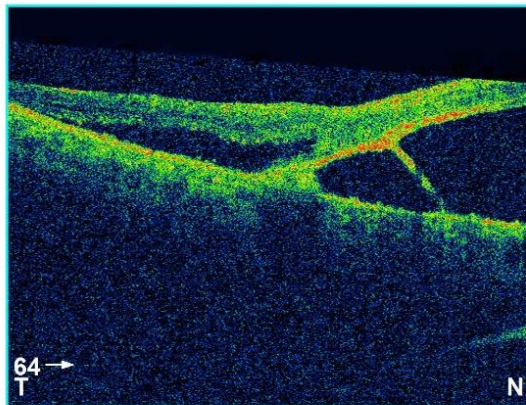
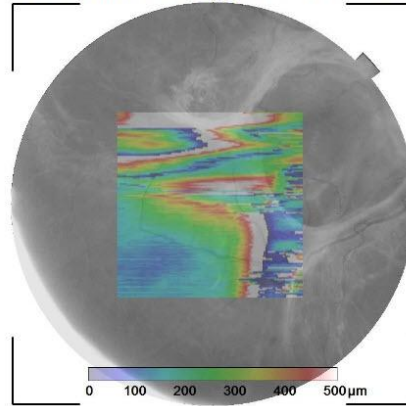
DOB : 1/1/1936

Age : 80 Scan : 3D(6.0 x 6.0mm - 512 x 128)

OD(R) Image Quality : **23** mode : Fine(2.0.0)
Capture Date : 21/11/2016



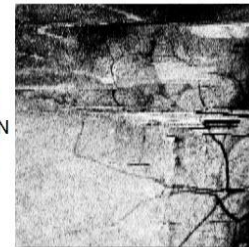
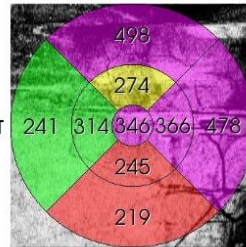
Retinal thickness map ILM - RPE / Red-free



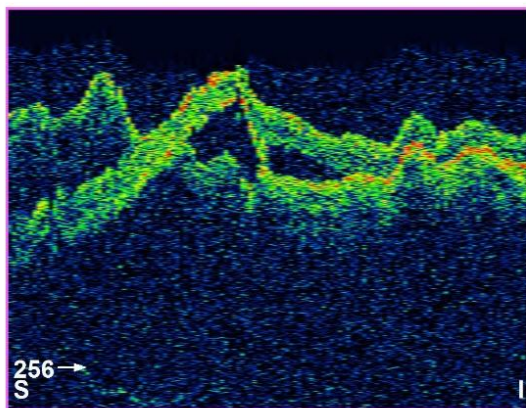
Retinal thickness ILM - RPE(μm)

ETDRS

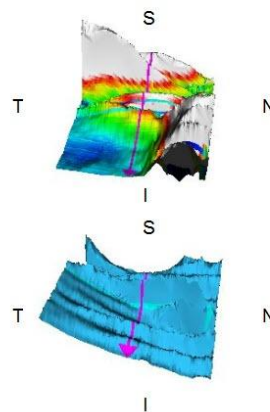
Shadowgram



	1	5	95	99	(%)
Average Thickness (μm)	345.6				
Center Thickness (μm)	361				
Total Volume (mm ³)	9.77				



ILM - RPE Map



RPE Surface

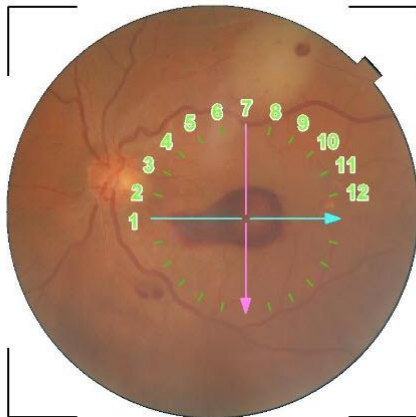
Comments :
JLN medical collage

Signature : _____ Date : _____

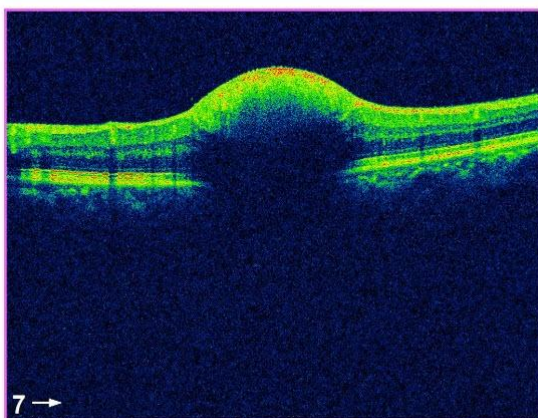
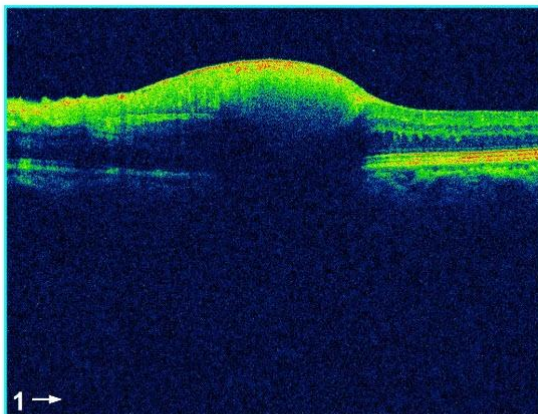
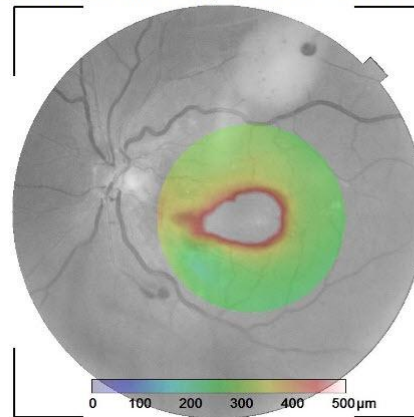
SUBMACULAR HEMORRHAGE

Radial Report 3D OCT-1(Ver.8.20) Print Date : 19/4/2018 **TOPCON**
ID : 1813 Ethnicity : Asian Technician :
 Gender : Male Fixation : OS(L) Macula
Name : Dharmaram singh DOB : 1/1/1958 Age : 60 Scan : Radial(6.0mm - 1024 x 12)

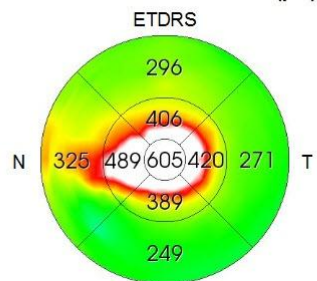
OS(L) Image Quality : **45** mode : Fine(2.0.0)
 Capture Date : 19/4/2018



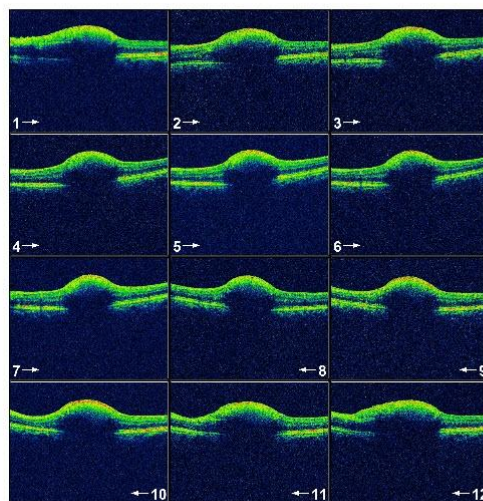
Retinal thickness map ILM - RPE / Red-free



Retinal thickness ILM - RPE (μm)



Average Thickness (μm) **325.3**



Comments :
 JLN medical collage

Signature : Date :

OCT reveals location of the submacular hemorrhage predominantly in the subretinal pigment epithelial space and there can be large hemorrhage with shadowing, obscuring the underlying RPE.

RETINAL SCARRING

Radial Report

3D OCT-1(Ver.8.20)

Print Date : 18/5/2019 **TOPCON**

ID : 2333

Ethnicity : Asian

Technician :

Name : Mrs. Chandrakanta

Gender : Female

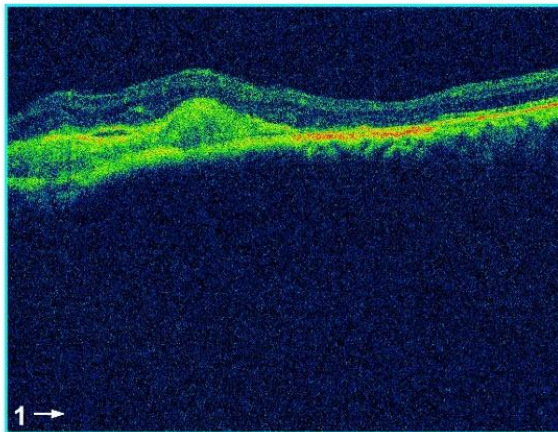
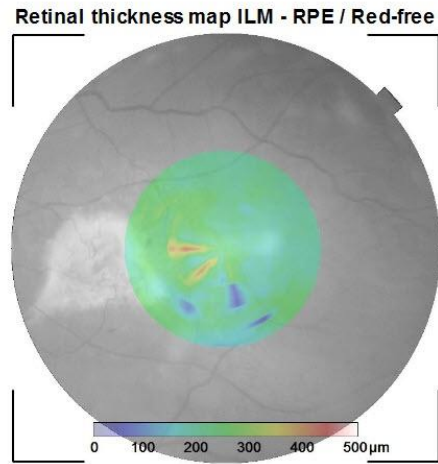
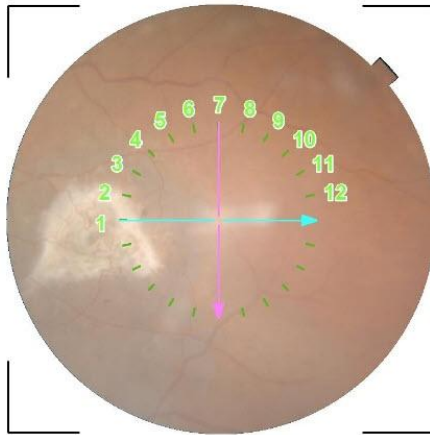
Fixation : OS(L) Macula

DOB : 1/1/1940

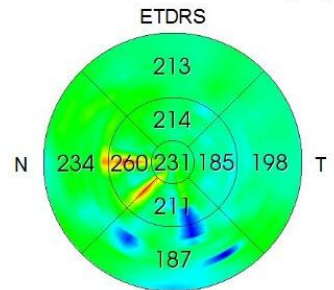
Age : 79

Scan : Radial(6.0mm - 1024 x 12)

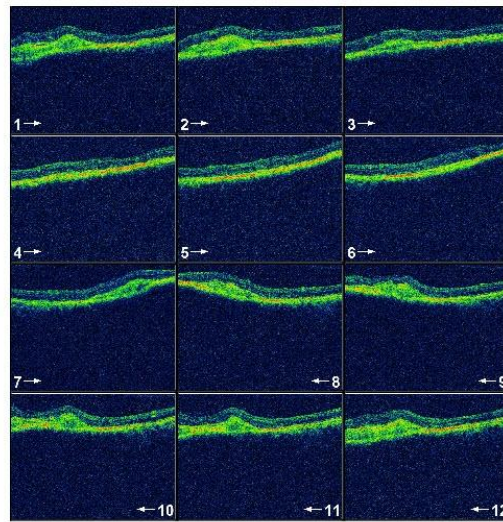
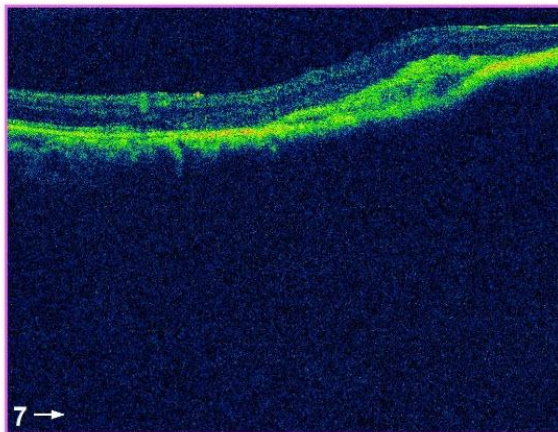
OS(L) Image Quality : **32** mode : Fine(2.0.0)
Capture Date : 18/5/2019



Retinal thickness ILM - RPE (μm)



Average Thickness (μm) **210.7**



Comments :

JLN medical collage

Signature :

Date :

MACULAR EDEMA IN EALE'S DISEASE

Radial Report

3D OCT-1(Ver.8.20)

Print Date : 10/9/2016 **TOPCON**

ID : 0952

Ethnicity : Asian

Technician :

Name:dharm raj gurjar

Gender : Male

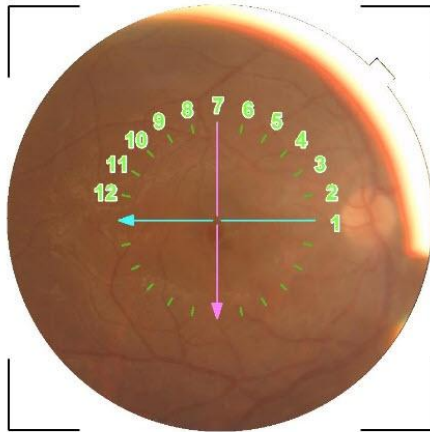
Fixation : OD(R) Macula

DOB : 4/7/1991

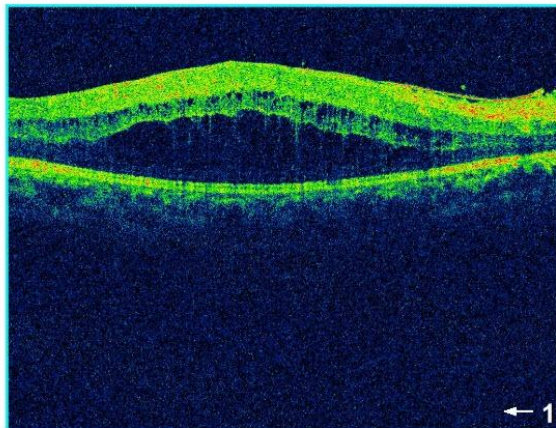
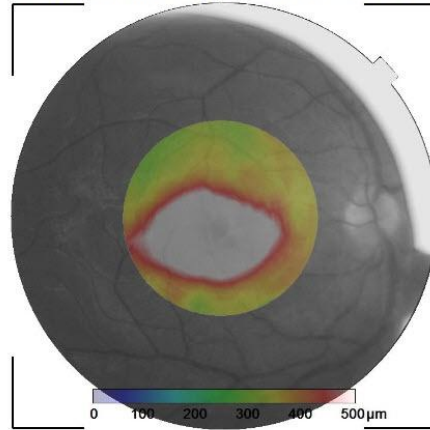
Age : 25 Scan : Radial(6.0mm - 1024 x 12)

OD(R)

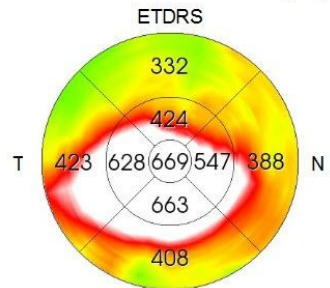
Image Quality : **39** mode : Fine(2.0.0)
Capture Date : 10/9/2016



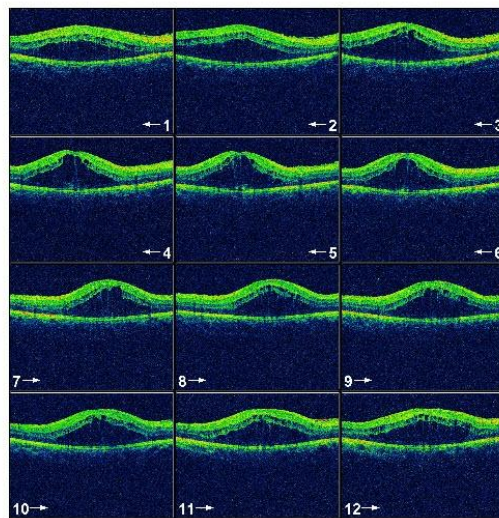
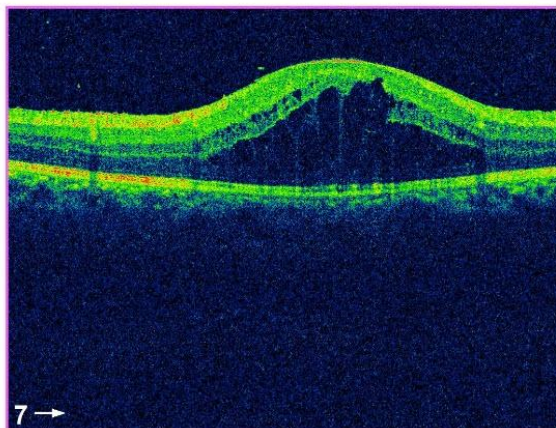
Retinal thickness map ILM - RPE / Red-free



Retinal thickness ILM - RPE (µm)



Average Thickness (µm) 435.1



Comments :

JLN medical collage

Signature :

Date :

Multiple cystoid spaces with intraretinal fluid in CME of a patient with Eale's disease as evidenced by fundus picture.

CNVM WITH CME AND PED

Radial Report

3D OCT-1(Ver.8.20)

Print Date : 27/9/2016 **TOPCON**

ID : 978

Ethnicity : Asian

Technician :

Name :manorma jain

Gender : Female

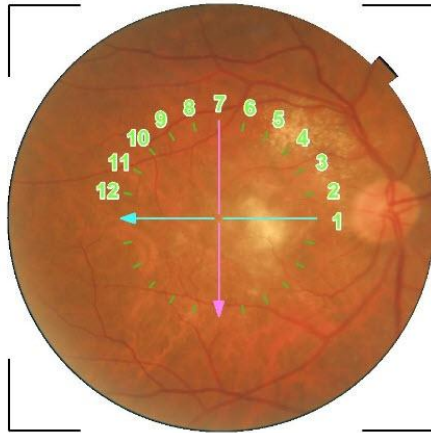
Fixation : OD(R) Macula

DOB : 26/3/1953

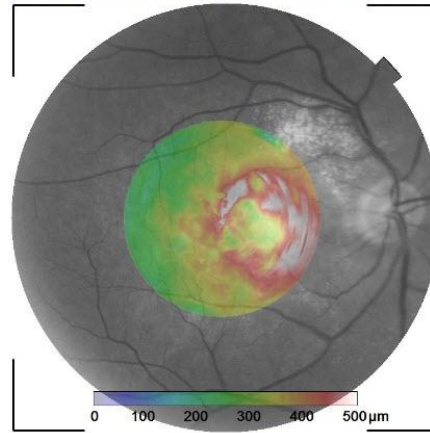
Age : 63

Scan : Radial(6.0mm - 1024 x 12)

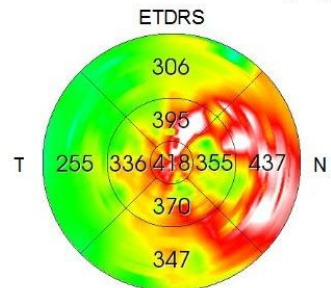
OD(R) Image Quality : **57** mode : Fine(2.0.0)
Capture Date : 27/9/2016



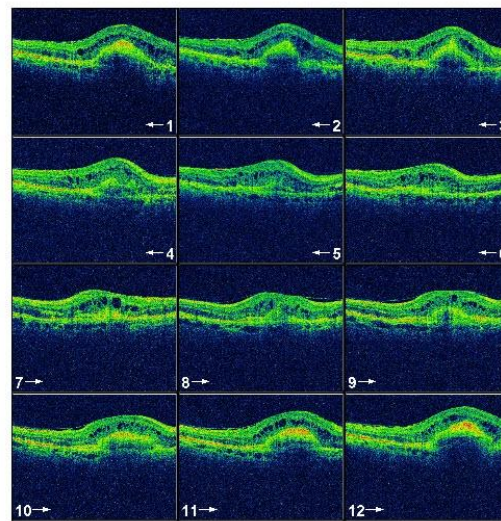
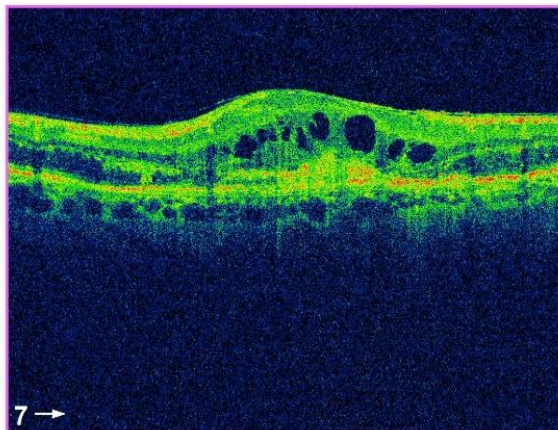
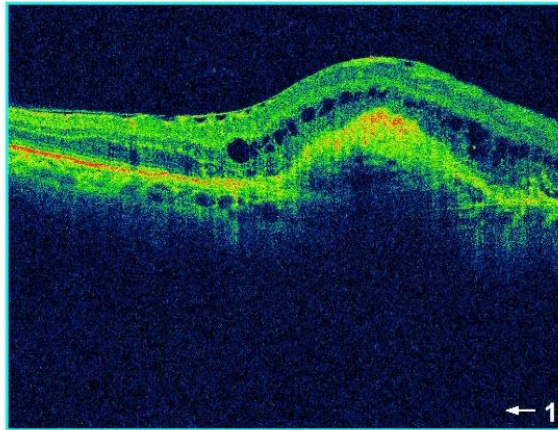
Retinal thickness map ILM - RPE / Red-free



Retinal thickness ILM - RPE (µm)



Average Thickness (µm) 344.7



Comments :

JLN medical collage

Signature :

Date :

Hyper-reflective fusiform thickening of the RPE-CC layer in CNVM along with multiple cystic optically black areas of CME with indefinite elevated green line of RPE-CC layer typical of fibrovascular PED.

SUBHYALOID HEMORRHAGE

Radial Report

3D OCT-1(Ver.8.20)

Print Date : 19/8/2016



ID : 918

Ethnicity : Asian

Technician :

Name:Abdul Rehmat

Gender : Male

Fixation : OS(L) Macula

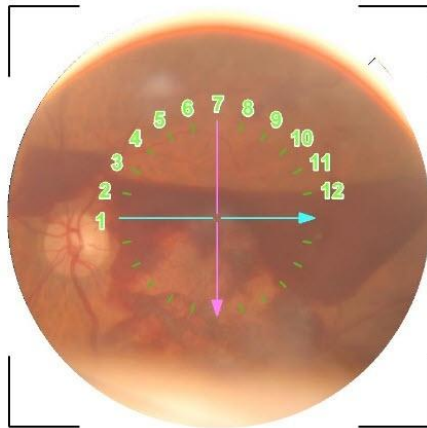
DOB : 1/4/1947

Age : 69 Scan : Radial(6.0mm - 1024 x 12)

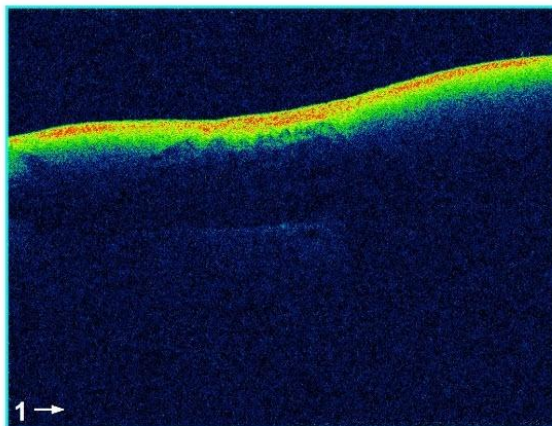
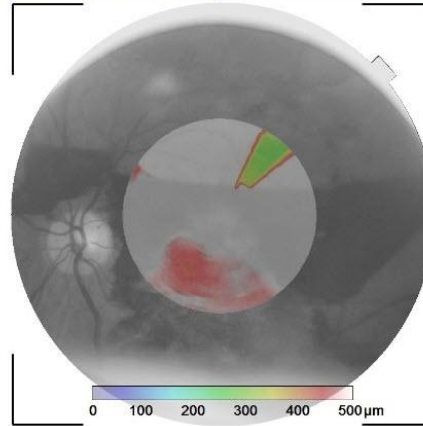
OS(L)

Image Quality : **27** mode : Fine(2.0.0)

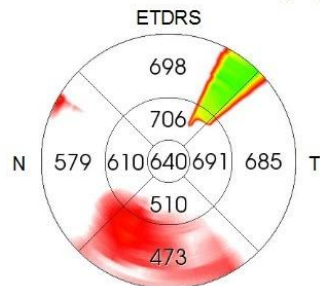
Capture Date : 19/8/2016



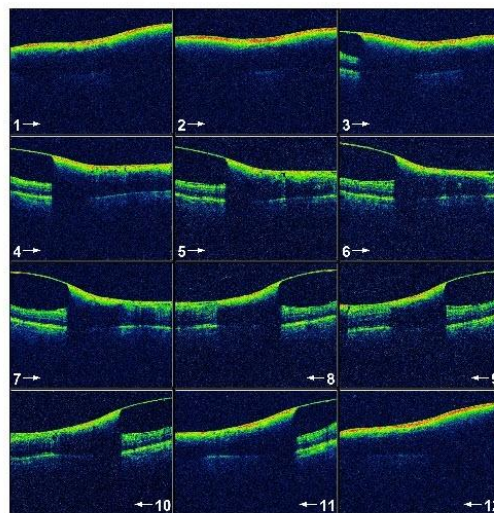
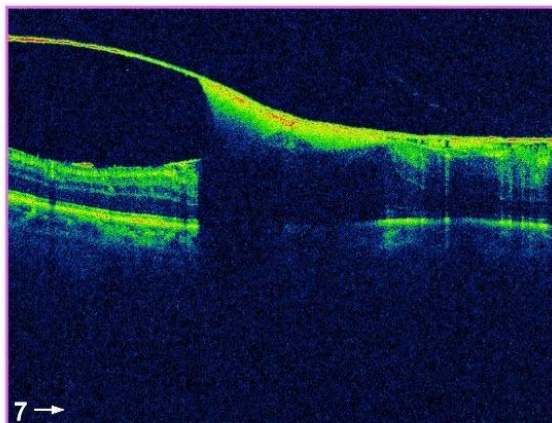
Retinal thickness map ILM - RPE / Red-free



Retinal thickness ILM - RPE (µm)



Average Thickness (µm) 614.4



Comments :

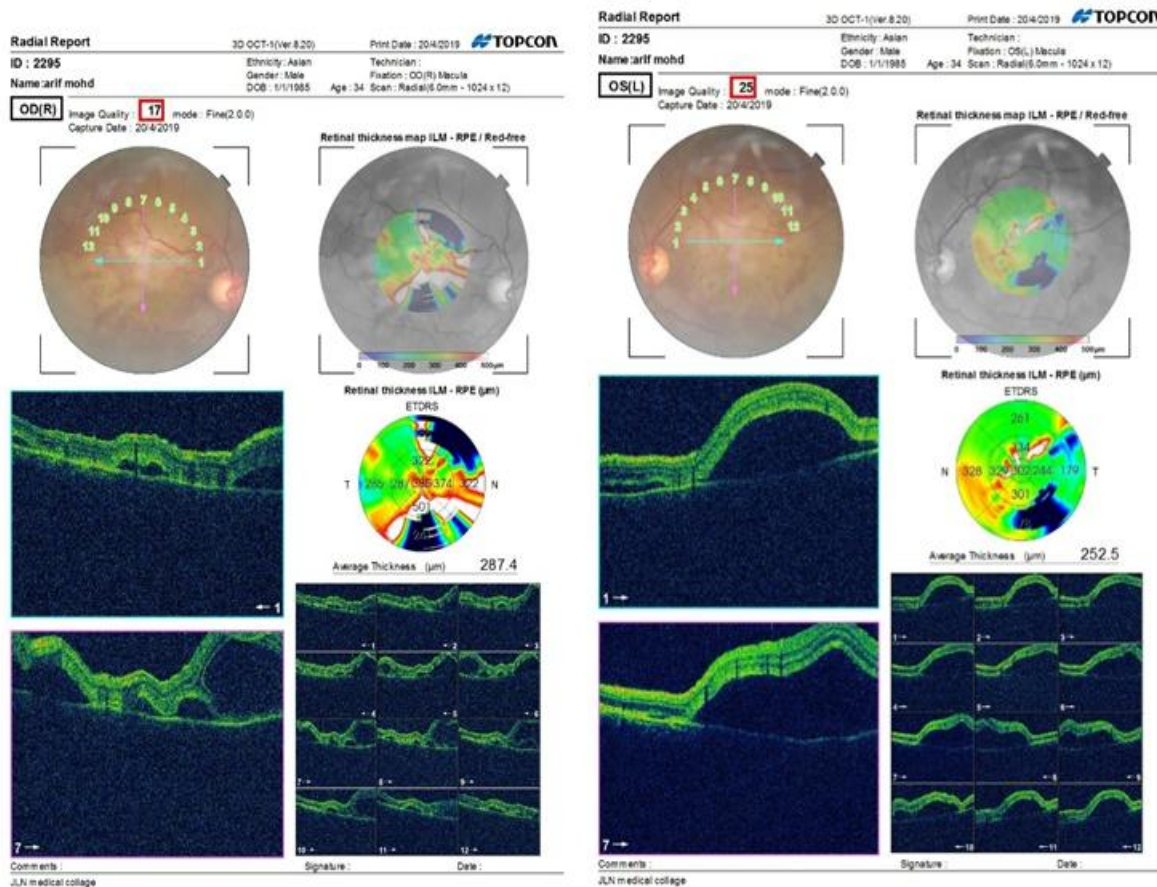
JLN medical collage

Signature :

Date :

OCT reveals a reflecting posterior hyaloid in the upper border fused with internal limiting membrane over the preretinal hemorrhage. OCT also gives the exact location of hemorrhage – sub-ILM or subhyaloid.

VKH



VKH characterized by bilateral multifocal neurosensory detachments with optically empty spaces.

ADVANTAGES OF OCT -

- Best axial resolution available so far.
- Scan various ocular tissues.
- Tissue sections comparable to histopathology sections.
- Easy to operate.
- Short scanning time.
- Non invasive, non contact.

LIMITATIONS OF OCT -

- Penetration depth of OCT is limited.
- Limited by media opacities.
- Each scan must be taken in range and focus.
- Axial motion is corrected with computer correlation software.
- Unable to visualize neovascular network or analyse if CNV is active.
- OCT images cannot be interpreted in isolation, must be correlated with fundus photography/ophthalmoscopy.

NEWER ADVANCEMENTS -

- With Longer-wavelength OCT systems including SS-OCT, the visualization of choroid-sclera interface is expected to improve.
- Doppler OCT can evaluate blood flow and volume of retinal and choroidal vasculature⁽²⁰⁻²⁴⁾, highlight vessels where the flow is present⁽²⁵⁾ and evaluate abnormalities in retinal and choroidal vasculature⁽²⁶⁾.
- En-face OCT provides further detail about the subtle pathological features in the retina and choroid in diseased states⁽²⁷⁾. It produces frontal sections of the retina layers so also called the 'C-scan OCT'.
- Enhanced depth imaging OCT enables the visualization of structures lying deeper in the eye like choroid.

- Intraoperative OCT helps surgeons to better delineate tissue structures thus reducing surgical time and excessive illumination.
- Adaptive optics OCT corrects for higher order ocular aberrations during image acquisition allowing improved lateral and near cellular level resolution.
- Optical microangiography (OMGA) technology allows volumetric map acquisition and in combination with widefield OCT can perform vascular perfusion mapping down to capillary level comparable to FFA and ICG.

II. Conclusion

OCT has provided better understanding, monitoring progression and response to various treatment modalities chorio-retinal diseases. This has revolutionized ophthalmic practice over the last decade. Further advancements in technologies are expected so that chorio-retinal diseases can be assessed in more detail.

References

- [1]. Huang D, Swanson EA, Lin CP, et al. Optical coherence tomography. *Science*. 1991;254:1178–1181.
- [2]. Sull AC, Vuong LN, Price LL, et al. Comparison of spectral/Fourier domain optical coherence tomography instruments for assessment of normal macular thickness. *Retina*. 2010;30:235–245.
- [3]. de Boer JF, Cense B, Park BH, et al. Improved signal-to-noise ratio in spectral-domain compared with time-domain optical coherence tomography. *Opt Lett*. 2003;28:2067–2069.
- [4]. Leitgeb R, Hitzinger C, Fercher A. Performance of Fourier domain vs. time domain optical coherence tomography. *Opt Express*. 2003;11:889–894.
- [5]. Ho J, Witkin AJ, Liu J, et al. Documentation of intraretinal retinal pigment epithelium migration via high-speed ultrahigh-resolution optical coherence tomography. *Ophthalmology*. 2011;118:687–693.
- [6]. Grulkowski I, Liu JJ, Potsaid B, et al. Retinal, anterior segment and full eye imaging using ultrahigh speed swept source OCT with vertical-cavity surface emitting lasers. *Biomed Opt Express*. 2012;3:2733–2751.
- [7]. Chinn SR, Swanson EA, Fujimoto JG. Optical coherence tomography using a frequency-tunable optical source. *Opt Lett*. 1997;22:340–342.
- [8]. de Boer JF, Milner TE, van Gemert MJ, Nelson JS. Two-dimensional birefringence imaging in biological tissue by polarization-sensitive optical coherence tomography. *Opt Lett*. 1997;22:934–936.
- [9]. Drexler W, Fujimoto JG. State-of-the-art retinal optical coherence tomography. *Prog Retin Eye Res*. 2008;27:45–88.
- [10]. Choma MA, Yang C, Izatt JA. Instantaneous quadrature low-coherence interferometry with 3×3 fiber-optic couplers. *Opt Lett*. 2003;28:2162–2164.
- [11]. Choma MA, Hsu K, Izatt JA. Swept source optical coherence tomography using an all-fiber 1300-nm ring laser source. *J Biomed Opt*. 2005;10:44009.
- [12]. Brown DM, Regillo CD. Anti-VEGF agents in the treatment of neovascular age-related macular degeneration: applying clinical trial results to the treatment of everyday patients. *Am J Ophthalmol*. 2007;144:627–637.
- [13]. Haouchine B, Massin P, Tadayoni R, et al. Diagnosis of macular pseudoholes and lamellar macular holes by optical coherence tomography. *Am J Ophthalmol*. 2004;138:732–739.
- [14]. Kusahara S, Teraoka Escano MF, Fujii S, et al. Prediction of postoperative visual outcome based on hole configuration by optical coherence tomography in eyes with idiopathic macular holes. *Am J Ophthalmol*. 2004;138:709–716.
- [15]. Negretto AD, Gomes AM, Goncalves FP, et al. Use of anatomical measures of idiopathic macular hole obtained through optical coherence tomography as a predictive factor in visual results: a pilot study. *Arq Bras Oftalmol*. 2007;70:777–783.
- [16]. Hillenkamp J, Kraus J, Framme C, et al. Retreatment of full-thickness macular hole: predictive value of optical coherence tomography. *Br J Ophthalmol*. 2007;91:1445–1449.
- [17]. Voo I, Mavrofrides EC, Puliafito CA. Clinical applications of optical coherence tomography for the diagnosis and management of macular diseases. *Ophthalmol Clin North Am*. 2004;17:21–31.
- [18]. Ojima T, Tanabe T, Hangai M, et al. Measurement of retinal nerve fiber layer thickness and macular volume for glaucoma detection using optical coherence tomography. *Jpn J Ophthalmol*. 2007;51:197–203.
- [19]. Garas A, Vargha P, Hollo G. Reproducibility of retinal nerve fiber layer and macular thickness measurement with the RTVue-100 optical coherence tomograph. *Ophthalmology*. 2010;117:738–746.
- [20]. Izatt JA, Kulkarni MD, Yazdanfar S, et al. In vivo bidirectional color Doppler flow imaging of picoliter blood volumes using optical coherence tomography. *Opt Lett*. 1997;22:1439–1441.
- [21]. Leitgeb R, Schmetterer L, Drexler W, et al. Real-time assessment of retinal blood flow with ultrafast acquisition by color Doppler Fourier domain optical coherence tomography. *Opt Express*. 2003;11:3116–3121.
- [22]. White B, Pierce M, Nassif N, et al. In vivo dynamic human retinal blood flow imaging using ultrahigh-speed spectral domain optical coherence tomography. *Opt Express*. 2003;11:3490–3497.
- [23]. Wang Y, Lu A, Gil-Flamer J, et al. Measurement of total blood flow in the normal human retina using Doppler Fourier-domain optical coherence tomography. *Br J Ophthalmol*. 2009;93:634–637.
- [24]. Leitgeb RA, Schmetterer L, Hitzinger CK, et al. Real-time measurement of in vitro flow by Fourier-domain color Doppler optical coherence tomography. *Opt Lett*. 2004;29:171–173.
- [25]. Makita S, Hong Y, Yamanari M, et al. Optical coherence angiography. *Opt Express*. 2006;14:7821–7840.
- [26]. Miura M, Makita S, Iwasaki T, Yasuno Y. Three-dimensional visualization of ocular vascular pathology by optical coherence angiography in vivo. *Invest Ophthalmol Vis Sci*. 2011;52:2689–2695.
- [27]. Srinivasan VJ, Adler DC, Chen Y, et al. Ultrahigh-speed optical coherence tomography for three-dimensional and en face imaging of the retina and optic nerve head. *Invest Ophthalmol Vis Sci*. 2008;49:5103–5110.

Dr. Rajesh Kumar Saini. “Optical Coherence Tomography: A New and Non-Invasive Diagnostic Tool for Chorio-Retinal Disorders.” *IOSR Journal of Dental and Medical Sciences (IOSR-JDMS)*, vol. 18, no. 10, 2019, pp 38-60.