

## Leukoplakia- Use of surgical Stripping and Skin Temp for Healing a Case Report

Dr. George Skariah. P, Dr.Sarath.S.S, Dr.Jyothi, Dr.Abhishek Pathak,

Dr. Syed Sajid Basha, Dr Sherin Shahana, Dr Kavya P V

(Department of oral and maxillofacial surgery, Government dental college ,Trivandrum)

Corresponding Author: Dr. George Skariah. P

---

**Abstract:** Oral leukoplakia is the most common potentially malignant disorder affecting oral cavity. Various surgical and non-surgical treatments have been reported, but currently there is no universal consensus on the most appropriate one and on the duration or interval of follow-up of patients with this condition. Management of oral leukoplakia should begin with elimination of risk factors (if any) such as tobacco abuse, betel chewing, alcohol abuse, superimposed candida infection over the lesion etc. Surgical treatment includes conventional surgery, electrocoagulation, cryosurgery, and laser surgery (excision or evaporation). In this case report we attempted conventional excision of leukoplakia with masked raw area with skintemp and evaluated healig of the lesion.

---

Date of Submission: 09-10-2019

Date of Acceptance: 25-10-2019

---

### I. Introduction

The term *leukoplakia* was coined in 1861 by Karl Freiherr von Rokitansky, who used it to refer to white lesions of the urinary tract<sup>1</sup>. In 1877 Schwimmer first used the term for an oral white lesion.<sup>2</sup>The name derives from Greek and is a combination of two words: “Leukos” means greyish white and “Plakos” means patch<sup>3</sup>.According to World Health Organization in 2005 defined it as “a white plaque of questionable risk having excluded known diseases or disorders that carry no increased risk for cancer”<sup>4</sup>.The etiology of leukoplakia is considered multifactorial, but smoking and tobacco is appreciated to be a frequently involved factor<sup>5,6</sup>.Clinically it is classified as early or thin, homogenous or thick, verruciform and speckled or erythroleukoplakia. Speckled type has highest risk of malignancy<sup>7</sup>.Nonsurgical treatment modalities include vitamins, antioxidants, bleomycin and photodynamic therapy, whereas surgical treatments are excision with grafting, LASER ablation and cryosurgery<sup>8</sup>.

### II. Oral Leukoplakia

#### Prevalence

Estimates of the global prevalence of oral leukoplakia range from 0.5 to 3.4%.<sup>9</sup>The point prevalence is estimated to be 2.6% (95% CI 1.72–2.74)<sup>2</sup> with a reported malignant transformation rate that ranges from 0.13 to 17.5%<sup>(10,11)</sup>. Prevalence increases with advancing age; it is less than 1% in men younger than 30 years, but 8% in men and 2% in women over 70 years. Smoking is the most commonly associated etiological factor but there are other possible factors such as alcohol, HPV infection, candidiasis, and reduced concentrations of serum vitamin A and beta-carotene<sup>12</sup>.

#### Classification

Considering the macroscopic appearance, oral leukoplakia is broadly classified into homogeneous and non-homogeneous subtypes. Homogeneous plaques are predominantly white, of uniform flat, thin appearance with shallow cracks of surface keratin, and have a smooth, wrinkled, or corrugated surface with a consistent texture throughout<sup>13</sup>.Non-homogeneous plaques are predominantly white, or white and red (erosive leukoplakia, erythroleukoplakia) and may be either irregularly flat, nodular (speckled), or verrucous<sup>14,15</sup>. Proliferative verrucous oral leukoplakia is a subtype of verrucous leukoplakia, and is characterized by a multifocal presentation, resistance to treatment, and high rate of malignant transformation<sup>14</sup>.

#### Histopathology

Oral leukoplakia can be distinguished as dysplastic and nondysplastic lesions based on histological examination.The presence of dysplasia has been associated with a risk of progression to cancer<sup>16</sup>.

It has been widely acknowledged that the grading of dysplasia is subjective, and there is little agreement among and between observers because of the lack of objectivity in the evaluation of established

criteria, arbitrary division of grades, lack of calibration of criteria and grading, and not enough knowledge about which criteria best predict malignant potential<sup>17</sup>. The binary system for histopathological grading was proposed to reduce variability between observers. In this system the lesions are graded as low risk (mild and moderate dysplasia) and high risk (severe dysplasia and carcinoma in situ) depending on the architecture and cytological changes. The sensitivity and specificity of the new binary grading system for predicting malignant transformation in oral epithelial dysplasia were 85% and 80%, respectively, and the accuracy was 82%<sup>17</sup>.

### **Malignant transformation**

Several factors have been associated with an increased risk of malignant transformation. Multivariate analysis has shown that age, site and type of lesion, and dysplasia are independent risk factor<sup>18</sup>.

### **Appearance**

In general, homogeneous lesions are thought to have a low risk of malignant transformation, mixed white and red lesions (or speckled leukoplakia) an intermediate risk, and pure erythroplakia (red lesions) the highest risk. However, none of these macroscopic features is reliably diagnostic of any histological grade of precursor lesion, and histological analysis of the lesions is mandatory to discover their biological potential<sup>19</sup>.

### **Site and age**

Lesions on the tongue or floor of the mouth, and larger lesions (more than 200 mm<sup>2</sup>) have also been known to be predictive indicators of malignant transformation, and it has been reported that in non-smokers they carry an increased risk. Elderly patients (over 60 years of age) with lesions on the lateral or ventral tongue, and who had non-homogeneous lesions with high-grade dysplasia, correlated a much higher risk of transformation.

### **Diagnosis**

A provisional diagnosis of oral leukoplakia is made when other possible etiological factors, including use of tobacco, have been ruled out. An arbitrary period of 2–4 weeks seems to be an acceptable time to look for regression after possible causative factors have been eliminated<sup>19</sup>. In practice this could mean – for example, smoothing the edges of a sharp tooth or a restoration. It is also well recognized that lesions sometimes take longer to regress or disappear.

A biopsy examination is essential if a lesion persists beyond this period to rule out any other specific disorder. Incisional biopsy with scalpel and histopathological examination of the suspicious tissue is the gold standard. Punch biopsy is a useful alternative and can be used in multiple and diffuse mucocutaneous lesions; incisional biopsy is done for large (more than 1.0 cm), multiple, or diffuse lesions. In those that contain areas of erythroplakia and leukoplakia, lesions with erythroplakia must be given priority because they have the most cellular activity<sup>20</sup>.

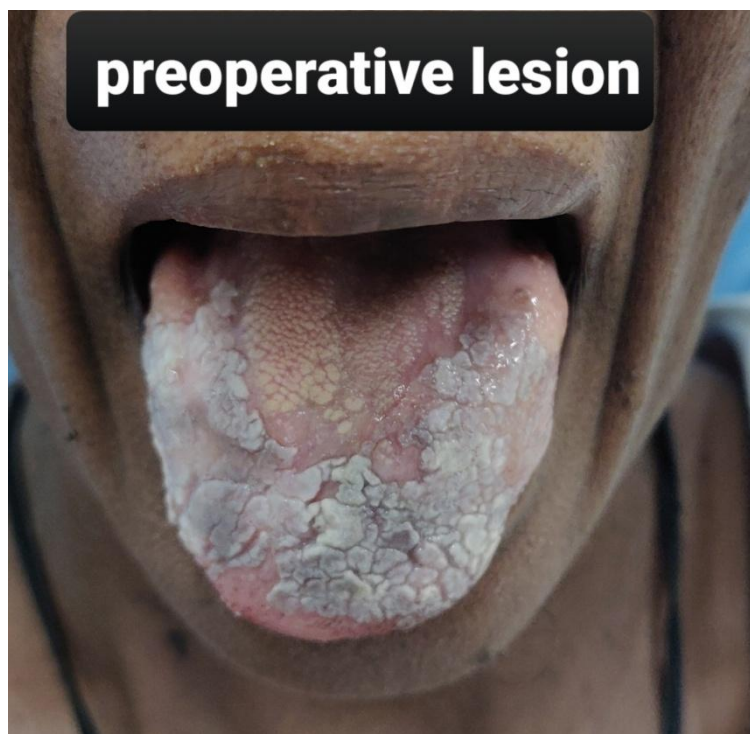
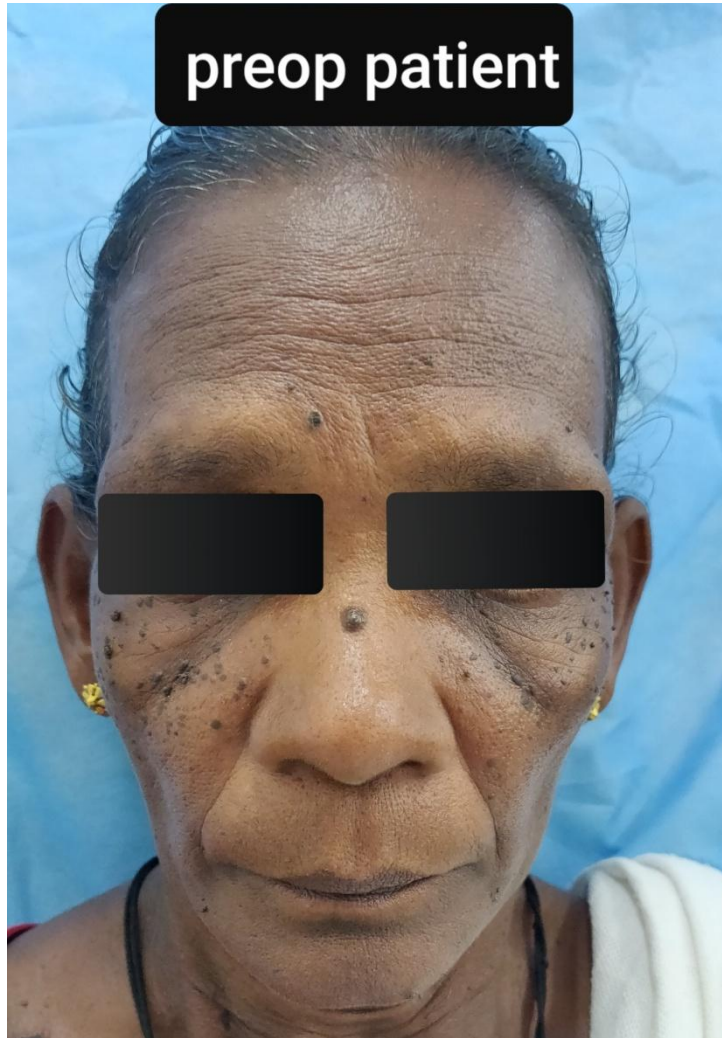### **Management**

The presence of epithelial dysplasia is still the strongest predictor of future malignant transformation. Some groups think that it is safe to treat all lesions irrespective of the presence of dysplasia, even though there has been no documented evidence that treatment of any kind prevents the possible future development of malignancy. Various non-surgical and surgical treatments have been reported, but currently there is no consensus on which is best. Outcomes seem to vary, and long-term follow-up studies are few. Operation can include conventional surgery<sup>21</sup>, Electrocauterisation, laser ablation or cryosurgery<sup>21,22</sup>. Non-surgical treatments to prevent malignant transformation may also be considered. The use of carotenoids (beta-carotene, lycopene)<sup>24</sup>, vitamins A, C, and K, and photodynamic therapy have been reported, but at this time randomised controlled trials for non-surgical treatment have not shown evidence that they effectively prevent malignant transformation and recurrence.<sup>25</sup> Invasive procedures include conventional surgery, electrocoagulation, cryosurgery, and laser surgery (excision or evaporation). Conventional surgery involves excision of the lesion with or without a skin graft or other dressing material, but often is not feasible for extensive lesions or those in certain anatomical locations. The associated morbidity of surgery also makes it less indicated for extensive lesions. Electrocoagulation produces thermal damage in the underlying tissue, which causes postoperative pain and edema, and leads to considerable scarring. Postoperative pain and edema are also severe after cryosurgery<sup>22</sup>. Carbon dioxide, neodymium:yttrium-aluminium garnet (Nd:YAG), argon, and potassium-titanyl-phosphate (KTP) lasers are used in the management of oral leukoplakia<sup>22</sup>. Advantages are haemostatic effects, minimal electro contractility, and minimal damage to the surrounding tissue, which reduces acute inflammatory reaction and postoperative pain. Wound healing is excellent because of limited contraction; it produces satisfactory mobility of the oral mucosa and minimum oral dysfunction. Various factors such as surgical technique, selection of patients, and follow-up periods may account for the wide range of results. The laser evaporation technique has a disadvantage, as no tissue is available for histopathological examination.

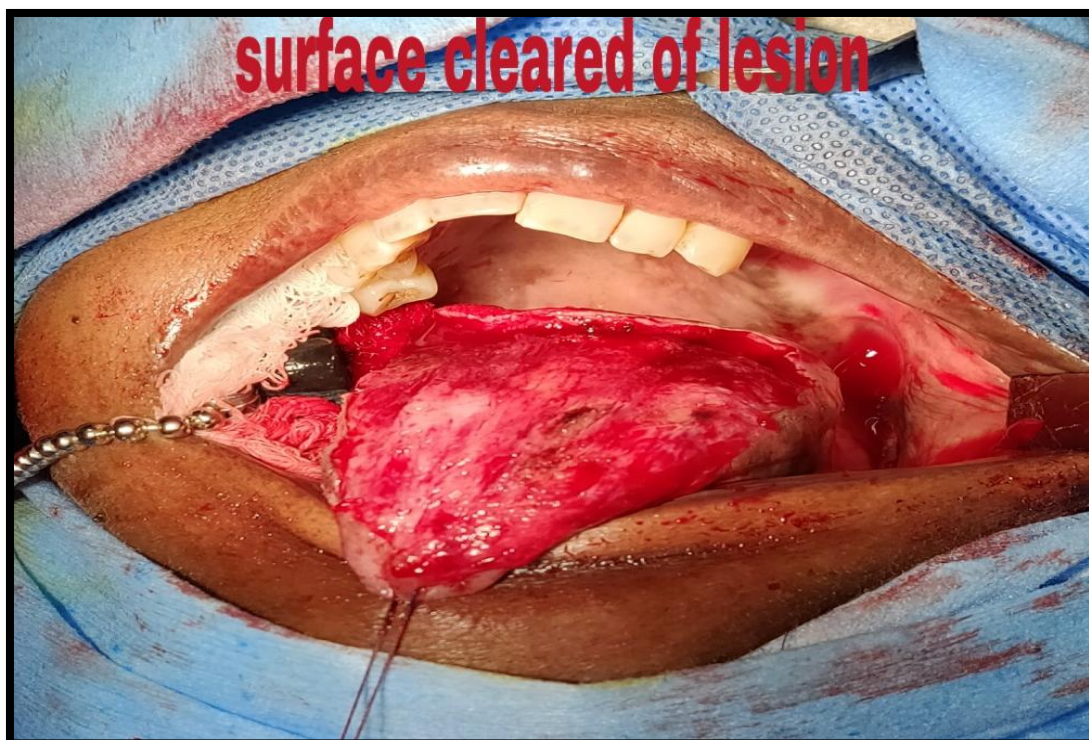
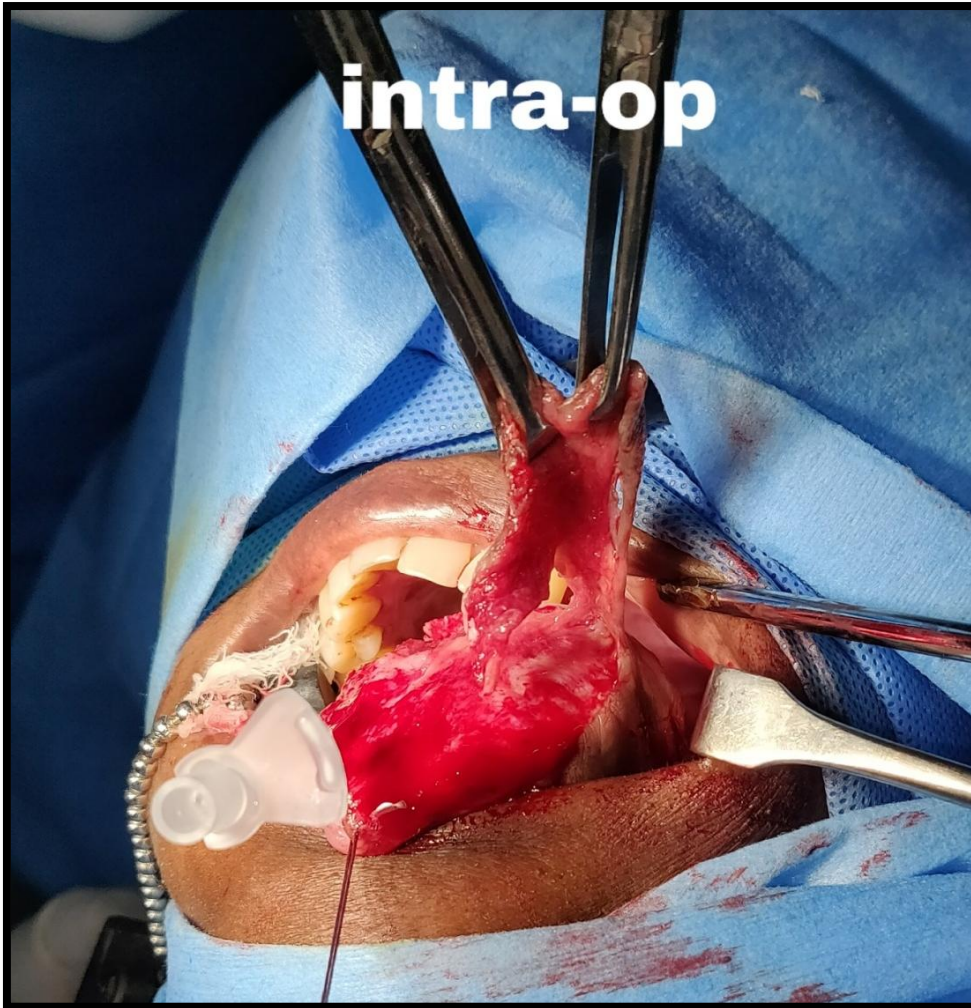
### III. Case Report

A 65 Year old female patient resident of Paripally, Trivandrum. Referred from Department of oral medicine ,came to Department of oral and maxillofacial surgery,government dental college Trivandrum with complaint of grayish white discoloration over tongue since 10 years.History of tobacco chewing since 25 years. Patient came to dept of oral medicine with similar complaint in 2010 diagnosed as leukoplakia and managed conservatively,lesion was responding to medication and was under irregular follow up.Patient is apparently healthy with no known systemic diseases. On intra oral examination it was noted that a non scrapable grayish white patch on dorsum of tongue extending to ventral surface on right side and anteriorly up to 5 mm behind tip of tongue ,posteriorly up to 2/3 rd of tongue measuring of 5.5\*3.2 cm in maximum dimension. As the lesion was of longer duration and was on long-term medical treatment, with no aggravation of symptoms she was referred from dept of oral medicine to rule out malignancy and consider for surgical management of lesion.Clinical diagnosis was confirmed with the help of Incisional biopsy, where the small portion of tissue was sent for microscopic examination.Routine haematological investigations were done.Surgical excision of Leukoplakia was planned under general anaesthesia. All universal precautions were followed. Lesion was made free from margins by incising it from surrounding normal mucosa. Gradual dissection was done underneath the lesion and lesion was removed by holding it with artery forcep and allis forcep. Raw submucosa after excision of lesion was covered by sterile SKIN TEMP and sutured .Proper medication was given to the patient postoperatively (inj Augmentin 625mg twice a day and inj Diclofenac sodium – SOS,inj metrogl 500mg tid) for five days. Betadine mouthwash was prescribed for better oral hygiene.Patient's tissue samples were sent to laboratory for histopathological examination. Healing progress was observed after 7 days and after a month. The patient is under follow up since 6 months and no recurrence has been found.Healing was indexed according to healing index by Landry(25) After skin temp placement at the interval of 7 days and 30 days .Healing progress was found very good to excellent in the case

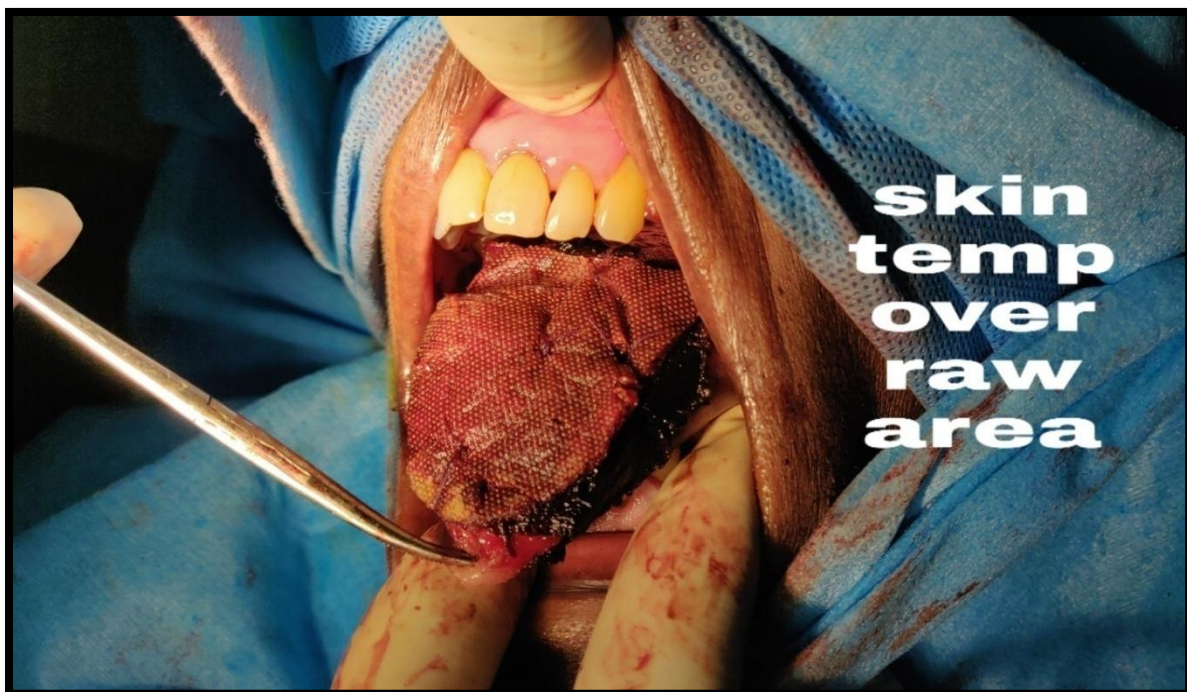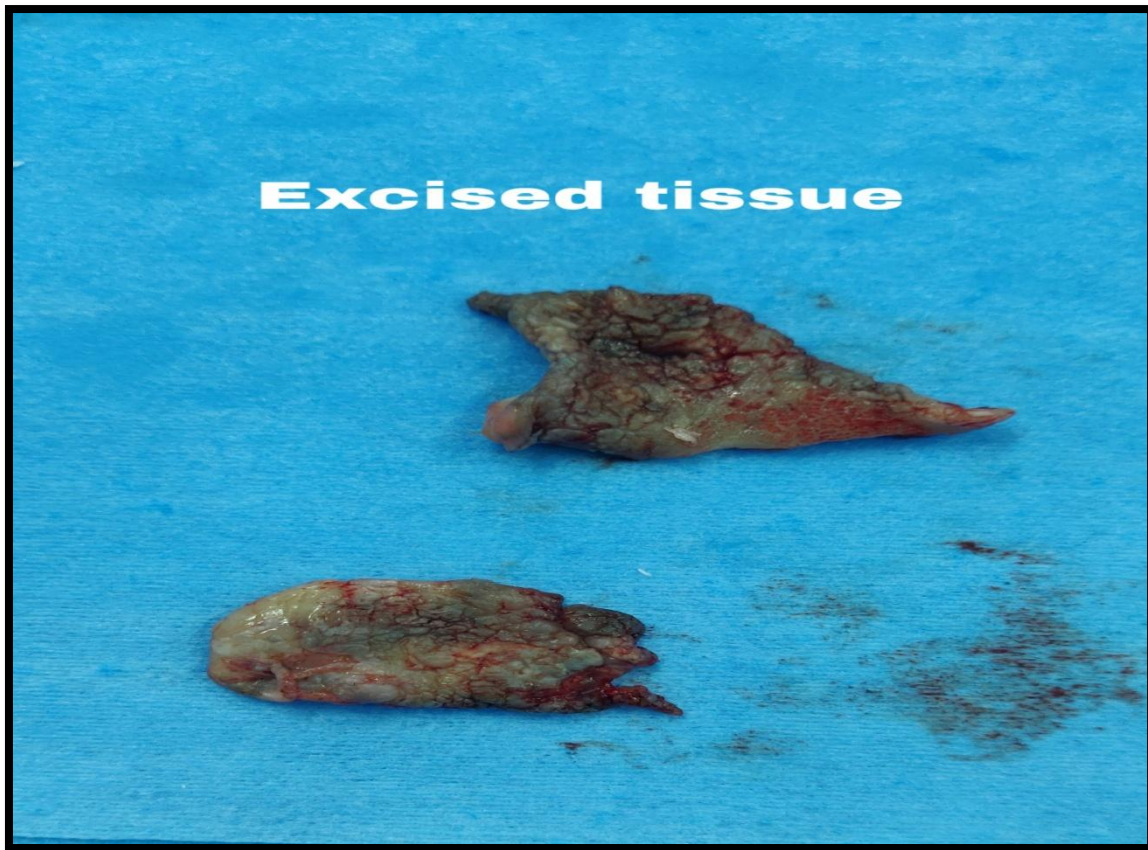HEALING INDEX	CRITERIA
VERY POOR 1	Tissue color: more than 50% of gingivae red Response to palpation :bleeding Granulation tissue: present Incision margin: not epithelialised, with loss of epithelium beyond margins Suppuration: present
POOR 2	Tissue color: more than 50% of gingivae red Response to palpation: bleeding Granulation tissue: present Incision margin: not epithelialised with connective tissue exposed.
GOOD 3	Tissue color: less than 50% of gingivae red Response to palpation: no bleeding Granulation tissue: none Incision margin: no connective tissue exposed
VERY GOOD 4	Tissue color: less than 25% of gingivae red Response to palpation: no bleeding Granulation tissue: none Incision margin: no connective tissue exposed
EXCELLENT 5	Tissue color: all gingivae pink Response to palpation: no bleeding Granulation tissue: none Incision margin: no connective tissue exposed



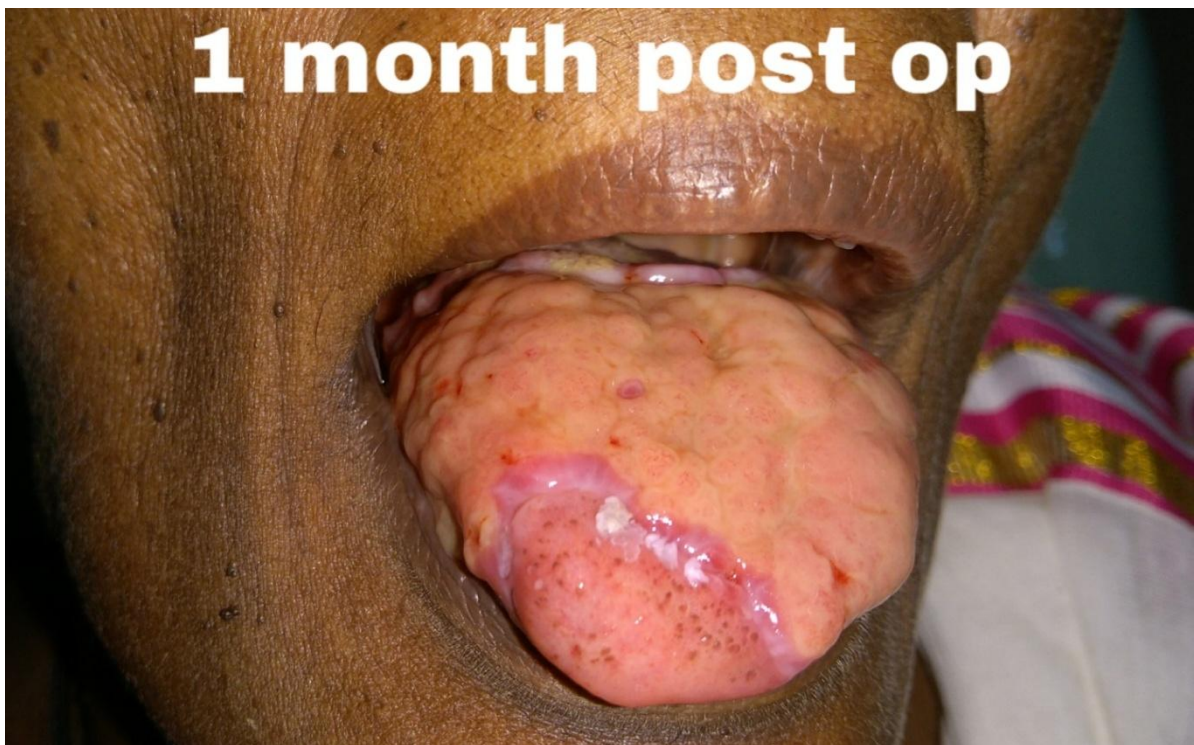
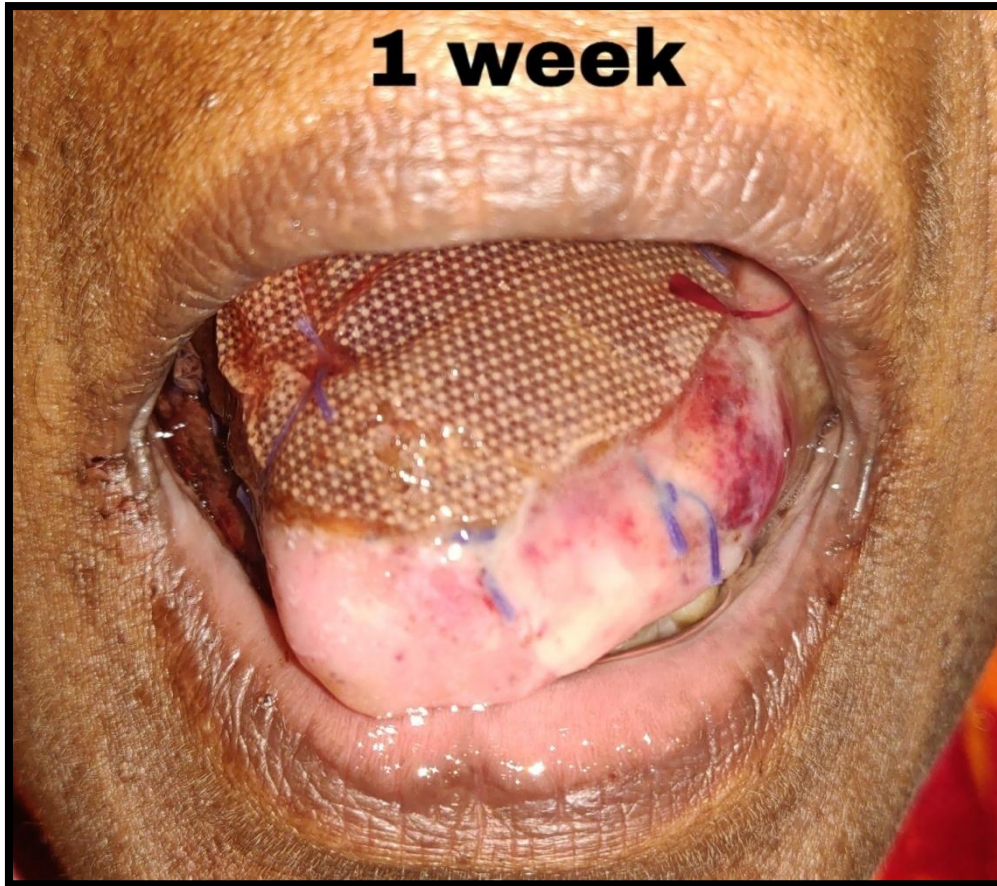










**preop biopsy**

DIRECTORATE OF MEDICAL EDUCATION

**DEPARTMENT OF ORAL PATHOLOGY AND MICROBIOLOGY**

GOVT. DENTAL COLLEGE, THIRUVANANTHAPURAM

**Histopathological Examination Report**

From the Department: OMFS

Biopsy No: 236/19

Name of Patient: Syamala

Age: 60 Sex: Female

Site of Biopsy: Dorsum of tongue

IP/OP No: 24210

Provisional Diagnosis: Leukoplakia

Date of receipt: 15.05.19

---

**GROSS SPECIMEN:** Formalin Fixed tissue, single soft tissue bit, pearly white in colour with underlying brown areas, firm in consistency.

**MICROSCOPY:** reveals serial sections of H&E stained tissue showing a hyperorthokeratinized stratified squamous epithelium overlying a connective tissue stroma. The epithelium shows mild dysplastic features. The connective tissue stroma shows moderate to dense collagenicity and moderate cellularity. The inflammatory cell infiltrate is minimal and composed of few lymphocytes. Vascularity is moderate with forming, formed and engorged blood vessels. Deeper areas of the section show numerous skeletal muscle fibers. Extravasated RBCs are also seen.

**DIAGNOSIS:** *Epithelium showing mild dysplasia with hyperorthokeratosis*

Date of issue: 23/05/2019



## post op biopsy report

DEPARTMENT OF ORAL PATHOLOGY AND MICROBIOLOGY

GOVT. DENTAL COLLEGE, THIRUVANANTHAPURAM

Histopathological Examination Report

From the Department of: OMFS

Biopsy No: 274-19

Name of Patient: Syamala

Age: 65years Sex: Female

Site of Biopsy: dorsum of tongue

IP/OP No: 41914/19

Provisional Diagnosis: OSMF with leukoplakia


Date of receipt: 11-06-19

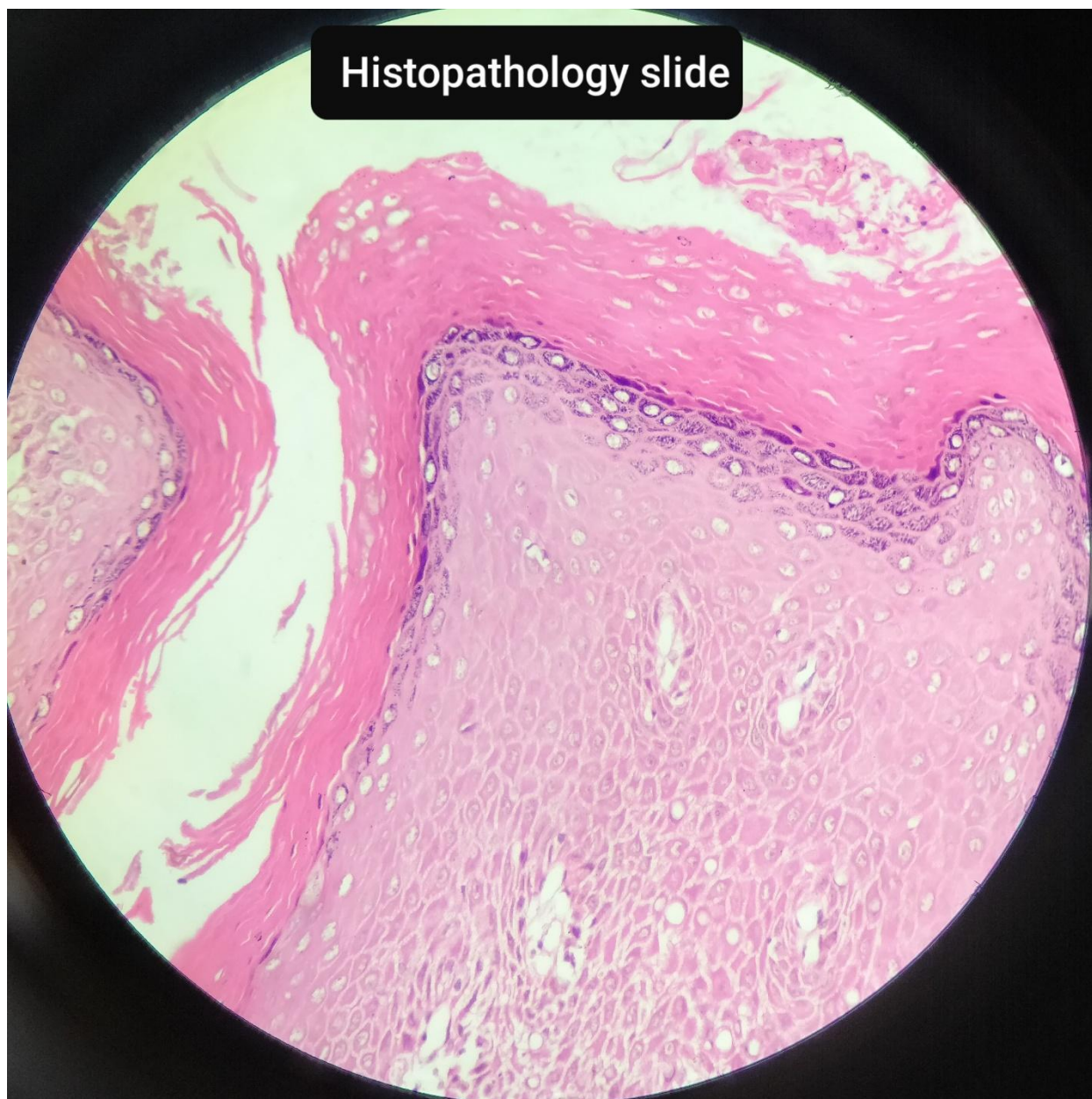
GROSS SPECIMEN: FF tissue two soft tissue bits greyish in colour with underlying brown areas, firm in consistency, irregular surface.

MICROSCOPY: Reveals serial sections of H&E stained tissue showing hyperkeratotic hyperplastic stratified squamous epithelium overlying a hyperplastic moderate to dense collagenous lamina propria. The epithelium is devoid of papillae and at most of the areas the epithelial-connective tissue interface is flat. The epithelium exhibits minimal dysplasia with hyper-orthokeratosis at majority of the areas. The connective tissue stroma is of moderate cellularity and moderate to dense collagenecity. Vascularity is intense with forming and formed blood vessels. Inflammatory infiltrate is moderate and seen predominantly in juxta epithelial and peri-vascular region. Deeper sections show muscle fibers and nerve tissue.

DIAGNOSIS: features suggestive of *epithelial hyperplasia with minimal dysplasia & hyperkeratosis*

Date of issue: 25-06-19

  
Name & Signature of the faculty



#### **IV. Conclusion**

SKIN TEMP grafting after surgical excision of leukoplakia is promising treatment modality. It avoids donor site morbidity for covering raw area with graft. Compared to LASERS and Cryotherapy chances of hazards are very less and less technique sensitive. It is a good treatment option for surgical management of leukoplakia keeping in mind some basic precautions.

#### **References**

- [1]. Petrou, Steven P; David M. Pinkstaff; Kevin J. Wu; Kenneth J. Bregg (November 2003). "Leukoplakia of the Bladder". Cliggott Publishing. Archived from the original on 10 September 2017. Retrieved 6 May 2013.
- [2]. E. Schwimmer, "Die idiopathischen Schleimhautplaques der Mundhöhle (Leukoplakia buccalis)," Archives of Dermatology—Syphilis, vol. 9, pp. 570–611, 1877.
- [3]. Anna Starzynska et al. Estimation of oral leukoplakia treatment records in the research of the department of maxillofacial and oral surgery, medical university of Gdansk. PostepDermAlergol 2015; 2: 114-122.
- [4]. World Health Organization. World Health Organization classification of tumours. In: Barnes L, Eveson JW, Reichart P, Sidransky D, editors. Pathology and Genetics. Head and Neck Tumours. Lyon: International Agency for Research on Cancer Press; 2005. pp. 177–9.
- [5]. S. Warnakulasuriya, N. W. Johnson, and I. van der Waal, "Nomenclature and classification of potentially malignant disorders of the oral mucosa," Journal of Oral Pathology and Medicine, vol. 36, no. 10, pp. 575–580, 2007.
- [6]. IoaninaParlatescu et al. Oral leukoplakia – an update. J Clin Med 2014; Vol. 9: No. 1.



- [7]. [7]. K. M. K. Masthan et al. Leukoplakia: A short review on malignant potential. *J Pharmacy and Bioallied Sciences* April 2015; Vol 7: Supplement 1.
- [8]. Anand Kumar et al. How should we manage oral leukoplakia ? *Br J Oral Maxillofac Surg.* 2013 Jul;51(5):377-83.
- [9]. Petti S. Pooled estimate of world leukoplakia prevalence: a systematic review. *Oral Oncol* 2003;39:770–80.
- [10]. Holmstrup P, Vedtofte P, Reibel J, Stoltze K. Long-term treatment outcome of oral premalignant lesions. *Oral Oncol* 2006;42:461–74
- [11]. Reibel J. Prognosis of oral pre-malignant lesions: significance of clinical, histopathological, and molecular biological characteristics. *Crit Rev Oral Biol Med* 2003;14:47–62.
- [12]. Brailo V, Vucicević Boras V, Cekić-Arambašin A, Alajbegić Z, Milenović A, Lukac J. The significance of salivary interleukin 6 and tumor necrosis factor alpha in patients with oral leukoplakia. *Oral Oncol* 2006;42:370–3
- [13]. Axéll T, Pindborg JJ, Smith CJ, van der Waal I. Oral white lesions with special reference to precancerous and tobacco-related lesions: conclusions of an international symposium held in Uppsala, Sweden May18–21 1994. An International Collaborative Group on Oral White Lesions. *J Oral Pathol Med* 1996;25:49–54.
- [14]. van der Waal I. Potentially malignant disorders of the oral and oropharyngeal mucosa: present concepts of management. *Oral Oncol* 2010;46:423–5.
- [15]. van der Waal I, Axéll T. Oral leukoplakia: a proposal for uniform reporting. *Oral Oncol* 2002;38:521–6. 10. Warnakulasuriya S, Reibel J, Bouquot J, Dabelsteen E. Oral epithelial dysplasia classification systems: predictive value, utility, weaknesses and scope for improvement. *J Oral Pathol Med* 2008;37:127–33.
- [16]. Warnakulasuriya S. Histological grading of oral epithelial dysplasia: revisited. *J Pathol* 2001;194:294–7. 12. Bosman FT. Dysplasia classification: pathology in disgrace? *J Pathol* 2001;194:143–4.
- [17]. Kujan O, Oliver RJ, Khattab A, Roberts SA, Thakker N, Sloan P. Evaluation of a new binary system of grading oral epithelial dysplasia for prediction of malignant transformation. *Oral Oncol* 2006;42:987–93.
- [18]. Liu W, Shi LJ, Wu L, et al. Oral cancer development in patients with leukoplakia—clinicopathological factors affecting outcome. *PLoS ONE* 2012;7:e34773.
- [19]. van der Waal I, Schepman KP, van der Meij EH, Smeele LE. Oral leukoplakia: a clinicopathological review. *Oral Oncol* 1997;33:291–301.
- [20]. Chan MH, Wolf JC. Biopsy techniques and diagnoses and treatment of mucocutaneous lesions. *Dent Clin North Am* 2012;56:43–73.
- [21]. Ribeiro AS, Salles PR, da Silva TA, Mesquita RA. A review of thenonsurgical treatment of oral leukoplakia. *Int J Dent* 2010;2010:186018.
- [22]. Ishii J, Fujita K, Komori T. Laser surgery as a treatment for oral leukoplakia. *Oral Oncol* 2003;39:759–69.
- [23]. Ishii J, Fujita K, Munemoto S, Komori T. Management of oral leukoplakia by laser surgery: relation between recurrence and malignant transformation and clinicopathological features. *J Clin Laser Med Surg* 2004;22:27–33.
- [24]. Sankaranarayanan R, Mathew B, Varghese C, et al. Chemoprevention of oral leukoplakia with vitamin A and beta carotene: an assessment. *Oral Oncol* 1997;33:231–6.
- [25]. Early Wound Healing Score: a system to evaluate the early healing of periodontal soft tissue wounds Lorenzo Marini,<sup>1</sup> Mariana Andrea Rojas,<sup>1</sup> Philipp Sahrman,<sup>2</sup> Rustam Aghazada,<sup>1</sup> Andrea Pilloni<sup>1</sup>

Dr. George Skariah. P. “Leukoplakia- Use of surgical Stripping and Skin Temp for Healing A Case Report.” *IOSR Journal of Dental and Medical Sciences (IOSR-JDMS)*, vol. 18, no. 10, 2019, pp 20-30.