

B Scan of Orbit with Its Clinico-Surgical Correlation

Dr. Hemangini Thakkar¹, Dr. Padma Badhe², Dr. Sagar Sonone³,
Dr. Dasari Ravi Kiran⁴

¹(Associate professor, Department of Radiology, Seth G.S Medical college and KEM hospital, Mumbai, India)

²(Associate professor, Department of Radiology, Seth G.S Medical college and KEM hospital, Mumbai, India)

³(Resident, Department of Radiology, Seth G.S Medical college and KEM hospital, Mumbai, India)

⁴(Resident, Department of Radiology, Seth G.S Medical college and KEM hospital, Mumbai, India)

Corresponding author- Dr. Padma Badhe

Abstract:

Aims and objectives- To evaluate role of USG in orbital and extra-orbital diseases.

Materials and methods- It was a hospital based, observational, descriptive study with a sample size of 144 cases during a period of 1.5yrs in the department of radiology of Seth G.S Medical college and KEM Hospital, Mumbai. Patients undergoing B-scan as advised by their treating physicians were included in this study.

Results-In our study, 144 patients underwent B scan for diagnosing various pathologies of the orbit out of which 135 patients were positive for ocular pathology and 9 patients were normal.

Out of 119 cases of intraocular pathologies, 32(23.7%) patients had vitreous hemorrhage followed by the retinal detachment which was seen in 25(18.5%) patients. 12(8.8%) patients had Vitreous detachment, 10(7.4%) patients had endophthalmitis.

There were total 16(11.8%)cases of extraocular pathologies, thyroid ophthalmopathy was the commonest extraocular pathology seen in 8(5.9%) patients, followed by a pseudo tumor seen in 7(5.1%) patients.

B scan was normal in 9 (6.6%)cases, these cases had opaque media (corneal opacity), B scan was performed to rule out posterior segment pathologies. Color Doppler was used simultaneously in all cases to see the vascularity of the different pathologies. Color Doppler imaging was very effective in the detection of the vascular lesions of the orbit like lidhemangioma,thyroid ophthalmopathy, retinal detachment and ocular tumors like retinoblastoma and melanoma.

Out of 32(23.7%) patients with history of trauma, vitreous hemorrhage was the commonest finding in trauma followed by retinal detachment.

There is 100% accuracy of the B-scan in diagnosing intraocular tumors, retinoblastoma is most common in pediatric age and melanoma in the adult population.. B scan of the orbit has limited value in assessing orbital masses with intracranial extension and the involvement of the bones. Cross sectional imaging CT scan and MRI are better in diagnosing intracranial extension and involvement of bone.

Conclusions-B- scan is quick technique and allows fast evaluation of orbit and it provides valuable information in the short time. B-scan with dynamic imaging technique gives us real time images of lesions with respect to ocular movements.

B scan is cost-effective and non-invasive imaging modality and best tool for follow up of many ocular pathologies. It is free of ionizing radiation and requires no contrast agents as required in the cross sectional imaging techniques like CT and MRI.

It is a sensitive and accurate diagnostic technique for vitreo-retinal pathologies, ocular neoplasms like retinoblastoma, melanoma and patients with trauma.

B scan is accurate in detecting and localizing foreign bodies. It plays a key role in emergency conditions and for management of ocular trauma. Color Doppler Imaging is an important part of the evaluation of the various ocular pathologies like retinal detachment, vascular lesions like hemangioma, lymphangioma.

It is a very effective imaging modality in conditions with opaque media where indirect ophthalmoscopy is not possible for pathologies of the posterior segment of the globe.

Keywords: Bscan and Orbit.

Date of Submission: 20-12-2018

Date of acceptance: 06-01-2019

I. Introduction

The cystic structure and superficial position make the eye ideal for ultrasound imaging. Ultrasonography is a noninvasive imaging technique without any ionizing radiation risk. It provides information, not given by any other imaging modality in cases of orbit. Ultrasound provides real-time cross-sectional images of various parts of the orbit and detects various pathologies.

More than a few decades have passed since the early reports of clinical usefulness of ultrasound in diagnosing orbital pathologies. The use of ultrasound for diagnostic imaging of the orbit and extraocular structures was originated by the work of Mundt and Hughes (A-scan) and Baum and Greenwood (B-scan) in the 1950s.(1)

The eye is evaluated with A- and B-mode scanning. Lesions in the posterior two-thirds of the orbit are detected through a transocular ultrasonography. Lesions located in the anterior third of the orbit are detected through ultra-high resolution ultrasonography. Real-time cross-sectional anatomy of the entire orbit is possible with conventional sonographic equipment and for visualization of the anterior chamber, a dedicated sonographicbiomicroscope is required.

Eyes are located superficially. The advent of high-frequency ultrasound, has made it ideal for imaging the globe and orbit. Ultrasound is used more commonly to evaluate the orbit and extraocular structures, especially in conditions in which direct examination by slit-lamp and fundoscopy is not sufficient. A sonographic examination is rapid and economic with rare contraindications. The other imaging modalitylike MRI has contraindications like patients with pacemakers and metallic implants, ultrasound avoids ionizing radiation associated with CT scan.(2)

Orbital B scan covers a wide range of diseases where clinical assessment is not possible like foreign bodies and trauma, retinal or choroid detachment, congenital or acquired structural anomalies and tumors, also in extraocular orbital diseases such as optic neuritis, abscess, foreign bodies or tumors. Doppler US increases the ability to diagnose orbital vascular anomalies and tumors and to assess blood flow in the vessels.

II. Aims And Objectives

1. To evaluate role of USG in orbital diseases, in differentiating ocular and extraocular diseases.
- 2.To evaluate orbital trauma and localization of foreign body.
3. To evaluate role of ultrasound in cases with opaque light conducting media where direct vision by ophthalmoscopy is impossible.

III. Materials And Methods

It was a hospital based, observational, descriptive study with a sample size of 144 cases during period of 1.5yrs in the department of radiology of Seth G.S Medical College and KEM Hospital, Mumbai. Patients undergoing B-scan as advised by their treating physicians were included in this study.

Based on outcome variables derived from previous literature, the most common pathological finding in B-scan in Indian population is that of vitreous hemorrhage.

Vitreous hemorrhage constitutes a proportion of 28% amongst the cases referred for B-scan in previous Indian literature. Based on this, considering an expected proportion of 0.28, with 95% confidence Interval and width of confidence interval 0.1535, the sample size required for our study was found to be 144.The same sample size was also obtained utilizing incidence of orbital trauma of 73.3%, which is a common indication for patients undergoing B-scan with a 95% confidence interval. B scan and color Doppler are integral parts of the same investigation, hence, the sample size and outcome measures used are the same for both.(3)

SamplingTechnique :Systematic random sampling.

A total of 1008 patient underwent B-scan in this tertiary hospital over a period of 18 months. Sampling interval taken was 7. A random number was chosen with the help of random number generator software, which was found to be 5. The first patient chosen was the 5th patient undergoing B-scan. Following this every 7th patient was chosen for the study.

Average no patients who were referred to the Ultrasound department for B scan in the study period of 18 months were 144.

Inclusion Criteria:

- Any sex, male or female of any age group including pediatric age group.
- Patients who were advised B-scan by their physicians.

ExclusionCriteria:

- Any patient not willing for the study.
- Any patient who is suspected case of ocular globe rupture due to trauma.
- Any patient who recently underwent ocular surgery.
- Any patient not compliant with procedure.

Study Procedure:

Proper informed consent was taken from the patient after explaining to them the risks and benefits of examination. All studies were performed on the Philips HD 11 XE and Philips Envisor ultrasound machine using linear high frequency transducer (7.5-13 MHz) and proper preset. Patients were instructed about the necessary eye movements to be performed with closed eyes. Examination was done in supine position with closed eyes and use of generous amount of the gel. Axial images of the globe were obtained from the upper to the lower poles and sagittal images were obtained from the temporal to nasal side. Oblique views and dynamic views were obtained with gentle eye movements from right to left and up to down. The other eye of the patient was used as control for the case. The final diagnosis with B-scan was correlated with clinical and surgical findings.

Statistical Methods: Descriptive and inferential statistical analysis has been carried out in the present study. Results on continuous measurements are presented on Mean SD (Min-Max) and results on categorical measurements are presented in Number (%). Significance is assessed at 5 % level of significance. The following assumptions on data is made,

Assumption: 1. Dependent variables should be normally distributed, 2. Samples drawn from the population should be random, Cases of the samples should be independent.

Chi-square/ Fisher Exact test has been used to find the significance of study parameters on categorical scale between two or more groups, Non-parametric setting for Qualitative data analysis. Fisher Exact test used when cell samples are very small.

Sensitivity, Specificity, PPV, NPV, Accuracy were computed to find the diagnostic properties of B scan against Final diagnosis.

Statistical Software: The Statistical software namely SPSS 18.0, and R environment ver.3.2.2 were used for the analysis of the data and Microsoft word and Excel have been used to generate graphs, tables etc.

IV. Results

In our study, 144 cases underwent B scan, It included patients from all age group. Adult population predominantly in the age group 4th and 5th decade were large in number (34.7%). The mean age of patients in our study is 42.58 with SD +19.42. The age distribution is shown below in the table

	No. of patients	%
1-10	9	6.3
11-20	14	9.7
21-30	11	7.6
31-40	31	21.5
41-50	32	22.2
51-60	18	12.5
61-70	19	13.2
71-80	7	4.9
>80	3	2.1
Total	144	100.0

Table 1 : Age distribution of patients.

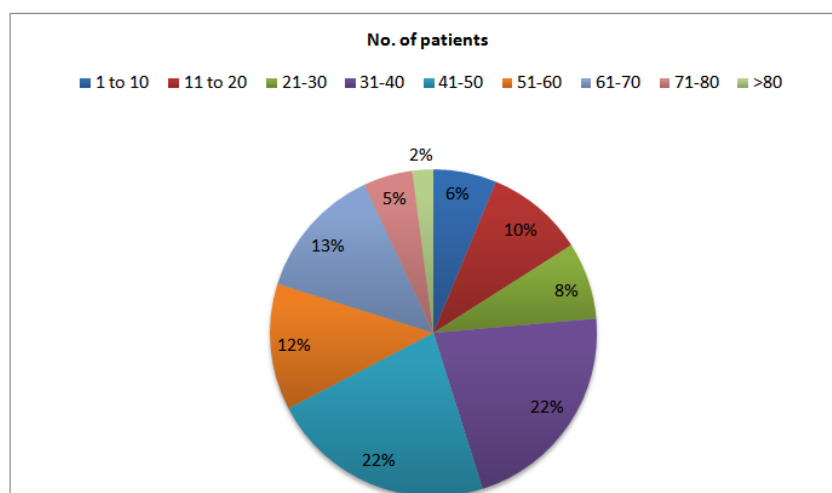


Fig 1: Pie Chart of Age distribution.

In this study, ocular pathologies were seen predominantly in males than females with sex ratio of 3:2. The table given below shows sex distribution of patients.

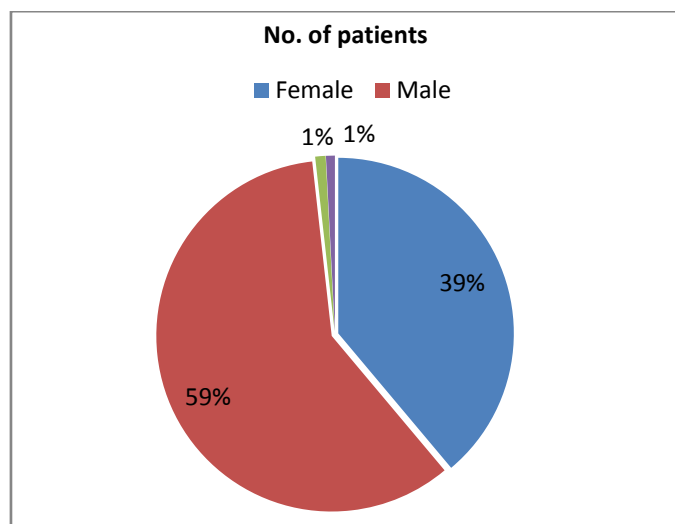
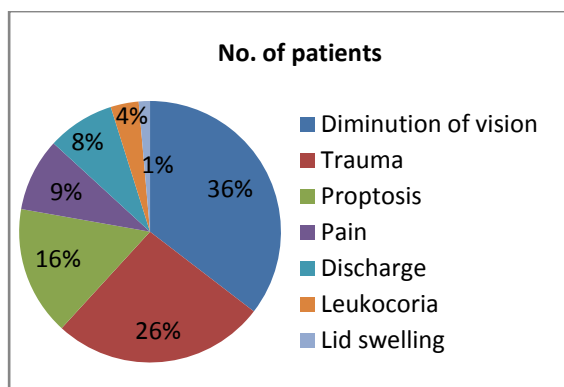


Fig 2 Pie chart showing gender distribution.

In this study, patients had presented with various ocular complaints like diminution of vision, trauma, proptosis, pain, eye discharge, leukocoria and eyelid swelling. Diminution of vision was the most common presenting complaint seen in our study. Out of 144 patients 51 patients(35.4%) had diminution of vision followed by trauma(26.4%). Least common presentation was lid swelling(1.4%).



	No. of patients	%
Diminution of vision	51	35.4
Trauma	38	26.4
Proptosis	23	16.0
Pain	13	9.0
Discharge	12	8.3
Leukocoria	5	3.5
Lid swelling	2	1.4
Total	144	100.0

Fig 3 Pie chart of Complaints of patients Table 3 showing presenting complaints of patients.

Opaque media was the most common indication for the B scan in our study, 72.2% patients had opaque media, where 5.6% were suspected having foreign body. Suspected orbital mass was the second most common indication for B scan. Lens opacification(cataract) and vitreous opacity are common causes of opaque media.

Indication of B Scan	No. of patients	%
Opaque media	104	72.2
Suspected orbital mass	21	14.6
Proptosis	11	7.6
Foreign body	8	5.6
Total	144	100.0

Table 4. Table showing distribution of indication of B scan

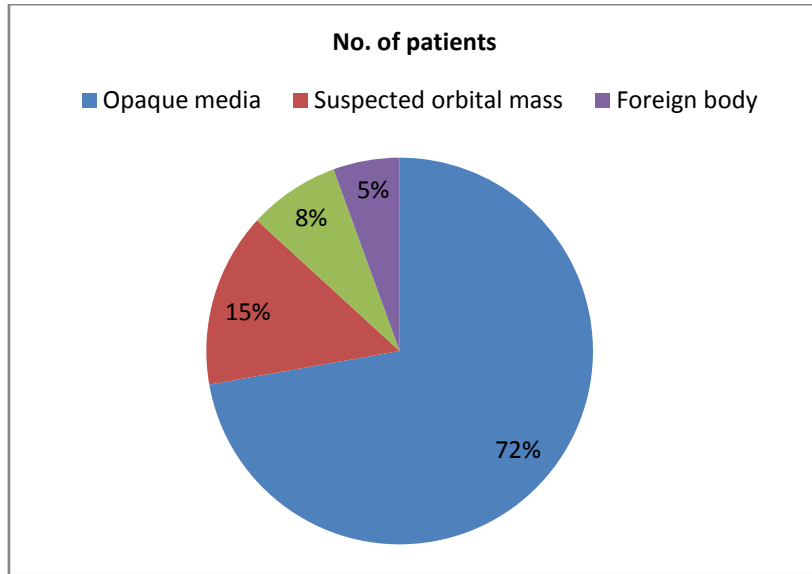


Fig 4 : Pie chart showing distribution of indication of B scan in patients.

In our study, 75 patients had involvement of left eye, 49 had involvement of the right eye . Only 20 patients had involvement of both eyes.

Involvement Eye	No. of patients	%
Both	20	13.9
Left	75	52.1
Right	49	34.0
Total	144	100.0

Table 5.: Table showing involvement of the eye.

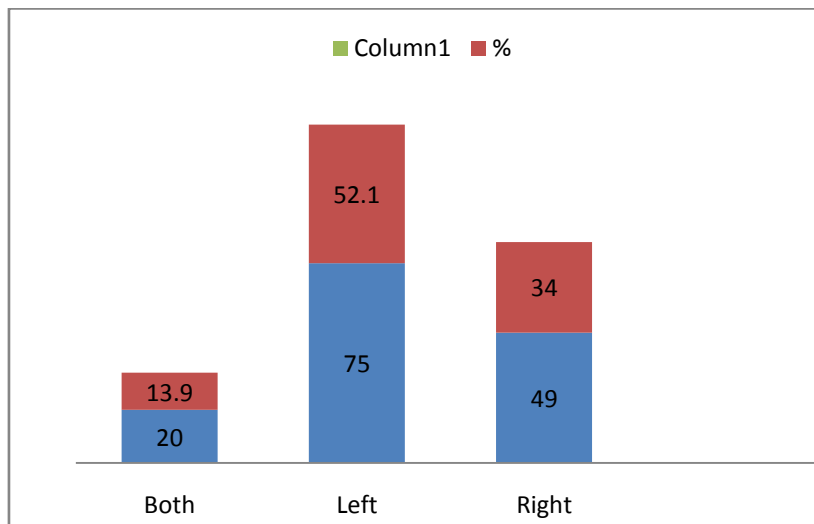


Fig 5: Bar diagram showing involvement of eye in patients.

Out of 144 patients, 135 patients had an abnormal finding on the B scan while only 9 patients had normal B scan. Vitreous hemorrhage was the most common abnormal finding followed by retinal detachment. There were ocular pathologies, while thyroid ophthalmopathy was the most common extraocular pathology.

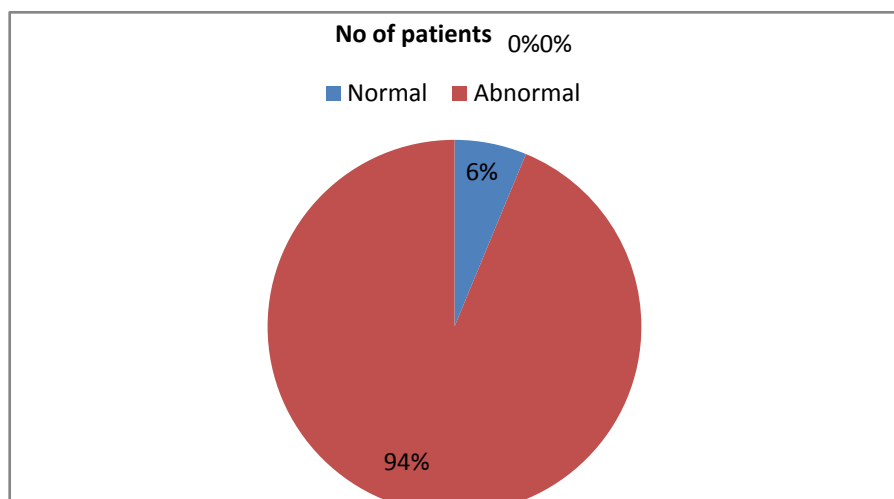


Fig 6: Pie chart showing B scan findings in patients.

Abnormal findings of B scan	No. of patients	%
• Vitreous haemorrhage	32	22.2
• Retinal detachment	25	17.4
• Vitreous degeneration	12	8.3
• Endophthalmitis	10	6.9
• Thyroid ophthalmopathy	8	5.6
• Pseudotumor	7	4.9
• Foreign body	6	4.2
• Vitreous detachment	6	4.2
• Dislocated lens	5	3.5
• Retinoblastoma	5	3.5
• Pleomorphic adenoma	3	2.1
• Choroidal detachment	2	1.4
• Scleritis	2	1.4
• Hyphema	1	0.7
• Lid carcinoma	1	0.7
• Cataract	1	0.7
• Lid hemangioma	1	0.7
• Melanoma	1	0.7
• Metastatic deposit	1	0.7
• Mucocoele	1	0.7
• Ocular cysticercosis	1	0.7
• Optic nerve glioma	1	0.7
• Pthisisbulbi	1	0.7
• Retension cyst	1	0.7
• Retrocular hematoma	1	0.7

Table 6: Table showing various abnormal findings on B scan.

B scan is able to distinguish ocular and extraocular pathologies in all patients. In our study 25 patients had extraocular pathologies and 119 patients had ocular pathologies.

Site pathology	No. of patients	%
Ocular	119	82.6
Extra ocular	16	17.4
Total	135	100.0

Table 7: Table showing site of pathology in patients.

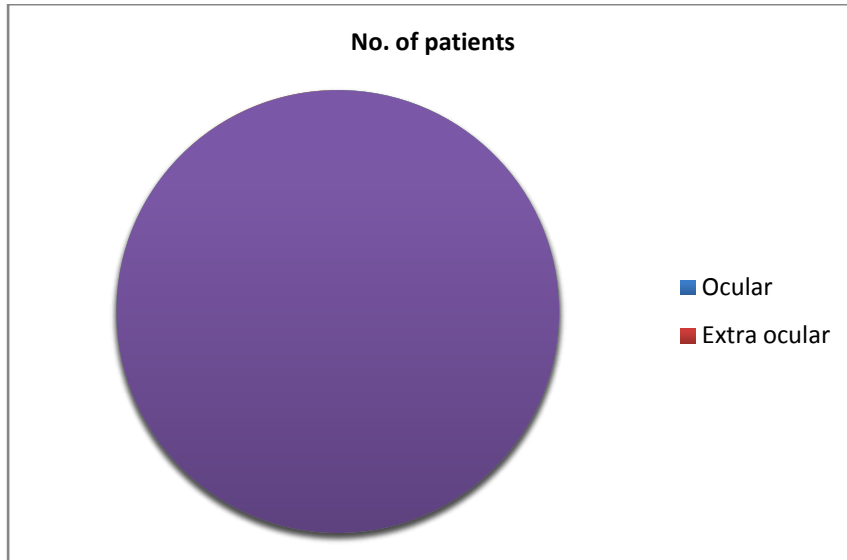


Fig 7: Pie chart showing site of pathology in patients .

Out of 25 patients with extraocular pathologies thyroid ophthalmopathy(32%)was the commonest followed by pseudotumor (28%). 3 patients(12%) had pleomorphic adenoma of lacrimal gland. Other pathologies like mucocoele, metastatic deposit, optic nerve glioma were also diagnosed on B scan.

Extra ocular Pathologies	No. of patients	%
optic nerve glioma	1	4.0
Retension cyst	1	4.0
Retrocular hematoma	1	4.0
Mucocoele	1	4.0
Metastatic deposit	1	4.0
Lid carcinoma	1	4.0
Lid hemanigioma	1	4.0
Pleomorphic adenoma	3	12.0
Thyroid ophthalmopathy	8	32.0
Pseudo tumour	7	28.0
Total	25	100.0

Table 8:showing distribution of extraocular pathologies in patients.

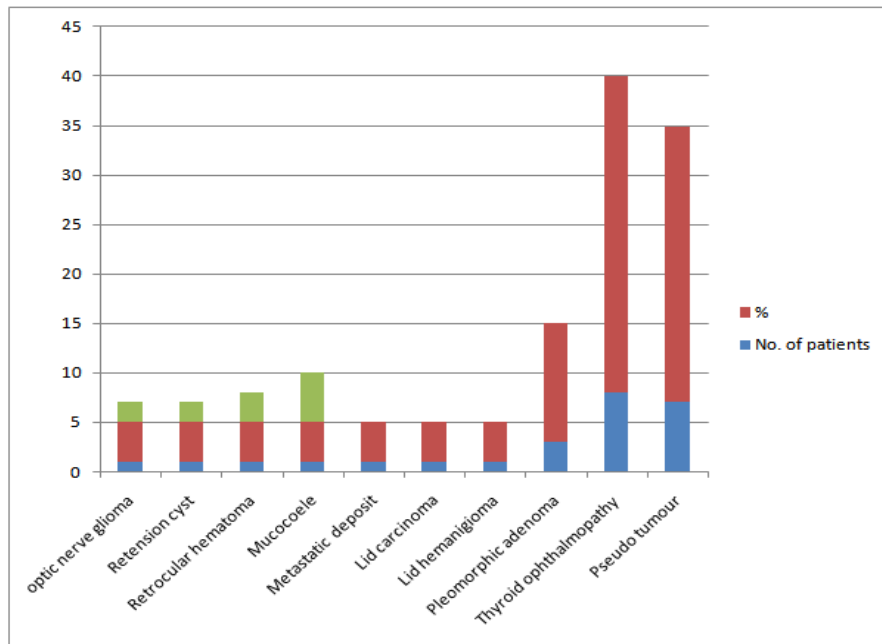


Fig 8: Bardiagram showing distribution of extraocular pathologies

Final Diagnosis	No. of patients (n=144)	%
Vitreous haemorrhage	31	21.5
Retinal detachment	26	18.1
Vitreous degeneration	12	8.3
Endophthalmitis	11	7.6
Thyroid ophthalmopathy	8	5.6
Pseudotumor	7	4.9
Foreign body	6	4.2
Dislocated lens	5	3.5
Retinoblastoma	5	3.5
Vitreous detachment	5	3.5
Pleomorphic adenoma	3	2.1
Fungal corneal infection	3	2.1
Choroidal detachment	2	1.4
Corneal dystrophy	2	1.4
Bacterial corneal infection	2	1.4
Fungal corneal ulcer	2	1.4
Scleritis	2	1.4
Cataract	1	0.7
Hyphema	1	0.7
Lid carcinoma	1	0.7
Lid hemanangioma	1	0.7
Melanoma	1	0.7
Metastatic deposit	1	0.7
Mucocoele	1	0.7
Ocular cysticercosis	1	0.7
Optic nerve glioma	1	0.7
Pthisisbulbi	1	0.7
Retension cyst	1	0.7
Retocular hematoma	1	0.7
Total	144	100.0

Table9: showing final diagnosis of patients.

Out of 144 patients , 38 patients had a history of the trauma. Vitreous hemorrhage was the most common finding on B scan followed by retinal detachment. The other pathologies like foreign body, lens dislocation ,choroidal detachment, phthisis bulbi and retrocular hematoma were also seen.

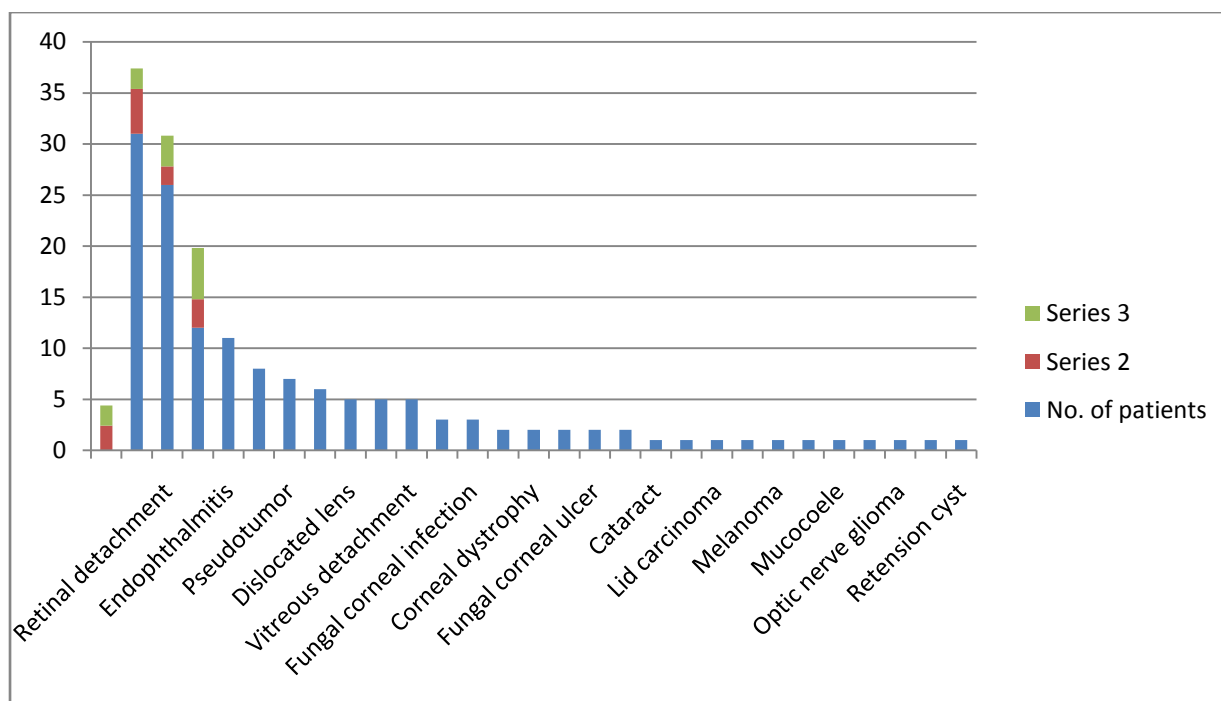


Fig 9:Bar Diagram showing the distribution of findings in patients with trauma.

Findings of the B scan were correlated with the final diagnosis of patients. Final diagnosis was achieved with final clinical, surgical and histopathological correlation. B scan findings and final diagnosis were grouped and statistical analysis was carried out.

In our study, in case of vitreous pathologies like vitreous hemorrhage, vitreous degeneration and vitreous detachment B scan had a diagnostic accuracy of 98.6 %, the sensitivity of 100%, specificity of 97.92%, PPV of 96% and NPV of 100% with the P value of <0.001 suggestive of strong significance.

Retinal detachment is the second most common finding in our study, where B scan had a sensitivity of 96.2%, specificity of 100%, PPV of 100%, NPV of 99.2% and diagnostic accuracy of 99.3 with strong statistical significance.

B scan was 99.3% accurate in diagnosing endophthalmitis with NPV of 99.2%, PPV of 100%. In patients with a history of the trauma with a foreign body and dislocated lens, B scan is accurate in diagnosing in the exact location of the foreign body and dislocated lens with PPV of 100% and NPV of 100%.

A total of 6 cases of intraocular tumors, 25 cases with extraocular pathologies and other rare ocular pathologies like phthisis bulbi, ocular cysticercosis and choroidal detachment were diagnosed accurately with B scan with a sensitivity of 100%, specificity of 100 %, PPV of 100% and NPV of 100%.

V. Discussion

In this study, all orbital pathologies were included. In this study, vitreous hemorrhage was found to be the commonest pathology. A total of 31 patients had the vitreous hemorrhage, diabetic retinopathy and trauma being the two most common causes of vitreous hemorrhage.

Vitreous detachment is the separation of vitreous from the retina. We had 5 cases of vitreous detachment, out of which, one case of retinal detachment was falsely diagnosed as vitreous detachment which was confirmed surgically.

12 cases of vitreous degeneration were diagnosed on B- scan with a diagnostic accuracy of 100%. Most of the patients were elderly.

Vitreous pathologies (50 cases) were the most common in our study. 100% Sensitivity and 98.6 % accuracy PPV of 96% and NPV 100% of B scan in diagnosing vitreous pathologies.

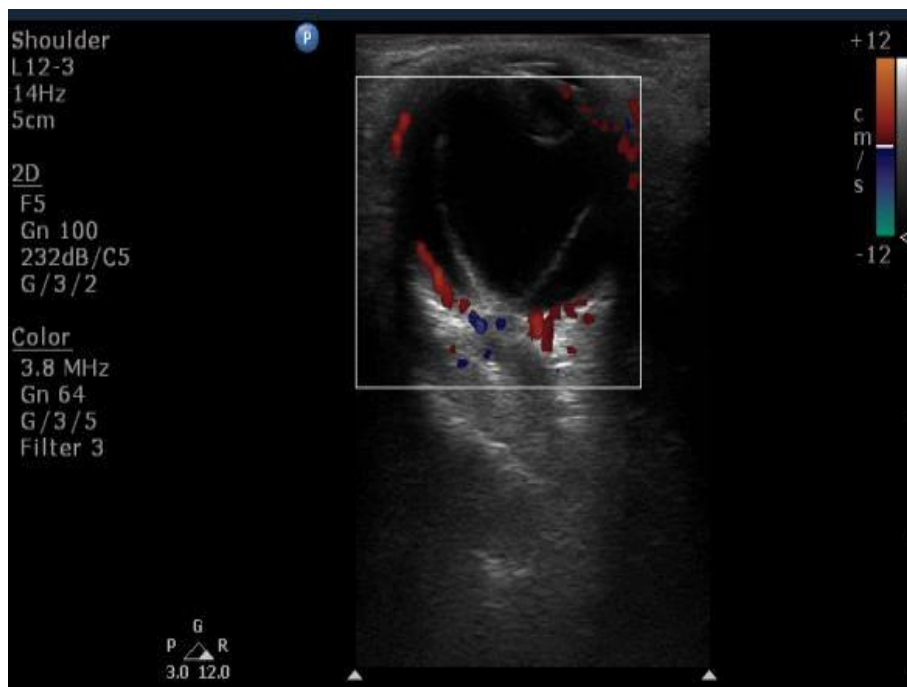

Fig 10: V shaped membranes attached to the optic disc -retinal detachment.

In this study, there were 26 cases of retinal detachment out of which 25 cases were diagnosed retinal detachment with a diagnostic accuracy of 99.3 %, specificity of 100% and 96.2 sensitivity of B scan, one case was false positively diagnosed.

There were 11 cases of endophthalmitis, 10 patients were diagnosed correctly on B scan, One case with endophthalmitis was diagnosed with vitreous hemorrhage as vitreous hemorrhage has similar imaging findings. Diagnostic accuracy of B scan was 99.3% and NPV of 99.2 %, PPV of 100%.

In this study, total 28 cases had a history of trauma with vitreous hemorrhage as commonest finding, all the cases with trauma were diagnosed with help of the B scan

The foreign body was accurately localized. Plain radiograph of orbit showed the presence of the foreign body which on surgical evaluation turned out to be a piece of metal (patient who was a blacksmith by occupation) embedded in the vitreous of the eye.

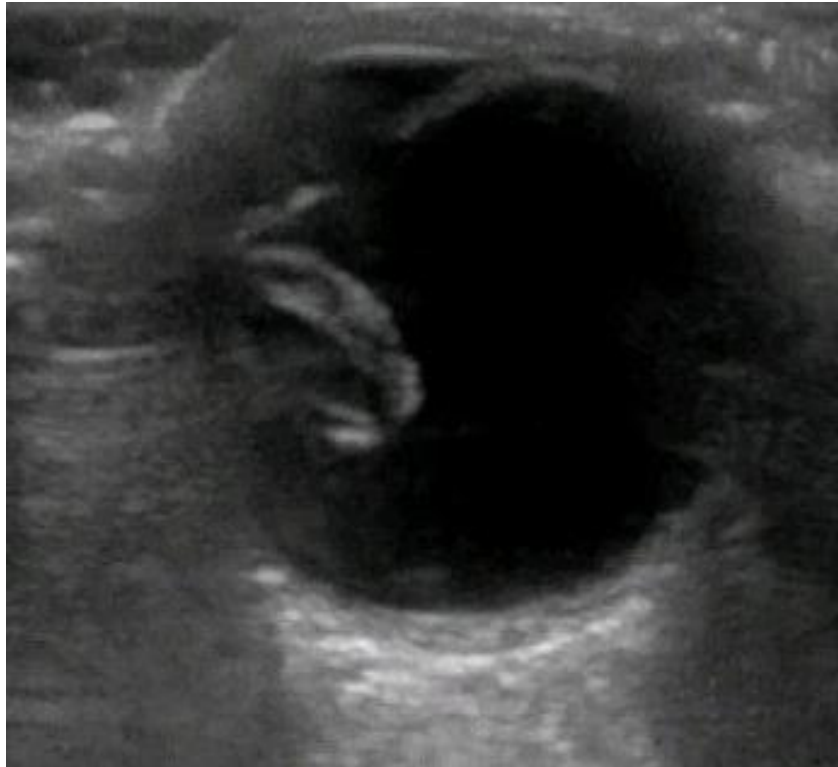

Fig 11: Dislocated lens in the vitreous cavity on B scan.

In this study, there were total 11 cases of intraocular foreign body and dislocated lens who had a history of trauma were diagnosed with an accuracy of 100 %. B scan was found to be an effective imaging modality in the detecting the foreign body and its exact location. But B scan was unable to reveal certain important findings in an orbital trauma such as fractures of orbital bones which are seen on the cross-sectional imaging like CT scan.

In this study we have one case of the hyphema, the patient had a history of blunt trauma to the orbit.(2)

It is the commonest tumor of the eye in paediatric age group. The case described below is of a 2.5 years old female child.

USG shows echogenic lesion and calcium deposits with optic nerve involvement beyond the point of surgical resection (associated with a 65% mortality rate). ultrasonic heterogeneous soft tissue mass is seen adjacent to coats of the eyeball with specks of calcification producing acoustic shadowing, thickening of anterior part of the optic nerve. On CDI mass shows vascularity.(17)

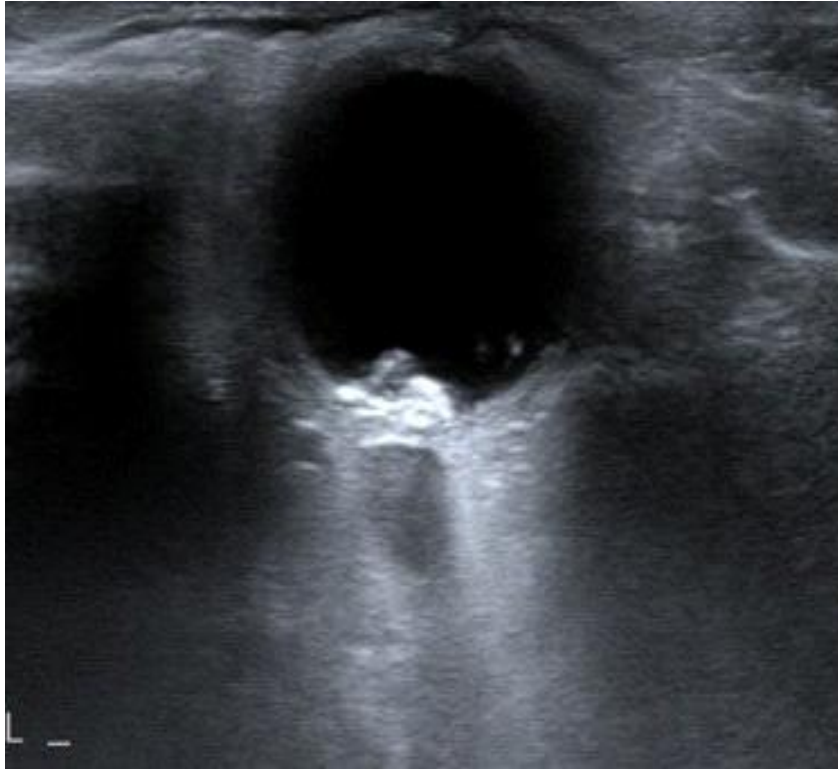

Fig 12: Mass lesion near the optic disc – retinoblastoma




Fig 13: Mass lesion occupying the posterior segment of eye - retinoblastoma.

In this study, there was one case of choroidal melanoma. Patient was 56 years old. She presented with sudden unilateral diminution of vision.

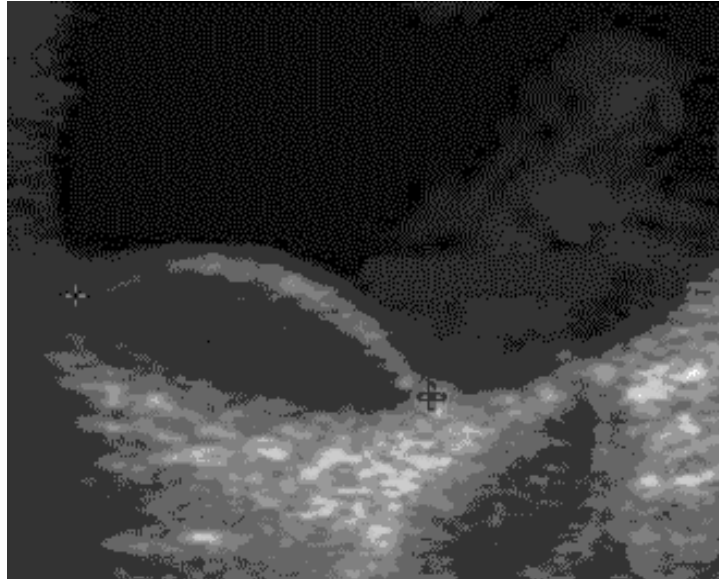


Fig 14 : Oval hypoechoic mass lesion arising from the choroid a choroidal melanoma

In this study, total 6 cases of ocular tumors were diagnosed. 5 cases of retinoblastoma in paediatric age group and 1 case of choroid melanoma in an adult patient. All cases were diagnosed accurately with a sensitivity of 100% and specificity of 100%. However intracranial extension could not be diagnosed on the B scan.

Graves' disease usually predominantly affects female patients. Development of thyroid ophthalmopathy is one of the common complications. In our study, we have 8 such cases.

Asymmetrical involvement with medial rectus being the most common extraocular muscle involvement with predominant enlargement of the belly of the muscle with loss of normal well-defined outline. The inferior and medial rectus muscle are most commonly involved followed by superior rectus muscle. It is the most common cause of proptosis in our study. On CDI it shows increased vascularity.(17)

Total 8 cases were diagnosed with thyroid ophthalmopathy, the diagnostic accuracy of 100% of B scan, the sensitivity of 100% and specificity of 100%

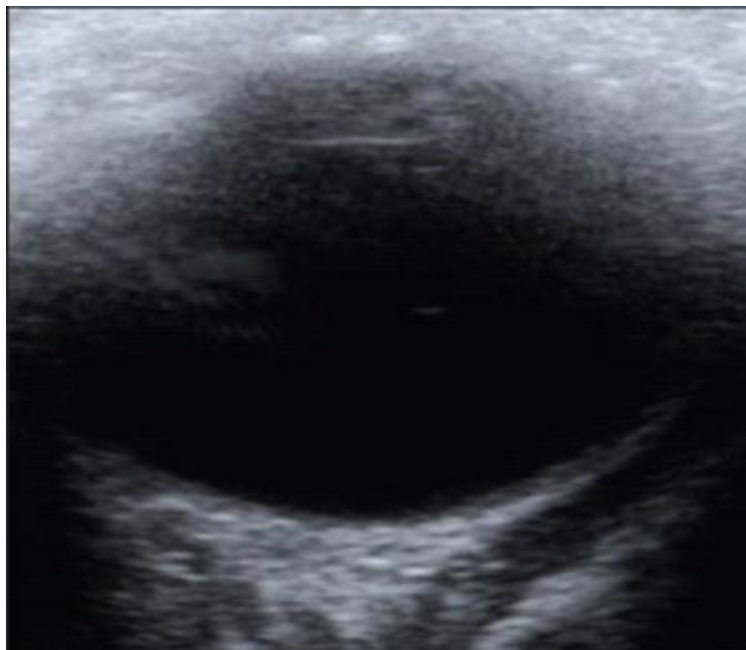


Fig 15: Thickened extraocular muscle -thyroid ophthalmopathy.

Choroidal detachment is separation of the choroid from the sclera resulting from accumulation of fluid or blood in the potential space below the choroid layer. Two cases were found in our study. In one case, two opposite echogenic convex lines could be seen extending into the vitreous cavity. These echogenic lines did not

involve the optic nerve head. One case was associated with history of trauma and second case was spontaneous choroidal detachment, a echogenic thick convex membrane was seen in temporal field extending anteriorly to the level of ora serrata.

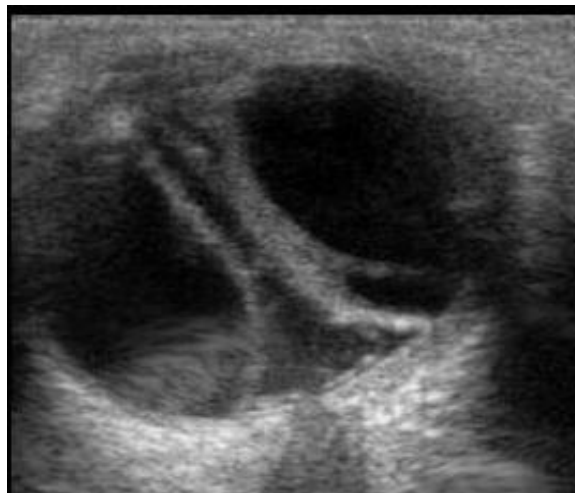


Fig 16 :Choroidal detachment with thick membranes and sub choroidal fluid

Ocular Cysticercosis is a parasitic infestation caused by *Cysticercus cellulose*, which is the larval form of *Taenia Solium*. We have one case with ocular cysticercosis.

On B-scan ocular ultrasonography, a well-defined cyst with a hyper echogenic scolex is seen in the posterior segment of the eye in the vitreous cavity. MRI reveals a hypointense cystic lesion and hyperintense scolex within the posterior segment of the eye. Patient was also a known case of Neurocysticercosis.(14)

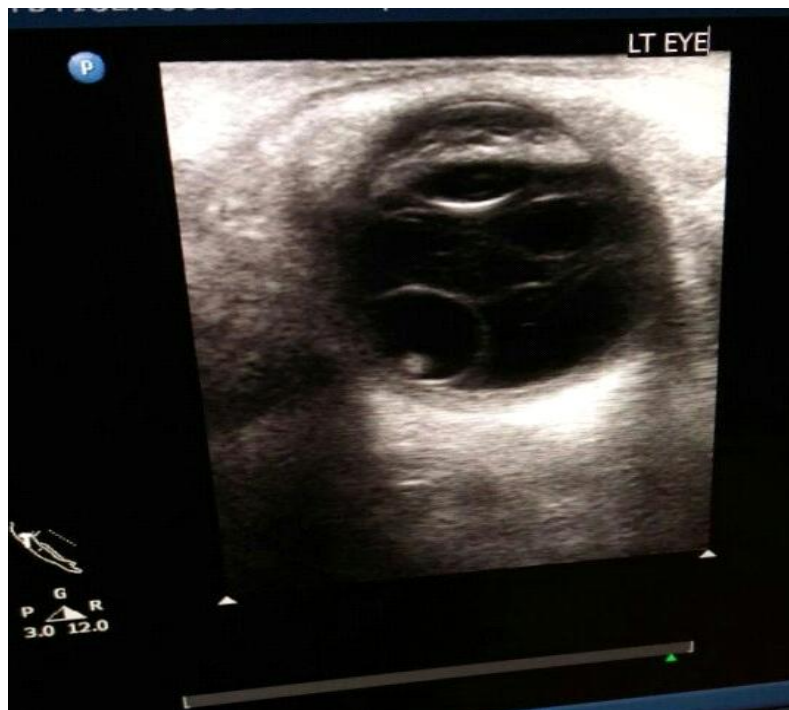

Fig 17 :Cystic lesion in the vitreous cavity with scolex within- ocular cysticercosis.

Pthisisbulbi is a end result of trauma to the eye. Patient presented with a shrunken end-stage eye that was small and distorted and had diminished axial length. The chorioretinal layers had become thickened. Hyperechoic material in the vitreous chamber is representative of old inflammation or infection, fibrosis, or mineralization.(5)

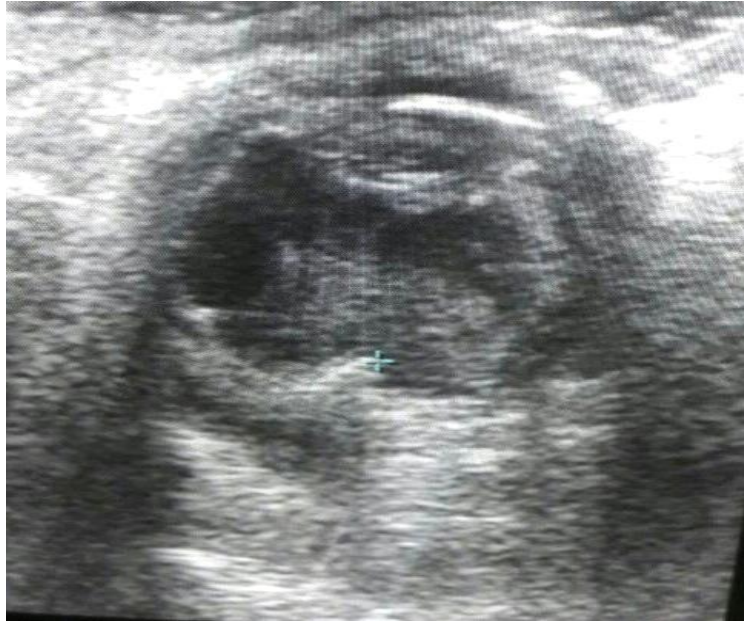

Fig 18 :Shrunken collapsed globe – phthisis bulbi

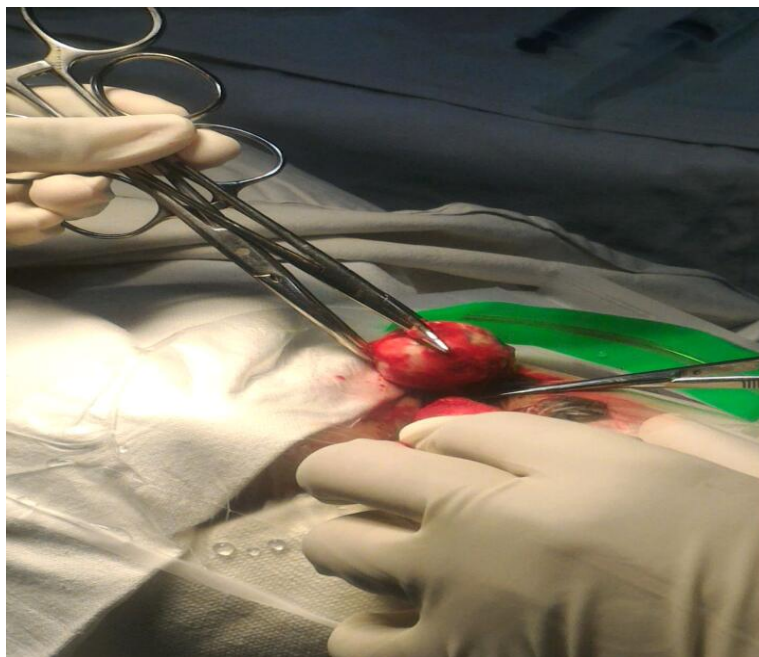


Fig 19: Patient with phthisis bulbi undergoing enucleation

We had total 9 cases of the corneal pathologies, 2 cases of corneal dystrophy, 3 fungal corneal infections, 2 cases of bacterial corneal infection, 2 cases of fungal corneal ulcer in all patients with corneal pathology B scan was normal, the diagnosis was confirmed on microscopy and culture and clinical findings. Basically, all patients were advised B scan to rule out the posterior segment pathologies as indirect ophthalmoscopy was not possible. B scan is not of any value in diagnosing anterior chamber pathologies but it is a very sensitive and accurate technique in diagnosing posterior segment pathologies.

VI. Summary

In this study, 144 patients underwent B scan for diagnosing various pathologies of the orbit. Orbital pathologies were more common in the adult age group with a mean age of 42.5 years. It was more common in the male patients with a ratio of 3:2(M:F).

The most common complaint of the patients was a diminution of the vision (35.4%) followed by trauma (26.4%) and least common was lid swelling (1.4%).

Opaque media was the most common indication for the B scan which included corneal pathologies, lens opacification, anterior chamber opacification with blood or pus and posterior segment pathologies like vitreous degeneration, vitreous hemorrhage. The opacification of the lens and vitreous opacities are common causes.

Left orbit (52.1%) was involved more commonly than the right orbit (16). Involvement of both eyes noted in the 13.9 % of the cases.

We were able to distinguish extraocular and intraocular pathologies with B scan with 100% sensitivity (16 cases of the extraocular and 119 intraocular pathologies).

Out of 119 cases of intraocular pathologies, vitreous hemorrhage is the commonest pathology followed by the retinal detachment. diagnostic accuracy of B scan in vitreous pathologies 98.6 % with sensitivity of 100% and specificity of 97.92%. In cases of retinal detachment, B scan is 96.2 sensitive with an accuracy of 99.3%.

There were total 25 cases of extraocular pathologies, thyroid ophthalmopathy was the commonest extraocular pathology (32%) followed by a pseudo tumor. 34% of patients who presented with proptosis had thyroid ophthalmopathy and 30 % of patients had pseudo tumor. Diagnostic accuracy of 100 %, sensitivity 100 % and specificity 100% was seen in case of extraocular pathologies.

B scan was normal in 9 cases, these cases had opaque media (corneal opacity), B scan was performed to rule out posterior segment pathologies. Color Doppler was used simultaneously in all cases to see the vascularity of the different pathologies. color Doppler imaging was very effective in the detection of the vascular lesions of the orbit like lid hemangioma, thyroid ophthalmopathy, retinal detachment and ocular tumors like retinoblastoma and melanoma.

Out of 32 patients with history of trauma, vitreous hemorrhage (39.47%) was the commonest finding in trauma followed by retinal detachment.

B-scan shows 100% accuracy in diagnosis & characterization of lacrimal gland tumors & optic nerve tumors. B scan is 100% accurate in diagnosing extraocular pathologies like mucocele, metastatic deposit but it is not able to detect extra-orbital extension of the metastatic deposit.

There is 100% accuracy of the B-scan in diagnosing intraocular tumors retinoblastoma is most common in pediatric age and melanoma in the adult population.. B scan of the orbit has limited value in assessing orbital masses with intracranial extension and involvement of the bones. Cross sectional imaging CT scan and MRI are better in diagnosing intracranial extension and involvement of bone.

VII. Conclusion

Ultrasonography of the orbit is not difficult to perform. Knowledge of ultrasound anatomy and scanning technique is mandatory for its proper usage. B scan of the orbit is useful in ocular and extraocular examinations and depicts multiple conditions such as inflammatory conditions, tumors, and in some cases, traumatic lesions.

B- scan is a quick technique and allows fast evaluation of orbit and it provides valuable information in the short time. B-scan with dynamic imaging technique gives us real time images of lesions and with respect to the ocular movements.

B scan is cost-effective and non-invasive imaging modality and best tool for follow up of many ocular pathologies. It is free of ionizing radiation and requires no contrast agents as required in the cross sectional imaging techniques like CT and MRI.

It is a sensitive and accurate diagnostic technique for vitreoretinal pathologies, ocular neoplasms like retinoblastoma, melanoma and patients with trauma.

B scan is accurate in detecting and localizing foreign bodies. It plays a key role in emergency conditions and for management of ocular trauma. CDI is an important part of the evaluation of the various ocular pathologies like retinal detachment, vascular lesions like hemangioma, lymphangioma.

It is a very effective imaging modality in conditions with opaque media where indirect ophthalmoscopy is not possible for pathologies of the posterior segment of the globe

Acknowledgement

The authors express their gratitude and indebtedness to the Department of Radiology, Seth G.S Medical College and KEM Hospital for providing necessary infrastructure and resources to accomplish this research work. The authors also express respect and gratitude to Dr. Hemant L.Deshmukh, Professor and Head, Department of Radiology, Seth G.S Medical College, KEM Hospital, Mumbai for providing valuable suggestion regarding this study. The authors are truly indebted to their colleagues, seniors and juniors for their support, valuable guidance, encouragement and help through the duration of the study. Finally, the authors are thankful to patients without whose help it would not have been possible to complete this study.

References

- [1]. The History of Ultrasound | BMUS [Internet]. [cited 2018 Feb 3]. Available from: <https://www.bmus.org/about-ultrasound/history-of-ultrasound/>
- [2]. Bedi DG, Gombos DS, Ng CS, Singh S. Sonography of the Eye. 2006;(October):1061–72. 5. Hulley SB, Cummings SR, Browner WS, Grady D NT. Designing Clinical Research [Internet]. [cited 2018 Apr 1]. Available from: <https://shop.lww.com/Designing-Clinical-Research/p/9781608318049>
- [3]. Sadler TW (Thomas W., Langman J. Langman’s medical embryology. [Internet]. Wolters Kluwer Health/Lippincott Williams & Wilkins; 2012 [cited 2018 Feb 4]. 384 p.
- [4]. Dudea SM. Ultrasonography of the eye and orbit. 2011;13(2):171–4.
- [5]. Lorente-Ramos RM, Armán JA, Muñoz-Hernández A, Gómez JMG, de la Torre SB. US of the Eye Made Easy: A Comprehensive How-to Review with Ophthalmoscopic Correlation. RadioGraphics [Internet]. 2012 Sep [cited 2018 Apr 2];32(5):E175–200. Available from: <http://pubs.rsna.org/doi/10.1148/rg.325115105>
- [6]. Marchini G, Pagliaruso A, Tosi R, Castagna G. Ultrasonographic findings in endophthalmitis. Acta Ophthalmol Scand [Internet]. 1995 Oct [cited 2018 Apr 1];73(5):446–9. Available from: <http://www.ncbi.nlm.nih.gov/pubmed/8751126>
- [7]. Finger PT, Khoobehi A, Rocca D Della, Jr JPSG. Three dimensional ultrasound of retinoblastoma: initial experience. 2002;1136–9.
- [8]. Singh AD. Essentials of ophthalmic oncology. SLACK; 2009. 258 p.
- [9]. Shields JA, Shields CL, Shields JA, Shields JA. Eyelid, conjunctival, and orbital tumors : atlas and textbook [Internet]. Lippincott Williams & Wilkins; 2008 [cited 2018 Apr 1]. 805 p.
- [10]. Britto FCC de, Rosier VV, Luz TV, Verde RCL, Lima CMF de, Lessa MM. Nasolacrimal duct mucocele: case report and literature review. Int Arch Otorhinolaryngol [Internet]. 2015 Jan [cited 2018 Apr 1];19(1):96–8. Available from: <http://www.ncbi.nlm.nih.gov/pubmed/25992160>
- [11]. Smoker WRK, Gentry LR, Yee NK, Reede DL, Nerad JA. Vascular Lesions of the Orbit: More than Meets the Eye. RadioGraphics [Internet]. 2008 Jan [cited 2018 Apr 1];28(1):185–204. Available from: <http://www.ncbi.nlm.nih.gov/pubmed/18203938>
- [12]. Kerlen CH. B-scan ultrasonography in optic nerve lesions. Doc Ophthalmol [Internet]. 1982 Jan 29 [cited 2018 Apr 1];52(3–4):317–25. Available from: <http://www.ncbi.nlm.nih.gov/pubmed/7067599>
- [13]. Ojaghi Haghghi SH, Morteza Begi HR, Sorkhabi R, Tarzamani MK, Kamali Zonouz G, Mikaeilpour A, et al. Diagnostic Accuracy of Ultrasound in Detection of Traumatic Lens Dislocation. Emerg (Tehran, Iran) [Internet]. 2014 [cited 2018 Feb 6];2(3):121–4. Available from: <http://www.ncbi.nlm.nih.gov/pubmed/26495362>
- [14]. Dhiman R, Devi S, Duraipandi K, Chandra P, Vanathi M, Tandon R, et al. Cysticercosis of the eye. Int J Ophthalmol [Internet]. 2017 [cited 2018 Apr 2];10(8):1319–24. Available from: <http://www.ncbi.nlm.nih.gov/pubmed/28861361>
- [15]. Parchand S, Singh R, Bhalekar S. Reliability of Ocular Ultrasonography Findings for Pre-surgical Evaluation in Various Vitreoretinal Disorders. Semin Ophthalmol [Internet]. 2014 Jul 10 [cited 2018 Feb 6];29(4):236–41. Available from: <http://www.ncbi.nlm.nih.gov/pubmed/24409949>
- [16]. Restori M, McLeod D, Wright JE. Diagnostic ultrasound in ophthalmology. J R Soc Med [Internet]. 1980 Apr [cited 2018 Feb 4];73(4):273–8. Available from: <http://www.ncbi.nlm.nih.gov/pubmed/7241443>
- [17]. Chaudhari HD, Thakkar GN, Gandhi VS, Darji PJ. Role of ultrasonography in evaluation of orbital lesions . 2013;68(22).

Dr. Padma Badhe. “B Scan of Orbit with Its Clinico-Surgical Correlation.” IOSR Journal of Dental and Medical Sciences (IOSR-JDMS), vol. 18, no. 1, 2019, pp01-16.