

## Evaluation of Breast Architecture and Mass Morphology in Digital Mammography using BIRADS

Mayson .M. Wansi<sup>1</sup>, Caroline Edward Ayad<sup>1</sup>  
Doha Abdo Mohammed Abdo<sup>1</sup>

<sup>1</sup>(College Of Medical Radiological Science/ Sudan University of Science and Technology Khartoum –Sudan)  
Corresponding Author: Mayson .M. Wansi

---

**Abstract:** Breast architectural distortion is an abnormal arrangement of tissue strands and happened linearly as an indicator of breast cancer and conceivably it has a benign cause also. This prospective analytic cross section study was to evaluate and correlate between breast architecture and mass morphology using Breast Imaging Reporting and Data System (BI-RADS). The study was conducted during the period from 2015 to 2018. 300 mammograms of ladies aged between 15 and 90 were evaluated. The research results showed that the architectural distortion was present in 117 of 300 (39%), and absence in 171 of 300 (57%). The architectural distortion and mass shape was correlated significantly at P-value = (0.000), the presence of architectural distortion was associated with irregular mass, whereas the absence of architectural distortion was associated with oval shape masses. The architectural distortion was associated significantly with speculated mass margin at P-value of (0.000) was found in 48 /102 cases. The relation between the architectural distortion and pathological outcomes using BIRADS was also been evaluated: 84/117 cases of distorted architecture were of BIRAD 4 (suspicious malignancy) and 54 of the cases were of BIRAD 1 with no presence of architectural distortion. Finally the study showed that there is association between architectural distortion and the features of mass morphology as well as the masses which were suspicious or highly suggestive to be malignant

**Keywords:** BIRAD, Distortion, Breast, Malignant masses

---

Date of Submission: 05-01-2019

Date of acceptance: 21-01-2019

---

### I. Introduction

The breast parenchymal pattern consists of thin, curvilinear lines that directed toward the nipple. This radiating pattern broken only by blood vessels. (Sickles, EA, D'Orsi CJ, Bassett LW, 2013). Architectural distortion defined as linear alterations of breast parenchyma pulled into a central focus, without a definite visible mass, resulting in radiating spiculations or thin lines pointing toward the center, like a star. (Ikeda and Miyake, 2016) Also defined as Appearance in which the normal architecture of the breast is altered by an invisible mass. (M.Á. *et al.*, 2016). The Architectural distortion can be due to malignant lesions, such as invasive cancer or ductal carcinoma in situ (DCIS), or to benign lesions, such as a radial scar or complex sclerosing lesion. (Bahl *et al.*, 2015) AD is the third mammographic manifestation of non-palpable breast cancer and is the most commonly undiagnosed anomaly in mammography, being the cause of false negatives. (Durand *et al.*, 2016) The Architectural distortion representing nearly 6% of abnormalities detected on screening mammography. (Gaur *et al.*, 2013) The suspicion of malignancy in an AD increases if it is associated with a mass. (M.Á. *et al.*, 2016). Architectural distortions appear as speculation, retraction, and distortion. Although most architectural distortions must be considered to represent cancer. (Ichikawa *et al.*, 2004)

The contour of the mass is the most discriminating morphological feature between benign and malignant. (Berment *et al.*, 2014) Characterization of lesion margin is also very important, as spiculated margins are highly suggestive of malignancy. (Mohindra *et al.*, 2018). The most significant features indicating whether the tumor is malignant or benign are its shape and the nature of its margins. (Ciecholewski, 2017) Architectural Distortion is a classical presenting appearance for infiltrating lobular carcinoma as 16% to 20%, and intra-ductal carcinoma represented 17%. (Boyer and Russ, 2014) Researchers used different methods to detect architectural distortion due to the relation between it and cancer. (Anand and Rathana, 2013), (Baeg and Kehtarnavaz, 2002). The current study aimed to evaluate the breast architecture and mass morphology in Digital Mammography using BIRADS as well to determine the risk of malignancy or suspicious lesions associated with architectural distortion and to evaluate the imaging features that may contribute to the prediction of malignancy in the setting of architectural distortion. The information from this study can be used to counsel patients and inform clinicians about expected pathologic outcomes.

## II. Materials and Methods

The study was prospective cross section study for 300 mammograms of women aged between 15 and 90 years old; all mammograms were reviewed by more than 2 radiologists and reported using BIRADS Lexicons. Two basic projections of mammography (Crano- Caudal(CC) and Mediolateral(MLO) were adopted.

The purpose of the study was to evaluate breast architectural distortion and to determine the relationship between it and mass morphology, so that the data collected according to presence of the mass and architectural distortion as the following:

### Criteria for Characterizing the Mass:

The term mass selected by the radiologist when found a 3D occupying space lesion and described the mass morphology (Shape, Margin) according to its shape either Oval, round or irregular. The researcher added a fourth descriptive term found in the reports as "lobulated". Moreover, the margin of the mass was described Circumscribed or (Well defined, Sharp), Obscured (Partially well defined), Microlobulated, Indistinct (ill defined), Speculated, or Irregular.

### Architectural Distortion:

It identified when the parenchyma is distorted with or with no definite mass visible. Each mammogram had finally different BIRADS category. As (0 incomplete, 1 Normal finding, 2 Benign, 3 probably benign, 4 Suspicious Malignancy and Highly suggestive Malignancy). Statistical analyses were performed using statistics program (SPSS version 10) to maintained accurate analysis and results. Statistical significance was determined with the chi-square test for category variables. The researcher found the correlation between the Mass morphology, Architectural distortion and final findings.

## III. Results

**Table 1: Distribution of samples according to architectural distortion**

Architectural distortion	Frequency	Percent
Distorted	117	39
Normal architecture	171	57
undefined	12	4
Total	300	100

**Table 2: Distribution of samples according to presence of breast mass**

Breast Mass	Frequency	Percent
Present	186	62.0
Absent	102	34.0
Undefined	12	4.0
Total	300	100.0

**Table 3: Correlation of architectural distortion with mass shape**

	Distribution of mass shape				Total
	Oval	Round	Irregular	Lobulated	
Yes	21	18	60	3	102
No	48	27	6	3	84
Total	69	45	66	6	186

(Using chi-square test, P-value = 0.000)

**Table 4: Correlation of architectural distortion with mass margin**

Architectural distortion	Distribution of mass margin						Total
	Circumscribed (Well defined, Sharp)	Obscured (Partially well defined)	Micro-lobulated	Indistinct (Ill defined)	Speculated	Irregular	
Yes	0	15	9	21	48	9	102
No	45	6	18	12	0	3	84
Total	45	21	27	33	48	12	186

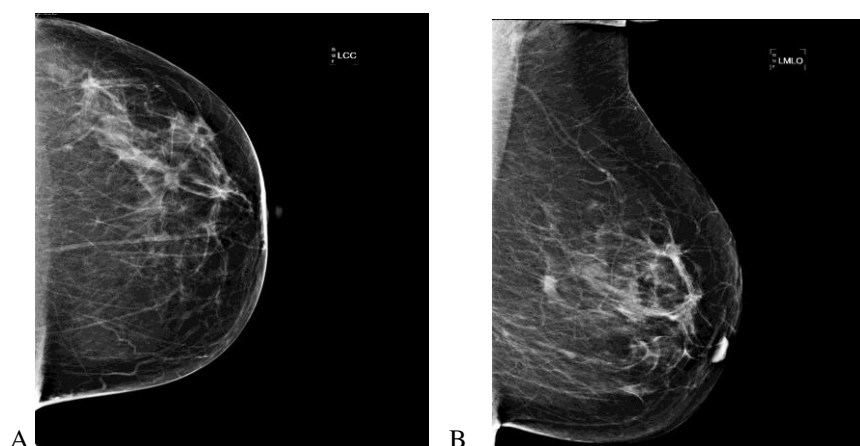
Using chi-square test, P-value = 0.000

**(Table 5) Correlation of architectural distortion with pathological outcomes.**

Pathological Outcomes	Count	Distribution of architectural distortion		Total
		Yes	No	
Negative (Normal finding)		0	54	54
	% within Distribution of pathological outcomes	0.0%	100.0%	100.0%

Benign	Count	0	33	33
BIRAD 2	% within Distribution of <b>pathological outcomes</b>	0.0%	100.0%	100.0%
Probably benign BIRAD3	Count	3	33	36
	% within Distribution of <b>pathological outcomes</b>	8.3%	91.7%	100.0%
Suspicious malignancy	Count	84	48	132
BIRAD 4	% within Distribution of <b>pathological outcomes</b>	63.6%	36.4%	100.0%
Highly suggestive malignancy	Count	30	3	33
BIRAD 5	% within Distribution of <b>pathological outcomes</b>	90.9%	9.1%	100.0%
Total	Count	117	171	288
	% within Distribution of <b>pathological outcomes</b>	40.6%	59.4%	100.0%

(Using chi-square test, P-value = 0.001)



**Figure 1:** Cranio Caudal (CC) view of the left breast, show that multiple masses with architectural distortion associated with mass. B- Mediolateral (MLO) view of the left breast for the same patient, show that presence of architectural distortion.

#### IV. Discussion

The research showed that the architectural distortion was present in 117 of 300 (39%), and absent in 171 of 300 (57%) and also the breast masses were found in 186 cases and distorted with absence of masses in 102 (34%) cases as shown in tables (1 and 2) that means that the distortion happened in most of the cases that detected to be affected with mass. This was consistent with one of the most valuable published studies which informed that the architectural distortion is defined by the Breast Imaging Reporting and Data System (BIRADS) system as an appearance in which “the normal architecture of the breast is distorted with no definite mass visible. (Shantanu Gaur et al 2013) The distortion happened because of the spiculations radiating from a point and focal retraction or distortion at the edge of the parenchyma. Our study showed that architectural distortion also be an associated findings with benign causes of architectural distortion.

Table 3 showed the correlation of architectural distortion with mass shape and presented as, the oval shape was 21 of 102 associated with presence of architectural distortion, whereas the irregular shape was 60 of 102 associated with presence of architectural distortion.

Table 4 showed the correlation between architectural distortion and mass margin. The higher numbers of cases associated with architectural distortion were those of speculated mass margin 48 of 102.

The correlation was done in the cases affected with mass and determined whether architectural distortion presented or not. Therefore, the total cases taken were 186 mammograms

When characterizing the mass as Circumscribed: it was considered to be well defined, sharply demarcated with an abrupt transition between the lesion and the surrounding tissue. In some cases where part of the margin is obscured, it was defined for as circumscribed. A mass for which any portion of the margin is indistinct, microlobulated, or speculated was classified on the basis to be of suspicious component. This was clearly found in table(4) where 15 cases were obscured and partially well defined with the presence of distorted background. Micro-lobulated was found in both cases with and without distorted architecture. The margin is characterized by short cycle undulations. References have mentioned this criterion in mammography, and used this descriptor when implies a suspicious findings (Car. J.2012). The Indistinct (“ill defined”) description was applied when there is no clear demarcation of the entire margin, or of any portion of the margin, from the surrounding tissue. This was recommended to be used to implies a suspicious finding.(Carl J.2012) This was found in 21, and 12 cases with and without architecture distortion respectively. The margin was characterized by lines radiating from the mass in the speculated character. 48 cases were described as speculated margin which was associated with distortion, this descriptor implies the suspicious finding also the masses with irregular margins as mentioned by( Carl. J.2012)

The correlation of architectural distortion with mass shape was : the oval shape was 21 of 102, 18 for round shape and 3 for lobulated shape associated with presence of architectural distortion, whereas the irregular shapes were 60 of 102 associated with presence of architectural distortion , that consider statistically significant at P-value = (0.000). The result proved that the architectural distortion goes with the irregular shape more than round or oval shapes .This was consistent with what was mentioned with (Shantanu Gaur et al 2013) who stated that although an irregular mass or calcification is the most common mammographic appearance of invasive cancer, architectural distortion is generally considered the third most frequent and sometimes the only presenting finding. And a speculated mass or architectural distortion was the most common radiographic findings.

In addition our study showed that, the correlation between architectural distortion and mass margin found that the higher number of cases associated significantly at P-value = (0.000) with architectural distortion were those of speculated margin 48 of 102. The result goes with the nature of architectural distortion as linear alterations in the breast parenchyma, so that speculation margin lead to linear or appear as linear deformity, according to nature of the tumor, that almost malignant as mentioned by (Shi *et al.*, 2007).

Table( 5) showed the correlation between the architectural distortion and pathological outcomes using BIRADS it presented that 84 of 117 were BIRAD 4 (suspicious malignancy)and were associated with presence of architectural distortion, and 54 of the cases were BIRAD 1 with no presence of architectural distortion it was correlated significantly at P-value = (0.001).That goes with previous studies (Bahl, M. *et al.*.2015) that showed that 75% of all mammography cases represent breast malignancy associated with architectural distortion. Moreover (M.Á., P. T. *et al.* .2016) in their study, have mentioned that 44.23% of the architectural distortion were corresponded to cancers.

## V. Conclusion

The study showed that both malignant and nonmalignant pathologic masses were associated with architectural distortion. The probably benign masses BIRAD3 , the suspicious malignancy BIRAD 4 and the highly suggestive malignancy BIRAD 5 were all can be presented with distorted back ground architecture. Many limitations facing the researcher in the current study; is that the dependency upon the architectural distortion alone may be one of the highest levels of inter-observer variability among mammographic findings as mentioned by previous researchers (Baker JA et al 1996, Onega T et al 2013, Onega T et al 2012) and should be accompanied with other additional imaging methods beside the mammography. In Some cases there are difficulties in diagnosing the speculated masses because their characters appeared as architectural distortion .The study recommended to apply additional imaging method and have mentioned that the the evaluation of the breast considering the architectural distortion alone is not quit enough and less likely to represent malignancy on mammography if there is no other imaging method to be correlated with the mammographic findings. This information can be used to counsel patients about expected pathologic outcomes

## Acknowledgements

We sincerely thank the participants without whom the study would not have been feasible. The Sudan University of Science and Technology, College of Medical Radiological Science and Radiology Department- in which the study was obtained, are thankfully acknowledged.

## References

- [1]. Anand, S. and Rathana, R. A. V (2013) 'Architectural Distortion Detection in Mammogram using Contourlet Transform and Texture Features', *International Journal of Computer Applications*, 74(5), pp. 12–19.
- [2]. Baeg, S. and Kehtarnavaz, N. (2002) 'Classification of breast mass abnormalities using denseness and architectural distortion', *ELCVIA Electronic Letters on Computer Vision and Image Analysis*, 1(1), pp. 1–20.
- [3]. Bahl, M. *et al.* (2015) 'Architectural Distortion on Mammography: Correlation with Pathologic Outcomes and Predictors of Malignancy', *American Journal of Roentgenology*, 205(6), pp. 1339–1345. doi: 10.2214/AJR.15.14628.
- [4]. Berment, H. *et al.* (2014) 'Masses in mammography: What are the underlying anatomopathological lesions?', *Diagnostic and Interventional Imaging*. Elsevier Masson SAS, 95(2), pp. 124–133. doi: 10.1016/j.diii.2013.12.010.
- [5]. Boyer, B. and Russ, E. (2014) 'Anatomical-radiological correlations: Architectural distortions', *Diagnostic and Interventional Imaging*. Elsevier Masson SAS, 95(2), pp. 134–140. doi: 10.1016/j.diii.2014.01.003.
- [6]. Ciecholewski, M. (2017) 'Malignant and benign mass segmentation in mammograms using active contour methods', *Symmetry*, 9(11). doi: 10.3390/sym9110277.
- [7]. Durand, M. A. *et al.* (2016) 'Tomosynthesis-detected architectural distortion: management algorithm with radiologic-pathologic correlation', *Radiographics*. Radiological Society of North America, 36(2), pp. 311–321.
- [8]. Gaur, S. *et al.* (2013) 'Architectural distortion of the breast', *American Journal of Roentgenology*, 201(5), pp. 662–670. doi: 10.2214/AJR.12.10153.
- [9]. Ichikawa, T. *et al.* (2004) 'Automated detection method for architectural distortion areas on mammograms based on morphological processing and surface analysis', 5370, p. 920. doi: 10.1117/12.535116.
- [10]. Ikeda, D. and Miyake, K. K. (2016) *Breast Imaging: The Requisites E-Book*. Elsevier Health Sciences.

- [11]. Miguel Ángel Pinochet T, Aleen Vanessa Altamirano S, Eleonora Horvath P, Marcela Uchida S, Claudio Silva F-A, Carla Darrás I. (2016) 'Distorsion of breast architecture: The best way to confront it', *Revista Chilena de Radiología*, 22(4), pp. 158–163. doi: 10.1016/j.rchira.2016.11.007.
- [12]. Mohindra, N. *et al.* (2018) 'Impact of addition of digital breast tomosynthesis to digital mammography in lesion characterization in breast cancer patients', *International Journal of Applied and Basic Medical Research*. Wolters Kluwer--Medknow Publications, 8(1), p. 33.
- [13]. Shi, J. *et al.* (2007) 'Characterization of mammographic masses based on level set segmentation with new image features and patient information', *Medical Physics*, 35(1), pp. 280–290. doi: 10.1118/1.2820630.
- [14]. Sickles, EA, D'Orsi CJ, Bassett LW, *et al.* (2002) *ACR BI-RADS® Atlas, Breast Imaging Reporting and Data System*.
- [15]. Shantanu Gaur, Vandana Dialani, Priscilla J. Slanetz, Ronald L. Eisenberg, (2013) Architectural Distortion of the Breast *AJR*; 201:W662–W670
- [16]. Carl J. D'Orsi, Edward A. Sickles, Ellen B. Mendelson, Elizabeth A. Morris, 2013 *ACR BI-RADS Atlas Breast Imaging Reporting and Data System*
- [17]. Baker JA, Kornguth PJ, Floyd CE Jr. Breast Imaging Reporting and Data System standardized mammography lexicon: observer variability in lesion description. *AJR* 1996; 166:773–778
- [18]. Onega T, Anderson ML, Miglioretti DL, *et al.* Establishing a gold standard for test sets: variation
- [19]. in interpretive agreement of expert mammographers. *Acad Radiol* 2013; 20:731–739
- [20]. Onega T, Smith M, Miglioretti DL, *et al.* Radiologist agreement for mammographic recall by case difficulty and finding type. *J Am Coll Radiol* 2012; 9:788–794

Mayson .M. Wansi, "Evaluation of Breast Architecture and Mass Morphology in Digital Mammography using BIRADS." *IOSR Journal of Dental and Medical Sciences (IOSR-JDMS)*, vol. 18, no. 1, 2019, pp 75-79.