

## Verrucous Carcinoma of Oral Region: Case Series and Mini Review.

<sup>1</sup>Dr. Lasya Borra, <sup>2</sup>Dr. Paul Mathai, <sup>3</sup>Dr. Bharti Wasan, <sup>4</sup>Dr. Muqthadir Siddiqui  
Mohammad Abdul, <sup>5</sup>Dr. Alen Pius, <sup>6</sup>Dr. Mariea Francis, <sup>7</sup>Dr. Rahul VC Tiwari

<sup>1</sup>BDS, Intern, Sibar Institute of Dental Sciences, Guntur, NTRUHS, Andhra Pradesh.

<sup>2</sup>FOGS, MDS, OMFS & Dentistry, JMMCH & RI, Thrissur, Kerala, India.

<sup>3</sup>MDS, OMFS, Senior Lecturer, Guru Nanak Dev Dental College & Research Institute, Sunam, Punjab.

<sup>4</sup>Registrar, Pediatric Dentistry, Ministry of Health, King Khaled Hospital, Riyadh, KSA.

<sup>5</sup>Assistant Professor, Dept. of Conservative Dentistry & Endodontics, PSM Dental College, Akkikavu, Thrissur, Kerala.

<sup>6</sup>PG Student, OMFS, KVG Dental College and Hospital, Sullia, DK, Karnataka, India.

<sup>7</sup>FOGS, MDS, OMFS, Consultant & Private Practitioner, Kondagaon, Chhattisgarh.

Corresponding Author: Dr. Lasya Borra

**Abstract:** Oral Verrucous Carcinoma [OVC] is described as a part of the Squamous Cell Carcinoma [SCC] due to its specific properties. Verrucous carcinoma is a form of squamous cell carcinoma with specific clinical, morphologic, and cytogenetic features. The term verrucous carcinoma refers to those exophytic squamous mucosal or cutaneous tumors that are heaped above the epithelial surface with a papillary micronodular appearance. Verrucous carcinoma is distinguished by controversy regarding appropriate diagnosis and treatment. In this paper, 3 cases of verrucous carcinoma of tongue, retromolar trigone region and maxillary vestibular region are reported and a mini review of literature is described.

Date of Submission: 01-01-2019

Date of acceptance: 15-01-2019

### I. Introduction

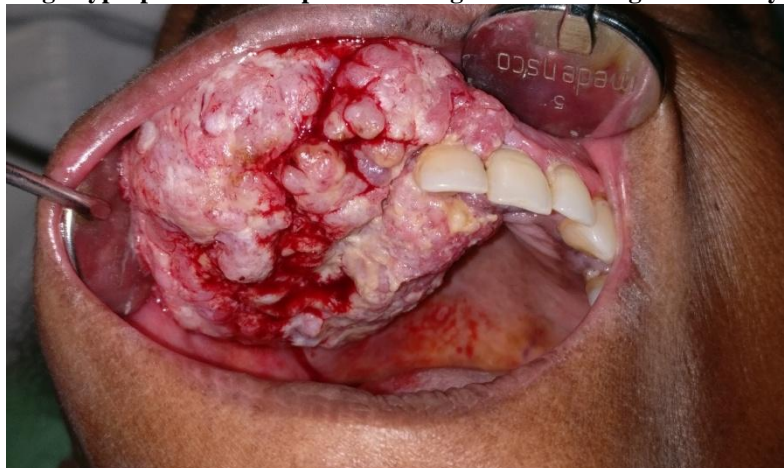Verrucous-type lesions are quite common in the oral region, representing 3% of all the biopsied oral lesions. They are characterized by a unique proliferation of the stratified squamous epithelium.[1] The lesions included in this spectrum ranges from benign lesions like papilloma, premalignant lesions like verrucous hyperplasia [VH] to malignant verrucous carcinoma [VC].[2] Most of them are clinically benign, but they are removed and subjected to microscopic evaluation for ruling out early malignancy.[1] VC and VH are clinically indistinct but can be differentiated based on careful gross and microscopic correlation.[1] VC is a diffuse, largely exophytic, superficial spreading highly keratinized warty form of well-differentiated squamous cell carcinoma [SCC] that is unlikely to metastasize.[3] It occurs commonly in elderly male and can be quite extensive at the time of presentation. It occurs at various extraoral sites such as larynx, vagina, rectal mucosae and skin from the breast, axilla, ear canal, and soles of the feet where it is associated with human papillomavirus [HPV] subtypes 16 and 18. Oral VC is far more common than extraoral VC and is distinctly linked to tobacco use.[4] The role of HPV in oral VC is controversial. Within the oral cavity, buccal mucosa and gingiva are the most frequently involved sites.[5]The Verrucous Carcinoma was described by LV Ackerman in 1948 [5] as an infrequent subtype of malignant disease which affects oral cavity. Usually, OVC presents a high tendency of local invasion, with a low tendency of dissemination, which varies depending on tumor size and evolution time [6], with a very low tendency to metastasize. Previous lesions as leucoplakias or erythroplakias, as well as Proliferative Verrucous Leucoplakia, are the sites where the OVC uses to arise from [7-9]. Its etiology is not well known, but smoking habit, alcohol consumption and betel nut chewing are proved causes. The role of the Human Papillomavirus in OVC oncogenesis is much less important than in the SCC oncogenesis [10-12]. Verrucous carcinoma usually debuts as an abnormal growth or as change in the consistency of a previous potentially malignant disorder of the oral cavity. All mucosal sites of the oral cavity can be affected. However, the rate of malignant transformation of a leukoplakia to an OVC is 20.81 times higher if they are located in the gingiva in comparison with the tongue [13]. Histopathologically, it frequently shows aneuploidy [14], which can be shown in conventional exfoliative cytology biopsies, which can be used as a marker of progression from potentially malignant disorder of the oral cavity to an OVC. Surgery is the best treatment. Although an optimal disease control can be achieved by surgery only, frequent revision is mandatory due to the increased risk of second tumors [15].

## II. Case Series

### Case 1:

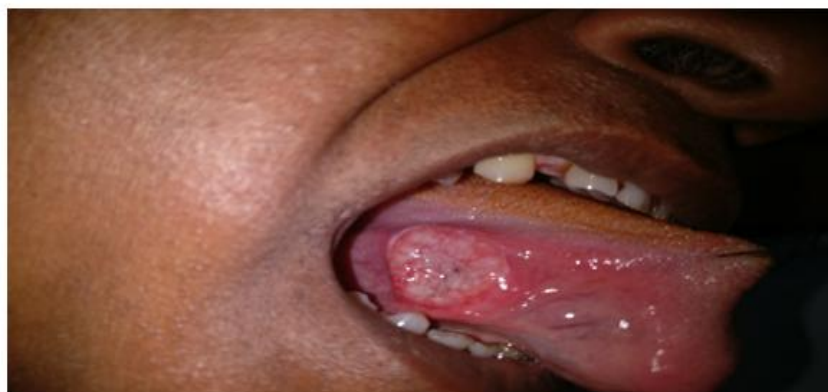A 48-year-old female patient with a history of tobacco chewing presented to the Department of Oral and Maxillofacial surgery with a slow growing large hyperplastic ulcero-proliferative growth in the right maxillary region. Clinical examination and radiographic CT scan assessment revealed a large soft tissue mass with superficial maxillary dento-alveolar involvement extending from the left central incisor to the right 1st molar region and from the gingivo-buccal sulcus region to the palatal side and crossing the palatal midline. No lymph node involvement was evident on clinical and radiographic examination. Deep incisional biopsies were taken from 3 different regions of the lesion which provided a provisional diagnosis of verrucous carcinoma. A sub-total maxillectomy on the right side was performed with an extension up to the left maxillary canine while maintaining a safe margin of 15 mm in all dimension. Primary reconstruction of the defect was performed with an antero-lateral thigh flap. An elective neck dissection for levels 1 to 3 on the right side was performed owing to the large extent and long-standing nature of the lesion. The final histo-pathological confirmed the diagnosis of verrucous carcinoma and all margins and lymph nodes were free of disease. (Fig.1)

**Fig. 1: Large hyperplastic ulcero-proliferative growth in the right maxillary region.**



### Case 2:

A 53-year-old female patient with a history of tobacco chewing presented to the Department of Oral and Maxillofacial Surgery with a history of long-standing pain and bleeding from the posterior region of her tongue on the right side. On clinical examination, a ulcero-proliferative lesion of approximately 2 cm in diameter was present on the lateral aspect of the right half of the tongue at the junction of the anterior 2/3rd and posterior 1/3rd. CT scan and MRI assessment revealed a lesion with a superficial diameter of 2 cm and depth of 0.5cm with no lymph-node involvement. A wide local excision while maintaining margins of 15mm in all dimensions was performed followed by primary closure of the defect. An elective neck dissection for levels 1 to 3 nodes was performed on the left side owing to the highly vascular nature of the tongue and depth of lesion. Histopathological examination revealed that the lesion was verrucous carcinoma and all margins and lymph-nodes were free from disease. (Fig.2)

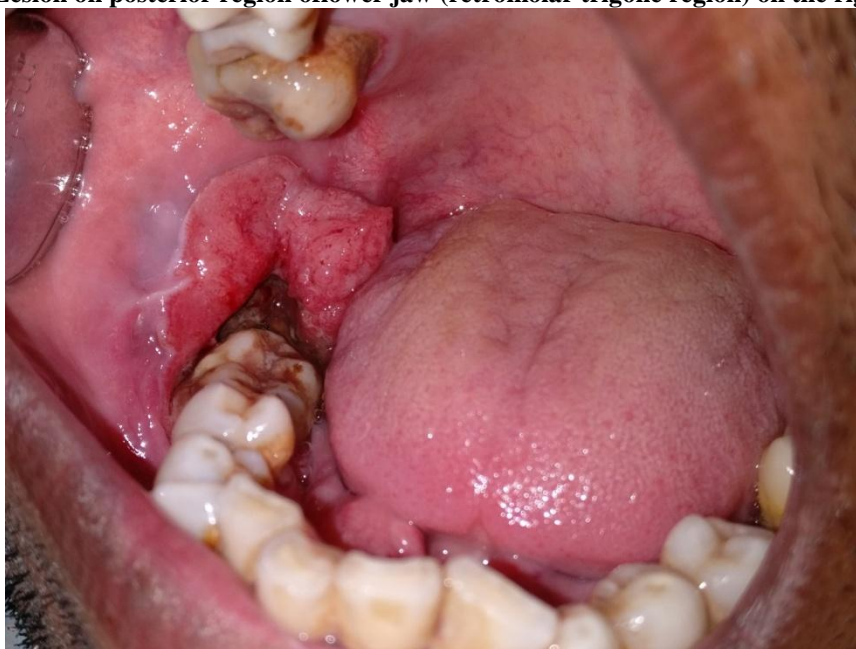


**Fig.2: Lesion on posterior region of tongue on the right side.**

**Case 3:**

A 53-year-old male patient with a history of tobacco chewing presented to the Department of Oral and Maxillofacial Surgery with a history of long-standing pain and bleeding from the posterior region of his lower jaw on the right side. On clinical examination, a ulcero-proliferative lesion of approximately 4 x 2 cm was present in the right retro-molar region. Radiographic assessment revealed a soft tissue mass in the right retromolar region with superficial erosion of the underlying mandibular dento-alveolar bone and a single enlarged submandibular lymph node [level 2A] of approximately 15mm in the largest diameter. An incisional biopsy of the lesion revealed verrucous carcinoma. A marginal resection of the lesion and the underlying bone maintaining a safe margin of 15mm was performed. The defect was closed primarily with a double layered closure using the adjacent buccal fat pad. No bony reconstruction was required as 1 cm of bone was still present along the inferior border of the mandible. A neck dissection was performed from levels 1 to 3. Histopathological examination revealed that the lesion was verrucous carcinoma and all margins and lymph nodes were free of disease. The enlarged submandibular lymph node revealed only inflammatory changes. (Fig.3)

**Fig.3: Lesion on posterior region of lower jaw (retromolar trigone region) on the right side.**



**III. Discussion**

Most common sites for verrucous carcinoma of the head and neck are the oral cavity and larynx. A review of 14,253 squamous cell carcinomas of the oral cavity by Krolls and Hoffman in 1976, however, identified the lip as the most commonly affected subsite, followed in descending order by the tongue and the floor of mouth. [16] Unlike squamous cell carcinoma, verrucous carcinoma arose most commonly on the gum [or gingiva], followed in descending frequency by the buccal mucosa, the tongue, palate, lip, and the floor of mouth. Tumors of the tongue, gum, and buccal mucosa predominated in the older age group [older than 75 years], whereas laryngeal tumors were more common in younger age groups. A greater percentage of males presented with laryngeal tumors, whereas a greater percentage of females presented with tumors of the tongue, gum, and buccal mucosa. The striking difference in the distribution of gender between the oral cavity and other head and neck sites has been addressed previously. [17] The more common use of snuff among elderly women, particularly in the southeastern United States, has been identified as one reason for the greater prevalence of verrucous carcinoma of the oral cavity among females. [13,46] This high incidence of oral verrucous carcinoma in elderly females exceeds that expected from greater exposure to snuff or other oral tobacco products. Gender- and age-related effects on immune competence both systemically and on the local oral epithelium may be implicated. [18] The common pathologic finding of reactive hyperplasia in enlarged lymph nodes draining verrucous carcinoma may be misinterpreted as demonstrative of metastatic disease if pathologic assessment of resected lymph nodes is not performed. [4] Alternatively, Batsakis et al. noted that metastases associated with a primary verrucous carcinoma may be explained either by an incorrect pathologic diagnosis or by the presence of occult squamous carcinoma in a lesion otherwise characteristic of verrucous carcinoma. [43] Schrader et al [8] and Jordan [19] have reported that verrucous carcinomas were slow-growing, exophytic, well-demarcated hyperkeratotic lesions. These typically present as extensive, white, warty lesions. [19] Shear and Pindborg [20]

reported that out of 28 patients with verrucous lesions, 24 [86%] used tobacco, and one was an areca quid chewer. Tobacco appears to be a major factor in causation of verrucous lesions. In Chen et al's [21] study of verrucous carcinomas in Taiwan, areca quid chewing was reported by 97.3%. In Chung et al's [21] study, the prevalence of verrucous lesions [not carcinomas] was 0.84%, and the frequency of current areca quid chewing in this subgroup was 55.6% [5/9]. The data indicate that, in Taiwan, areca quid use could be a major risk factor in verrucous lesions. Tobacco chewing habit is accepted as the primary etiological factor for oral VC.[4,22] Tobacco smoking and alcohol are known chemical carcinogen, but their association with VC is feeble. The etiology of VC is not well-defined. HPV has been considered one of the causative factors.[23] HPV subtype s 16 and 18 have been identified in up to 40% of oral VC.[7] The viral oncoproteins E6 and E7 binds to the proteins regulating cell division cycle p53 and Rb, inducing proliferative changes that are responsible for the malignant phenotype. [24] The role of HPV in oral VC is still controversial. Some authors hypothesized the synergistic action between chemical carcinogen and viral carcinogen.[25] Sequential combined effect of HPV 16 and tobacco related carcinogen can lead to malignant transformation of oral keratinocytes.[26] On the contrary, experiments have also shown that even though a minority of VC were positive for p16 and HPV DNA, but the uniform absence of transcriptionally active high-risk HPV has led to the conclusion that these are not HPV-driven tumors.[11] Poor oral hygiene and chronic irritation which were consistently present in our cases also support their etiologic role, although not as a primary factor. One case was seen in lower lip which suggests the role ultraviolet exposure too.[25]Surgical excision alone is the most common treatment of verrucous carcinoma. Improved outcomes were not shown with the addition of radiation therapy to surgery. Initial management with irradiation alone resulted in notably worse survival compared with surgical treatment for both laryngeal and oral cavity verrucous carcinoma.

#### **IV. Conclusion**

Verrucous hyperplasia, verrucous keratosis, and verrucous carcinoma may not be distinguished clinically or may coexist. It should be kept in mind that verrucous hyperplasia may also develop from leukoplakic lesions, and it may transform into verrucous carcinoma or squamous-cell carcinoma, acting as a potential precancerous lesion. Two of our cases were initial histopathological misdiagnoses; one was verrucous keratosis and the other was verrucous hyperplasia. In fact, all our cases were verrucous carcinoma. Thus, both clinicians and pathologists must be careful about warty and exophytic lesions in the oral cavity.

#### **References**

- [1]. Gnepp DR. Diagnostic Surgical Pathology of the Head and Neck. 2nd ed. Philadelphia: WB Saunders; 2001.
- [2]. Thomas GJ, Barrett AW. Papillary and verrucous lesions of the oral mucosa. *Diagn Histopathol* 2009; 15:279-85.
- [3]. Sapp JP, Eversole LR, Wysocki GP. Contemporary Oral and Maxillofacial Pathology. 2nd ed. St. Louis: Mosby; 2004.
- [4]. Neville BW, Damm DD, Allen CM, Bouquot JE. Oral and Maxillofacial Pathology. 2nd ed. New Delhi: Saunders; 2002.
- [5]. Steffen C. The man behind the eponym: Lauren V. Ackerman and verrucous carcinoma of Ackerman. *Am J Dermatopathol*. 2004; 26:334-41.
- [6]. Liu W, Shen XM, Liu Y, Li J, Zhou ZT, Wang LZ. Malignant transformation of oral verrucous leukoplakia: a clinicopathologic study of 53 cases. *J Oral Pathol Med*. 2011; 40:312-6.
- [7]. Bagan JV, Jiménez-Soriano Y, Diaz-Fernandez JM, Murillo-Cortés J, Sanchis-Bielsa JM, Poveda-Roda R, et al. Malignant transformation of proliferative verrucous leukoplakia to oral squamous cell carcinoma: A series of 55 cases. *Oral Oncol*. 2011; 47:732-5.
- [8]. Mete O, Keskin Y, Hafiz G, Kayhan KB, Unur M. Oral proliferative verrucous leukoplakia: Underdiagnosed oral precursor lesion that requires retrospective clinicopathological correlation. *Dermatol Online J*. 2010; 16:6.
- [9]. Bagan J, Scully C, Jimenez Y, Martorell M. Proliferative verrucous leukoplakia: a concise update. *Oral Dis*. 2010; 16:328-32.
- [10]. Saghavanian N, Ghazvini K, Babakoochi S, Firooz A, Mohtasham N. Low prevalence of high-risk genotypes of human papilloma virus in normal oral mucosa, oral leukoplakia and verrucous carcinoma. *Acta Odontol Scand*. 2011; 69:406-9.
- [11]. Lin HP, Wang YP, Chiang CP. Expression of p53, MDM2, p21, heat shock protein 70, and HPV 16/18 E6 proteins in oral verrucous carcinoma and oral verrucous hyperplasia. *Head Neck*. 2011; 33:334-40.
- [12]. Yamakawa-Kakuta Y, Kawamata H, Doi Y, Fujimori T, Imai Y. Does the expression of HPV16/18 E6/E7 in head and neck squamous cell carcinomas relate to their clinicopathological characteristics? *Int J Oncol*. 2009; 35:983-8.
- [13]. Alkan A, Bulut E, Gunhan O, Ozden B. Oral verrucous carcinoma: a study of 12 cases. *Eur J Dent*. 2010; 4:202-7.
- [14]. Maraki D, Boecking A, Pomjanski N, Megahed M, Becker J. Verrucous carcinoma of the buccal mucosa: histopathological, cytological and DNA-cytometric features. *J Oral Pathol Med*. 2006; 35:633-5.
- [15]. Liao CT, Kang CJ, Chang JT, Wang HM, Ng SH, Hsueh C, et al. Survival of second and multiple primary tumors in patients with oral cavity squamous cell carcinoma in the betel quid chewing area. *Oral Oncol*. 2007; 43:811-9.
- [16]. Smart CR, Karnell LH, Eberle C, Zippin C, Lum D, Clive R, et al. Quality control. In: Steele GD, Winchester DP, Osteen RT, Menck HR, Murphy GP, editors. National Cancer Data Base annual review of patient care, 1994. Atlanta, GA: American Cancer Society, 1994:117-26.
- [17]. Clive RE, Ocwieja KM, Karnell LH, Hoyler SS, Seiffert JE, Young JL, et al. A national quality improvement effort: cancer registry data. *J Surg Oncol* 1995; 58:155-61.
- [18]. Eberle C, Phillips JL, Tary P, Menck HR. Quality management in the National Cancer Data Base: a re-abstracting study of the Midwest region. *J Regist Manage* 1997; 24:93-7. 47. Neville BW. Verrucous carcinoma [snuff dipper's cancer]. *Oral and maxillofacial pathology*. 1st ed. Saunders, 1995:304-6.
- [19]. Batsakis JG, Hybels R, Crissman JD, Rice DH. The pathology of head and neck tumors: verrucous carcinoma. Part 15. *Head Neck Surg* 1982; 5:29-38.

- [20]. Shear M, Pindborg JJ. Verrucous hyperplasia of the oral mucosa. *Cancer* 1980; 46:1855-1862.
- [21]. Chen BL, Lin CC, Chen CH. Oral verrucous carcinoma: an analysis of 73 cases. *Clin J Oral Maxillofac Surg* 2000; 11:11- 17.
- [22]. Barnes L, Eveson JW, Reichart P, Sidransky D, editors. *World Health Organization Classification of Tumors. Pathology and Genetics of Head and Neck Tumors*. Lyon, France: IARC Press; 2005.
- [23]. Eversole LR. Papillary lesions of the oral cavity: Relationship to human papillomaviruses. *J Calif Dent Assoc* 2000; 28:922-7.
- [24]. Schwartz RA. Verrucous carcinoma of the skin and mucosa. *J Am Acad Dermatol* 1995; 32:1-21.
- [25]. Kim MS, Shin KH, Baek JH, Cherrick HM, Park NH. HPV-16, tobacco-specific N-nitrosamine, and N-methyl-N'-nitro-N-nitrosoguanidine in oral carcinogenesis. *Cancer Res* 1993; 53:4811-6.
- [26]. Patel KR, Chernock RD, Zhang TR, Wang X, El-Mofty SK, Lewis JS Jr. Verrucous carcinomas of the head and neck, including those with associated squamous cell carcinoma, lack transcriptionally active high-risk human papillomavirus. *Hum Pathol* 2013; 44:2385-92.

Dr. Lasya Borra. "Verrucous Carcinoma of Oral Region: Case Series and Mini Review." *IOSR Journal of Dental and Medical Sciences (IOSR-JDMS)*, vol. 18, no. 1, 2019, pp 50-54.