

## Acute Abdomen caused by Spontaneous urinary bladder rupture: Case Series and Review of Literatures.

Shailesh Kumar\*, Sumit Pathania, Animesh Gupta

Department of general surgery, PGIMER & Dr. RML hospital New Delhi India.

\*Professor of Surgery Department of General Surgery PGIMER Dr Ram Manohar Lohia Hospital New Delhi  
India.

Corresponding Author: Shailesh Kumar

---

### Abstract

**Introduction-** Spontaneous intraperitoneal rupture of the urinary bladder is a rare condition, mostly associated with some underlying chronic conditions necessitating long term catheterization. The preoperative diagnosis is difficult because of its presentation with non specific sign and symptoms.

**Case Presentation-** We are presenting case series of Spontaneous intraperitoneal rupture of the urinary bladder. Both cases were diagnosed intraoperatively because of their presentation similar to that of an acute abdomen due to intestinal perforation.

**Conclusion-** High degree of suspicion is the crux of the pre operative diagnosis. cystography/CT could play an important role in early diagnosis and better outcome.

**Key Words:** SRUB (Spontaneous rupture of Urinary bladder), Acute Abdomen.

---

Date of Submission: 30-12-2018

Date of acceptance: 15-01-2019

---

### I. Introduction

Spontaneous rupture of the urinary bladder (SRUB) is very uncommon cause of acute abdomen. SRUB is most often associated with some underlying chronic illness or other immunosuppressive illness like h/o radiotherapy, inflammation, malignancy, urinary obstruction, or other causes found in almost all cases<sup>1</sup>. Sisk and Wear in 1929 first coined and defined the term spontaneous urinary bladder rupture as "If the bladder ruptures without external stimulation, it is spontaneous and deserves to be reported as such"<sup>2</sup>. Patients with rupture of urinary bladder usually present with symptoms and signs of peritonitis<sup>3</sup>. Schein et al. assert that The SRUB is normally remain undiagnosed and is usually diagnosed during laparotomy<sup>4</sup>.

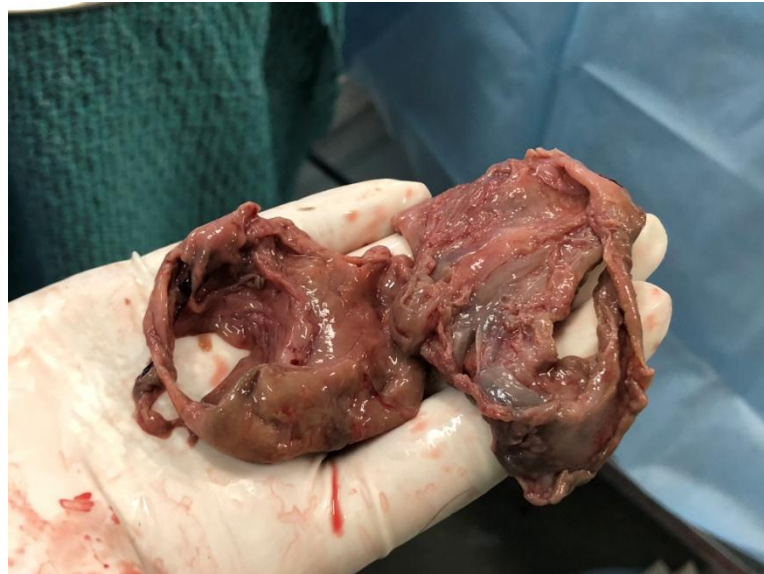### II. Case Report

Our first case was a 45 year old male diabetic patient referred from other hospital with diagnosis of perforation peritonitis with intra abdominal drain and Foley's catheter in situ. Patient had history of pain abdomen and distention with vomiting off & on for last 3 days.

Patient had history of CVA for last 2 years after which he developed quadriparesis and gradually become bed ridden since last four months. Patient had uncontrolled diabetes from past 4-5 years with irregular medication. He had history of urinary retention with pyuria for last 4 months for which intermittent Foley's catheterisation was done. Patient also had history of hematuria on and off from past 2 months

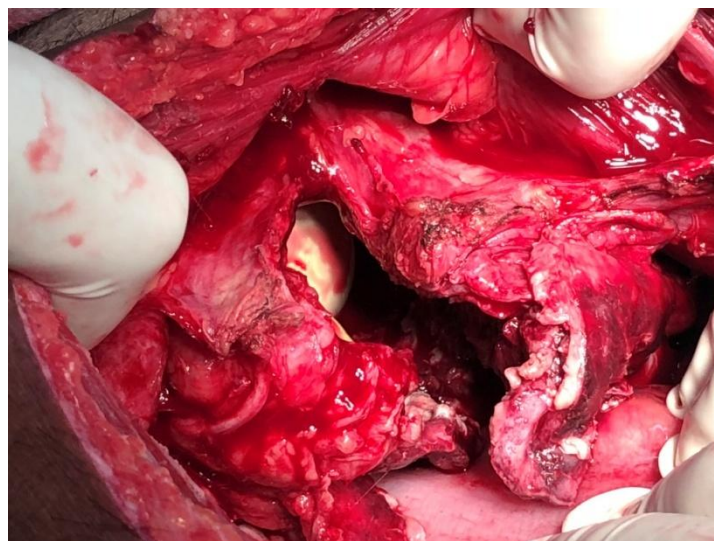
On admission Patient was in shock with 200ml fluid mixed with abscess in abdominal drain and 100ml high color urine in Urobag. Abdominal examination revealed symmetrically distention with no bowel sounds. Patient was resuscitated and planned for Emergency exploratory laparotomy. A written informed consent was taken from the patient. Investigations revealed haemoglobin 7.7 gm%, WBC 17,200/cumm, platelet 36000, UREA 81mg/dl, Creatinine 1.4mg/dl, Na 143mmol, K 3.8mmol and INR 1.45

Intra operatively there was presence of approximately 300ml of turbid fluid in the pelvis having urinary smell with large 4\*4 cm perforation present over dome and posterior wall of urinary bladder with inflamed and necrotic bladder wall (**Fig 1.**)



**Fig1-** Show Necrosed dome and posterior wall of the Urinary bladder

100cc of pus and clot was drained from urinary bladder. Stomach, bowel and rest of solid organs appear normal. Urinary bladder wall freshened and margins sent for histopathological examination which later on revealed chronic benign lesions(**Fig2.**)

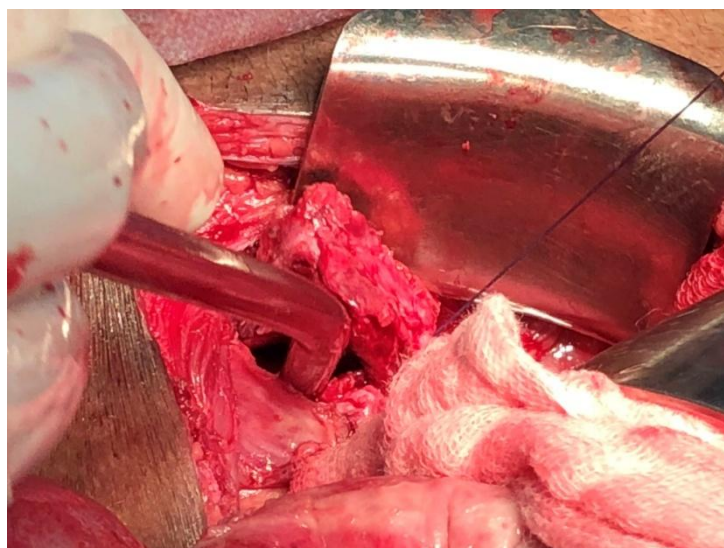


**Fig2** Shows big Perforation over dome and posterior wall

Our second case was 60-yearold male with psychologically unstable conditionreferred to our emergency room with complains of abdominal pain ,distention andvomiting, with ryles tube and Foleys catheter in situ. He had history of Traumatic paraplegia following road traffic accident 6 month back. He was on domiciliary CIC (clean intermittent catheterization) for last 4 months. There was history of intermittent pyuria and hematuria since last 2 months.

On admission Patient had Abdominal pain with distention and no bowel sound. Investigations revealed Hb 8.6 gm%, WBC 23,200cumm, with abnormal liver and renal function. Ultrasonography revealed distended bowel with around 250-300 ml thick fluid collections in the pelvis. Rest investigations were within normal limit

On laparotomy, peritoneal fluid were mopped out. Omentum was stuck to the pelvis. On dissection it revealed edematous urinary bladder wall with perforation around 2\*2 cm on the dome posteriorly(**Fig 3.**)



**Fig 2-**shows perforation over dome

Stomach, bowel and other solid organs appears within normal limit. Perforation margin were freshened and repaired in two layers leaving suprapubic and trans urethral catheterization with drain in space of retzius. The perforation margins on histopathological examination revealed chronic inflammatory lesions

### **III. Discussion**

A spontaneous Urinary bladder rupture is an uncommon clinical condition with high mortality rate as patient usually present with non specific systems and no history of any trauma abdomen. It results in diagnostic dilemma and hence delayed diagnosis. According to Mallick et al<sup>5</sup> an accurate initial diagnosis of urinary bladder rupture was made in 2 out of 15 case reports between 1967 and 2007

In most of the cases, it is secondary to some associated co-morbidities like infectious disease, Neurogenic bladder, irradiation, invasive malignancy, obstructed labour<sup>6</sup>. Wilson reported a case of SRUB due to neurogenic bladder in a patient with *Tabes Dorsalis* in 1940<sup>7</sup>. SRUB due to invasive bladder tumor is a rare cause of perforation<sup>8,9</sup>. Diabetes cause neurogenic bladder as a diabetic neuropathy with decreased bladder sensitivity leading to chronic urinary retention and recurrent urinary tract infections may also have increased incidence of bladder rupture<sup>10</sup>. Bladder wall dysfunction is due to disturbance in neurological function because of stroke and possible urinary retention<sup>11</sup>. Neurological dysfunction in the form of brainstem ischemia has specifically been reported in the past as a cause of urinary retention.<sup>12</sup> The most frequent location for spontaneous intraperitoneal perforation of urinary bladder is the dome or the posterior wall of the bladder<sup>13</sup>.

In our case, cause of SRUB is probably because of disturbance in neurological function secondary to stroke and diabetes along with urinary bladder infection (cystitis) particularly in the first case. We also suspect chronic over distension complicated with acute on chronic cystitis leading to ischemia and hence perforation mainly in the second cases. Both of our patients presented to surgical emergency with features suggestive of acute abdomen and diagnosed as case of SRUB intraoperatively. In both the cases, site of perforation were dome with some part of the posterior wall.

Diagnosis of SRUB can be made by CT abdomen which shows perforation and fluid collection but cystography is ideal which has high sensitivity rate. Cystogram is the diagnostic test of choice, though false negative cystography with bladder perforation is not uncommon. Lowe et al reported the successful use of CT scan in confirming the diagnosis when cystography is negative or equivocal.<sup>14</sup> Treatment is surgical debridement of perforation margin and repair in two layers with SPC and Foleys catheterization with drain in space of retzius. Laparoscopy is an excellent option not only for diagnosis but also for repair, how-ever it requires skills and experience.<sup>6</sup>

### **IV. Conclusion**

Diagnosis of SRUB is mainly by the High degree of suspicion particularly in patient present with acute abdomen with history of hypo gastric pain, haematuria, urinary tract infection with other immunosuppressive co-morbidities. Early diagnosis by cystography/CT should be done, but in absence of these modalities in emergency, exploratory laparotomy should be performed without delayed for better outcome in terms of morbidity and mortality.

**INFORMED CONSENT:** Written informed consent was obtained from both the patient who participated in this case.

**FINANCIAL DISCLOSURE:** The authors declared that this study has received no financial support.

**CONFLICT OF INTEREST:** None declared.

### References

- [1]. Schraur WH, Huffman J, Bagfley DH. Acute abdominal pain caused by spontaneous perforation of the urinary bladder. *SurgGynecol Obstet.* 1983;156:589–592. [[PubMed](#)]
- [2]. Sisk IR, Wear JB. Spontaneous rupture of the urinary bladder. *J Urol.* 1929;21:517–521.
- [3]. Ahmed J, Mallick IH, Ahmad S: Rupture of urinary bladder: a case report and review of literature. *Cases J* 2009;2:7004.
- [4]. Schein M, Weinstein S, Rosen A, Decker GAG. Spontaneous rupture of the urinary bladder delayed sequel of pelvic irradiation a case report. *S Afr Med J.* 1986;70:841–842. [[PubMed](#)]
- [5]. Urology Care Foundation: Bladder Diverticulum. [www.urologyhealth.org/urology/index.cfm?article=111](http://www.urologyhealth.org/urology/index.cfm?article=111). Updated January 11, 2014.
- [6]. Zubair AL-Qassim, AZA Mohammed, Roland England, Zeb Khan. Idiopathic spontaneous rupture of the Urinary bladder. *Cent.European J Urology.* 2012;65(4):235-237.
- [7]. Wilson L. Spontaneous rupture of the urinary bladder in a tabetic patient. *Med Bull Vet Admin.* 1940;17:93-95.
- [8]. Stone E. Spontaneous bladder rupture. *Arch Surg.* 1931;23:129.
- [9]. Bastable JRG, De Jode LR, Warren RP. Spontaneous rupture of the bladder. *Br J Urol.* 1959;31:78–86. [[PubMed](#)]
- [10]. Gomes C.A., de Figueiredo A.A., de Soares C., Jr. Acute abdomen: spontaneous bladder rupture as an important differential diagnosis. *Rev. Col. Bras. Cir.* 2009;36:364–365.
- [11]. Mitchell T, Al-Hayek S, Patel B, Court F, Gilbert H: Acute abdomen caused by bladder rupture attributable to neurogenic bladder dysfunction following a stroke: a case report. *J Med Case Rep* 2011;5:254.
- [12]. Lee KB, Jang IM, Roh H, Ahn MY, Woo HY. Transient urinary retention in acute right lateral medullary infarction. *Neurologist.* 2008;14:312–315. doi: 10.1097/NRL.0b013e3181714a09. [[PubMed](#)]
- [13]. Addar MH, Stuart GC, Nation JG, Shumsky AG. Spontaneous rupture of the urinary bladder: a late complication of radiotherapy- case report and review of the literature. *GynecolOncol.* 1996;62:314–316. doi: 10.1006/gyno.1996.0234. [[PubMed](#)]
- [14]. Lowe FC, Fishman EK, Oesterling JE. Computerized tomography in diagnosis of bladder rupture. *Urology.* 1989;33:341. doi: 10.1016/0090-4295(89)90283-5. [[PubMed](#)]

Shailesh Kumar. “Acute Abdomen caused by Unrecognised Spontaneous urinary bladder rupture: Case Series and Review of Literatures.” *IOSR Journal of Dental and Medical Sciences (IOSR-JDMS)*, vol. 18, no. 1, 2019, pp 14-17.