

Peripheral Ameloblastoma Presenting As a Gingival Mass

Dr. Minu S¹, Dr. Philips Mathew²

¹(Junior Resident, Department of Oral Medicine & Radiology, Govt. Dental College, Kottayam, Kerala)

²(Assistant Professor, Department of Oral Medicine & Radiology, Govt. Dental College, Kottayam, Kerala)

Corresponding Author: Dr. Minu S

Abstract: Peripheral ameloblastoma (PA) is a rare, benign, extraosseous odontogenic soft tissue tumour that is confined to the gingiva or the alveolar mucosa. PA presents the same histological characteristics as of intraosseous ameloblastoma, although it is less aggressive than this classical subtype. We report here, a clinical case of PA of the gingiva in the left posterior mandible. This reports emphasis the need for submitting all excised tissue for microscopic examination and to include ameloblastoma in the differential diagnosis of a gingival lesion which clinically resembles a pyogenic granuloma, peripheral giant cell granuloma, or peripheral ossifying fibroma.

Keywords: Lower gingiva, Odontogenic tumor, Peripheral ameloblastoma

Date of Submission: 19-01-2019

Date of acceptance: 04-02-2019

I. Introduction

Ameloblastomas are the most common odontogenic tumor and they are clinically and histologically diverse. The first detailed description of this lesion was by Falkson in 1879, but the term 'ameloblastoma' was coined by Churchill in 1933.^[1] These tumors have several distinct clinical types, including solid, multicystic, unicystic, desmoplastic, and peripheral ameloblastomas (PAs). Each has a specific biological behavior and consequently a different prognosis and treatment.^[2] Although ameloblastomas are subclassified as follicular, plexiform, granular, basal cell, acanthomatous, and desmoplastic types in histology, different histological patterns can coexist in the same lesion.^[3] It represents approximately one percent of oral tumours, with 80 percent of ameloblastomas occurring in the mandible, and develops from the odontogenic epithelium and its derivatives or remnants. Sometimes it arises from a dentigerous cyst.^[5,6]

Peripheral ameloblastoma, a rare and unusual variant of ameloblastoma that occurs in extraosseous regions such as the gingiva and oral mucosa covering the alveolus. They account for approximately 2% to 10% of all ameloblastomas.^[7] Clinically, a PA is a painless, firm, exophytic growth with a smooth, granular, pebbly, warty, or papillary surface. The primary importance of these tumours is the non-specific clinical appearance that can mimic any of the non odontogenic swellings on the gingiva and lead to incomplete treatment and lack of long term follow up if wrongly diagnosed. This paper reports a case of peripheral ameloblastoma in a 46-year-old male that presented as a painless swelling on the mandibular posterior gingiva.

II. Case Report

A 46-year-old male patient reported to our department with the chief complaint of growth on lower left posterior gum region since 1 month^[Fig. 1]. Patient was apparently all right till a month back, and then he noticed the peanut sized growth, which gradually increased to present size. It was not associated with any pain or discharge. Patient has not had any history of trauma related to the region, and no deleterious oral habits.

He had prior consultation with a medical practitioner about 2 weeks back, and is advised to take antibiotics. After 5 days of medication, the swelling remained. His medical and family histories were noncontributory. On general examination the patient was moderately built and nourished, with stable vital parameters. Mild pallor was present. There was no regional lymphadenopathy.

On intraoral examination, a well-defined solitary, exophytic growth was seen on gingiva, in the left side of the mandible, measuring approximately about 2cm x 1.5cm, extending from the distal aspect of 38 up to 1.5cm posteriorly into retromolar trigon. Overlying mucosa was pink in colour with hyperkeratotic patch in the anterior aspect. Surrounding mucosa appeared normal. On palpation it was sessile, non-tender, firm in consistency with smooth surface, and with well-defined margin. There was no bleeding or pus discharge on palpation.

Based on the clinical findings, a provisional diagnosis of peripheral ossifying fibroma was made, with a probable differential diagnosis of pyogenic granuloma.

In addition, the patient was subjected to the following investigations:

1. Routine blood examination
2. Radiograph-IOPAR
3. Vitality test
4. Excisional biopsy

All hematological investigations were normal. Intra oral radiographs of the region showed no obvious bony involvement^[Fig.2]. The teeth associated with the lesion showed positive response in vitality test. An excisional biopsy of the lesion was performed under local anaesthesia.

Histopathology^[Fig.3] showed serial sections of odontogenic epithelium proliferating in the form of interconnected strands, which were peripherally lined by tall columnar like cells, and centrally by stellate reticulum like cells. A few follicles were also noted. The intervening stroma was delicately collagenous with diffused collection of chronic inflammatory cells and with moderate vascularity. Based on these findings, a diagnosis of peripheral plexiform ameloblastoma was given.

The patient reported after 1 month for a review. The mucosal area on the operated site showed good healing^[Fig.4], with no evidence of recurrence, or any bony involvement^[Fig.5]. The patient was instructed to follow up for further reviews every 6 months for the next couple of years.

III. Discussion

Peripheral ameloblastoma, a rare and unusual variant of ameloblastoma that occurs in extraosseous regions such as the gingiva and oral mucosa covering the alveolus without exhibiting the invasive and aggressive behavior of its intraosseous counterpart^[10]. They account for approximately 2% to 10% of all ameloblastomas^[7]. The first documented case of PA can be attributed to Kuru in 1911^[11], though Stanley and Krogh^[12] were the first to adequately document a case of ameloblastoma that was located entirely within the soft tissue overlying bone but separate from it.

Peripheral ameloblastomas are more common in males. The mean age of patients with PA (males 53 years, females 51 years) is significantly higher than for the intraosseous counterpart, which has a mean age of 37 years^[3]. The male:female ratio is 1.9:1 and the mandible: maxilla ratio is 2.4:1^[3]. The most common site of their occurrence is the mandibular mucosa, in the region of lingual gingiva of the canine, premolar area, followed by the molar-retromolar region^[13]. This is in line with the patient case.

PA can also be seen infrequently in the maxilla^[14]. There have also been rare instances of the lesion occurring in extra gingival regions like the buccal floor and floor of the mouth^[15]. Clinically, these lesions are usually asymptomatic and appear as an exophytic condition with the overlying mucosa being normal in colour and smooth surfaced. Their size can be up to 5 cm and the larger ones usually become symptomatic because of the trauma due to their interference with occlusion.

PA is difficult to diagnose based only on clinical findings, and it can be confused clinically with an epulis, fibroma, gingival tumor, or carcinoma including intraoral BCC^[16]. PA is frequently diagnosed after histological examination of specimens from a resected tumor or biopsy. In our case, we were unable to diagnose PA purely based on the clinical findings.

Histologically, a PA consists of proliferating ameloblastic epithelium underlying mucosal epithelium. The histopathological picture of these lesions can be either the acanthomatous, plexiform, or follicular types. Because of the location, and its histopathologic features it is possible to mistake it with basal cell carcinoma^[17]. Like the basal cell carcinoma of the skin, the PA shows proliferation of basal cells often arranged in nests included in a fibrous stroma with areas of contact with the epidermis. The arrangement of the rim cells of the nests are palisading, but in contrast with the basal cell carcinoma, those cells have the nuclei located on the basis of the cytoplasm, the rim cells of the peripheral ameloblastoma have the nuclei located on the upper part of the cytoplasm. In addition, the immunohistochemical analysis establishes the differences between these two types of tumors. The basal cell carcinoma shows diffuse and marked positivity for Ber-EP4 and negativity for cytokeratin 19; on the contrary, the peripheral ameloblastoma is always negative for Ber-EP4, except very focal areas in which a true basalioid differentiation is present, and diffusely and markedly positive for the cytokeratin 19^[18].

Radiographically, a PA is superficial to cortical bone with no sign of bone involvement. Therefore, a PA is considered less aggressive than an intraosseous ameloblastoma, which does invade bone^[3]. A few cases of PA have shown some bone involvement, which has been referred to as cupping or saucerization due to the depression resulting from the pressure of the tumor on bone^[19,20]. In our case, no bone resorption was seen.

The treatment of PA consists of surgical excision down through the periosteum. The recurrence rate of PA is much lower (19%) than that of intraosseous ameloblastoma (33%)^[21]. Recurrence is rare even with conservative resection; however, some cases of malignant transformation of PA have been reported. Moreover, PA and intraoral BCC may be the same entity^[22]. Therefore, long-term follow-up is essential.

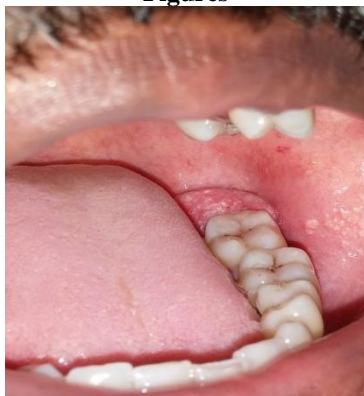IV. Conclusion

In conclusion, this report emphasizes the need for submitting all excised tissue for microscopic examination, and to include ameloblastoma in the differential diagnosis of gingival lesions, which may clinically resemble pyogenic granuloma, peripheral giant cell granuloma, or peripheral ossifying fibroma.

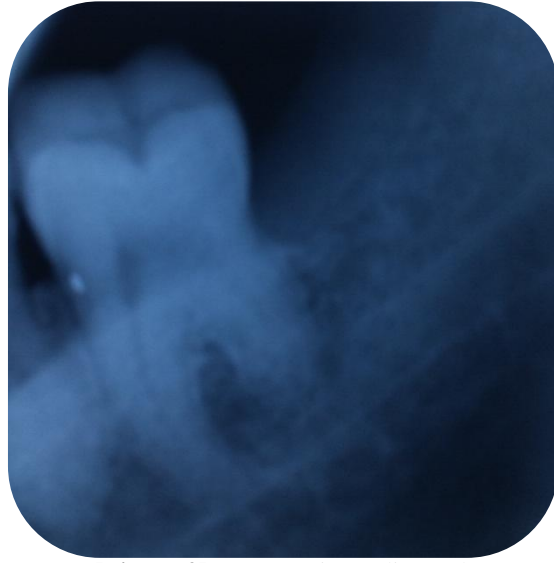
References

- [1]. Larsson Å, Almerén H. Ameloblastoma of the jaws. *Acta Pathologica Microbiologica Scandinavica Section A Pathology*. 1978;86(1- 6):337-49.
- [2]. Gardner DG. Some current concepts on the pathology of ameloblastomas. *Oral Surg Oral Med Oral Pathol Oral Radiol Endod* 1996; 82: 660-9.
- [3]. Gardner DG, Heikinheimo K, Shear M, Philipsen HP, Coleman H. Ameloblastoma. In: Barnes L, Eveson J, Reichart P, Sidransky D, eds. *World Health Organization classification of tumours; pathology and genetics of head and neck tumours*. Lyon: IARC Press, 2005: 296–300.
- [4]. Kishino M, Murakami S, Yuki M, Iida S, Ogawa Y, Kogo M, et al. A immunohistochemical study of the peripheral ameloblastoma. *Oral Dis* 2007; 13: 575-80.
- [5]. Iordanidis S, Makos C, Dimitrakopoulos J, Kariki H. Ameloblastoma of the maxilla. Case report. *Australian Dental Journal*. 1999;44(1):51-5.
- [6]. Shteyer A, Lustmann J, Lewin-Epstein J. The mural ameloblastoma: a review of the literature. *Journal of oral surgery*. 1978;36(11):866-72.
- [7]. Ficarra G, Hansen LS. Peripheral ameloblastoma: A case report. *Journal of Cranio-Maxillofacial Surgery*. 1987;15:110-2.
- [8]. Pekiner F, Ozbayrak S, Sener B, Olgac V, Sinanoglu A. Peripheral ameloblastoma: a case report. *Dentomaxillofacial Radiology*. 2007;36 (3): 183-6.
- [9]. Mathur LK, Bhalodi AP, Manohar B, Bhatia A, Rai N, Mathur A. Focal fibrous hyperplasia: a case report. *International Journal of Dental Clinics*. 2010; 2(4):56-7.
- [10]. El-Mofty S, Gerard N, Farish S, et al: Peripheral ameloblastoma: A clinical and histologic study of 11 cases. *J Oral Maxillofac Surg* 48:970,1991.
- [11]. Zhu EX, Okada N, Takagi M: Peripheral ameloblastoma: Case report and review of literature. *J Oral Maxillofac Surg* 53:590,1995.
- [12]. Stanley HRJ, Krogh HW: Peripheral ameloblastoma. Report of a case. *Oral Surg Oral Med Oral Pathol* 12:760-765,1959.
- [13]. Kiran Holikatti, Swapnil Deore, Pavan Gothe, Nageshkumar Shinde. Ameloblastoma masquerading as gingival enlargement: A case report with unusual presentation. *Journal of Oral & Maxillofacial Surgery, Medicine and Pathology*, in press, corrected proof, Available online 2 Jan 2015.
- [14]. Bryan J Vanoven, Noah P Parker, Guy J Petruzzelli. Peripheral ameloblastoma of the maxilla: a case report and literature review. *American journal of Otolaryngology* Vol 29 Issue 5,357-360, Sep-Oct 2008.
- [15]. Emiko Tanaka Isomura, Masaya Okura, Syunsuke Ishimoto, Chiaki Yamada, Yudai Ono, Mitsumobu Kishino, and Mikihiko Kogo Case report of extralingival peripheral ameloblastoma in buccal mucosa *Oral Surg Oral Med Oral Pathol Oral Radiol Endod* 108:577-579,2009.
- [16]. Kishino M, Murakami S, Yuki M, Iida S, Ogawa Y, Kogo M, et al. A immunohistochemical study of the peripheral ameloblastoma. *Oral Dis* 2007; 13: 575-80.
- [17]. Simpson HE. Basal cell carcinoma and peripheral ameloblastoma. *Oral Surg Oral Med Oral Pathol* 38:233–40,1974.
- [18]. M. Lentini, A. Simone, G. Carrozza Peripheral ameloblastoma: use of cytokeratin 19 and Ber-EP4 to distinguish it from basal cell carcinoma *Oral Oncology EXTRA* 40 79–80,2004.
- [19]. Redman RS, Keegan BP, Spector CJ, Patterson RH. Peripheral ameloblastoma with unusual mitotic activity and conflicting evidence regarding histogenesis. *J Oral Maxillofac Surg* 1994; 52: 192-7.
- [20]. Lin SC, Lieu CM, Hahn LJ, Kwan HW. Peripheral ameloblastoma with metastasis. *Int J Oral Maxillofac Surg* 1987; 16: 202-4.
- [21]. Yamanishi T, Ando S, Aikawa T, Kishino M, Nakano Y, Sasai K, et al. A case of extralingival peripheral ameloblastoma in the buccal mucosa. *J Oral Pathol Med* 2007; 36: 184-6.
- [22]. Koutlas IG, Koch CA, Vickers RA, Brouwers FM, Vortmeyer AO. An unusual ostensible example of intraoral basal cell carcinoma. *J Cutan Pathol* 2009; 36: 464-70.

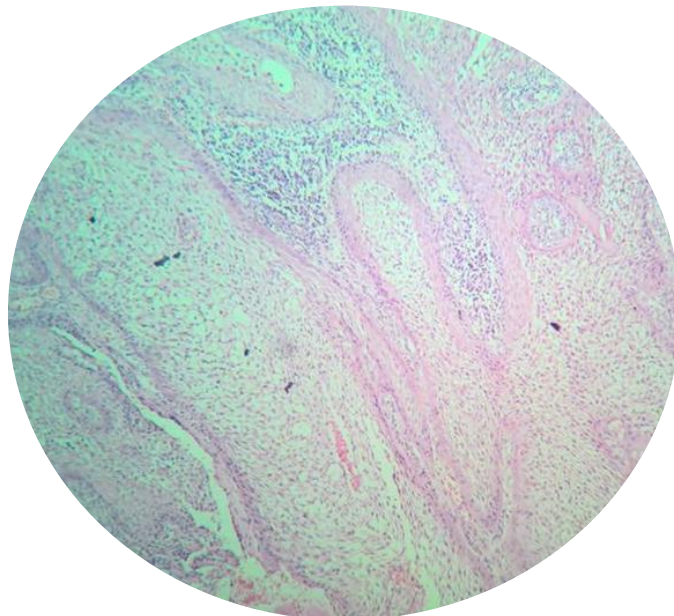
Figures



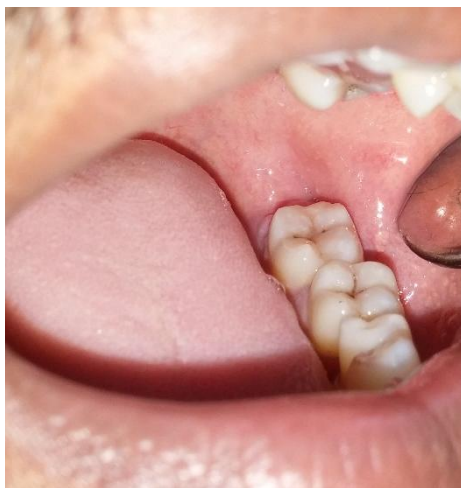[Figure 1]:Preoperative view of the lesion



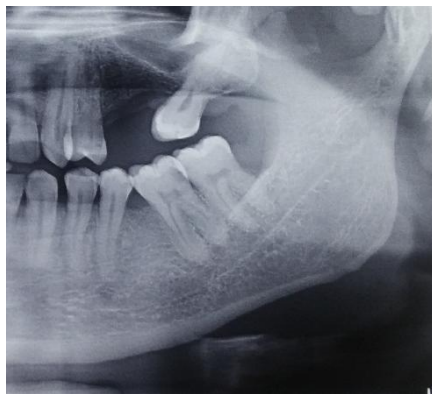[Figure 2]:Preoperative radiograph



[Figure 3]: Photomicrograph of biopsy specimen



[Figure 4]:Postoperative view of the region



[Figure 5]:Postoperative radiograph

Dr. Minu S. "Peripheral Ameloblastoma Presenting As a Gingival Mass." IOSR Journal of Dental and Medical Sciences (IOSR-JDMS), vol. 18, no. 1, 2019, pp 55-59.