

## A Clinical Study of Single Stage Postero-Lateral Transpedicular Ecompression with Screw Rod Fixation in Traumatic Thoraco-Lumbar Spinal Injuries

Chanumolu Praveen, K V V Satyanarayana Murthy, B Chandrasekhar, I Babji Syam Kumar, G Penchalaiah and Gottipati Bindu Narmada.

Department Of Neurosurgery, Guntur Medical College and Government General Hospital, Guntur-522001, Andhra Pradesh, India.

Corresponding Author: Chanumolu Praveen

**Keywords:** Thoracolumbar fractures, surgical treatment and technique, neurological recovery, transpedicular, vertebral body decompression, graft placement and fixation.

Date of Submission: 16-01-2019

Date of acceptance: 31-01-2019

### I. Introduction and Background

Thoracolumbar fractures occur from any and all forms of trauma and are the commonest spinal injuries. About twenty percent of them may be associated with neurological deficits [1,2]. In India however Dorsolumbar fractures are often associated with neurologic deficit and present a significant economic burden to the family and society [3]. The management of thoracolumbar fractures continues to evolve [4]. It remains difficult, however, to prove that surgical treatment provides an increased potential for neurological recovery. Also, the role of a decompressive laminectomy is still unclear [5].

Accepted methods of treatment of dorsolumbar burst fractures include conservative therapy, posterior reduction and instrumentation and anterior decompression and instrumentation. Early mobilization and rehabilitation is the most important aim of the management [6,7].

Operative decompression and internal fixation has become an accepted method of treatment of patients with unstable fracture with partial neurological deficit. Harrington's distraction instrumentation has its own limitations like decreased flexibility of spine, implant breakage, loss of fixation and loss of lumbar lordosis [8]. The search for an ideal implant which could provide segmental rigid fixation and yet allow early immobilization without support has continued. Steffee [9] in 1986 reported a pedicular screw placement based on the concept of force nucleus of the vertebral body pedicle. The Steffee plate system is a versatile implant which can be used in traumatic, degenerative and neoplastic disorders of the spine.

In the present scenario surgical reconstruction and fusion form the treatment of choice for unstable thoracolumbar fractures. The goal of the treatment of unstable thoracolumbar injuries is optimizing neural decompression while providing stable internal fixation over the least number of spinal segments [10]. Either anterior or posterior or both the approaches can be used to achieve fusion but the efficacy of either approach is the same [11,12,13]. However posterior approach is less extensive [14]. Pedicle screw devices allow immediate stable fixation as the screws traverse all the three columns. The pedicle screws are passed one or two levels above and one or two levels below the injured vertebra via posterior approach.

The posterior decompressive laminectomy has fallen out of favour with reports now suggesting that neurological deterioration could result following the procedure [15,16,17]. The anterior approach allows for excellent exposure of the vertebral body, however the procedure is associated with significant post-operative morbidity and a second procedure may be needed for posterior stabilization of the spine [18].

The transpedicular approach allows for a single stage vertebral body decompression, graft placement and fixation. The procedure is cost effective and allows early mobilization of the patients [16-18].

In this study we want to assess our results of single staged posterior transpedicular decompression of fractured vertebral body compressing the spinal cord.

### Aims & Objectives of the study

- To study the specified injury occurrence, age and sex distribution of traumatic thoracolumbar spinal injuries in our patient population.
- To study the role of imaging in the diagnosis, postoperative results and follow up of traumatic thoracolumbar spinal injuries.

- To demonstrate the feasibility of spinal canal decompression, vertebral height correction and kyphotic angle correction through the posterior transpedicular approach in our patients with thoracolumbar injuries.
- To analyze, the overall results of transpedicular decompression and pedicular screw rod fixation in our patients with traumatic thoracolumbar spinal injuries.

## **II. Materials and Methods**

**STUDY AREA:** This study was conducted in Department of Neurosurgery, Government General Hospital (GGH) / Guntur Medical College, Guntur. This is a tertiary care referral center in the Guntur district in the state of Andhra Pradesh.

**STUDY POPULATION:** Patients admitted with traumatic thoraco-lumbar spinal injuries at GGH, Guntur in the study period.

**STUDY PERIOD:** From March 2016 to March 2017, a period of 12 months.

**SAMPLE SIZE:** During this period a total of 446 patients were admitted (March 2016 to March 2017) with traumatic spinal injuries, of which 174 cases were of thoracolumbar injuries. Out of these only 49 patients of the above mentioned subjects were enrolled as per the inclusion and exclusion criteria mentioned below.

### **INCLUSION CRITERIA:**

- Spinal canal compression caused by bony fragments or otherwise, who demonstrate worsening of neurological status.
- Patients with incomplete deficits in whom neurologic function was plateaued.
- Patients who had significant canal compromise.
- Patients who had significant loss of anterior body height.
- Patients who had significant post traumatic spinal kyphosis.

### **EXCLUSION CRITERIA:**

- Patients with complete cord transection were excluded from the study.
- Patients who had complete loss of sensory and motor functions below the level of injury (Frankel's Grade A), after they have recovered from post traumatic spinal shock.
- The patients with pre-existing systemic illness or associated extra spinal injuries significant enough to result in increased morbidity or mortality.
- Patients found to have pathological fractures, both pre-operatively and/ or post operatively detected were excluded.
- Patients who were managed conservatively were also excluded from the study.
- Patients who did not consented for surgery and/ or inclusion in this study after proper explanation of the study, operation to be performed, implant use, prognosis and risks associated, were also excluded from this study proper.

**STUDY DESIGN:** This study was a prospective clinical study of patients admitted with traumatic thoracolumbar spinal injuries in our institute, only those cases indicated for surgery were randomly selected and thorough clinical and radiological evaluation was done (as detailed in study tools and techniques below) in them. Proper evaluation in these patients both pre-operatively and post-operatively were done to come to conclusions at the end of study period.

### **PARAMETERS STUDIED:**

**a) Disease occurrence** of traumatic thoracolumbar spinal injuries in our attending outdoor, emergency and admitted patients in comparison to total number of patients admitted in department of Neurosurgery in the study period.

**b) Age and sex distribution** of traumatic thoracolumbar spinal injuries in our patient population.

**c) Mode of injury** and the interval of time from occurrence of injury and admission to hospital and operations were studied to see the time interval of occurrence to intervention and their results in our patients.

**d) Clinical assessment** in the form of completeness of neurological injury, other associated injuries were studied in our patient population.

**e) Radiological assessment** with different imaging modalities- plain X-rays, Digital Xrays, C.T.scans and M.R.I.scans were done in our patients and studied. The level of injury, the type of injury, spinal instability scores, vertebral height reduction, antero-posterior spinal canal diameter, kyphotic angle measurements and

sagittal & coronal translational displacement were studied in the diagnosis, postop period and followup of our patients with traumatic thoracolumbar spinal injuries were studied in our patients.

**f) Operations performed**, operative time required, blood requirement, postoperative hospital stay were studied in our patient population.

**g) Analysis of the surgical results** by the following:

1. Clinical parameters: preoperative and postoperative early and in follow-up results according to Frankel clinical grading (Table-1).
2. Radiological parameters: preoperative and postoperative radiological results, level and type of vertebral fractures (Table-2), particularly spinal deformity (kyphosis) correction, antero-posterior spinal diameter correction at the level of the injury, vertebral height correction, stability of the spine and translation correction were assessed. Preoperative and postoperative spinal instability quantifications were done by scoring system of White and Panjabi criteria for spinal instability (Table-3).
3. Early, delayed and late complications of surgery were evaluated in our patient population. Moreover long term outcomes of management in our patients were studied as per Dennis pain score (Table-4); Dennis work score (Table-5) and implant failures were specifically reviewed in detail.

### **STUDY TECHNIQUES:**

Thoracolumbar spinal injuries have been defined in this study as fractures of D11, D12, L1 and L2 respectively. Admitted indoor patients with thoracolumbar spinal injuries were selected for this study.

### **Thoracolumbar Injury Occurrence:**

Occurrence of thoracolumbar injuries in our patient population was attempted to be calculated in this study. Percentage of the patients attending at our outdoors with thoracolumbar injuries, percentage of admitted patients with thoracolumbar injuries and percentage of thoracolumbar injuries operated to total operations performed in our institute in the department of Neurosurgery in the study period have recorded in this study and calculated thereof. Only 49 patients were selected and enrolled in the study proper after applications of inclusion and exclusion criteria and after obtaining thorough consent from the patients and their parties.

### **Age and Sex distribution:**

Age and sex distribution of our patient population were studied in details.

### **Time interval between injury and admission:**

Due to large volume of neurosurgical referrals in our institution and limited resources available, time interval between occurrence of injury and institutionalization was studied in this study, since they have direct impact on overall patient outcome.

### **Time interval between admission and operation:**

Time interval between admission and surgical intervention required was also evaluated in this study. This time interval was the time required to properly investigate the patient radiologically, make surgical planning, and get informed consent from patient and parties; as also the limited specialized operation theatre available to perform such surgeries. However this time interval also has direct impact on overall patient outcome.

### **Pre-operative clinical assessment:**

After admission to our institute, a detailed history and examination was carried out especially evaluating the mode of trauma, associated injuries, Frankel grading (Table-1), sensory level and any spinal deformity. Full neurological examination sensation, motor, anal tone, signs of sacral sparing etc. were done and documented repeatedly to look for and pick up neurological deficits and deteriorations.

### **Pre-operative radiological assessment:**

Plain X-rays, in anteroposterior and lateral views were obtained in all cases soon after the admission. Following which, CT scans and/ or MRI scans of the relevant area were performed with the intention of assessing the following in that particular case and for later comparison and evaluation:

1. Level of injury in the particular case.
2. Type of injury, as per McAfee & associates classification.
3. Vertebral body height measurement and assessment of percentage loss of height .
4. Anteroposterior spinal canal diameter measurement.
5. Kyphotic angle measurement.

6. Sagittal and coronal translation deformity as assessed by different imaging studies. Sagittal translation has been described as Listhesis and coronal translation as translational deformity respectively in this study.

**Spinal instability:**

Spinal instability of the injured spine was clinically and radiologically, confirmed and scored using White & Panjabi criteria of spinal instability (Table-3).

**Pre operative assessment:**

Basic preoperative workup for anaesthesia was done in all cases of the study. The goals for surgical treatment of spine fractures were decompression, realignment and stabilization. Factors such as age, associated injuries, comorbidities and the interval between time of injury and the time of treatment, were also considered.

**Surgical planning:**

Before final planning and case selection for surgery, transpedicular decompression and fixation, cases of this study were individually assessed by two neurosurgical consultants separately, to remove case selection bias in the study. Only those cases where both neurosurgical consultants agreed unanimously on posterior approach and transpedicular decompression, the case were finally selected for this study and surgery planned. Using plain radiographs, CT and/ or MRI as well as clinical assessment, the pedicle to be approached was selected. This was usually on the side with worse neurologic deficit. If the neurologic deficit was the same bilaterally or in patients with normal neurologic function, the side with more bony fragments or with larger degree of compression was selected. Surgical approach through a single pedicle was sufficient in most of the cases.

The opposite pedicle was attempted to be left intact for the purpose of additional instrumentation. The communication of the opposite pedicle was determined by preoperative CT scan. If there was laminar fracture, more extensive decompression was planned.

**Operations performed:**

Those patients with unstable spine selected for surgery were explained of pros and cons of the surgical treatment and proper consent taken. Patients willing for surgery and study inclusion were included. Single staged posterior transpedicular thoracolumbar vertebral body decompression through standard midline posterior thoracolumbar incision followed by segmental fixation by titanium pedicular screws and rod were done in all cases. Short segmental fixation was tried in maximum cases, however long segmental fixation was chosen in highly unstable spinal injuries, high kyphotic deformity and where preoperatively due to technical causes short segmental fixation could not be practically done.

**Surgical Technique:**

The patient was taken to the operating room and depending on the stability of fracture; patient was placed over rolls with the usual precautions. The usual posterior midline approach to the spine was made; the level of fracture and the pedicle to be decompressed were identified by an intraoperative lateral radiograph. The following are the usual technical sequence in our patients.

**1. Temporary reduction and stabilization:** The spine is temporarily stabilized on one side by short segment or long segment (as decided preoperatively) pedicular screws and rods, placed at least one level above and below the fractured segments. This was so done to prevent unnecessary motion during the decompression. Partial or complete reduction of the sagittal and coronal deformity was achieved during this stage. The opposite pedicle was always tried to be saved, so that it could be used for insertion of an additional screw for more stability.

**2. Removal of the pedicle:** The pedicle to be removed was identified at the junction of the superior articular process, lamina and transverse process. The transverse process is fully exposed. The entrance of the pedicle is removed by osteotome and a rongeur and the pedicle is probed. The lack of resistance at the fracture site is noted. The base of the transverse process is then osteotomized by removing the posterior cortex of the transverse process with a Leksell rongeur and then the anterior cortex using a Kerrison rongeur. Once the osteotomy is completed, the transverse process is left floating with its soft-tissue attachments. The direction of the pedicle is verified again using pedicle probe, and the lateral cortex of the pedicle is identified and removed using rongeurs. The medial and inferior wall is usually preserved. By staying next to the cortex, injury to the segmental vessels at the waist of the vertebral body was avoided and the nerve roots were also protected. It was often possible to preserve the inferior articular process and avoid damage to the facet joint. If however a more extensive posterior decompression was needed, the inferior articular process was also removed.

The cancellous bone of the pedicle is identified and gradually removed by enlarging the opening. Different forms of curettes were used to get access to the desired vertebral body. The medial and inferior cortices of the pedicle were usually left intact to protect the dura during this stage of procedure.

**3. Decancellization of the vertebral body:** Using specialized angled curettes, the cancellous bone anterior to the posterior cortex of the vertebral body and fragments were gradually removed to create space so the fragments could be reduced. These curettes were used with a rotary motion in two hands. The cup of the curette always moved away from the posterior cortex and the dura.

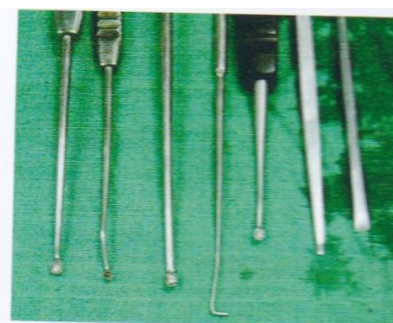**4. Removal of the disc and cleaning the endplates:** The disc curettes were used to clean the superior disc from the endplates. The disc material was removed by long handled rongeurs. When adequate space was created in the vertebra and the disc above was removed, then reduction and bone grafting was undertaken.

**5. Removal of the medial cortex of the pedicle and reduction of fragments:** If the medial cortex of the pedicle was not already fractured, it was removed from the superior margins using Kerrison rongeurs; if it was fractured, it was removed, through the fractured site. The lower portion of the pedicle was left intact except in more extensive approaches. The dura was exposed and protected. All the sharp edges of the bone were removed to protect the dura. A special curve elevator is passed between fragments and the dura to separate the fragments from the dura before the impactor is inserted. Because the space was already created anterior to the fragments, reduction was usually easy and the fragments were pushed anteriorly into the vertebral body using the special impactor.

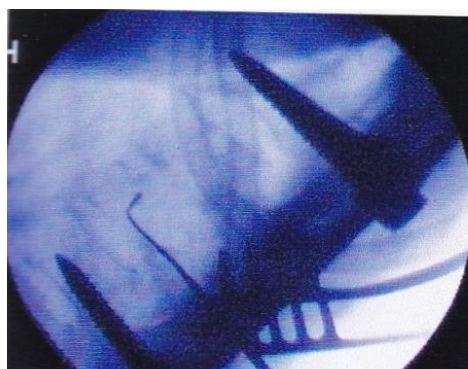
**6. Anterior grafting:** The anterior longitudinal ligament and annulus fibrosus were felt with a probe to detect any deficiencies. Small blocks of corticocancellous bone graft were then inserted from the opening of the pedicle to fill the disc space and to support the anterior column. The dura was inspected again for any possible compression. Bone fragments from the vertebral body were also impacted into the body and disc space away from the dura, which were inspected to ensure that no loose fragments were present.

**7. Completion of the instrumentation:** The decompression side was instrumented using desired sagittal contour and the implant on the opposite side is replaced and adjusted. Slight compression was applied between the two vertebrae to compress the grafts between them. Final tightening of the instrumentation was accomplished and additional grafting was applied posterolaterally. After completion of instrumentation, the dura and disc space were inspected again and alignment was confirmed by intraoperative radiograph.

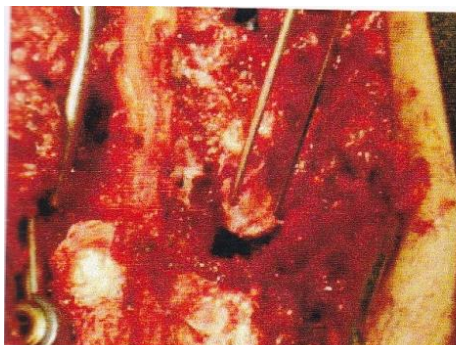During the procedure, the blood loss from the bone or epidural veins was controlled by bone wax, gel foam and thrombin; however, good exposure reduced the chance of uncontrollable blood loss. The small opening, especially on the lamina rather than the pedicle, did not allow access to the anterior bleeders. The adequacy of the decompression was assessed during the procedure by a special elevator. In addition to posterior fusion, a posterolateral facet arthrodesis using autogenous bone graft was essential to achieve fusion.



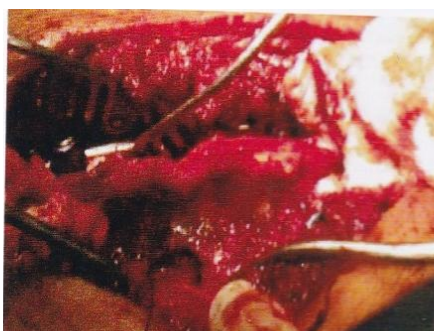The special instruments required for transpedicular decompression



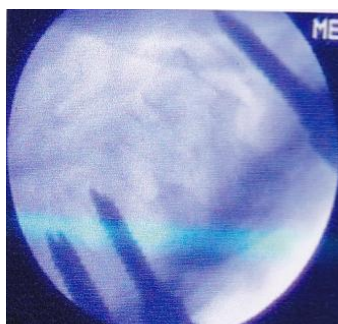The completeness of the transpedicular decompression is assessed by C-arm



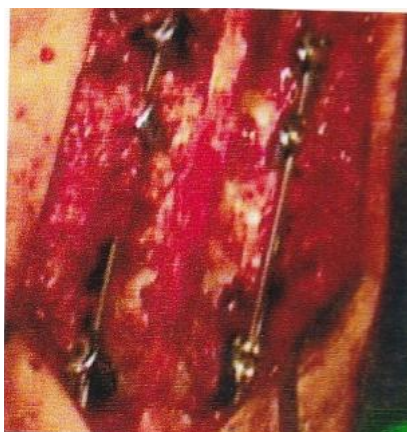
The decompressed vertebral body is packed with local bone grafts



The packed area is reassessed and packed local bone grafts hammered



The packed area is reassessed and completeness is assessed by C-arm



At the completion, the rods and the screws are tightened

**Operative time and Blood transfusions:**

In all cases of the study, the operation time was noted from the time of making the incision to closure of the surgical wound. The number of blood units required in individual cases of the study was also noted and studied.

**Post-operative period:**

Check X-rays were done after 3 days of operation. Thoracolumbar support was given to all the patients and aggressive physiotherapy was started after 3 days of operation to mobilize the patients early. The neurological status of the patients and any other early surgical complications were noted during the post-operative stay.

**Post-operative clinical assessment:**

During the post operative stay, neurological and clinical improvement/ deterioration as per Frankel's Grade was noted. Early postoperative complications were also enumerated and studied.

**Post-operative radiological assessment:**

Plain X-rays, in anteroposterior and lateral views were obtained all cases at 6 weeks, 3 months and thereafter in all subsequent follow-up visits. CT scans were done in a few cases for postoperative study, however MRI screening scans of only the relevant area were performed in all cases and assessment of the following were done systematically:

1. Vertebral body height measurement and assessment of the percentage correction in comparison to the preoperative studies.
2. Anteroposterior spinal canal diameter correction achieved in comparison to preoperative imaging.
3. Kyphotic angle correction achieved.
4. Sagittal and coronal translation deformity correction achieved.

**Surgical complications:**

Any or all surgical complications occurring in this study population were enumerated and studied, with special emphasis on hardware failure.

**Follow Up:**

Patients in this study were followed up at 6 weeks, 3 months, 6 months, 12 months. The neurological status of the patients as per Frankel's grade was recorded; any other complications were also noted. Particularly digital X-rays were done in all cases in each follow up visits and loss of kyphotic angle correction and loss of vertebral height correction were recorded and studied. MRI or CT scan was done only in those cases where new neurological symptoms, deterioration in previous neurological status or in cases of operative or implant failures were found.

**Long term outcome:**

Patients of this study group were evaluated for arthrodesis achieved at the injured vertebral body level. Moreover long term outcome was evaluated in this study by Dennis pain scale [22] and Dennis work scale [22]. Arthrodesis of the operated part, fusion within the body of the vertebrae were studied by radiological, X-rays (in all) and CT scan (in few cases) after completion of 1 year after surgery in the follow up.

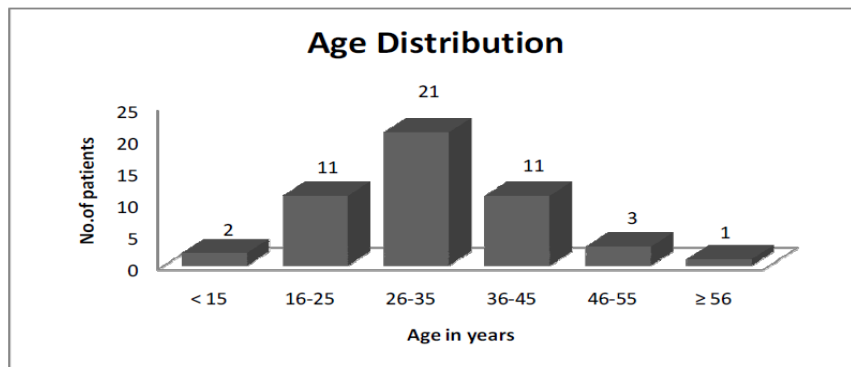
**Analysis & Results:**

**Thoraco-Lumbar Injury Occurrence:**

Total outdoor attendance in the 12 months span of study was 6518 cases approximately of which about 174 (2.66%) cases were of thoracolumbar spinal injuries in our institution. Neurologic injuries were present in only 72 (41.3%) cases of the 174 cases of the thoracolumbar spinal injuries. During this period 814 elective surgeries were undertaken in our institution, of which 72 cases (8.8%) of traumatic thoraco-lumbar spinal injuries were operated.

**Age distribution:**

In our 49 patients, youngest was of 12 years and eldest was 58 years old. Most of the patients (34, 69.3%) were in the age group of 20-40 years. The mean age of our patient population was 32 years, median 30 years and mode 32 years respectively.

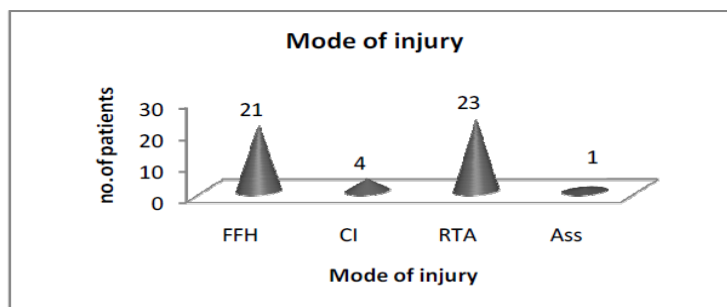


**Sex distribution:**

In our study there were 40 male patients and 9 female patients.

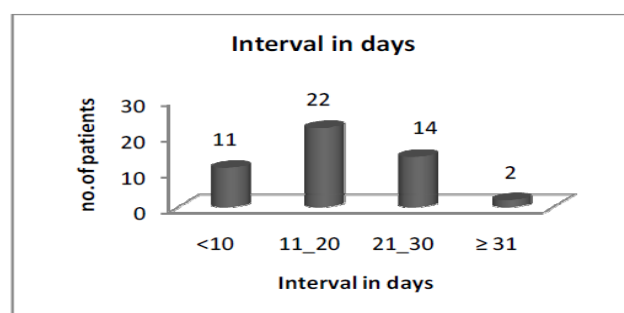
**Mode of Injury (MOI):**

Road traffic accident (RTA) was the most common cause of injury in our study, followed by accidental fall from height (FFH). Occupational injuries in the form of accidental fall of labours during work without the use of safety equipments was high in this study with 17(34.7%) patients. Caving-in (CI) of walls and ceiling over the patients was found in 4 cases and there was 1 case of assault (Ass) in this study.



**Interval between Injury and Operation:**

Our patients had a mean interval of 17 days between the incident of the injury and the definitive surgery. The least waiting interval was 6 days and maximum was 32 days respectively. The median and mode of the patient population on interval between occurrence of injury and surgery were 15 days.

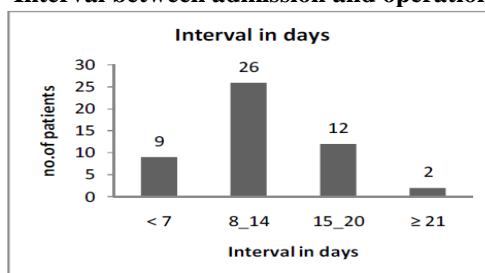


**Interval between admission and operation:**

This interval of time between our institutional indoor admission and the definitive operations performed were studied. This was the time required for the patients to be initially optimized and thoroughly investigated for their injuries, along with exclusion of other spinal and associated major injuries. The mean duration of interval of post admission waiting was 12.8 days, range being 6 days to 29 days, with median and modal duration of interval of indoor waiting was approximately 13 days. The graphic depiction of patient population is provided below.



**Interval between admission and operation**

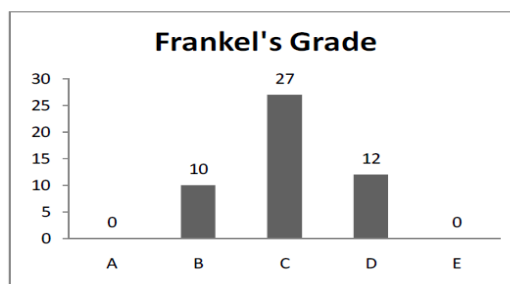


**Pre-operative clinical Assessment:**

**Frankel's Grading for completeness of injury:**

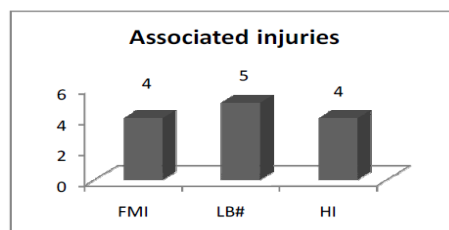
As has been detailed in materials and methods, pre-operatively all the patients in the study population were thoroughly assessed clinically and grading of the completeness of the spinal cord injuries were assessed as per Frankel's grading of all the patients. Patients with Frankel's grade A & E were not included in the study.

Frankel's Grading for completeness of injury		
Grade	Completeness of Spinal Cord injury	No. of patients
A	Complete (M-,S-)	Not included
B	Incomplete (S+,M-)	10(20.4%)
C	Incomplete (M<3 power)	27(55.1%)
D	Incomplete (M≥3 power)	12(24.5%)
E	Normal (S+,M+)	Not Included



**Associated injuries:**

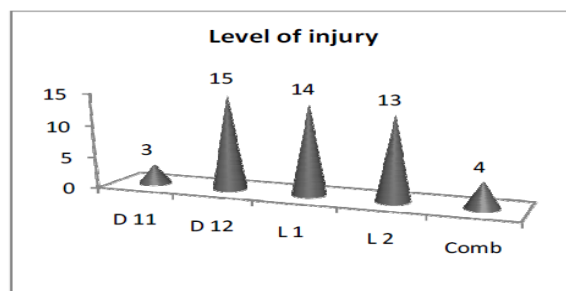
As already mentioned that the patients admitted with severe head injuries, major chest injuries, abdominal injuries, pelvic injuries & other major injuries which required major operative intervention and would have caused increased morbidity, mortality and altered outcome associated with thoracolumbar injuries were not included in the study. However, in the included 49 patients in the study, 13 patients had associated injuries of head injury(HI), facio-maxillary injuries(FMI) and long bone fractures(LB#).



All the patients enrolled in the study were subjected to plain X-rays/ Digital X-rays of the injured spinal segment in both antero-posterior and lateral views and MRI scans of the dorso-lumbar spine to assess neurological injuries. Pre-operative CT scans were done in only 25 selected cases, in whom pedicular disruption was to be evaluated or there was difficulty in radiological categorization of spinal vertebral fractures and measurement of kyphotic angle.

**Level of Thoraco-Lumbar spinal vertebral fracture:**

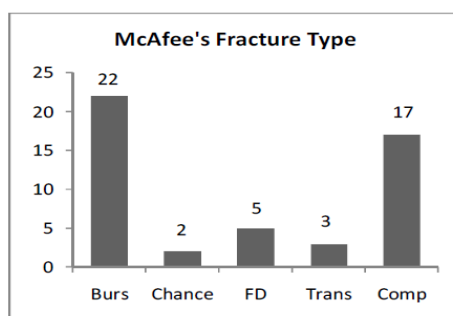
Out of 49 patients in this study, 45 (91.8%) had a single level bony injury and 4 (8.2%) patients had injuries at 2 consecutive bony levels. Of the combined injuries 2 patients had D11, D12 injuries and other 2 had D12, L1 injuries respectively.



**Type of vertebral injuries:**

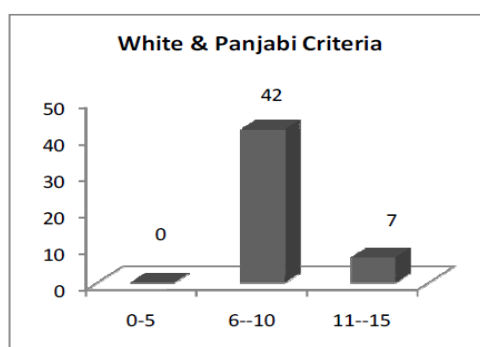
The types of vertebral body injuries in this study of 49 patients were classified as per McAfee classification of spinal injuries into 6 types. The classification and population distribution of the study is given below.

Type of spinal vertebral fracture	No. of patients
1 Wedge-Compression fracture	17 (34.8%)
2 Stable burst fracture	2 (4.1%)
3 Unstable burst fracture	20 (40.8%)
4 Chance injury	2 (4.1%)
5 Flexion-Distraction injury	5 (10.2%)
6 Translational Shear Injury	3 (6%)



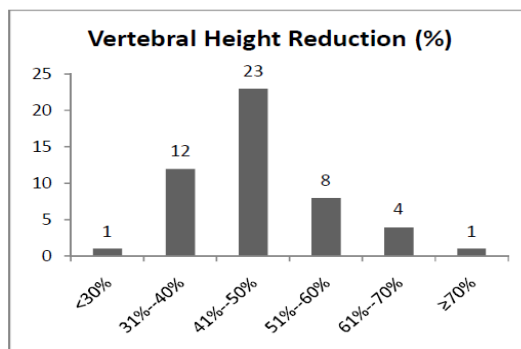
**Spinal instability assessment:**

All the 49 patients of the study were evaluated radiologically for spinal instability by the White & Panjabi criteria of spinal instability. In this study, a mean and median White & Panjabi score of 9 and a mode of 10 was evaluated respectively.



**Pre-operative vertebral height reduction:**

The patients were studied radiologically for assessment of vertebral body height. X-rays, CT scans and MRI scans were used to assess the percentage of reduction of vertebral height of the fractured spinal segment. A wide range of vertebral height reduction is found in our patients ranging from 29% to 74%, with a mean reduction of 47.5%, median of 45% and modal reduction of 50% respectively.



**Pre-operative spinal canal diameter:**

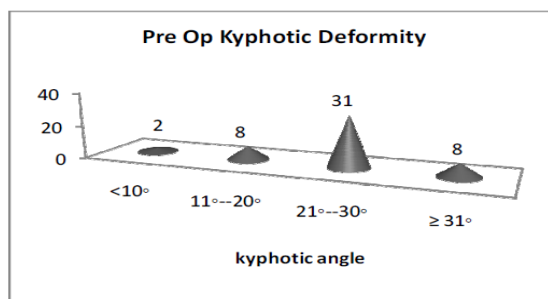
The pre-operative spinal canal antero-posterior diameter was studied radiologically in our patient population. The range varied from 2 mms to 10 mms. The mean AP diameter in our patient population was 5.6 mms, median of 5mms and mode of 4 mms respectively. The canal compromise was subdivided into 3 categories A, B and C as per the percentage of canal compromise, with AP diameter > 66.66%, 33.33% - 66.66% and < 33.33% respectively.

A.P.D. Reduction			No.s
<1/3 <sup>rd</sup>	>66.66%	A	6
>1/3 <sup>rd</sup> - <2/3 <sup>rd</sup>	33.33% - 66.66%	B	20
>2/3 <sup>rd</sup>	<33.33%	C	23

**Pre-operative kyphotic angle measurements:**

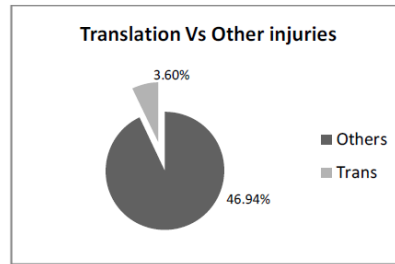
All the patients in the study were thoroughly evaluated for kyphotic angle at the injured spinal segment. Lateral view of digital X-rays and sagittal sections of MRI was used for measurement. However in case of discrepancies 3D CT reconstruction images were used for calculating the kyphotic angle.

In our study, the mean kyphotic angle was calculated to be 25.26°. the median kyphotic angle was 26° and the mode was 24°. The range of kyphotic deformity in 49 of our patients ranged from 8° to 36° respectively.



**Traumatic Listhesis and Translation:**

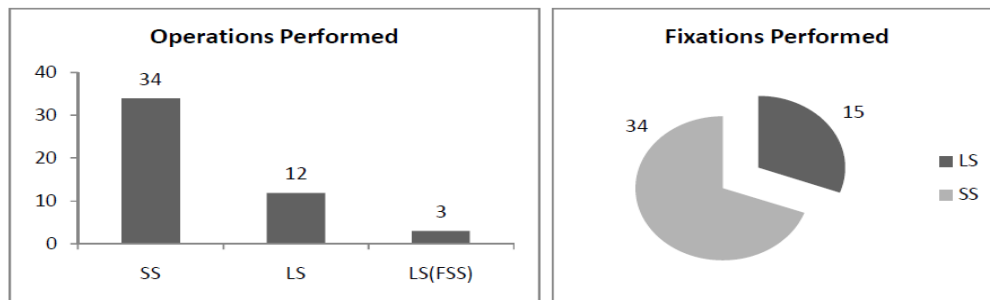
In this study, sagittal translational deformity was taken as spondylolisthesis and coronal translational deformity as translation. Out of 49 patients in the study, 2 (4%) patients had traumatic listhesis and 1 (2%) patient had traumatic translation of the vertebral bodies. This was likely so that almost all patients, except these three presenting with translational shear injuries during the study period had radiological and/or clinical complete transection of the spinal cord and hence were excluded from the study.



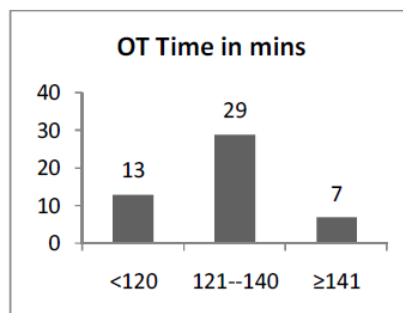
**Operations performed:**

Single staged posterior transpedicular thoracolumbar vertebral body decompression through standard midline posterior thoraco-lumbar incision followed by segmental fixation by titanium pedicular screws and rod was done in all cases. Short segmental fixation was done in maximum cases. Long segmental fixation was done only in highly unstable injuries, high kyphotic deformity and in cases where per-operatively due to technical causes, short segmental fixation could not be done.

Out of 49 patients, 34 cases underwent short segmental fixation (SS), 12 cases were opted for long segment fixation (LS) due to high instability score or high kyphotic deformity. In 3 cases per-operatively due to anatomical and technical reasons short segmental fixation could not be achieved, hence long segmental fixation [LS (FSS)] was done. However optimal transpedicular decompression was done in all cases followed by bone grafting of local bony tissue and iliac bone grafts.



In this study the time required for surgery was studied. The operative time was taken from incision to closure of the wound. The mean operating time in this study population was 129 minutes, median of 130 minutes and mode of 130 minutes respectively.



**Blood transfusions required:**

In this study all 49 patients required blood transfusions of 1 to 3 units preoperatively or postoperatively. The mean amount of blood transfusion required was 1.75 units (612 ml), while the median and mode of blood requirement was 2 units.

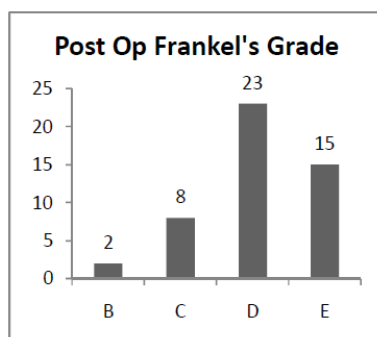
**Post-operative hospital stay:**

Post-operative hospital stay was analyzed. In our study population, post-operatively patients stayed for 6 days to 21 days. The mean post-operative hospital stay of our study population was 11.3 days, median and mode was 10days respectively.

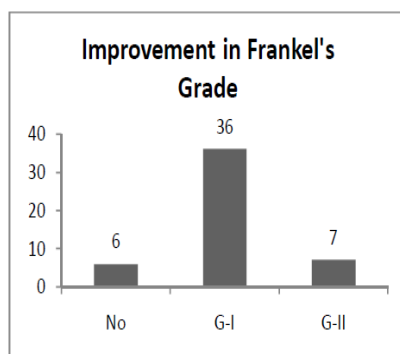
**SURGICAL OUTCOME**

**Early Post-Operative Frankel's Grade:**

Post operatively clinical improvement was again assessed by Frankel's grading system before discharge and at 6 weeks. The best grade of the patient achieved in this early postoperative period and up to 6 weeks was analyzed as early Frankel's grade improvement. 6 patients did not improve from their pre-operative Frankel's grade, all others improved by a range of 1 to 2 degrees in their early postoperative period. The mean improvement in grade was 1.02, median and mode of 1.

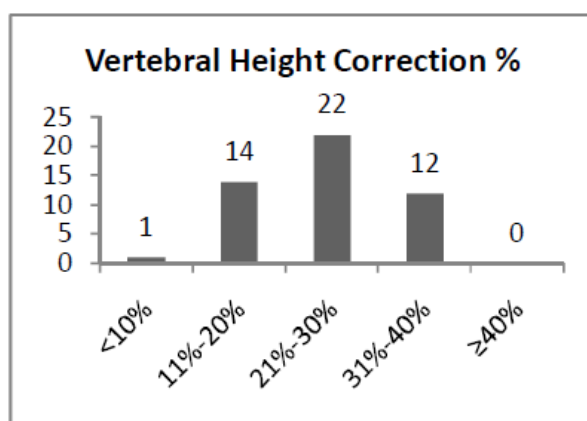


Improvement in grade by 1 was found in 36 patients of which 28 improved within first 15 days and other 8 patients by 3<sup>rd</sup> to 6<sup>th</sup> week post-operatively. 7 other patients improved by 2 grades post operatively of which 3 improved by first 15 days and the other 4 improved by 3<sup>rd</sup> to 6 weeks postoperatively.



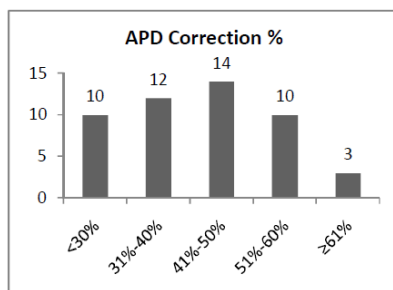
**Vertebral height correction:**

In our patient population post-operatively serial radiographs were performed. Initially on 3<sup>rd</sup> post-operative day check digital X-rays, both A.P and lateral views were done. Later serial X-rays were done at 6 weeks and then every 6 months. CT scan & MRI scans were done in selected cases where digital X-rays were not informative or contradictory. The average increased percentage of vertebral height was taken for analyzing outcome. The mean improvement in vertebral height postoperatively was by 24.5%, the range being from 9% to 38% respectively. The median and modal improvement in vertebral height was 24%.



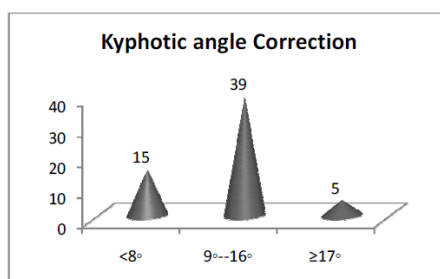
**Spinal canal diameter correction:**

Post operatively segmental CT scan and/ or MRI scan was done post operatively after 6 weeks to 3 months for measurement of corrected antero-posterior spinal canal diameter in our patient population. The mean increase of AP diameter was 41.27% with a wide range of 13% to 62% increase in AP diameter. The median and mode of AP diameter increase was 45% and 46% respectively in this study group.



**Kyphotic angle correction:**

Our patient population post-operatively was subjected to serial radiographs. Initially on 3<sup>rd</sup> post-operative day check digital X-rays, both AP and lateral views were done. Kyphotic angle correction was measured and calculated case wise and cumulatively presented in the graphics below. The minimum kyphotic angle correction was 3° and the maximum correction achieved was 18°, with mean correction of 11°.



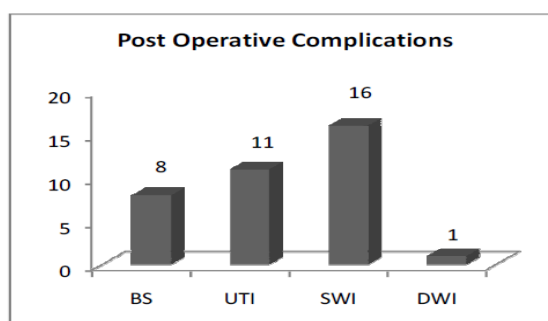
**Traumatic listhesis & Translation correction:**

Out of 3 patients with translational injuries in this series, the translational deformity was corrected successfully in all the 3 cases. Sagittal deformity correction was successfully achieved in 2 cases and coronal in 1 case respectively. However no improvement in postoperative Frankel's grade was noted in any of the 3 cases with translational injuries.

**Complications of surgical management:**

Out of 49 patients in this study,

Complications	Abb	No. of cases
Bed sore	BS	8 (16.3%)
Urinary tract infections	UTI	11 (22.45%)
Superficial wound infections	SWI	6 (12.25%)
Deep wound infections	DWI	1 (2%)

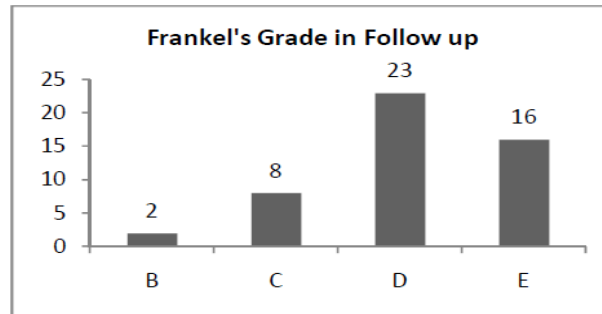


**Follow-up outcome:**

**Frankel's grading:**

Post-operatively, clinical improvement was again assessed by Frankel's grading system at 6 weeks, 3 months, 6months, 9 months and 1year. The best grade of the patient achieved in the follow up period was taken as final Frankel's grade. 6 patients did not improve from their pre-operative Frankel's grade, all the others improved.

At 3 months follow-up, 3 patients again improved by 1 grade, than their early post-operative period of 6 weeks. Thus the mean improvement in grade of this series was 1.08, median and mode of 1.

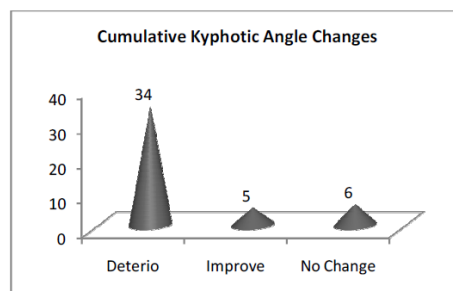


**Follow-up kyphotic angle:**

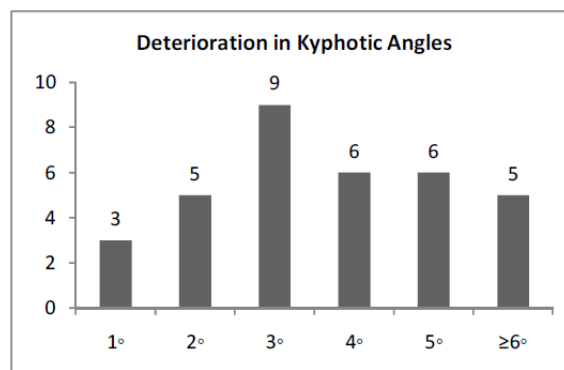
In our patient population of 49, only 45 came for regular follow-up post-operatively and were subjected to serial radiographs. CT and MRI scans were done in selected cases where digital X-rays were not informative or contradictory. Kyphotic angle changes, from early post-operative calculations were seen in 39 of our patients.

While 6 cases did not show any change in kyphotic angle between early postoperative period and follow-up. 34 of our patients showed deterioration of 1° to 10° than earlier kyphotic angles with a mean deterioration of 3.85°. While 5 cases showed improvement in kyphotic angles of 1° to 4°, with a mean improvement of 2.6°.

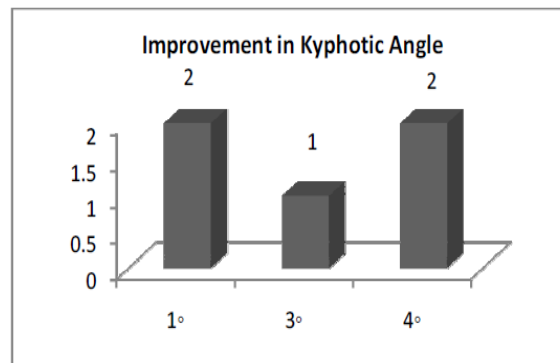
When cumulatively calculating the deterioration, improvement and no changes of kyphotic angle in follow-up periods, the mean was deterioration of 2.4°.



**Kyphotic deterioration graph ( n=34):**



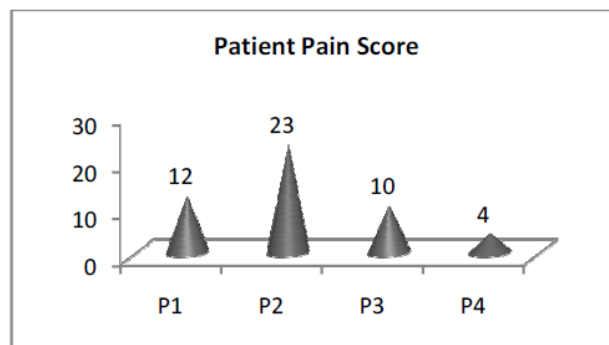
**Kyphotic improvement graph (n= 5):**



**Long term outcome:**

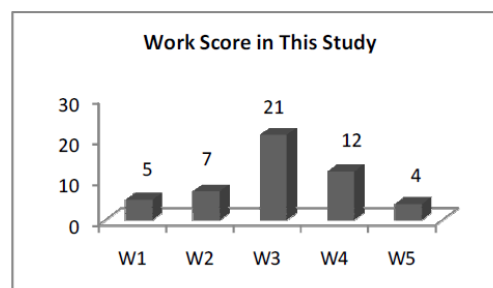
**Pain scoring:**

Post-operatively all the patients were assessed for local pain. The Dennis pain scale was used to assess the individual's pain score. The range of pain score as per Dennis scale was P1 to P4, with the mean of P2.



**Work scale:**

Post-operatively, all the patients of the study were assessed for functional capacity or work index. The Dennis work scale was used and the range of function was W1 to W5. The mean grade of work scale in this study was W3.



**Long term complications and mortality:**

In the long term follow-up of our patients post-operatively, only 1 (2%) patients showed hardware failure, in the form of slippage of rod and partial extrusion of one pedicular screw, 7 months after the operation. No other patient showed or as yet reported any hardware failure or any long term complications. Mortality in this study was found in only 1 (2%) case, 6 months after the operation due to development of bed sore, complicated with sepsis and multiorgan failure.

**Long term Arthrodesis:**

In our study population, in all the cases autogenous local bone was used as graft in all the cases and arthrodesis was studied by X-rays in 33 patients out of 49 cases at follow-up after 1 year of definitive surgery (the rest 16 cases have not completed 1 year of follow-up). Satisfactory arthrodesis was achieved in 31 of 33 patients (94%).



### III. Statistical Analysis Of Results

#### Statistical analysis of Age & Sex distribution:

Out of 40 patients in this study, statistical age range was 32.14+/- 10.12 years, actual range 12years to 58 years. 69.3% of our patients were in the productive age group of 20-40 years. There was male predominance in our patient population with 81.6% of male patients with Male to Female ratio of 4.5:1.

#### Analysis of Mode Of Injury:

Road traffic accidents(RTA) was the most common cause of injury in our study with 47%, followed by accidental fall from height(FFH) in 43% of cases.

#### Analysis of time intervals in our patients:

In our patient population, statistically calculated time interval between injury and definitive operation was 16.92+/- 7.23 days, actual range of 6-32 days. The median and mode of the patient population on interval between occurrence of injury and surgery was 15days.

Moreover, in our study, statistical time interval between admission and operation was 12.78+/- 5.53 days, actual range of 5-29 days. This interval represents the institutional resources available for patient optimization, investigations, availability of theatre and indirectly the overall patient load in our hospital.

#### STATISTICAL ANALYSIS OF CLINICAL ASSESSMENT AND RESULTS:

#### STATISTICAL ANALYSIS OF ASSOCIATED INJURIES:

Patients admitted with major associated injuries were excluded from the study proper. 26.5% of the study patients had associated injuries.

#### Statistical analysis of Frankel's grading and improvements:

Patients in this study presented with a mean Frankel's grade C, range B to D. statistical range of presentation was grade C/3 ( $3.04 \pm 0.68$ ). early post-operative results in this study, mean Frankel's grade was D, range B to E. Statistical early post-operative results mean Frankel's grade D/4; range  $4.08 \pm 0.81$ . At follow up statistical postoperative improvement, mean Frankel's grade D/4; range  $4.14 \pm 0.82$ . Frankel's grade improvement at early postoperative period was  $1.04 \pm 0.54$  scores, range 0-2 score. Followup post operative Frankel's grade improvement was  $1.10 \pm 0.51$  scores, range 0-2 scores. Application of paired t-test in these results appears to be statistically significant ( $p < 0.05$ ). details provided below.

Frankel's	Mean	Variance	N
Pre-op	3.04	0.456	49
Early post-op	4.08	0.666	49
Follow-up	4.14	0.667	49
Paired t-test values of pre-op and early post-op; $t = -13.53$ , $p = 5.342 \times 10^{-18}$ at 0.05 level, two means are statistically significant.			
Paired t-test values of pre-op and follow-up; $t = -15.123$ , $p = 6.918 \times 10^{-20}$ , at 0.05 level, two means are statistically significant.			

#### Statistical analysis of radiographic assessment and results:

#### Statistical analysis of level of thoraco-lumbar spinal vertebral fracture:

92% patients in this study had single level bony injury and the rest 8% had injuries at two consecutive levels. D12 fractures were most commonly found in 30% and L1 in 29% respectively.

#### Statistical analysis of type of vertebral injuries:

Burst fractures were the most common type of injuries with 45% followed by compression fractures in 35% respectively.

#### Statistical analysis of White & Panjabi criteria for spinal instability assessment:

In our study population, statistical WPC range was  $9.02 \pm 1.82$ , actual range 6-12. The median WPC score was 9 and mode of 10 respectively.

**Statistical analysis of vertebral height correction:**

The patients in this study group had post traumatic statistical vertebral height range of 47.51%± 10.11%, actual range of 29%-74%. The median post-traumatic vertebral height was 45%. Post-operatively the study population had statistical vertebral height range of 71.82± 6.32%, actual range of 60-86%, with median of 71% respectively. Statistically the vertebral height corrected, difference of post-traumatic vertebral height presentation and post procedural correction, on application of paired t-test was found to be significant(p<0.05). Details are provided below.

Vertebral height	Mean	Variance	N
Pre-op	47.51%	102.297	49
Post-op	71.82%	39.986	49
Paired t-test values of pre-op and post-op vertebral heights; t= -24.196, p= 1.5276E-28, at 0.05level, two means are statistically significant.			

In this study population, post-operative statistical vertebral height correction range was 24.10% ± 6.77%, actual range of correction 9%-37%, with statistical median correction of 23% respectively.

**Statistical analysis of spinal canal diameter correction:**

The pre-operative spinal canal diameter percentage range on statistical calculation was 14.86%± 16.83%, actual range 15%-71% and median canal spinal percentage was 36% respectively.

Post-operatively spinal canal diameter percentage after correction, range on statistical calculation was 82.51%± 7.2%, actual range of 66-100% and median spinal canal % was 83% respectively.

Statistically the spinal canal diameter corrected, difference of post-traumatic spinal canal percentage diameter on presentation and post procedural correction, on application of paired t-test was found to be significant(p<0.05). Details are provided below.

Spinal canal diameter	Mean	Variance	N
Pre-op	40.857%	283.167	49
Post-op	82.51%	51.880	49
Paired t-test values of pre-op and post-op spinal canal diameter; t= -20.543,p= 1.99621E-25, at 0.05 level, two means are statistically significant.			

In this study population, the post operative spinal canal diameter, statistical correction range was 41.26% ± 13.87%, actual range of correction 13%-62% with statistical median correction of 45% respectively.

**Statistical analysis of kyphotic angle correction:**

The patients in this study group had post traumatic kyphotic angle presentation, statistical range of 25.26°± 6.01°, actual range of 8°-36°. The median post traumatic kyphotic angle on presentation was 26°. Post-operatively the study population had statistical kyphotic angle range of 10.96° ± 3.84°, actual range of 3°-18° with median of 10° respectively. Statistically the kyphotic angle corrected, difference of post-traumatic kyphotic angle on presentation and post-procedural correction on application of paired t-test was found to be significant(p<0.05). details are provided below.

Kyphotic angle	Mean	Variance	N
Pre-op	25.26°	37.157	49
Post-op	10.96°	14.748	49
Paired t-test values of pre-op and post-op kyphotic angle; t=25.567, p=1.30713E-29, at 0.05 level, two means are statistically significant.			

In this study population, the post-operative statistical kyphotic angle correction range was 14.31°± 3.92°, actual range of correction 3°-23°, with statistical median correction of 15% respectively. Henceforth in this series the post-operative kyphotic angle correction achieved in percentage was, statistical range 56.64%± 10.15%, actual range of correction 33.33%- 78%, with statistical median correction achieved postoperatively was 57% respectively.

#### **Statistical analysis of follow-up of kyphotic angle:**

The study population in the post-operative followup after 3 months showed changes in kyphotic angle corrected. In majority there was deterioration in corrected kyphotic angle, however in some there was improvement in deformity. The post operative kyphotic angle correction loss at followup was, statistical range of loss was  $+2.62 \pm 2.89^\circ$ , actual range of kyphotic angle loss was  $-4^\circ$  to  $+10^\circ$  with statistical median kyphotic angle correction loss of  $+3^\circ$  respectively.

#### **Statistical analysis of traumatic listhesis and translation.**

Out of 49 patients in this study, 2 patients (4%) had sagittal and 1 patient (2%) had coronal traumatic translational of vertebral bodies. In all the 3 (100%) cases, translational deformity was radiologically corrected and maintained correction in the follow-up period. However none of the patients in this group showed any improvement in their post-operative Frankel's grade.

### **STATISTICAL ANALYSIS OF DEFINITIVE MANAGEMENT**

#### **Statistical analysis of operations performed**

Standard single staged posterior transpedicular thoraco-lumbar vertebral body decompression through standard midline posterior thoracolumbar incision followed by segmental fixation by titanium pedicular screws and rods was done in all cases. Short segmental fixation was done in 69.4% cases and long segmental fixation was done in 30.6% of the cases respectively.

#### **Statistical analysis of operating time**

The statistical operating time in this study was  $129.29 \pm 13.65$  mins with actual range of 100- 165 mins & median time of surgery was 130 mins respectively.

#### **Statistical analysis of Blood transfusions required**

The statistical blood transfusions required in this study was  $1.75 \pm 0.60$  units, with actual range of 1-3 units and median blood requirement of 2 units respectively.

#### **Statistical analysis of post-operative hospital stay**

Statistical post-operative hospital stay range was  $11.31 \pm 4.07$  days, actual range of 6-21 days and median of 10 days respectively.

#### **Statistical analysis of Dennis pain scoring**

The post-operative patients statistical Dennis pain score range was  $P2.12 \pm 0.88$ , actual range P1-P5 and statistical median of P2 respectively.

#### **Statistical analysis of Dennis work scale**

The post-operative patients statistical Dennis work scale range was  $W3.06 \pm 1.07$ , actual range W1-W5 and statistical median of W3 respectively.

## **IV. Discussion**

#### **Age and Sex Distribution:**

Thoracolumbar fractures are common in young males in US as a result of high velocity deceleration mechanism and occur most commonly in association with falls or motor vehicle accidents [23,24]. Out of 49 patients in this study, mean age was  $32.14 \pm 10.12$  years, actual range of 12-58 years. 69.3% of the patients were in the age group of 20-40 years. There was a male predominance in our patient population with Male to Female ratio of 4.5:1.

Khan et al. study of Pakistani earthquake victims [25] with thoracolumbar injuries managed with pedicular screws and rods had a range of 11-32 years (mean age of 21 years) with female to male ratio of 8.5:1. Butt and Farooq [26] in their study from Kashmir show an average age of the patients to be 33.6 years (range: 20-50 years), and there were 36 males and 14 female patients. Other studies from India [27], Korea [28] show similar asian epidemiological distribution.

#### **Mode of injury:**

Large kinetic energy is required to cause thoracolumbar injuries [29]. These patients are typically young males involved in high speed motor vehicle accidents. The transfer of axial loads through the transition from a rigid thoracic kyphosis to the mobile lumbar region results in a high incidence of thoracolumbar junction fractures. In the US [23,29] the most common mode of injury was road traffic accidents. Mavrogenis [30] reported in his study of 25 patients, 14 were due to RTA, 9 were due to fall from height and 2 cases were due to

suicide attempt. Butt [26] in his study of 50 patients, reported that fall from height usually a tree was the most common mode of injury. In our study, RTA was the most common cause of injury in 47% followed by fall from height in 43% of the cases. Various studies from India [31-33] have mainly documented, fall from height as the most common cause from rural India and traffic accidents common in urban India respectively.

#### **Time intervals:**

Baseer & Mahapatra [32] of AIIMS, Delhi India in their review of 94 cases concluded that greater fraction of the patients operated within 7 days showed improvement compared to those who were operated after 7 days, though it was statistically insignificant. Dashti and Lee [34] in their review article commented that in severely injured patients, early intervention in less than 72 hours, resulted in fewer complications, shorter hospital stay and reduced requirement for ventilation [35,36]. Dashti commented that there is considerable controversy with regards to the timing of the surgery in presence of neurological injury. Animal studies showed that early intervention had better results have failed to be proven in clinical setting in humans [34,35,36]. Studies relating to timing of surgical intervention are few and they relate to cervical cord injuries. Dashti felt that the timing of surgery depends on hospital logistical and resources issues. A skilled operative and anaesthesia team ready to perform the surgery was more important than any patient-related variable, except occurrence of neurological deterioration [34].

In our patient population, average time interval between injury and definitive operation was  $16.92 \pm 7.23$  days, actual range of 6-32 days. The median and mode was 15 days. Moreover in our study population, average time interval between admission and operation was  $12.78 \pm 5.53$  days, actual range of 5-29 days.

### **CLINICAL ASSESSMENT AND RESULTS**

#### **Associated Injuries:**

Patients with fall from height commonly have associated long extremities fractures [24]. Butt and Farooq [26] in their study of 25 patients, found associated injuries in 13 patients: 2 head injuries, 3 hemo- and/or pneumothoraces, 2 extremity fractures, 5 patients with rib, clavicle or facial bone fracture and one patient with intra-abdominal injury requiring laparotomy. In our study, patients with major associated injuries were excluded from the study proper, however 26.5% of the study patients had associated injuries of which extremity fractures were most common followed by facio-maxillary and head injuries.

#### **Clinical grading and improvements:**

Baseer and Mahapatra [32] in their retrospective analysis of 94 patients operated found majority had severe neurological deficits, with their pre-op mean Frankel's score being  $1.93 \pm 1.4$ . They commented that as shown with other studies pre-operative Frankel's score was the single most important factor in deciding the neurological outcome [37,38]. Their study [32] showed that almost all the patients with incomplete cord injury improved with time. The only factor which was significant in deciding the outcome was pre-operative Frankel's score, with almost all patients who had Frankel's of C, D or E showing improvement (P value 0.032) as shown by other studies as well [38,39]. Even in complete cord injury the incidence of complication due to immobilization of the patients were reduced dramatically with improved quality of life. Thus early surgery can help in rehabilitation and early mobilization of patients and thus prevent complications such as decubitus ulcers, chest infections and deep vein thrombosis etc. this also makes patients independent on others for their daily activities [32,34].

Sagwan et al.[33] in their study of 50 patients concluded that, the patients having incomplete lesions of the spinal cord i.e ASIA impairment scale B and above (C,D and E) showed neurological improvement by at least one or more grades, whereas in patients with complete lesion of the spinal cord, chances of neurological improvement were poor. In their study, the majority of the patients had severe neurological deficit (36 out of 50 i.e 72% of the total patients were evaluated as ASIA A). This explains a comparatively less number of patients with complete neurological recovery in our study (only 8% of the patients showed complete neurological recovery).

Patients in our present study group presented with average Frankel's grade C/3 ( $3.04 \pm 0.68$ ). early post-operative results (<6weeks) average Frankel's grade was D, range B to E.

Statistical early post-operative results mean Frankel's grade was D/4; range  $4.08 \pm 0.81$ . at followup (>3months) statistical postoperative improvement, mean Frankel's grade was D/4; range  $4.14 \pm 0.82$ . Thus in present study Frankel's grade improvement at early postoperative period was  $1.04 \pm 0.54$  scores, range of 0-2 score. Follow-up post operative Frankel's grade improvement was  $1.10 \pm 0.51$  scores, range 0-2 scores. Results were statistically significant ( $p < 0.05$ ).

Olumide [40] showed 0.4, 1.09 and 0.66 Frankel grade improvements with anterior, posterior and antero-posterior approaches respectively. Nadeem M et al [41] showed 0.9 Frankel grade improvement with one

year followup, while in the study of 19 patients Khan and Nadeem [25] had average improvement of 1.11 Frankel grade with similar one year followup.

It was important to note that Olumide [40] did not study paraplegic (Frankel A) patients whereas in Khan and Nadeem [25] series, 17 out of 19 patients (89.4%) were in Frankel A.

## **RADIOGRAPHIC ASSESSMENT AND RESULTS**

### **Level of Thoraco-Lumbar Spinal Vertebral fracture:**

Sangwan et al [33] in their study of 50 patients showed clustering of the spinal injuries at D12 or L1 level. Other studies [58,60,63,72] also show clustering of thoracolumbar trauma around D12 & L1. Weyns et al [42] showed 60% injuries over D12-L1, Viale et al [43] showed 55% and Carl et al [83] showed 82% of the injuries at D12-L1 junction. The increased affliction of the thoracolumbar junction in trauma can be due to more than one specific reason. Firstly this is the most mobile segment compared to any other segment.

Shetty et al [31] in their study of thoracolumbar trauma of 37 patients found 19 (51.4%) patients had D12-L1 injuries. In our study 92% of the patients had single level fracture and the rest 8% had injuries at two consecutive bony levels. D12 fractures were commonly found in 30% and L1 in 29% respectively of our study population.

### **Type of vertebral injuries:**

Khan et al. [25] used McAfee's classification of thoracolumbar injuries in their study of 19 earthquake affected victims of Pakistan. They found that the wedge compression was the commonest in 11 patients (58%) where as fracture subluxation was seen in 2 patients (10.5%). There were 4 burst fractures (21%), 2 translational injuries (10.5%) and no distraction injuries. Baser et al [32] in their study of 94 patients found common type of fractures as compression and burst fractures both accounting for 26 (27.7%) each. There were 7 cases of spondyloptosis. On MRI 28 patients (29.8%) showed complete cord transection. Another 43 (45%) showed cord signal changes with 23(24.3%) showing normal cord.

Arif et al [44] in their study of 76 patients used Dennis classification of fractures. The four major types of fractures were compression fractures 56(73.6%), burst fractures 12(15.78%), flexion-distraction injuries 4(5.26%) and fracture dislocations 4(5.26%). In our present study burst fractures were the most common type of injury with 45% followed by compression fractures 35% respectively.

### **Vertebral height correction:**

Arif et al [44] in their study of 76 patients reported their patients vertebral body height ranged from 6mm to 13mm in the pre-operative period. Post operatively the vertebral body height ranged from 18 to 22 mm (mean 15mm) which was almost the same as neighboring vertebra. There was significant difference between preoperative and immediate post operative values. Mallik and Singh et al [45] in their study of 40 cases opined, the anterior vertebral body height calculated from the preoperative and post operative lateral radiograph and 100% of their patients had improvement after surgery. No patient had decrease in vertebral height at follow-up. The mean pre-operative height was 61.60% whereas postoperative mean height was 71.56%. They could achieve solid fusion in 90% of the operated patients.

In this study posttraumatic average vertebral height range of  $47.51\% \pm 10.11\%$ , Range of 29%-74%. The median posttraumatic vertebral height was 45%. Postoperatively the study population had average vertebral height range of  $71.82\% \pm 6.32\%$ , range of 60-86%, with median of 71% respectively. In this study population, the postoperative vertebral height correction range was  $24.10\% \pm 6.77\%$ , actual range of correction 9% -37%, with median correction of 23% respectively.

### **Spinal canal diameter correction:**

Butt et al [26] in their study of 50 patients concluded that the average pre-operative vertebral height was 44.7%, which improved to 72% in the immediate post-operative period. The loss of vertebral body height averaged 3.0% at the final followup. Mavrogenis et al [30] in their study found canal compromise improved to  $15.3 \pm 7.8\%$ .

In this present study, the average pre-operative spinal canal diameter percentage was  $40.86\% \pm 16.83\%$ , range 15%-71% and median spinal canal percentage was 36% respectively. Post operatively average spinal canal diameter percentage after correction was  $82.51\% \pm 7.2\%$ , range of 66%-100% and median spinal canal diameter was 83% respectively. In this study population, the average postoperative spinal canal diameter (APD) was  $41.26\% \pm 13.87\%$ , range 13%-62%, with statistical median correction of 45% respectively.

### **Kyphotic angle correction and loss:**

Sangwan et al [33] found the Moss Miami spinal implant system satisfactory in obviating the deformity and maintaining the achieved correction. The average correction of 16° was achieved and there was average loss of 2° in 6 months follow-up in their study of 50 cases. Sagwaan et al [33] in their study opined that the progression of kyphosis by only 2° in the post-operative period may be due to delayed ambulation of their patients and use of braces, thus allowing for proper spinal stabilization and fracture consolidation. In a study Esses et al [46] had the average pre-operative kyphotic angle of 18.2° and the average post-operative angle of 3.5°, Carl et al [47] reported average improvement of 7.3° in kyphosis postoperatively and average loss of correction of 6.5° at followup, and thus only 1° of correction was attained. A study by McNamara et al [48] showed the average progression of kyphosis by 8.7° in the operated cases from post-operative period to the final followup. Arif et al [44] in their study of 76 patients found the mean kyphotic angle was 27° preoperatively. Immediately after surgery, the correction of kyphosis averaged 7° which was the same at final follow-up. The sagittal index of the fractured vertebra ranged from 12° to 36° in the pre-operative period (mean:8°) and from 5° to 20° (mean:12°) at the final evaluation one year after surgery. In another study [49] the correction of kyphosis was 98% averaged post-operatively while in Arif et al [44] study correction of kyphosis was 92% average. Helton et al [50] had observed that the sagittal index of the fractured vertebra improved from 8° to 32° (mean 20°) during the pre-operative period to 3° to 25° (mean 14°) in the immediate post-operative period.

Butt et al [26] in their study of 50 patients had the average pre-operative kyphotic angle of 21.48° which improved to 12.86° in the immediate post-operative period. The loss of kyphotic angle correction averaged 3.46° in long term follow-up.

In this study average post-traumatic kyphotic angle was  $25.26 \pm 6.09^\circ$ , range of 8°-36°, median of 26° respectively. Postoperatively the study population had an average kyphotic angle of  $10.96 \pm 3.84^\circ$ , range of 3°-18°, with a median of 10° respectively. In this study the post operative average kyphotic angle correction was  $14.31 \pm 3.92^\circ$ , range of correction 3°- 23°, with median correction of 15° respectively. In this study the post-operative kyphotic angle correction loss at followup was, of average  $+2.62 \pm 2.89^\circ$ , range of kyphotic angle loss was -4° to +10°, with statistical median kyphotic angle correction loss of +3° respectively.

## **V. Definitive Management**

### **Surgical Management:**

The management of fractures in thoracolumbar region is a controversial subject. Disadvantages of conservative management include deterioration of neurological status in 17% of the patients, progressive kyphotic deformity in 20%, persistent back ache, decubitus ulcer and deep vein thrombosis. Most of these complications can be avoided by early mobilization and decreased hospital stay by early surgery [58].

Decompressive laminectomy has fallen out of favour as a treatment option in thoracolumbar spine injuries as it does not relieve primary compression and also further increases instability. The damage to the already oedematous cord may be worsened during the procedure [58,59,60]. The anterior approach provides excellent visualization of thoracolumbar vertebral body. However the procedure is associated with some morbidity and entails venturing into areas not routinely accessed by neurosurgeons. Stabilization through the anterior approach requires use of stabilization devices which are expensive. The transpedicular approach allows for vertebral body decompression, fusion and fixation through a single area of access with minimal morbidity. The functional recovery seen with this procedure are comparable with other procedures [55,56,57].

The transpedicular approach however does have certain drawbacks. Decompression is a tedious process and there is a possibility of the compression fragment being left behind. Shetty et al [31] from India tried to overcome this by using a flexible fiber optic nasal endoscope to directly visualize the fragments. They had some success with this technique. However bleeding from the bone may limit visibility in some cases. They also found the transpedicular decompression and fixation difficult in injuries above the 10<sup>th</sup> thoracic vertebrae. In lesions above this level they used the anterior approach for decompression and fixation.

In 1992, Lemons et al [39] claimed that compared with spinal instrumentation alone, transpedicular decompression showed no benefit in terms of post-operative canal dimensions or neurological outcome. On the basis of this experience, transpedicular decompression offers no advantage over spinal instrumentation alone [39].

Baseer et al [32] in their study of 94 patients, majority of them (76) were approached posteriorly. Eighteen patients were operated through anterolateral approach. Seven patients were operated through minimally invasive percutaneous screw and rod placement. Short segment fixation was done in 61 patients whereas in 33 patients long segment fixation was done. Synthetic graft was used in 42 patients and autologous bone graft was used in the remaining 45 for fusion. Both anterior and posterior column fusion was done in 20 patients.

AIIMS in their study also showed that there was no correlation of outcome with the surgical approach (anterior or posterior) as also pre-operative methyl prednisolone, other systemic injury or hypotension [32].

In our present study transpedicular decompression of fractured segment followed by short segmental fixation was done in 69.4% cases and long segmental fixation was done in 30.6% cases respectively. Satisfactory decompression was achieved in all cases.

Bony fusion was achieved in 18/19 (95%) of the cases in Khan et al [25] series, whereas Sasso [61] had reported a 95.6% arthrodesis rate with dynamic compression plates and pedicle screws in 23 patients. Sengupta et al [62] showed similar fusion rates with iliac crest or local bone in a single level fusion but less morbidity in case of local bone. We also used autogenous local bone as graft in all the cases and in our series arthrodesis was achieved in 31 of 33 patients (94%).

#### **Post operative complications:**

Basheer et al [32] in their retrospective review of 94 cases, the most common complication was chest infection (14%). Wound infection was present in 6%, three patients developed sepsis with multiorgan dysfunction syndrome. Three patients died in peri-operative period, two of them had severe chest infection with sepsis and other one had associated head injury. Four patients had construct failure with screw pullout and had to be operated again. Sangwan et al [33] in their study of 50 cases reported faulty screw placement in 6 cases, nut loosening in 4, implant pull out in 2, bursitis over implant in 3 and loss of correction in 6 cases. 4 patients had developed bed sores, 6 had urinary tract infection and 2 patients developed periurethral fistula.

A number of complications have been reported for transpedicular spinal fixation. Blumenthal et al [63] noted an overall complication rate of 6% with the Wiltse pedicle screw system.

In our study the most common post-operative complication was UTI in 11(22.5%) cases, 8(16.3%) cases developed pressure sores, 7 developed wound infections- managed conservatively. In 1 (2%) case there was hardware failure, in the form of screw loosening and rod pullout after 8 months after surgery, which required second surgery for fixation of screw and rod. 1 (2%) patient died, 6 months after the operation due to development of bed sore complicated with sepsis and multiorgan failure.

#### **Declaration and Drawbacks of the study:**

In the present study, the small number of patients and the lack of control group may be considered a limitation. In addition, we did not control for the use of different implant manufacturers and implants design and neurological improvement of the patients was not related to the specific type of fracture, patient's age, body mass and comorbidities also may affect the validity and reproducibility of our results. Nonetheless, surgery technique was strictly controlled and there was no potential selection bias in regard to fracture type and level of decompression. Our incidence of neurological improvement and post-operative kyphotic deformity is consistent with other published series [65-67] and represents a valid finding. Furthermore, the purpose of this study was not to evaluate outcome of the patients with a specific thoracolumbar fracture type, but to evaluate the effect of posterior transpedicular decompression on neurological improvement of these patients with unstable thoracolumbar spinal fractures.

### **VI. Summary and Conclusions**

- G.G.H, Guntur is the tertiary care referral center for Neurosurgery in Guntur district of Andhra Pradesh. 2.66% of the total outdoor attending patients during the study period had thoraco-lumbar injuries; of these 41.3% of the cases had neurological deficit. During the study period 8.8% of the elective surgeries were undertaken for traumatic thoraco-lumbar injuries in our institution.
- Out of 49 patients in the study, average age was  $32.14 \pm 10.12$  years, range 12-58 years. 69.3% of the study patients were in the productive age group of 20-40 years. There was male predominance with 81.6% male patients, with male to female ratio of 4.5:1.
- In our patients, road traffic accidents (RTA) was the most common cause of injury in 47%, followed by accidental fall from height in 43% of the cases.
- Time interval between injury and definitive operation in our patients, was  $16.92 \pm 7.23$  days, range of 6-32 days. The study population had average time interval between admission and operation of  $12.78 \pm 5.53$  days, range of 5-29 days. This interval represented our institutional resources available for these selected patients, as also time for optimization, investigations and availability of theatre and indirectly the overall patient load in our hospital.
- Any major associated injuries with thoracolumbar fractures were excluded from this study. However 26.5% of the selected patient population had associated injuries in this study, of which long bone fractures, facio-maxillary injuries and head injuries were common.
- Average clinical presentation of our patients in this study was Frankel's grade C/3 ( $3.04 \pm 0.68$ ), with a mean of grade C and range B to D. Early post-operative (6weeks to 3months) results in this study was, mean Frankel's grade of D, range B to E. Statistical early postoperative average result was Frankel's grade D/4; range  $4.08 \pm 0.81$ .

- At follow up (>3months) statistical improvement was mean Frankel's grade was D/4; range  $4.14 \pm 0.82$ .
- Frankel's grade of improvement at early post-operative period (6weeks to 3 months) in this study was  $1.04 \pm 0.54$  scores, range of 0-2 score. Follow up (>3months) Frankel's grade improvement was  $1.10 \pm 0.51$  scores, range 0-2 scores. This was found to be statistically significant ( $p < 0.05$ ).
- 92% of our patients in this study had single vertebral level bony injury and the rest 8% had consecutive two bony level injuries. D12 fractures were most common in 30% and L1 in 29% respectively in this study. Burst fractures were the most common type of injury with 45% followed by compression fractures 35% respectively. In our study population mean WPC instability score (White & Panjabi instability criteria) was  $9.02 \pm 1.82$ , actual range 6-12.
- The patients in this study group had post-traumatic vertebral height average of  $47.51\% \pm 10.11\%$ , actual range of 29%-74%. The median post-traumatic vertebral height was 45%. Postoperatively the study population had an average vertebral height of  $72.82\% \pm 6.32\%$ , actual range of 60%-86%, with a median of 71% respectively. The vertebral height corrected was found to be statistically significant ( $p < 0.05$ ). Henceforth in our study, the postoperative mean vertebral height correction attained was  $24.10\% \pm 6.77\%$ , actual range of correction 9%-37%, with statistical median of 23% respectively.
- The pre-operative average compromised spinal canal diameter percentage on presentation was  $40.86\% \pm 16.83\%$ , range 15%-71% and median spinal canal percentage was 36% respectively. Post operative average corrected spinal canal diameter percentage was  $82.51\% \pm 7.2\%$ , range of 66%-100% and median spinal canal percentage was 83% respectively. Statistically the spinal canal diameter corrected was found to be significant ( $p < 0.05$ ). Henceforth in this study population, the post-operative spinal canal diameter (APD), statistical correction range was  $41.26\% \pm 13.87\%$ , actual range 13%-62%, with a median correction of 45% respectively.
- The patients in this study group had average post-traumatic kyphotic angle on presentation as  $25.26^\circ \pm 6.09^\circ$ , range of  $8^\circ$ - $36^\circ$  and median of  $26^\circ$  respectively. Postoperatively the study population had statistical kyphotic angle range of  $10.96^\circ \pm 3.84^\circ$ , actual range of  $3^\circ$ - $18^\circ$ , with a median of  $10^\circ$  respectively. Correction was found to be statistically significant ( $p < 0.05$ ). Henceforth in this study, the post-operative kyphotic angle correction attained was  $14.31^\circ \pm 3.92^\circ$ , range of correction  $3^\circ$ - $23^\circ$  and median correction of  $15^\circ$  respectively. Thus the postoperative kyphotic angle correction achieved in percentage was, an average of  $56.64\% \pm 10.15\%$ , range of 33.33%-78% and median of 57% respectively. The study population in the post-operative follow up after 3 months showed, changes in kyphotic angle corrected. In majority (78%), there was deterioration in the corrected kyphotic angle. The post operative average kyphotic angle correction loss at follow up was  $+2.62^\circ \pm 2.89^\circ$ , range of kyphotic angle loss was  $-4^\circ$  to  $+10^\circ$ , with median of  $3^\circ$  respectively.
- Out of 49 patients in this series, 2 (4%) patients had sagittal and 1 (2%) patient had coronal traumatic translation of vertebral bodies. In all the 3 (100%) cases, translational deformity was radiologically corrected and maintained in the follow up period. However there was no clinical improvement in these cases.
- Single staged posterior transpedicular thoraco-lumbar vertebral body decompression through standard midline posterior thoraco-lumbar incision followed by segmental fixation by titanium pedicular screws and rod was done in all the cases. Short segmental fixation was done in 69.4% of cases and long segmental fixation was done in 30.6% of cases respectively. The average operating time was  $129.29 \pm 13.65$  minutes, range of 100-165 minutes and median of 130 minutes respectively. The average blood transfusions required in this series were  $1.75 \pm 0.60$  units, range of 1 to 3 units and a median of 2 units respectively.
- Post-operative hospital stay average was  $11.31 \pm 4.07$  days, range of 6-21 days and a median of 10 days respectively.
- The post-operative patient's mean Dennis pain score was  $P2.12 \pm 0.88$ , range P1-P5 and a median of P2 respectively. The post-operative patient's mean Dennis work scale was  $W3.06 \pm 1.07$ , range W1-W5 and a median of W3 respectively.

### **Conclusion:**

Posterior transpedicular spinal canal decompression and instrumentation is a reasonable alternative technique to anterior decompression procedures and circumferential fusion, providing for satisfactory spinal canal decompression and neurological improvement.



**Table-1: Frankel grading for completeness of injury [19]**

GRADE	NEUROLOGICAL STATUS
A	Complete (no sensory or motor function is preserved)
B	Incomplete (Sensory, but no motor function is preserved below the neurological level)
C	Incomplete (Motor function is preserved below the neurological level and the majority of the key muscles below the neurological level have a muscle power grade of < 3)
D	Incomplete (Motor function is preserved below the neurological level, and the majority of key muscles below the neurological level have a muscle power grade of ≥ 3)
E	Normal (sensory & motor function is normal)

**Table 2: McAfee and Associates classification of spinal vertebral injuries [20]**

	Types of spinal vertebral fractures
1	Wedge – Compression fracture
2	Stable Burst fracture
3	Unstable Burst fracture
4	Chance injury
5	Flexion Distraction injury
6	Translational Shear injury

**Table-3: White & Panjabi criteria of spinal instability [21]**

Condition	Points assigned
Loss of integrity of anterior(and middle) column	2
Loss of integrity of posterior column(s)	2
Acute resting translational deformity	2
Acute resting angulation deformity	2
Acute dynamic translation deformity exaggeration	2
Neural element injury	3
Acute disk narrowing at level of suspected pathology	1
Dangerous loading anticipated	1

A score of 5 points or more implies the presence of instability

**Table – 4: Dennis Pain Scale [22]**

P1	No pain
P2	Occasional minimal pain; no need for medication
P3	Moderate pain, occasionally medications required no interruption of work or activities of daily living
P4	Moderate to severe pain, occasionally absent from work; significant changes in the activities of daily living
P5	Constant, severe pain; chronic pain medications

**Table – 5: Dennis Work Scale [22]**

W1	Return to previous employment (heavy labor) or physically demanding activities
W2	Able to return to previous employment (sedentary) or return to heavy labor with restrictions
W3	Unable to return to previous employment but works full time at new job
W4	Unable to return to full time work
W5	No work, completely disabled.

### References

- [1]. Kewalramani LS, Taylor RG. Multiple Non-Contiguous Injuries to the Spine Acta Orthop Scand 1976; 47:52-8
- [2]. Henderson RL, Reid DC, Saboe LA. Multiple Noncontiguous Spine Fractures. Spine 1991; 16:128-31.
- [3]. N Basheer, Deepak Gupta, GD Sathyarthi, Deepak Aggarwal, S Sinha, BS Sharma, AK Mahapatra Unstable dorsolumbar fractures: A prospective series of 94 cases Department of Neurosurgery, JPNA Trauma Centre, AIIMS, New Delhi. Indian Journal of Neurotrauma (UNT), Vol.7, No. 1, 2010; 56-59.
- [4]. Saboe LA, Reid DC, Davis LA, Warren SA, Grace MG. Spine Trauma and Associated Injuries. J Trauma 1991; 31:43-8
- [5]. Holdsworth F. Fractures, Dislocations, and Fracture-Dislocations of the Spine. J Bone Joint Surg Am 1970; 52:1534-51.
- [6]. Hassan Dashti, Haw Chou Lee, Eldin E Karaikovic, Robert W. Gaines Jr Decision making in dorsolumbar fractures. Neurology India 2005; 53:Issue 4.
- [7]. Denis F. The Three Column Spine and Its Significance in the Classification of Acute Thoracolumbar Spinal Injuries. Spine 1983; 8:817-31.
- [8]. Leventhal MR. Fractures, dislocation and fracture dislocation of spine. In AH Crenshaw (Ed.): Campbell's Operative Orthopaedics, Vol.5 St, Louis Mos by year book Inc1992.pp.3517-82
- [9]. Steffe AD, Biscup RS. Sitkowski DJ. Segmental spine plates with pedicle screw fixation A new internal fixation device for disorder of lumber and thoracolumbar spine. Clin Orthop 1986, 203:-45-53
- [10]. Danisa OA, Shaffrey CI, Jane JA, Whitehill R, Wang G), Szabo TA, et al Surgical approaches for the correction of unstable thoracolumbar burst fractures: a retrospective analysis of treatment outcomes. J Neurosurg 1995;83:977-83
- [11]. Shafiq K, Iqbal M, Hameed A, Mian JM. Role of transpedicular fixation in thoracolumbar spinal injuries. Neurol Surg 1998;1:21-7
- [12]. Sar C, Bilen FE. Flexion was more painful than extension. Thoracolumbar flexion distraction injuries combined with vertebral body fractures. Am J Orthop 2002,31:147-51.
- [13]. Wesley AC, William TH. Injuries to thoracic and lumbar spine. In: Wilkins RH, Rengachary SS, editors. Neurosurgery. 2nd ed. New York: McGraw- Hill; 1996.p 2987-95.
- [14]. Shafiq K, Ahmed M, Rehman A, Abrar S, Mian JM. Management of unstable lower thoracic and lumbar spine with transpedicular fixation. Ann KE Med Coll 1999,5:303-7.
- [15]. Erickson D.L., Hancock D.O. Brown W.E. et al.: One stage decompression, stabilisation for thoraco-lumbar fractures. Spine 1977 2: 53-56
- [16]. Frankel H.L., Hancock D.O., Hyslop G. et al: The value of postural reduction in the initial management of closed spine injuries with paraplegia and tetraplegia. Paraplegia 1969; 7: 179-192.
- [17]. Jelsma R.K., Rice J.F., Jelsma L.F. et al: The demonstration and significance of neural compression after spinal surgery. Surg. Neurology 1982; 18: 79-92.
- [18]. Cook W.A. Jr., Hardaker W.T. Jr.: Injuries to the thoracic and lumbar spine. In Wilkins R.H., Rengachary s.s. (eds), Neurosurgery Vol I McGraw Hill, 1996. pp 2987- 2995.
- [19]. Frankel HL, Hancock DO, Hyslop G, Melzak J, Michaelis Ls, Ungar GH, et al. The value of postural reductions in the initial management of closed injuries of spine with paraplegia and tetraplegia. Paraplegia 1969;7:179-92.
- [20]. McAfee PC, Yuan HA et al. the value of CT in thoracolumbar fractures: an analysis of 100 cases and a new classification. J Bone Joint Surg 65A: 461-473, 1983.
- [21]. White AA, Panjabi MM: Clinical Biomechanics of the spine. Edition 4, Philadelphia, JB Lippincott, 1978.
- [22]. Denis F, Armstrong GWD, Seals K, Matta L. Acute thoracolumbar burst fractures in the absence of neurological deficit: A comparison between operative and non-operative treatment. Clin Orthop 1984; 189: 142 - 149.
- [23]. James S. Harrop, Alexander R. Vaccaro, Kevin T. Foley, Iain Kalfas: Trauma Surgery: Thoracic & Thoracolumbar Spine: Chapter 45; The Text Book of Spine Surgery, Third Edition, Edited by Keith H Bridwell & R.L. DeWald. Lippincott-Raven Publishers, Philadelphia: 2005.
- [24]. Ryan J, Vaccaro AR, Kwon BK Thoracolumbar Trauma Chapter 319 page 3233- 3249: Youmans Neurological Surgery 6 Ed; edited by H. Richard Winn 2011, publisher Elsevier Saunders.
- [25]. Inayatullah Khan, Muhammad Nadeem et al. Dept of Neurosurgery, Shifa International Hospital, Islamabad, Pakistan. Thoracolumbar Junction injuries & their management with Pedicle Screws J Ayub Med Coll Abnottabad; 19(4) 7.
- [26]. Mohammad F. Butt, Munir Farooq et al. Kashmir India; Management of unstable thoracolumbar spinal injuries by posterior short segment spinal fixation: Int Orthop. 2007 April; 31(2): 259-264.
- [27]. N Basheer, Deepak Gupta, AK Mahapatra et al. Dept of Neurosurgery, JPNA Trauma Centre, AIIMS, New Delhi. Unstable dorsolumbar fractures: A prospective series of 94 cases Indian Journal of Neurotrauma (LUNT) Vol. 7, No. 1, 2010
- [28]. Deuk Soo Jun, Chang Hun Yu et al. Incheon, Korea: Posterior Direct Decompression and Fusion of the Lower Thoracic and Lumbar Fractures with Neurological Deficit; Asian Spine Journal Vol. 5, No. 3, pp 146-154,2011.
- [29]. Hu R, Mustard CA, Burns C: Epidemiology of incident spinal fractures in a complete population. Spine 21(4): 492-499, 1996
- [30]. Andreas Mavrogenis, Haridimos Tsidakidis et al. Dept of Ortho Athens Greece Posterior Transpedicular Decompression for Thoracolumbar Burst Fractures, Folia Med (Plovdiv) 2010 Oct-Dec;52(4):39-47
- [31]. Arjun Shetty, Ireshanava Neurosurgeon Tejasvini Hospital, Mangalore India. Transpedicular Approach To Dorso-Lumbar Spine Injuries J.Orthopaedics 2007;4(2)e8
- [32]. N Basheer, Deepak Gupta, AK Mahapatra et al. Dept of Neurosurgery, JPNA Trauma Centre, AIIMS, New Delhi. Unstable dorsolumbar fractures: A prospective series of 94 cases Indian Journal of Neurotrauma (LUNT) Vol. 7, No. 1, 2010 56

- [33]. SS Sangwan, R Singh et al. Department of Orthopaedics, Physical Medicine and Paraplegia, Pt. B.D. Sharma PGIMS, Rohtak, Haryana, India Role of Moss Miami Spinal System in Traumatic Unstable Thoracolumbar Spine: a study of 50 cases: *Ann Neurosurg.*, 2008; 8: 1-6.
- [34]. Dashti, Haw Chou Lee, Eldin E Karaikovic, Robert W. Gaines Jr. Decision making in dorsolumbar fractures. *Neurology India* 2005; 53:Issue 4.
- [35]. Chipman JG, Deuser WE, Beilman GJ. Early Surgery for Thoracolumbar Spine Injuries Decreases Complications. *J Trauma* 2004;56:52-7.
- [36]. Dai LY, Yao wF, Cui YM, hou Q. Thoracolumbar Fractures in Patients With Multiple Injuries: Diagnosis and Treatment-a Review of 147 Cases. *J Trauma* 2004;56:348- 352
- [37]. Alvine GF, Swain JM, Asher MA, Burton DC. Treatment of thoracolumbar burst fractures with variable screw placement or Isola instrumentation and arthrodesis: Case series and literature review. *J Spinal Disord Tech* 2004; 17:251-64.
- [38]. Gertzbein SD. Spine update. Classification of thoracic and lumbar fractures. *Spine* 1994; 19:626-8.
- [39]. Lemons VR, VanBuren R. et al. Management of thoracolumbar fractures with accompanying neurological injury. *Neurosurgery* 1992; 30(5):667-71.
- [40]. Olumide AD, Christopher IS, John AJ. Surgical approaches for the correction of unstable thoracolumbar burst fractures: a retrospective analysis of treatment outcomes. *Neurosurg* 1995;83:977-83.
- [41]. Nadeem M, Ghani E, Zaidi GL, Rehman L, Noman MA, Khaliqz- Zaman. Role of fixateur interne in thoracolumbar junction injuries. *J Coll Physicians Surg Pak.* 2003;13(10):584-7
- [42]. Weyns F. Neurological outcome after surgery for thoracolumbar fractures *Eur Spine* 1994; 3: 276-81.
- [43]. Viale GL, Silvestro C, Francoviglia N, Casta F, Bragazzi R, Bernucci C, MaieilioM. Transpedicular decompression and stabilization of burst fractures of the lumbar spine. *Surg Neurol* 1993; 40: 104 -11
- [44]. Mohammad Arif, Mohammad Inam et al. Department of Orthopaedics, Hayatabad Medical Complex Peshawar, Pakistan: Management of Thoracolumbar Spinal Fractures by Pedicular Screws and Rods: *Gomal Journal of Medical Sciences* July-December 2009, Vol. 7, No. 2: 109-112.
- [45]. Farid H Malik, Manjeet Singh, MA Basit, Siddhartha Sharma, Agnivesh Tikoo, Dara Singh A Comparative Study of Management of Thoracolumbar Spine Injuries with Neurological Deficit by Steffee Plating and Conservative Method *J K Science journal* Vol. 12 No. 3, July- September 2010.
- [46]. Esses SI, Botsford DJ, Kostwik JP. Evaluation of surgical treatment for burst fractures. *Spine* 1990, 15(7):667-73
- [47]. Carl AL, Tromanhauser SG, Roger DJ. Pedicle screw instrumentation for burst fractures and fracture - dislocations. *Spine* 1992; 17(8S):317-24.
- [48]. McNamara M, Stephans GC, Spengler DM. Transpedicular short-segment fusions for treatment of lumbar burst fractures. *J Spinal Disord* 1992; 5(2): 183-7
- [49]. Thomas KC, Bailey CS, Dvorak MF, Fisher KB. Comparison of operative and nonoperative treatment for thoracolumbar burst fractures in patients without neurological deficit: a systematic review. *J Neurosurg Spine* 2006; 4:351-8
- [50]. Helton LA, Defino Fabiano RTC. Low thoracic and lumbar burst fractures radiographic and functional outcomes *Eur Spine J* 2007 16:1934-1943.
- [51]. Rehtine GR II, Cahill D, Chrin AM. Treatment of thoracolumbar trauma: comparison of complications of operative versus nonoperative treatment. *J Spinal Disord* 1999; 12:406-9
- [52]. Hitchon PW, Torner JC. Recumbency in thoracolumbar fractures. *Neurosurg Clin N Am* 1997; 8:509-17.
- [53]. Hitchon PW, Torner JC, Haddad SF, Follett KA. Management options in thoracolumbar burst fractures. *Surg Neurol* 1998; 49: 619-27
- [54]. Rehtine GR II, Cahill D, Chrin AM. Treatment of thoracolumbar trauma: comparison of complications of operative versus nonoperative treatment. *J Spinal Disord* 1999; 12:406-9.
- [55]. Frankel H.L., Hancock D.O., Hyslop G. et al: The value of postural reduction in the initial management of closed spine injuries with paraplegia and tetraplegia. *Paraplegia* 1969; 7: 179-192.
- [56]. Benzel E.C., Larsen S.J.: Functional recovery after decompressive operation for thoracic and lumbar spine fractures. *Neurosurgery* 1986 19: 772-778.
- [57]. Jelsma R.K., Kirsh P.T., Jelsma L.F. et al: Surgical treatment of thoracolumbar fractures. *Surg. Neurology* 1982 18:156-166.
- [58]. Hashimoto T, Kaneda K: Relationship between traumatic spinal canal stenosis & neurologic deficits in thoracolumbar burst fractures. *Spine* 13: 1268-1272, 1988.
- [59]. Vaccaro A, Baron E, Sanfilippo J, et al. Reliability of a novel classification system for thoracolumbar injuries: the Thoracolumbar Injury Severity Score. *Spine.* 2006;31(11 suppl):S62-S69; discussion S104.
- [60]. Harrop J, Vaccaro A, Hurlbert R, et al. Intrarater and interrater reliability and validity in the assessment of the mechanism of injury and integrity of the posterior ligamentous complex: a novel injury severity scoring system for thoracolumbar injuries. Invited submission from the Joint Section Meeting on Disorders of the Spine and Peripheral Nerves, March 2005 *Neurosurg Spine*, 2006;4: 118-122.
- [61]. Sasso RC, Cotler HB, Reuben JD. Posterior fixation of thoracic and lumbar spine fractures using DC plates and pedicle screws. *Spine* 1991,16(3 Suppl):S134-9
- [62]. Sengupta DK, Truumees E, Patel CK, Kazmierczak C, Hughes B, Elders G et al. Outcome of local bone versus autogenous iliac crest bone graft in the instrumented posterolateral fusion of the lumbar spine. *Spine* 2006;31(9):985-91
- [63]. Blumenthal S. Gill K. Complications of the Wiltse Pedicle fixation system. *Spine* 1993; 18(13): 1867-71
- [64]. Wood K, Bohn D, Mehbod A. Anterior versus posterior treatment of stable thoracolumbar burst fractures without neurologic deficit: A prospective, randomized study, *J Spinal Disord Tech* 2005,18:15-23
- [65]. Andress HJ, Braun H, Helmberger T, et al. Long-term results after posterior fixation of thoraco-lumbar burst fractures. *Injury* 2002,33(4):357-65
- [66]. Triantafylou SJ, Gertzbein SD. Flexion distraction injuries of the thoracolumbar spine: a review. *Orthopedics* 1992; 15(3):357-64

Chanumolu Praveen. "A Clinical Study of Single Stage Postero-Lateral Transpedicular Ecompression with Screw Rod Fixation in Traumatic Thoraco-Lumbar Spinal Injuries." *IOSR Journal of Dental and Medical Sciences (IOSR-JDMS)*, vol. 18, no. 1, 2019, pp 09-35.