

## Adenoid Cystic Carcinoma of the External Auditory Canal Mimicking Granuloma- A Case Report

<sup>1</sup>Dr. U. C. Dutta, <sup>2</sup>Dr. Shamim Ahmed, <sup>3</sup>Dr.M.L.A.Rahman

1. Director, Laboratory & Blood Bank (Author for correspondence), 2. Senior consultant (ENT), 3. Medical Director

Rahman Hospitals Pvt. Ltd. Vip Road, Six Mile, Khanapara, Guwahati, Assam, India Pin: 781022

Corresponding Author: Dr. U. C. Dutta

**Abstract:** Malignant tumours of external auditory canal are rare, adenoid cystic carcinoma is being of the rarest of these tumours. Due to its unusual clinical presentation, unpredictable behavior and perineural invasion it is of utmost importance to detect the tumour early which will save the precious life of a patient.

We present here a case of young female (28 years old) with left external auditory canal mass which was initially suspected as granuloma, postoperative biopsy and Immunohistochemistry confirmed it as Adenoid cystic carcinoma of the EAC which is a rare case in the literature.

**Keywords:** Adenoid cystic carcinoma; External auditory canal; Parotid, perineural

Date of Submission: 16-01-2019

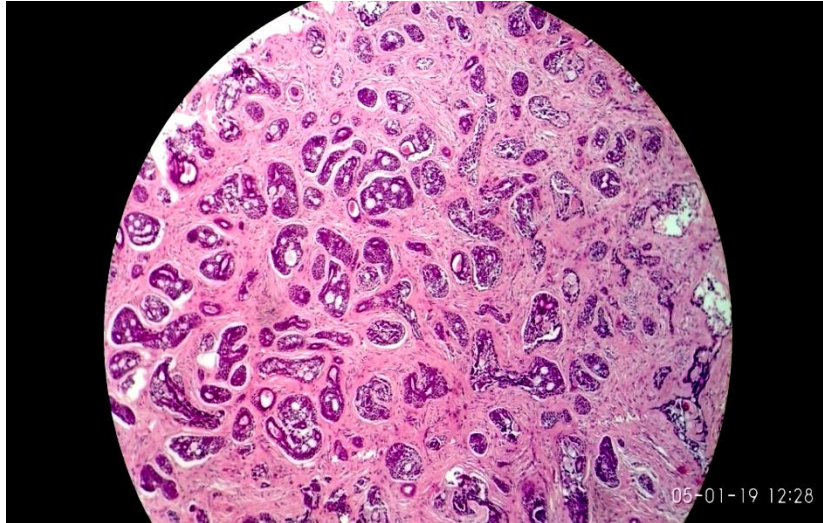
Date of acceptance: 31-01-2019

### I. Introduction

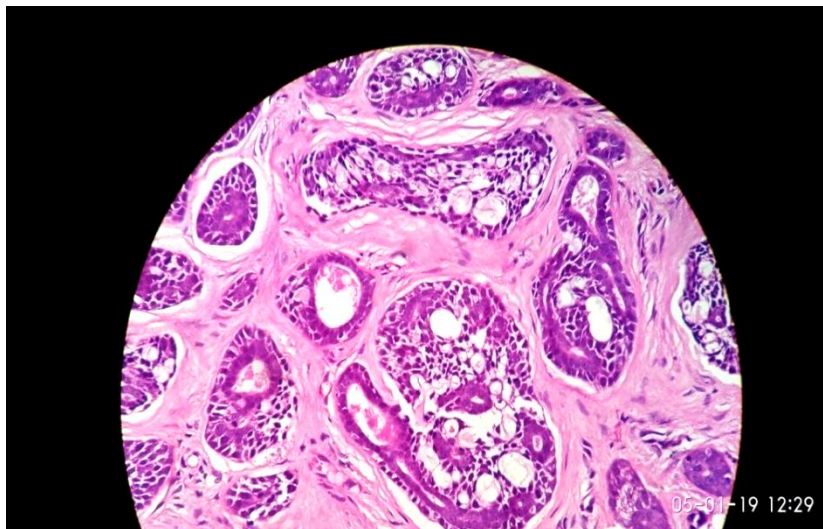
Tumours are unusual in the ear, more so in the external ear where most of the neoplasms observed are those of the covering skin. Only the ceruminous glands are peculiar to the external ear, but ceruminous tumours are also very rare. Adenoid cystic carcinoma is a malignant tumour of ceruminous gland and clinically mimics many inflammatory conditions like granuloma, benign tumours and malignant tumours. The tumour needs early detection, proper evaluation and complete treatment because of its unpredictable behaviour, tendency to recur and variable response to treatment modalities.

Case Presentation:

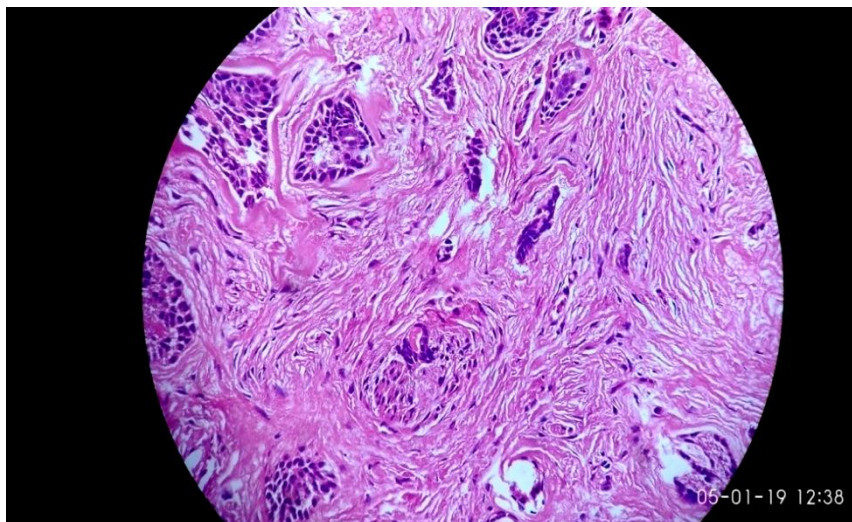
A 28-year-old female patient presented to ENT OPD of our hospital with left external auditory canal swelling associated with itching and on & off and ear ache without ear discharges for a duration of 1 year. Clinical examination revealed that the mass was occupying the outer one third of the external auditory canal and causing partial obstruction. There was no evidence of hearing loss. The case was clinically diagnosed as granuloma and subjected to excision biopsy. Operative findings revealed an oedematous granulation tissue measuring 5 x 8 x 11 mm which was originating from the posterior wall of the left external auditory canal, without any evidence of erosion of bone or regional lymph node enlargement. The findings were suggestive of an inflammatory etiology possibly granuloma. CT scan showed a faintly enhancing mass lesion was appearing from the posterior wall of the left external auditory canal, there were no erosion of bone and no involvement of regional lymph node. Two small tissue fragments were received by the histopathology laboratory which were processed by FFPE technique and stained by H&E stain. Microscopically, the tumor was composed of basaloid cells arranged in a cribriform architecture (Figure 1 & 2). Occasional Solid areas were noted at places. Perineural invasion was identified in this case with small groups of neoplastic cells invading perineural space [Figure 3]. Immunohistochemistry showed CK5/6 immuno- reactivity score - 1+, P63 score - 1+, S100 score - 1+, KI score - 3+ in neoplastic cells and CD117 score - 4+ in neoplastic luminal cells. Membranous positivity in the inner ductal cells was observed in (CK7 immunohistochemistry). These findings confirmed the diagnosis of Adenoid cystic carcinoma of the External ear with perineural invasion.



**Figure1:** Neoplastic cells with characteristic cribriform architecture (Hematoxylin & Eosin, original magnification X200).



**Figure 2:** Higher magnification showing characteristic cribriform pattern (Hematoxylin & Eosin, original magnification X400).



**Figure 3:** Perineural invasion- tumor cells are infiltrating a nerve (Hematoxylin-Eosin, original magnification X200).

## II. Discussion

Adenoid Cystic Carcinomas has been described as unusual tumours of the external ear by WHO [1]. This case of ACC involving a 28 year old female is apparently one of the rare cases of North East India. In fact, ear has not been cited as one of the leading sites of cancer of the North East India [2]. The tumour has a male predominance; it is slow growing, indolent but aggressive. Recurrences are frequent, often late and difficult to predict. Lymph node metastasis is rare. 5 year survival is 60%, 10 year is 30%, 15 year is 15% [10].

Generally, the common clinical manifestations of Adenoid Cystic Carcinoma include otorrhea, regular pain, hearing loss and bleeding [3]. There was no discharge or bleeding in our case. The pain is attributable to perineural involvement. Earlier reports clearly show that female in their forties and fifties are more prone to the ACC [4, 5], our case being on the lower side of median age. The histogenesis of ACC is stated to be from the ceruminous glands of external ear and the tumour is grouped with Adenocarcinoma and Mucoepidermoid carcinoma of the external ear by World Health Organization. Ceruminous glands located in the external ear and this has been confirmed by immunohistochemical and electron microscopic studies [1, 3, 6]. In some cases, the tumor may have arisen in the adjacent parotid salivary gland and secondarily may have extended into the ear canal [7, 8, 13]. In our case that mass was occupying the concha and extended to the outer one third of the external auditory canal and causing partial obstruction of the canal. There was no evidence of involvement of the Parotid gland or nearby bony tissue. CT scan showed a faintly enhancing mass lesion was appearing from the posterior wall of the left external auditory canal, there were no erosion of bone and no involvement of regional lymph node. Clinically, the findings were suggestive of an inflammatory etiology- possibly a granuloma. Histologically the tumour presents with Cribriform, solid or tubular pattern similar to cylindroma of skin. Small bland myoepithelial cells with scant cytoplasm and dark compact angular nuclei surround pseudoglandular spaces with PAS+ excess basement membrane material and mucin along with Peripheral perineural invasion and small true glandular lumina. There is usually no squamous differentiation and no extensive necrosis [9].

Histological findings of the lesion was consistent with adenoid cystic carcinoma with tumor composed of basaloid cells arranged in cribriform architecture and were infiltrated to adipose tissues. ACC is stated to be the second most common tumor associated to perineural invasion after squamous cells carcinoma [10]. Frequent perineural invasion was observed in the present case which is a classical characteristic and diagnostically helpful feature of adenoid cystic carcinoma [11, 12]. Immunohistochemistry showed CK5/6 immunoreactivity score - 1+ , P63 score - 1+, S100 score - 1+, KI score - 3+ in neoplastic cells and CD117 score - 4+ in neoplastic luminal cells. Membranous positivity in the inner ductal cells was observed in (CK7 immunohistochemistry). These findings confirmed the diagnosis of Adenoid cystic carcinoma of the External ear with perineural invasion [Figure 3].

## III. Conclusion

We report here a rare case of Adenoid Cystic Carcinoma of External Auditory Canal in a 28 years old female. Initial, Clinical and CT findings were suggestive of an inflammatory mass but histopathology and Immunohistochemistry examination confirmed the mass as tumor with features of adenoid cystic carcinoma. The patient underwent to radical excision of the tumor. Postsurgical recovery was uneventful. Due to its unpredictable behaviour, early detection of adenoid cystic carcinoma of the external auditory canal and its differentiation from other benign conditions should be emphasized even if the lesion may look inflammatory or benign clinically.

Consent form- Written informed Consent was obtained from the patient for the publication of this case report including the images.

Ethical approval - This study was approved by the Ethical committee of the Rahman Hospitals Pvt. Ltd.

Author's contribution: - 1. Dr. Shamim Ahmed: Performed clinical examination & carried out surgical procedures, 2. Dr.U.C.Dutta: Diagnosed the tumour, Designed and Collected data from relevant literatures & text books and prepared the manuscript for publication, 3. Dr.M.L.A.Rahman: supervised the study and rendered valuable guidance.

Conflict of interest: There is no conflict of interest.

Acknowledgement: The authors are thankful to Dr. (Mrs.) T. A. Rahman, CMD, Rahman Hospitals Pvt. Ltd. for giving permission to publish the article.

## References

- [1]. Seethala R R, Stenman G Update from the 4th Edition of the World Health Organization Classification of Head and Neck Tumours: Tumors of the Salivary Gland. *Head and Neck Pathol* . 2017 ; 11:55–67
- [2]. Sharma JD, Katakai AC , Barman D, Sharma A, Kalita M. Cancer statistics in Kamrup urban district: Incidence and mortality in 2007–2011. *Indian Journal of cancer*. 2016 ; 53 (4) 600-606
- [3]. Faisal D Adenoid Cystic Carcinoma of the External Auditory Canal "Rare Case Report. *Glob J Oto* . 2016 ; 1: 555-567.

*Adenoid Cystic Carcinoma of The External Auditory Canal Mimicking Granuloma- A Case Report*

- [4]. Almuhanha K, Alfulajj A Adenoid cystic carcinoma of the external auditory- A Case Report. Arch Otolaryngol Rhinol .2018; 4(1): 023-026
- [5]. Liua S –C , et al. Adenoid cystic carcinoma of the external auditory canal. Journal of the Chinese Medical Association. 2012 ; 75: 296- 300.
- [6]. Dong F, Gidley PW, Ho T, Luna MA, Ginsberg LE, et al. Adenoid cystic Carcinoma of the external auditory canal. Laryngoscope. 2008 ; 118: 1591-1596.
- [7]. Bhagat S, Varshney S, Bist SS, Mishra S, Aggarwal V Case Report: Adenoid Cystic Carcinoma of External Auditory Canal. Online J Health Allied Scs. 2012 ; 11:
- [8]. Fliss DM, Kraus M, Tovi F Adenoid cystic carcinoma of the external auditory canal. Ear Nose Throat J . 1990 ; 69: 63545.
- [9]. Handra-Luca A, Salivary gland Epithelial / myoepithelial tumors: Adenoid cystic carcinoma. PathologyOutlines.com, Inc. Revised: March 2018
- [10]. Hicks GW Tumours arising from the glandular structures of the external auditory canal. Laryngoscope. 1983; 93: 326-340.
- [11]. Balamucki CJ, Amdur RJ, Werning JW, et al. Adenoid cystic carcinoma of the head and neck. Am J Otolaryngol. 2012; 33: 510–518.
- [12]. Perzin KH, Gullane P, Conley J Adenoid cystic carcinoma of external auditory canal. A clinicopathological study of 16 cases. Cancer 1982 ;50: 2873- 2883.

Dr. U. C. Dutta. “Adenoid Cystic Carcinoma of The External Auditory Canal Mimicking Granuloma- A Case Report.” IOSR Journal of Dental and Medical Sciences (IOSR-JDMS), vol. 18, no. 1, 2019, pp 01-04.