

A Case Series of Giant Cell Tumor of Tendon Sheath

Dr. Ramesh Kumar Korumilli¹, Dr Muvva Sri Harsha², Dr Kanmathareddy Amulya³, Dr Srikanth Jakkula⁴, Dr V Madhuri⁵

¹(Professor and HOD, General surgery, SVS Medical college, Dr KNR university of Health sciences, INDIA)

²(Post-Graduates of General Surgery, SVS Medical college, Dr KNR university of Health sciences, INDIA)

³(Post-Graduates of General Surgery, SVS Medical college, Dr KNR university of Health sciences, INDIA)

⁴(Post-Graduates of General Surgery, SVS Medical college, Dr KNR university of Health sciences, INDIA)

⁵(Assistant professor, General Surgery, SVS Medical college, Dr KNR university of health sciences, INDIA)

Corresponding Author: Dr. Ramesh Kumar Korumilli

Abstract: Giant cell tumor of tendon sheath is a relatively rare non-malignant soft tissue tumor arising from the synovial cells and is associated with high recurrence rate. However it is the second most common tumor in hands after ganglion cysts. Few factors considered for recurrence are proximity of distal inter phalangeal joints, presence of degenerative joint disease, pressure erosions in radiograph, increased mitotic activity. But only consistent observation found is incomplete excision of the tumor which leads to recurrence. Here we present a case series comprising of 4 cases over a period of 2 years for whom marginal excision was done and they were kept on regular follow up without any recurrence.

Keywords: Giant cell tumor, Hand, Recurrence, Tendon Sheath

Date of Submission: 12-01-2019

Date of acceptance: 27-01-2019

I. Introduction

It was first described by Chasaignac in 18th century.^[1] It is a slow growing, benign and rare soft tissue tumor arising from the synovial cells of tendon sheath. It is second most tumor of hands followed by ganglion cysts.^[2,3] Possible etiological factors for GCT Trauma, inflammation, metabolic disease and a neoplastic etiology GCT is a common tumor in hands and its incidence in amongst the fingers is as follows :- index finger followed by thumb, the long, the ring and then with little finger. Giant cell tumor of tendon sheath are associated with a high recurrence rate if proper marginal excision is not done. Possible etiological factors for GCT include Trauma, inflammation, metabolic disease and a neoplastic etiology.^[4,5] However majority of the cases are of unknown etiology. A diagnosis can be made with help of Fine needle aspiration cytology (FNAC) and imaging studies. Marginal excision is the treatment of choice.

II. Case reports

1. A 52 Years old male presented with painless swelling over the middle phalanx of left long finger since 2 Years. No H/O trauma. On Examination, A single, firm, non tender, non-transiluminant mass with restricted mobility was present over the middle phalanx of left long finger. Skin over the swelling was not pinchable. A provisional diagnosis of neuroma was made after USG. FNAC was planned which revealed GCT of tendon sheath. Tumour excised. HPE revealed numerous osteoclast types of giant cells surrounded by spindle cells and many polygonal cells. Diagnosis of GCT of tendon sheath was made.

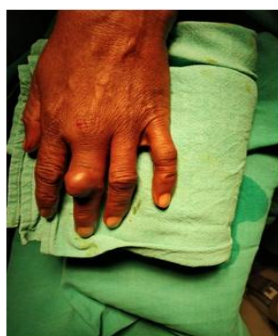

Fig 1 – Pre-operative

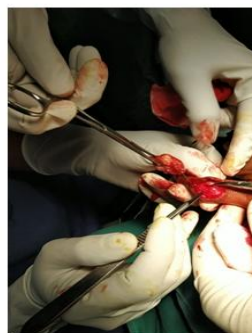


Fig 2 – Intra-operative

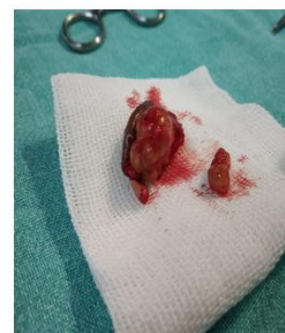

Fig 3 – Gross specimen

2. An 23 year old female presented with a painless swelling over the proximal half of right thumb since 9 months. No history of trauma. Examination revealed a single, firm, lobulated, non-tender, non-trans illuminating mass, mobile only in the horizontal plane over the proximal half of the right thumb; skin over the swelling is pinchable. Radiological investigation revealed no indentation of the bone and FNAC suggested GCT of tendon sheath. Marginal excision was done and the specimen was sent for histopathological examination. HPE confirmed our diagnosis. Patient was on follow up for 2 years and no recurrence noted

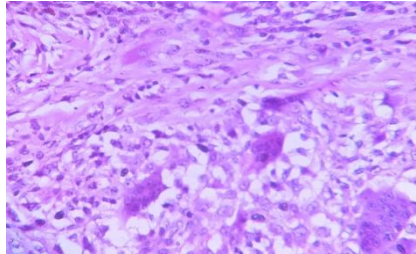


Fig 4 – HPE showing Giant cells

3. A 42 year old male presented with a firm painless swelling in the left index finger since 17 months. History of trauma is associated with the swelling. On examination 3x2 cms swelling is noted in proximal phalanx of left index finger. Its firm in consistency with restricted mobility and skin over swelling is pinchable. FNAC followed by Marginal excision was done. HPE revealed partially capsulated lesion with larger polygonal cells with vacuolated granular cytoplasm and vesicular nucleus, along with areas showing osteoclastic type of tumor giant cells and many clusters of cholesterol cleft spaces which is confirmative of our diagnosis
4. A 36 year old female came to our OPD with chief complaints of a slow growing, painless swelling in right ring finger since 13 months. No history of trauma. On examination a 2x2 cms firm swelling in middle phalanx of the right index finger. No restriction of movement in the joint. Swelling has no movement in the vertical plane and restricted mobility in horizontal plan. With the help of FNAC and imaging studies a diagnosis of Giant cell tumor of tendon sheath was made. Marginal excision of the tumor was done and patient kept on regular follow-up

III. Discussion

It is a slow growing, benign and rare soft tissue tumor arising from the synovial cells of tendon sheath Giant cell tumor of tendon sheath (GCTTS) is an extra-articular, localized and painless soft tissue swelling which has a longer duration. It is also called as fibrous histiocytoma of tendon sheath, Xanthogranuloma, and benign synovium.^[6] Giant cell tumor of tendon sheath is commonly seen in third, fourth and fifth decades of life with a male to female ratio of 2:3.^[7,8] Overall incident of GCT is one in 50,000 individuals. Possible etiological factors for GCT Trauma, inflammation, metabolic disease and a neoplastic etiology GCT is a common tumor in hands and its incidence in amongst the fingers is as follows :- index finger (29.7%) followed by thumb (12.9%), the long (24.6%), the ring (16.8%) and then with little (16%) finger.^[4,5] Many factors are considered as causing recurrence, including proximity to the distal interphalangeal joints, presence of degenerative joint disease, pressure erosions in the radiographs and increased mitotic activity.^[9] However the most widely accepted cause of recurrence is incomplete surgical excision of the tumor.

Byers classified GCTTS into two types i.e localized nodular which commonly occurs in hands and diffuse type which is more common in joints.^[10] Diffuse variety is commonly associated with recurrence. Differential diagnosis include Ganglion cyst, pigmented villonodular synovitis, desmoids tumor, fibroma, fibrosarcoma, glomangioma, knuckle pads and synovial sarcoma.

Sonography detects whether the tumor is solid or cystic and describes the relationship of the lesion to the surrounding structures. Information regarding the extent of contact with underlying tendon is possible with sonography.^[11] X-ray helps us to identify if there is any underlying bone or joint involvement. FNAC of the tumor helps in making an accurate pre-operative diagnosis and thus facilitates a well planned surgical approach. On microscopy GCTTS shows multinucleated giant cells, polyhedral histiocytes, fibrosis, lipid laden cells and hemosiderin deposits. Mitosis and high cellularity were also seen in GCTTS however their relation to recurrence is debatable.^[12,13]

Complete surgical excision remains the mainstay of treatment, assisted either with an operating microscope or a magnifying loupe. The recurrence rates after excision ranges from 7 to 45%.^[14] Meticulous excision of giant-cell tumours of tendon sheath reduces the incidence of recurrence. Radiotherapy has been suggested after inadequate excision and in patients with high mitotic activity to prevent recurrence.^[15]

IV. Conclusion

Even though GCTTS is a benign tumor it is associated with higher recurrence rate. So it is very important to make an accurate pre-operative diagnosis which helps in planning an appropriate surgical procedure thus decreasing the chances of recurrence. Here we shared our experience in dealing 4 cases of GCTTS over period of 2 years at our institution. Patients were kept on regular followup without any recurrence.

References

- [1]. Verheyden JR, Damron TA, Murray DG, Giant cell tumour of tendon sheath on Medscape: eMedicine 2002 accessed on 20th December 2013
- [2]. Darwish FM, Haddad WH. Giant cell tumour of tendon sheath: experience with 52 cases. *Singapore Med J* 2008;49(11):879-882.
- [3]. Uriburu JF, Levy VD. Intraosseous growth of giant cell tumors of the tendon sheath (localized nodular tenosynovitis) of the digits: report of 15 cases. *J Hand Surg Am* 1998;23:732-736.
- [4]. Lowyck H, De Smet L (2006) Recurrence rate of giant cell tumors of the tendon sheath. *Eur J Plast Surg* 28:385-388
- [5]. Reilly KE, Stern PJ, Dale JA (1999) Recurrent giant cell tumors of the tendon sheath. *J Hand Surg Am* 24:1298-1302
- [6]. Fletcher CD, Krishnan K, Unni KK, Mertens F. *World Health Organization Classification of Tumors, Pathology, and Genetics of tumors of Soft Tissue and Bone*. Lyon, France: IARC Press;2002. P112-114.
- [7]. Walsh EF, Mechrefe A, Akelman E, Schiller AL. Giant cell tumor of tendon sheath. *Am J Orthop* 2005; 34 : 116-21.
- [8]. Schultz RJ and Kearns RJ. Tumors in the hand. *J Hand Surg* . 1983; 8 : 803-6.
- [9]. Rao AS, Vigorita VJ (1984) Pigmented villonodular synovitis (Giant-Cell tumor of the tendon sheath and synovial membrane): a review of 81 cases. *J Bone Joint Surg* 66A:76-94
- [10]. Ikeda K, Osamura N, Tomita K (2007) Giant cell tumour in the tendon sheath of the hand: importance of the type of lesion. *Scand J Plast Reconstr Surg Hand Surg* 41:138-142
- [11]. Middleton WD, Patel V, Teefey SA et al (2004) Giant cell tumors of the tendon sheath: an analysis of sonographic findings. *Am J Roentgenol* 183:337-339
- [12]. Messoudi A, Fnini S, Labsaili N et al (2007) Giant cell tumors of the tendon sheath of the hand: 32 cases. *Chir Main* 26:165-169
- [13]. Liu PT (2007) Radiological reasoning: acutely painful swollen finger. *Am J Roentgenol* 188:A13-S17
- [14]. Docken WP. Pigmented villonodular synovitis: a review with illustrative case reports. *Sem Arthritis Rheum* 1979;9 : 1-22
- [15]. Kotwal PP, Gupta V, Malhotra R (2000) Giant cell tumour of the tendon sheath- is radiotherapy indicated to prevent recurrence after surgery? *J Bone Joint Surg* 82B:571-573

Dr. Ramesh Kumar Korumilli. "A Case Series of Giant Cell Tumor of Tendon Sheath." *IOSR Journal of Dental and Medical Sciences (IOSR-JDMS)*, vol. 18, no. 1, 2019, pp 18-20.