

Spontaneous Gastric Perforation in an Adolescent: A Case Report

Vijay anand¹, Balakrishna², Mageswaran^{3*}, Rakesh pandey⁴

¹ Assistant professor, Department of general surgery, Aarupadai veedu medical college, Pudcherry, Tamilnadu, India

² Postgraduate, Department of general surgery, Aarupadai Veedu Medical College, Pudcherry, Tamilnadu, India

³ Postgraduate, Department of general surgery, Aarupadai veedu medical college, Pudcherry, Tamilnadu, India

⁴ Postgraduate, Department of general surgery, Aarupadai veedu medical college, Pudcherry, Tamilnadu, India
Corresponding Author: Vijay anand

Abstract: Gastric perforation in an adolescent age group is a very rare disorder. Etiology of gastric perforation still remains unclear. Although case reports on duodenal perforation are available but only handful of case reports are available for gastric perforation in adolescent age group. If we overlook, it will end up in life threatening situations. Although perforations due to various etiologies are common, spontaneous gastric perforation is very rare. Here we share our experience on a 17year old boy who presented with complaints of abdominal pain which turned out to be a gastric perforation. Emergency exploratory laparotomy was performed, which revealed pre-pylorus perforation and was closed with modified graham's patch

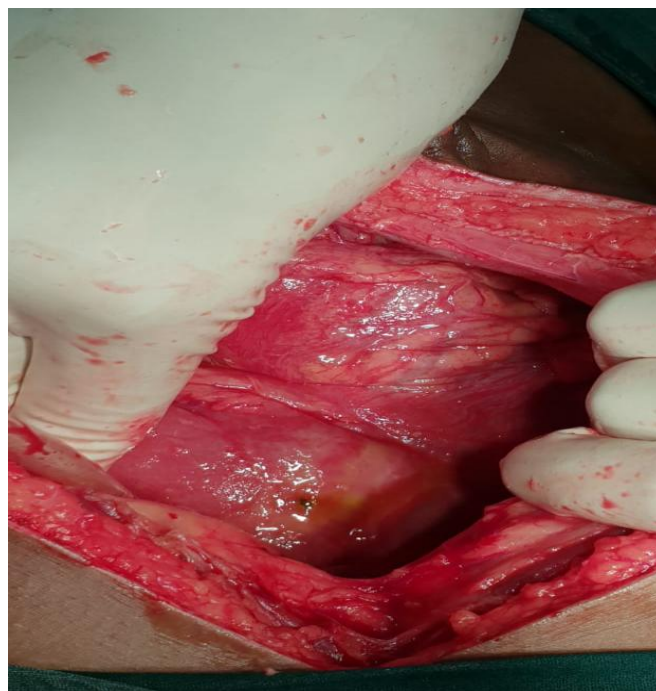
Keywords: Gastric perforation, Adolescent, pneumoperitoneum, Grahams patch repair

Date of Submission: 11-01-2019

Date of acceptance: 27-01-2019

I. Case report

A 17year old boy came with complaints of abdominal pain for the past four days. The pain was initially dull aching, non radiating more in the epigastric region. Over the course of four days pain increased in intensity associated with ten episodes of vomiting which is non-projectile, non-bilious contains undigested food particles. There is no history of trauma, loose stools, constipation, obstipation. There is no history of any drug intake, NSAIDs abuse. There is no previous history of H.pylori infection. He has habit of skipping breakfast and irregular eating habits. No similar illness in the past.



On examination he is conscious, oriented, looking toxic and dehydrated. He is febrile with tachycardia. Per abdomen guarding and rigidity present, diffuse tenderness present. On percussion there was obliteration of liver dullness. Per rectal examination was insignificant. Blood investigations revealed elevated total wbc count of 12,900cells/cu.mm. X-ray abdomen revealed pneumo peritoneum. Emergency exploratory laparotomy was proceeded and intra operatively a gastric perforation of size 4mm was found in pre-pylorus region with oozing of ingested food particles. Thorough decontamination was done and gastric perforation was closed with modified graham's omental patch. Abdomen was closed in layers after placing drain. On post-op day three he was started on sips of water which was gradually advanced in a day to liquid diet followed by soft solid diet. He tolerated well. Drain was removed on post-op day six and was discharged home on seventh post-op day. Follow up visits were uneventful.

II. Discussion

Spontaneous gastric perforation is a rare clinical entity. Etiology still remains unclear.

Spontaneous gastric perforation in neonates has been reported in the literature. It is rare beyond the neonatal period(1). The diagnosis can be overlooked due to vague and variable symptoms and low index of suspicion due to its rarity in this age group(2). Elevated intraluminal pressure and ischemia of the bowel wall are also cited as possible causes(3). Imaging features of spontaneous gastric perforation include pneumoperitoneum on radiograph and oral contrast extravasation with gastric wall irregularity or disruption(4). H.pylori infection should be ruled out in all cases. Studies have suggested that if signs of peritonitis are present the exploratory laparotomy should be done(5). This should be done within 12 hours to avoid poor outcome(6). Traditional open surgical method is usually undertaken. Simple closure with or without Omentum is one of the most commonly used technique(7). The Graham's patch is still relevant and useful in emergency surgery for perforated peptic ulcer in selected patients(8). The patients with duodenal perforation who present with unstable haemodynamics and gross peritoneal contamination the safest surgery, is a simple closure with a Graham's patch using omentum(9).

III. Conclusion

Duodenal or gastric perforation is a surgical emergency. Any delay in diagnosis and treatment will be life threatening. It should be always be included in the differential diagnosis of all acute abdomen presentations. X-ray abdomen erect should be taken on all acute abdomen cases to rule out pneumoperitoneum. Exploratory laparotomy should never be delayed. In our case we did modified graham's patch repair. Biopsy is a must in cases of gastric perforation to know the etiology. H.pylori should always be ruled out. If h.pylori positive, H.pylori kit should be started to prevent recurrence. Post operatively patient should be closely monitored for any signs of leak. It is regarded spontaneous, if no cause found.

Acknowledgement

Authors would like to thank Dr.B.Kanchanaa,head of the department general surgery for her constant motivation and remarkable help in surgical management of this case..

References

- [1]. Akalonu A, Yasrebi M, Rios ZM. Spontaneous gastric perforation in two adolescents. Am J Case Rep. 2016;17:694
- [2]. Nasio NA, Saidi H. Perforated peptic ulcer disease at Kenyatta National Hospital, Nairobi. East Central African J Surg. 2009;14(1):13-6
- [3]. Libeer F, Vanhamel N, Huyghe M, Verlinden E. Spontaneous gastric rupture in non-neonatal children: A case report. Acta Chir Belg. 2007;107:560-63
- [4]. Testini M, Portincasa P, Piccinni G, Lissidini G, Pellegrini F, Greco L. Significant factors associated with fatal outcome in emergency open surgery for perforated peptic ulcer. World J Gastroenterol. 2003;9:2338-40.
- [5]. Syanes C, Lie RT, Syanes K, Kie SA, Soreide O. Adverse effects of delayed treatment for perforated peptic ulcer. Ann Surg. 1994;220(2):168-75.
- [6]. Lin CM, Lee HC, Kao HA, et al. Neonatal gastric perforation: Report of 15 cases and review of the literature. Pediatr Neonatol. 2008;49(3):65-70.
- [7]. Arora BK, Arora R, Arora A. Modified Graham's repair for peptic ulcer perforation: reassessment study. Int Surg J. 2017;4(5):1667-71.
- [8]. Tessema E, Meskel Y, Kotiss B. Perforated peptic ulcer in Tikur Anbessa Hospital. Ethiop Med J. 2005;43(1):9-13.26
- [9]. Nasio NA, Saidi H. Perforated peptic ulcer disease at Kenyatta National Hospital, Nairobi. East Central African J Surg. 2009;14(1):13-6

Vijay anand."Spontaneous Gastric Perforation in an Adolescent: A Case Report." IOSR Journal of Dental and Medical Sciences (IOSR-JDMS), vol. 18, no. 1, 2019, pp 08-09.