

Xanthogranulomatous Pyelonephritis: A rare case identified

DrMedhaviDhir, DrLavleenBharti, DrHarpal Singh, Dr R.K Kundal,
DrSurinderKaur, DrVinayGuriaya
Corresponding Author: DrMedhaviDhir

Abstract: Xanthogranulomatous pyelonephritis (XGP) is a rare manifestation of chronic kidney inflammation. It is an uncommon chronic destructive granulomatous process of renal parenchyma in association with long-term urinary tract obstruction and infection. It can be life-threatening if not recognized early and treated appropriately. It affects females more often than males, with a wide range of age, from newborn to elderly. The present study describes the case of 42 year old female who presented with the complaint of pain abdomen right side and radiological evidence of renal calculi.

Date of Submission: 11-01-2019

Date of acceptance: 27-01-2019

I. Introduction

Xanthogranulomatous pyelonephritis (XGP) is a chronic destructive granulomatous inflammation that is characterized by urinary tract obstruction, urinary calculi, and invasion of the renal parenchyma. XGP can be found in 2 forms: the focal form and diffuse form. The diffuse form of XGP is rare but manifests extrarenal complications.^[1,2]

Diagnosis of XGP is usually made radiographically and later confirmed by histopathology. Treatment most often involves a combination of surgery and antibiotics^[3,4]

II. Case Report

A 42 year old female came to urology department of Rajindra Hospital Government Medical College Patiala with the chief complaint of severe pain abdomen right lumbar region, on and off, radiating to the back since 1 year. There was no history of burning micturition. On ultrasound the right kidney was enlarged. Renal parenchyma showed thinning with grade 3 to 4 hydronephrosis. Multiple calculi are seen in the renal pelvis and calyces likely to be staghorn calculus.

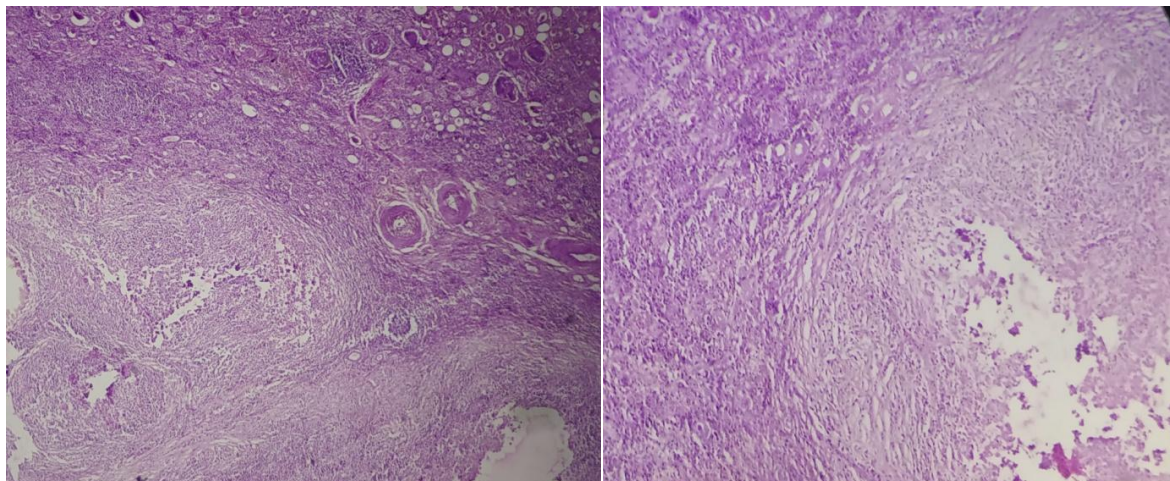
The nephrectomy specimen was fixed in 10% buffered formalin and processed for paraffin wax sectioning. The sections were stained with haematoxylin-eosin stain.

Gross features

A specimen of kidney was received measuring 10x5.5x4.5 cm. multiple hard nodules appreciated on the surface. On cut section multiple cystic areas are identified. Cortex and medulla could not be appreciated. Multiple blackish color stones recovered

Histopathological features

Section shows tissue consist of glomeruli and tubules. Glomeruli exhibit hyalinization, some of the tubules showing thyroidisation. Interstitium shows ill formed granulomas at places comprising of lymphocytes, epithelial cells along with multinucleate giant cells. Also seen inflammatory cells comprising of foamy histiocytes, plasma cells, neutrophils and lymphocytes.



III. Discussion

Xanthogranulomatous pyelonephritis (XPN) is a rare entity and constitutes less than 1% of chronic pyelonephritis. It mainly occurs in adults with preponderance in females of younger age group. It usually involves single kidney and is associated with renal stones in 2/3 of cases and con-comitant infection with *E. coli*, *Pro-teus mirabilis*, *Klebsiellaspp*, *Staphylococcus aureus*, *Enterococcus spp*, *Pseudomonas spp*, *Streptococcuspp*, including anaerobic organisms^[5].

In 70% of XGP patients, the causes of the urinary obstruction, such as staghorn calculi or renal calculi, are found in many sites of the urinary tract. XGP are found most commonly in middle-aged women, and these patients generally show symptoms of fever, flank pain, malaise, and weight loss.^[1,2,6]

However the definitive diagnosis of this entity is achieved only by histopathological examination which shows the presence of lipidladen macrophages (xanthoma cells),as well as other inflammatory cells, including plasma cells, leukocytes, and histiocyte^[7,8]. Antibiotics usually do not resolve the problem and nephrectomy either partial or total remains the treatment of choice^[9].

IV. Conclusion

Xanthogranulomatous pyelonephritis is an unusual variant of chronic pyelonephritis. Most cases occur in the setting of obstruction due to infected renal stones.Computed tomography is the mainstay of diagnostic imaging for xanthogranulomatous pyelonephritis. Imaging studies may demonstrate diffuse or focal form. Nephrectomy remains the treatment of choice especially in diffuse cases of xanthogranulomatous pyelonephritis.

References

- [1]. Ghoz HM, Williams M, Pereplechikov A, et al. An unusual presentation of xanthogranulomatous pyelonephritis: psoas abscesswithreno-colic fistula. *Oxf Med Case Reports* 2016;2016:150–3.
- [2]. Alan C, Ataus S, Tunc B. Xanthogranulomatous pyelonephritis with psoas abscess: 2 cases and review of the literature. *IntUrolNephrol* 2004;36:489–93.
- [3]. Chuang CK, Lai MK, Chang PL, Huang MH, Chu SH, Wu CJ, Wu HR. Xanthogranulomatous pyelonephritis: experience in 36 cases. *J Urol.* 1992;147(2):333–6.
- [4]. Craig WD, Wagner BJ, Travis MD. Pyelonephritis: radiologic-pathologic review. *Radiographics.* 2008;28(1):255–77. doi: 10.1148/rg.281075171.
- [5]. Leoni AF, Kinleiner P, Revol M, et al. Xanthogranulomatous Pyelonephritis: Review of 10 cases. *Arch Esp Urol.* 2009;62(4):259–271
- [6]. O’Boyle C, Gleeson M, Butler M, et al. Case report: xanthogranulomatous pyelonephritis presenting as a cutaneous fistula. *Ir J Med Sci* 1993;162:150–1.
- [7]. Brown PS, Dodson M, Weintrub PS. Xanthogranulomatous Pyelonephritis: Report of Nonsurgical Management of a Case and Review of the Literature. *Clin Infect Dis.* 1996;22:308–314.
- [8]. Isbudak OI, Sozen S, İşik S. Renal tuberculosis mimicking xanthogranulomatous pyelonephritis: ultrasonography, computed tomography and magnetic resonance imaging findings. *Turk J Pediatr.* 2002;44(2):168–171.
- [9]. Nawaz H, Khan S, Hussain I, et al. Xanthogranulomatous Pyelonephritis due to calculi: Report of 63 cases and review of literature. *J.PMA.* 2005;55:387–389.

DrMedhaviDhir. “Xanthogranulomatous Pyelonephritis: A rare case identified.” *IOSR Journal of Dental and Medical Sciences (IOSR-JDMS)*, vol. 18, no. 1, 2019, pp 01-02.