

Rehabilitation of Long Span Partially Edentulous Arch Using Clasp less Cast Partial Denture and Precision Attachment - An Aesthetic Approach: Case Series

Dr.Bindal Patel¹, Dr.Shikha Shah², Dr. Rajesh Sethuraman³,
Dr.Tamanna Chhabra⁴, Dr.Kavita Gupta⁵

¹ (Post Graduate Student, Department of Prosthodontics and Crown and Bridge, K. M. Shah Dental College and Hospital, Vadodara, Gujarat, India)

² (Post Graduate Student, Department of Prosthodontics and Crown and Bridge, K. M. Shah Dental College and Hospital, Vadodara, Gujarat, India)

³ (Professor and Head of Department, Department of Prosthodontics and Crown and Bridge, K. M. Shah Dental College and Hospital, Vadodara, Gujarat, India)

⁴ (Professor, Department of Prosthodontics and Crown and Bridge, K. M. Shah Dental College and Hospital, Vadodara, Gujarat, India)

⁵ (Professor, Department of Prosthodontics and Crown and Bridge, K. M. Shah Dental College and Hospital, Vadodara, Gujarat, India)

Abstract: Rehabilitation of Multiple missing teeth is always challenging job for a prosthodontist in partial edentulous patient especially in distal extension cases. Successful treatment can be done with accurate diagnosis and careful treatment planning. Implant fixed prosthesis has become contemporary choice for the replacement of natural teeth in distal extension cases. But all the patients cannot afford the cost. A small number patient who can afford may have limitations like systemic diseases, or the anatomical considerations may contraindicate the dental implant options. So for that group of patient conventional methods of fabrication of the removable partial denture is a best treatment option. In modern dentistry claspless cast partial denture with precision attachment is a newer treatment modality for partially edentulous arch. Prime function of attachment retained partial denture is to distribute the masticatory forces to the wide area thereby reducing the damage to the abutments, soft tissues and bony ridges in addition to improved esthetics and proprioceptive responses. In this case series patient's esthetic and functional requirements were fulfilled with attachment retained cast partial denture using semi-precision attachments.

Keywords: Cast partial denture, Precision attachment, Distal extension

Date of Submission: 07-01-2019

Date of acceptance: 24-01-2019

I. Introduction

Dentistry is not limited to prevention and treatment of dental diseases but it extends its use to meet the esthetic demands of the patient. It has evolved from curative to creative care.¹ Successful oral rehabilitation necessitates contemporary and advanced treatment planning. It becomes more challenging in distal extension cases.

Multiple treatment options are available now a days for replacement of partially edentulous arches includes Implant supported fixed prosthesis, Removable partial dentures with precision attachments, Overdentures and Clasp retained removable partial dentures. In such partial edentulous situations, implant prosthodontics has been first choice for rehabilitation in this modern dentistry, although conventional removable prosthodontics is also there. It has been a treatment consideration where implant therapy is not possible due to insufficient amount of bone, local or systemic factors or economic reasons.² While restoring missing teeth, our prime objective should be to restore function and preservation of oral tissues and esthetics. Numerous removable partial dentures (RPDs) are made where negligence to above mentioned factors occurs while attention is paid in mere replacement of missing teeth. This results in detrimental effect on remaining natural dentition.³

Prosthodontic rehabilitation of distal extension partially edentulous situations remains challenging. Fixed prosthesis is not a suitable treatment option due to loss of natural teeth. The support of distal extension RPD is derived from edentulous ridge and terminal abutment teeth. The terminal abutments act as fulcrum while functional movements of RPD as well as retentive clasps exert force on abutment teeth which may jeopardize the periodontium of these teeth.⁴ Another treatment modality for such clinical situations is combination of fixed

and removable partial dentures using precision attachment retained cast partial denture was largely preferred, with barely satisfactory esthetical results. Precision attachment has long been considered the highest form of partial denture therapy. Attachment retained RPD provide esthetic as well as functional replacement of remaining teeth and related oral structure. The few retrospective studies reported the survival rate of 83.3% for 5 years, of 67.3% up to 15 years and of 50% when extrapolated to 20 years.^{5,6}

II. Types of Attachments

An attachment is defined as “A mechanical device for the fixation, retention and stabilization of a prosthesis”.⁷ It's a con consisting of two parts, one part is connected to a root, tooth or implant and the other part to a prosthesis. According to Mensor (1971) attachment has classified as

1. Intracoronallattachments,
2. Extracoronallattachments,
3. Studattachments and
4. bar type of attachments.⁸

Based on resiliency they are also classified as solid or rigid, with or without a U pin or screw and (hinge, vertical, rotatory type).⁹

Based on physiologic, functional, and esthetic need of the prosthesis, appropriate precision attachments should be selected. Esthetics is the Primary indication of attachment retained partial denture. When partial denture is treatment of choice for distal extension situations, the precision attachment is most equitable and definite means of distributing stresses.

This case series describes a patient with maxillary and mandibular bilateral distal extension Kennedy's class I condition which is prosthetically restored by a cast partial denture retained using an extracoronallcastable precision attachment (RHEIN 83 OT CAP attachments system).

III. Case reports

Case 1:

A 62-year-old male reported to the Department of Prosthodontics with the chief complaint of multiple missing teeth in maxillary and mandibular arch and inability to chew food properly and wants replacement of teeth. Medical history was no-significant. On intraoral examination, maxillary arch was completely edentulous and in mandibular arch 31, 32, 36,37,41,42,46,47 teeth were missing and there was generalized attrition of remaining teeth. The periodontist was consulted to know the prognosis of the remaining teeth. The major concern of prosthodontic team was retention and stability of the prosthesis along with replacement of the missing teeth. In addition to this condition of presence of (maxillary complete denture against Kennedy's Class 1 RPD may cause combination syndrome.

Radiographic examination and diagnostic model study evaluation was suggested of presence of adequate interocclusaldistance. Patient was explained about various available treatment options like fixed partial denture combine with cast partial denture, Overdenture and implant.

Final treatment plan was chosen on considering the pros and cons of the various available treatment options and patient's esthetic need, functional requirement and economical condition. Mandibular arch was rehabilitated with splinting of lower remaining anterior teeth with metal ceramic FPD in relation to 35-45 to which the Rheine 83 extracoronall attachments were attached. For maxillary arch conventional complete denture prosthesis was planned.

CLINICAL PROCEDURE

All periodontal and intentional endodontic therapies were completed first and then the patient was referred back to the Department of Prosthodontics. The preliminary impressions were taken (figure no.1), over which custom made tray was fabricated.

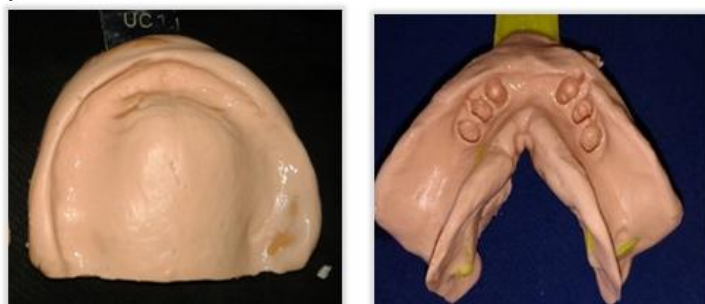

Figure no.1 Primary impressions

Border molding was carried out using green stick compound and final Impressions were made by dual impression technique. To evaluate the vertical dimensions and to recheck the inter-ridge space, the jaw relations were recorded. Face bow (Hanau, Waterpik, Ft Collins, CO, USA) transfer is done and mounting was done in semi adjustable articulator. (Waterpik, Ft Collins, CO, USA) After this, the actual treatment was started with reducing the crown height of the remaining teeth and diagnostic mock-up was done (figure no.2)

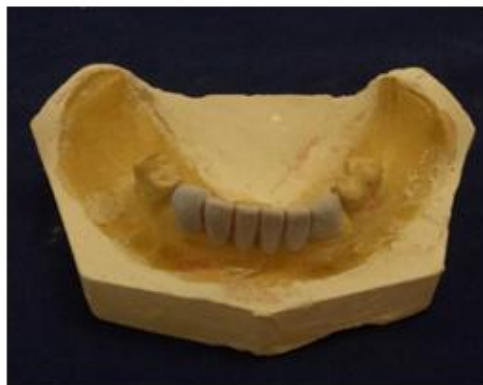

Figure no.2 Mockup of mandibular anterior

On which putty index were made which help while final tooth preparation. Then mandibular anterior teeth 33 and 43 were prepared for the metal-ceramic prosthesis. After that temporary prosthesis was fabricated and evaluated in patient's mouth for esthetics and phonetics. Then after temporary prosthesis was cemented using zinc oxide eugenol cement.



Figure no.3 Occlusal plane determined by Broadrick plane

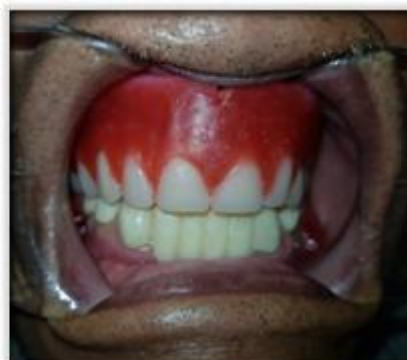

Figure no.4 Temporization of mandibular teeth

The posterior occlusal plane was determined by Broadrick plane analyzer (figure no.3). The posterior teeth 34, 35, 44 and 45 were prepared and on which mock-up was done. Teeth setting of all maxillary anterior teeth and mandibular posterior teeth 36, 37, 46, 47 were done according to determined occlusal plane. Putty index of mock-up was taken which helped for final preparation.

Anterior teeth setting was checked in patients mouth for the esthetic and phonetics. After that the final preparation for metal ceramic restoration of 34, 35, 44 and 45 was carried out. With the help of putty index occlusal clearance was checked. Temporary prosthesis of lower anterior teeth was removed and preparation was refined. Final impression made using the two step putty wash technique with a polyvinyl siloxane (PVS) Impressions material. Temporization of all mandibular teeth were done and occlusion was checked (figure no.4)

Obtained cast was surveyed and wax up was done to fabricate metal ceramic FPD. The terminal teeth, i.e., 35 and 45 are selected as abutments to which the Rheine 83 semi-precision were to be attached on their distal ends. (figure no.5) The patrix part of this attachment were attached to the wax pattern of both 35 and 45 and with the help of the dental surveyor their parallelism was checked. After casting the wax pattern along with

the castable parts of Rheine 83 attachment, metal try in of the casted pattern was done in the patient's mouth to check the fit of the prosthesis.(figure no.6)

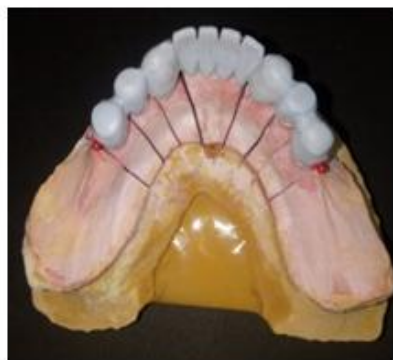

Figure no.5 Wax pattern with Rhein Attachment

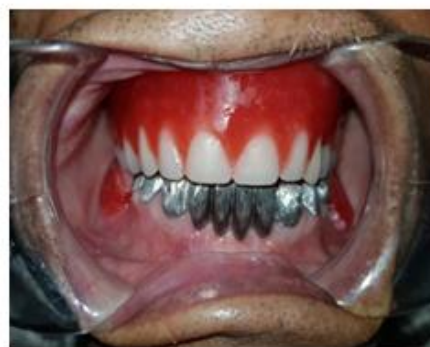

Figure no. 6 Metal try in

After checking of fitting of metal, ceramic build up was done. Final prosthesis was undergone finishing, and polishing. And then final prosthesis was cemented using glass ionomer luting cement (GC FUJI 1, GC Corporation, Tokyo, Japan)(figure no.7).

The impression for cast partial denture framework was taken using PVS impression material and sent to the laboratory. The cast was poured with type IV gypsum and was scanned by Exocad software and then cast partial denture framework was designed. Mandibular plate type of major connector was selected. All scanned data than send as STP file to the milling machine(figure no.8). After milling final cast partial framework was finished and polished.

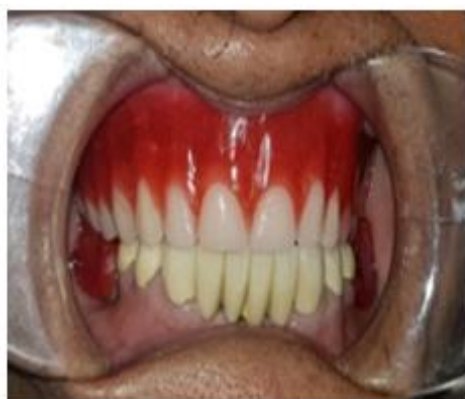

Figure no.7 Final cementation of mandibular teeth

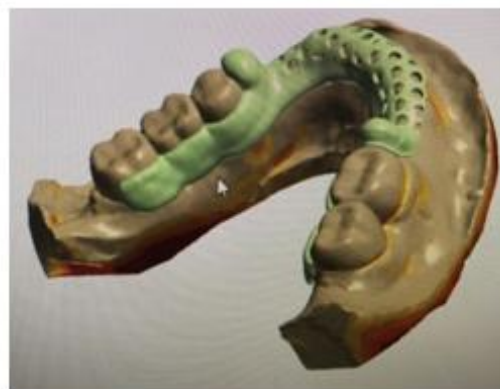

Figure no.8 cast partial denture framework fabricated with CAD-CAM

The fitting of framework was checked in patient's mouth and border moulding was carried out with green stick compound. Then wash impression was taken with zinc-oxide eugenol impression paste. The cast was poured using altered cast technique (figure no.9). The cast is mounted on articulator and mandibular posterior teeth setting was done and checked it in a patient's mouth. Theacrylization of Mandibular RPD and maxillary complete denture was done using DPI – Acrylyn H. The finishing and polishing of the both dentures were accomplished assess esthetics, occlusion and speech. With the help of self-cure acrylic resin using DPI-Cold Cur, the retentive caps were picked up within the partial denture (figure no.10).

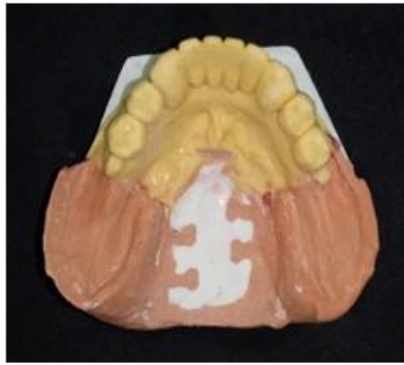

Figure no.9 Cast poured with altered cast technique

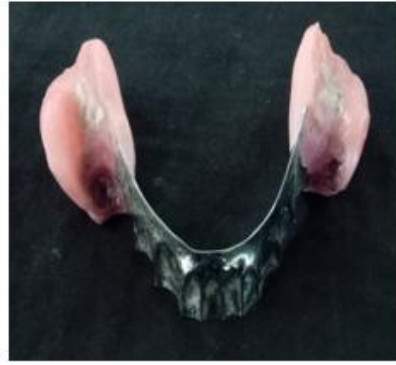

Figure no. 10 Tissue surface of the attachment retained cast partial denture showing the retentive caps

Finally, the upper complete denture and the lower attachment retained cast partial denture was fitted in the patient's mouth and the occlusion was checked. Esthetics and speech were also assessed. Figure no.11 shows the frontal view of the patient after the insertion of the prosthesis.

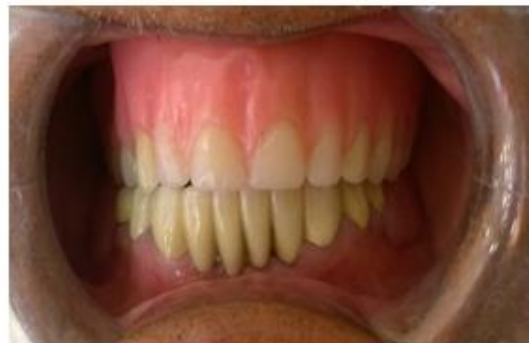
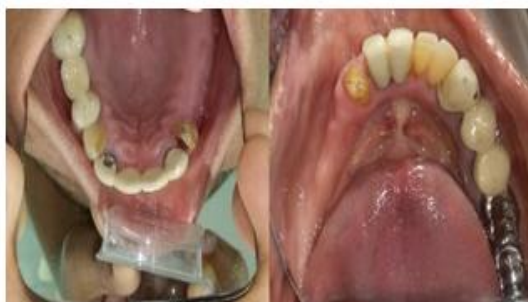
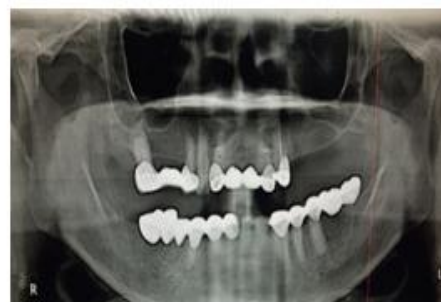Figure no.11 Insertion of prosthesis

Case 2:

A 48-year-old female patient reported to the Department of Prosthodontics with the chief complaint of inability to chew food properly due to multiple missing teeth in maxillary and mandibular arch. Medical history was not significant. On oral examination, old prosthesis porcelain fused to metal bridge from 12 to 22 and 14 to 16 and 23 was endodontically treated with porcelain fused to metal crown were present in maxillary arch and porcelain fused to metal bridge from 41 to 46 and 33 to 35 with metal bridge in 36 and 37 present in mandibular arch (Figure 1). After radiographic examination it was found that there was a long span cantilever bridge were made previously on 33 to 37 in which 36 and 37 was cantilevered and 41 to 46 where 44,45,46 was cantilevered (Figure 2).

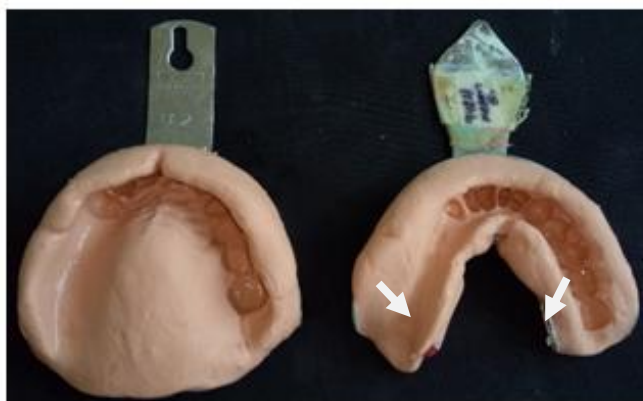

(Figure: 1 Preoperative occlusal view of maxillary and mandibular arch)



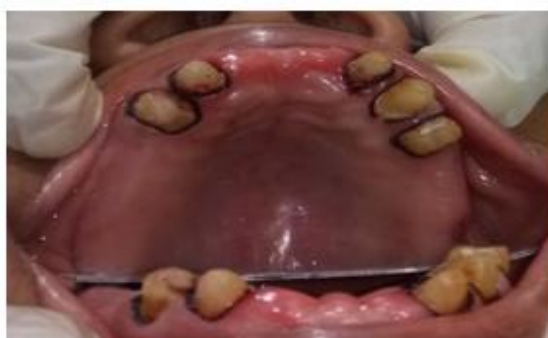(Figure: 2 Radiographic examination)

Treatment was planned by accordance to patient's esthetic need and economical condition. Treatment plan included Removal of all old fixed prosthesis first then evaluating the remaining teeth. After evaluation it was found that 35 and 43 had carious lesion and 16 had grade 2 mobility. Hence, the patient was advised to undergo extraction of 16 and endodontic treatment of 35 and 43. After completing the all endodontic treatment and extraction. On oral examination, teeth missing in maxillary arch were 15,16,17,24,25,26,27 and in mandibular arch missing teeth were 36,37,44,45,46,47. Diagnostic impression was made (Figure 3).



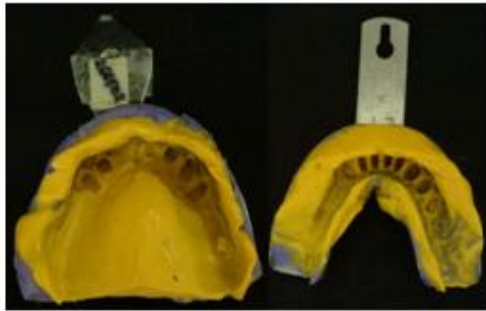(Figure: 3 Diagnostic impression)

After diagnostic model study, Diagnostic casts were articulated on a semi-adjustable articulator using facebow at the anticipated vertical dimension of occlusion, following which diagnostic wax-up was done within the mounted cast. The tentative articulation helped in assessing the available inter-arch space, and this was found to be adequate. So, fixed partial denture was planned on 15 to 23, followed by attachment retained (Preci-Sagix, CEKA Attachments, Swiss) cast partial denture in maxillary arch and fixed partial denture was planned on 42 to 35 in mandibular arch, followed by mandibular RPD overdenture with O-ring attachment. 14, 13,12,22 and 23 were prepared to receive porcelain fused to metal bridge in maxillary arch and 42, 41, 31,32,33 and 34 were prepared to receive porcelain fused to metal bridge in mandibular arch (Figure 4).

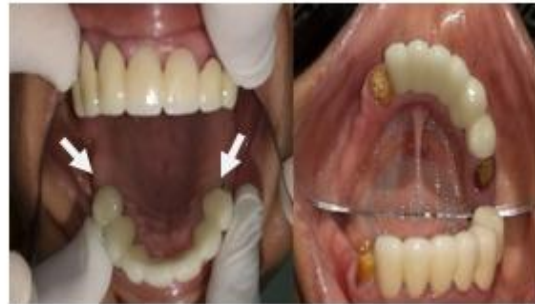

(Figure: 4 Intraoralocclusal view of prepared maxillary teeth with gingival retraction)

All preparation was done with the use of tentative jaw relation at the anticipated vertical dimension of occlusion. Gingival retraction was done and final impressions of maxillary and mandibular arches were made using polyvinyl siloxane impression material (Figure 5) (Imprint™II, 3M ESPE, Germany) and the cast was poured in die stone (Kalrock, Kalabhai Karson, Mumbai). Wax patterns were fabricated and burnout plastic male components (Preci-Sagix standard attachment, CEKA, Swiss) were attached to the distal surface of maxillary right 1st premolar and distal surface of maxillary left canine of the waxed abutment using dental surveyor. Fixed partial denture with a male part of Preci-Sagix attachment was casted in Ni–Cr alloy (MeAlloy, Dentsply, UK). Porcelain build-up of fixed partial denture was completed followed by final trial in patient's mouth (Figure 6).



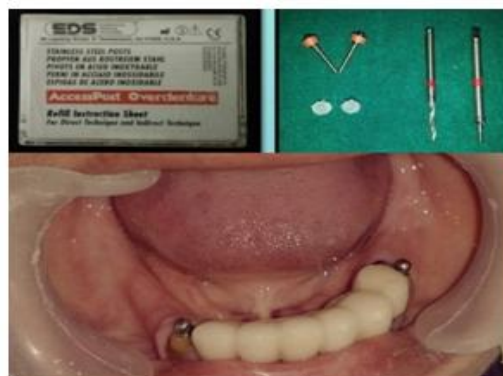(Figure: 5 Final impression)



(Figure: 6 Final cementation with sagittal attachment in maxillary arch)

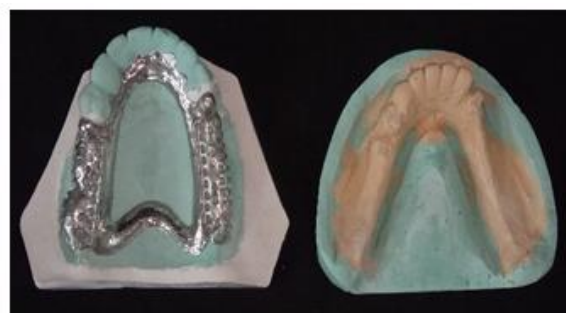
After cementation of fixed prosthesis, maxillary impression was made in polyvinyl siloxane impression material (Imprint™II, 3M ESPE, Germany) and poured in die stone. Cast partial framework was designed on the master cast using CAD-CAM technology and the entire cast partial framework was cast in Co–Cr alloy (Bego, Dentaureum, Germany).

After cementation of fixed prosthesis in mandibular arch Abutment teeth 35 and 43 were prepared with a dome-shaped contour hemispherically rounded in all dimensions up to gingival line. Preparation for the "O-ring" direct access post was done with the primary reamer and countersink drill (Access Post Overdenture, Essential Dental systems) (Figure 7).



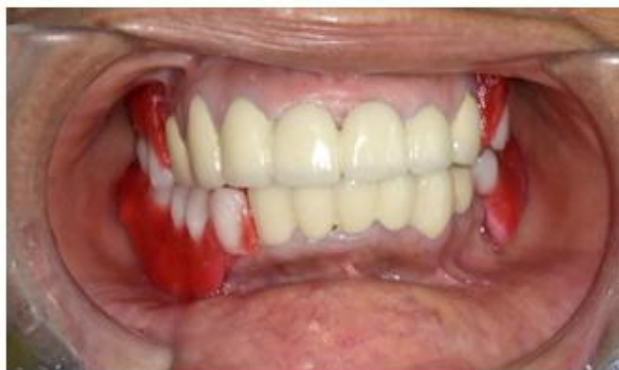(Figure: 7 Access post placement in 35 and 43 in mandibular arch)

After the required height was obtained, the access post was checked for the fit and finally cemented. The rubber band was placed over the O-ring. Primary impressions were made (alginate) and custom trays fabricated and an elastomeric final impression was made and cast poured in die stone (Figure 8)



(Figure: 8 Final cast with cast partial denture framework)

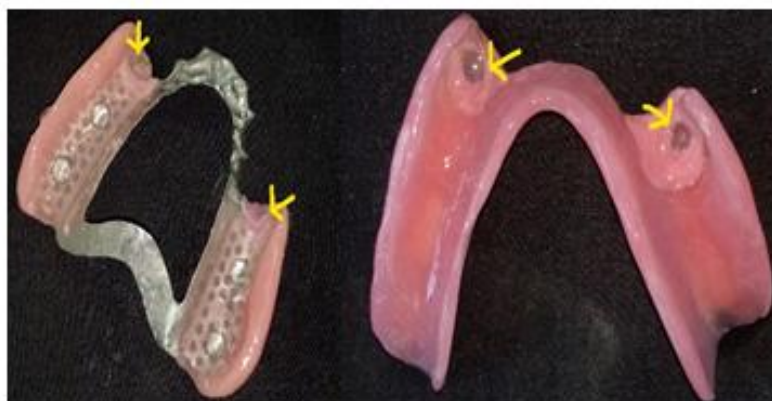Maxillomandibular relation was recorded and mounted on semi-adjustable articulator using facebow. Teeth arrangement was done and wax try in done (Figure 9).



(Figure: 9 Try in of maxillary and mandibular denture)

Occlusion and esthetics was verified in patient's mouth. After a satisfactory trial, the trial denture was invested and dewaxed cast partial denture for maxillary arch was fabricated in heat cure denture base resin (Leucitone 199 DentureResin; Dentsply, Trubyte). Female components of attachments were attached to cast partial denture using an autopolymerising denture-base resin. Retention was found to be satisfactory after insertion of maxillary cast partial in patient's mouth. Then mandibular denture base were adjusted to the supporting mucosa. After the mandibular denture-base and tissue-surface adjustments were complete, then the attachments were incorporated into the denture base. Rubber band was used to cover the height of contour and the denture-base attachment, that is, the nylon caps were placed onto the abutments and were luted chairside to the denture base using an autopolymerising denture-base resin. When the denture base was removed, the tissue surface was observed to evaluate the successful transfer of the female attachment process. The excess material from the access openings was removed, and the area polished. Finally, both the dentures were placed in the

patient's mouth and checked. Post insertion instructions and cleaning of the prosthesis were given to the patient.(Figure 10)



(Figure: 10 Final denture with Female component)

IV. Discussion

In case of partially edentulous mouth, retention provided by the usage of precision attachments may have many advantages like, comfort, satisfaction, chewing ability, as well as adequate distribution of occlusal loads and preservation of abutment teeth & less postoperative adjustments in patients with removable partial dentures.

Precision attachment provide balance between functional stability and cosmetic appeal in partial dentures .Sometimes precision attachment is said to be a connecting link between fixed and removable

prosthesis as it incorporates features of both type of prosthesis. The majority of extracoronal attachments available have resilient attributes. As omnipolar motion is possible with highly resilient extracoronal attachments, alignment is not a critical issue. So multiple paths of placement for the prosthesis is advantageous.

Preci-Sagix type of attachment was selected for presented case report as these attachments are extracoronal resilient and economical. These attachments are working on broken stress philosophy, which permit some vertical movement so as a result, transferred stress on abutment will reduce. According to Feinberg, he said that this type of resilient attachments reduce destructive lateral forces because they are free moving and passive. Greater retention and stability is provided by segmented female component which contacts a greater surface area. The female

The decision regarding the selection of the type of attachment is carefully considered in removable partial denture design. Conventional clasp type of removable partial denture is also a popular treatment choice as its lower cost, easy fabrication method and maintenance. But if patient demands for esthetics and abutment alignment and cross arch bracing is need to be concern then attachment retained removable partial denture is the treatment of choice. However this treatment plan required thorough knowledge and understanding of prosthodontic principles and attachment use, as well as an awareness of the complexity and complications associated with its use.

The goals for the successful treatment in attachment retained cast partial denture include 2 main factors:

- The development of a stress-directing attachment design and
- Distribution of forces between the abutment teeth and residual ridge.

V. Conclusion

Attachment retained RPD is a viable treatment option in unilateral or bilateral distal extension condition and if patient is more concern about esthetics and economic condition does not permit the use of dental implants, then precision attachment retained cast partial dentures would be an excellent option as it provide adequate retention, stability, esthetics and function.

References

- [1]. Patil R. Esthetic dentistry – an artist's science. 1st ed. Mumbai: PR Publications; 2005.
- [2]. Lil W, Solar P. Indications, diagnosis, and recall. In: Watzek G, editor. Endosseous implants: scientific and clinical aspects. Chicago (IL): Quintessence; 1996. p. 153-182.
- [3]. Master M, Shetty O, Charushila SS. Full mouth rehabilitation of a patient using cast partial dentures with precision attachments. Heal Talk 2013;5(5):26-28.
- [4]. Ku YC, Shen YF, Chan CP. Extracoronal resilient attachments in distal-extension removable partial dentures. Quintessence Int 2000 May; 31(5):311-317.
- [5]. Burns DR, Ward JE. A review of attachments for removable partial denture design: Part 1. Classification and selection. Int J Prosthodont 1990; 3:98-102.
- [6]. Burns DR, Ward JE. A review of attachments for removable partial denture design: Part 2. Treatment planning and attachment selection. Int J Prosthodont 1990; 3:169-74.
- [7]. Glossary of Prosthodontic Terms – 8, J Prosthet Dent, 2005.
- [8]. Preiskel HW. Precision attachment in prosthodontics. 1&2. London: Quintessence Publishing Co Ltd, 1995.
- [9]. Makkar S, Chhabra A, Khare A. Attachment retained removable partial denture: A case report. Int Journal of Clinical Dental Science 2011; 2(2):39-43.