

A Clinical Study of Efficacy of Dermis Fat Graft as Primary Orbital Implant Following Evisceration and Enucleation

Dr.Mvdl Satyanarayana .M.S¹, Dr.M.Preethy²

¹Asst professor of ophthalmology,RIMS,Kadapa.

²Post graduate in ophthalmology,RIMS,Kadapa.

Corresponding author: Dr.Mvdl Satyanarayana

ABSTRACT:

AIM:The aim is to provide evidence for dermal fat graft as a safe and stable primary orbital implant for orbital volume replacement following ocular evisceration and enucleation.

METHODS: Study was conducted on 15 patients undergoing evisceration and enucleation for various reasons who underwent dermis fat graft as a primary implant. Out of 15 patients 6 were females and 9 were males. Graft was taken from the peri umbilical area. Post-operative orbital volume replacement was evaluated by Luedde's exophthalmometer.

RESULT: Out of 15 patients 6 females, 9 males were included in the study. Good orbital volume replacement noted in 93.3% of the patients. Suture abscess was noted in 6.7% patients. At 6 weeks post-operatively, patients received an ocular prosthesis. Prosthesis fit was stable due to deepened fornices.

CONCLUSION: Dermis fat graft as a primary orbital implant in patients undergoing evisceration and enucleation is cosmetically better with good orbital volume replacement and stable prosthesis fitting with good motility.

Key words: dermis fat graft, orbital volume replacement, primary orbital implants

Date of Submission: 02-09-2018

Date of acceptance: 18-09-2018

I. Introduction

Smith and Petrelli³ first described the use of autogenous dermis fat grafts as a secondary implant following extrusion. As a primary implant, the use of dermis fat graft has been described following ocular enucleation.¹⁵ Despite the success of alloplastic implants, autogenous graft as an orbital implant should not be discounted, as complications arising from alloplastic implants such as exposure and extrusion have been reported. In particular, exposure rates of porous implants after evisceration and enucleation range from 2 to 10%.^{16,17}

It is associated with low morbidity and a satisfactory cosmetic result.⁵

The DFG is composed of dermis and subcutaneous fat, after removal of the epidermis. The dermis is believed to enhance vascularisation and decrease the incidence of fat atrophy. It also acts as a barrier against fatty augmentation. The site most frequently used to harvest the graft is the gluteal area, but other areas such as the abdomen and the periumbilical can also be used to harvest such a graft.⁶

Method of data collection

Sample size: 15

Study type: prospective study

Patients attending out-patient department of ophthalmology, RIMS, Kadapa, requiring evisceration or enucleation for various reasons were enrolled in the study. Informed consent was obtained from all patients prior to entry in the study.

II. Materials and methods

A total of 15 patients presenting to the out-patient department of ophthalmology, RIMS, Kadapa, requiring evisceration and enucleation for various reasons were enrolled in the study. A detailed history was taken. Anterior segment was examined using slit lamp. Ophthalmoscopic examination, proptometry, tonometry were done wherever necessary. Examination also included assessment of general health, routine blood tests (blood sugar, haemoglobin, total and differential leucocyte count) blood pressure, and electrocardiogram. CT-scan/MRI was advised wherever necessary. Patients were taken for either evisceration or enucleation depending on the condition of the eye. This was followed by dermis fat grafting. Graft was taken from the peri umbilical region.

Procedure:

All procedures were performed under local anesthesia

Procedure of evisceration

360°peritomy done followed by limbal incision with 15 no blade .Corneal button removed .uvea was seperated from the sclera with the help of evisceration spatula and Intra-ocular contents scooped out using evisceration scoop. After the procedure sclera shell was thoroughly cleaned with absolute alcohol.

Procedure of enucleation

- 360°peritomy done. All the 6 extra-ocular muscles were identified, secured and disinserted.
- Optic nerve cut and the eyeball removed.

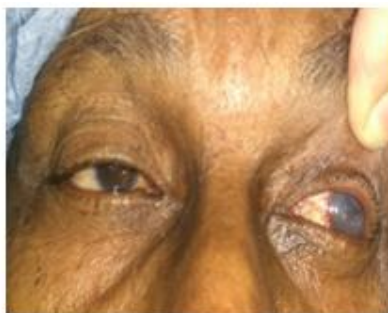

Fig 1 :pre-operative picture of the patient with painful blind eye due to absolute glaucoma.

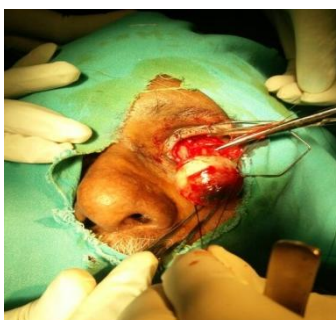

fig 2 :enucleaton of the eyeball

Harvesting dermis fat graft.

- After local anaesthesia the epidermis over the marked out site with pre-determined measurements was shaved off with No. 15 surgical blade.The underlying dermis with fat was then excised using No. 15 blade and scissors elliptically tofit into the orbital socket (20-25mm in longest diameter, and about 4–6cm in depth) and placed in saline solution and the wound was closed.

DFG implantation

- DFG was implanted into the posterior tenon’s space. Secured extraocularmuscles ,anteriortenons and then conjunctiva was sutured to the edge of DFG with 6/0 Vicryl suture in an interrupted fashion.
- In evisceration scleral shell opened by four petal technique and DFG was placed inside the scleral shell and sclera sutured to margins of DFG with 6-0 vicryl and a conformer was placed over the conjunctiva into the fornices.
- Post operatively, the eyes were treated with oral antibiotics, NSAIDs and topical antibiotic eye drops for one week. Patients were followed up till 6 months.
- Sutures at the harvested site were removed 1 week postoperatively. At 4 weeks the patient received an ocular prosthesis.

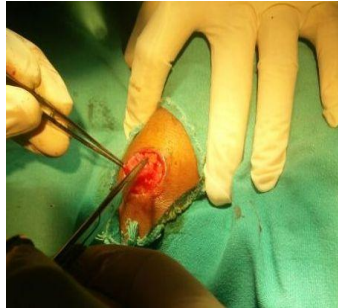

FIG :3:harvesting dermis fat graft from peri umbilical region.

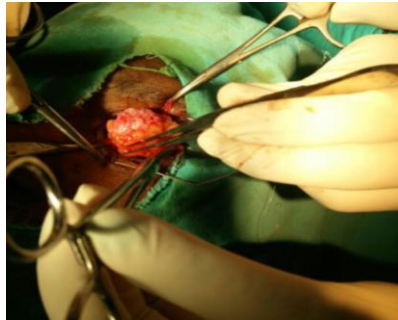


fig 4:Implantation of the dermis fat graft

III. Results

Prospective study done on 15 patients who underwent evisceration/enucleation with primary dermis fat grafting.

Table 1 Sex distribution in the study

Sex of the patients	Frequency	Percent
Valid		
female	6	40
male	9	60
Total	15	100.0

4 patients underwent evisceration and 8 undergone enucleation.

Table 2 Indications

CAUSE	NUMBER	INDICATION
Open globe injuries	5	Enucleation
Painful blind eye	6	Enucleation
Endophthalmitis	2	evisceration
Anterior staphyloma	2	Evisceration

Table 3 :laterality of eye

laterality	number
left	10
right	5
Total	15

All patients underwent primary dermisfat grafting after enucleation/evisceration.Following dermis fat grafting, orbital volume replacement was studied by luedde'sproptometer at day 1, 4 weeks,8 weeks , and 6 months post operatively.

Table 4 Proptometry reading of the other eye and test eye following dermis fat grafting`

Other eye(mm)	Post op day 1	Post op 4wks	Post op 8 wks	Post op 6 months
19	23	19	15	15
18	24	21	19	19
22	24	22	20	20
23	25	23	22	22

19	25	23	22	22
17	26	23	21	21
23	27	24	21	21
18	24	21	20	20
22	24	22	21	21
20	24	21	20	20
19	22	20	19	19
24	26	22	21	21
Avg -20.33	24.5	21.75	20.08	20.08

Mean proptometry of the other eye was 20.33. Operated eye mean proptometry was 24.5mm on post-op day 1, 21.75mm post-op 4th week, and 20.08mm post-op 8th weeks and 6 months.

14 out of 15 patients had good graft take up. In only one patient due to underestimation of amount of graft good orbital volume is not maintained. 93.3% success rate found in the procedure done.

In 14 out of 15 patients, socket with the graft was healthy with deep fornices. Prosthesis fit was stable.

fig 5:pre operative picture



fig 6: post operative after 8 wks



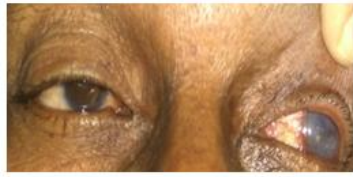

Fig 7: preoperative picture

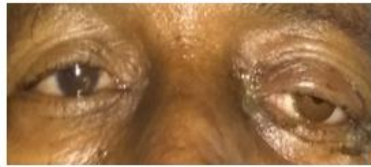


fig 8: postoperative 8 wks

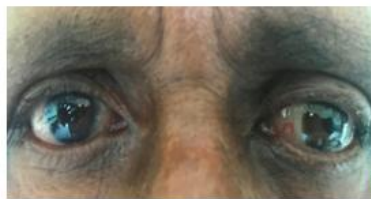

Fig 9: post operative 6 months

Table 5: Number of successful prosthesis fit

Prosthesis fit		Frequency	Valid Percent
Valid	fail	1	6.7
	good	14	93.3
	Total	15	100

IV. Discussion:

The use of dermis fat graft to reconstruct an anophthalmic socket was first described by Smith and Petrelli in 1978³. Autologous dermis fat graft (DFG), composed of dermis and an attached subcutaneous fat, is an acceptable volume replacement implant for primary enucleation and evisceration.⁹⁻¹⁴ The dermal component, in orbit reconstruction provides structural support for the ingrowth of conjunctiva over the graft and its eventual vascularization. This minimizes reabsorption of graft fat with resultant replacement of lost orbital volume.¹¹

It also preserves conjunctival surface area and deepens conjunctival fornix depth to enhance prosthesis fitting.¹¹ being autologous, it has neither the risk of rejection nor transfer of infection from cadaveric homologous tissue.¹²⁻¹⁴

Since their first use in orbital surgery by Smith and Petrelli in 1978,³ DFGs have been widely used in the reconstruction of the anophthalmic socket, both primarily after enucleation and secondarily after extrusion or migration of an existing alloplastic implant. DFG orbital implant is an effective means of replacing orbital volume and affording motility of the ocular prosthesis. It is associated with low morbidity and a satisfactory cosmetic result.¹

The DFG is composed of dermis and appended subcutaneous fat, after removal of the epidermis. The dermis is believed to enhance vascularization and decrease the incidence of fat atrophy. It also acts as a barrier against fatty augmentation. The site most frequently used to harvest the graft is the gluteal area, but other areas such as the abdomen and the periumbilical can also be used to harvest such a graft.⁴

In the orbit, special attention should be given when performing this procedure, the most important being to respect the vascular supply of the recipient bed. Thus, it should not be used in any orbit with compromised vascular supply, such as after severe trauma (in particular chemical burns), irradiation, or in patients with systemic vascular disease because the risk of graft atrophy and loss is significantly increased. The DFG should be in contact with orbital fat to enhance graft viability. Thus, Tenon's fascia, sclera, or pseudocapsule left after implant extrusion should be incised or excised to facilitate this.

Other important aspects to prevent or minimize the complications are to avoid the following: excessive cautery of the graft bed, use of oversized grafts, excessive handling of the graft and excessive pressure on the graft following implantation. A meticulous suturing technique is mandatory. It has been seen that a fat pad thickness of 20mm significantly lowers the incidence of enophthalmos and superior sulcus deformity with no compromise to implant motility.⁵

Although mainly performed following enucleation, DFG orbital implants have been performed following evisceration whereby the edge of the graft was sutured to the anterior scleral ring.⁶Conjunctival re-epithelialization of the dermal surface and enhancement of orbital volume after dermis-fat grafting in eviscerated sockets have been reported.⁶It is advisable to make relaxing incisions into the base of the existing scleral bed to provide an adequate vascular bed for the composite DFG.⁷

DFG offers the advantages of replacing the lost orbital volume as well as preserving conjunctival surface area. This is achieved by partially covering the implanted dermis with conjunctiva and leaving an exposed area of dermis similar to the diameter of the cornea. Normal fornix depth is also maintained. There is no risk of infection transmission, implant extrusion or exposure. Additionally, this procedure carries no extra cost and offersexcellent cosmetic and functional results. Disadvantages include a certain lack of predictability such as underestimation of the adequate volume required of the harvested graft. Further, DFGs also produces a scar at the donor site.

Complications are usually minor. Most complications can be avoided by employing the careful surgical techniques mentioned earlier. Fat atrophy and volume loss are variable and may require further dermis-fat grafting. This complication is commonly seen in cases of secondary implantation, particularly following chemical injuries.¹Graft atrophy is usually seen in older patients. In contrast, fatty augmentation causing increase in the size of the graft is usually seen in young children, representing the normal proliferation of fat cells seen in the young. This complication is managed by surgical debulking of the graft.⁸ Graft failure is usually associated with a compromised orbital vascular supply.

V. Conclusion:

Dermis fat graft as a primary implant in patients undergoing evisceration and enucleation is cosmetically better with good orbital volume replacement and stable prosthesis fitting with good motility.

References

- [1]. Smith B, Bosniak S, Nesi F, Lisman R. Dermis-fat orbital implantation: 118 cases. *Ophthalmic Surg.* 1983;14:941-943. [PubMed]
- [2]. The autogenous dermis-fat orbital implant in children. Mitchell KT, Hollsten DA, White WL, O'Hara MA. *J AAPOS.* 2001;5:367-369. [PubMed]
- [3]. Smith B, Petrelli R. Dermis-fat graft as a movable implant within the muscle cone. *Am J Ophthalmol.* 1978;85:62-66. [PubMed]
- [4]. Bonavolonta G, Tranfa F, Salicone A, Strianese D. Orbital dermis-fat graft using periumbilical tissue. *PlastReconstr Surg.* 105:23-26. 200. [PubMed]
- [5]. Sihota R, Sujatha Y, Betharia SM. The fat pad in dermis fat grafts. *Ophthalmology.* 1994;101:231-234.[PubMed]
- [6]. Borodic GE, Townsend DJ, Beyer-Machule CK. Dermis fat graft in eviscerated sockets. *OphthalPlastReconstr Surg.* 1989;5:144-149. [PubMed]
- [7]. Lasudry J, Jonckheere P, Robert P-V, Adenis J-P. Dermis-fat graft in orbital surgery. *Oper Tech in Oculoplast Orbit and Reconstr Surg.* 2001;4:15-24.
- [8]. Smith EM, Jr, Dryden RM, Tabin GC, Thomas D, To KW, Hofmann RJ. Comparison of the effects of enucleation and orbital reconstruction using free-fat grafts, dermis grafts, and porous polyethylene implants in infant rabbits. *OphthalPlastReconstr Surg.* 1998;14:415-424. [PubMed]
- [9]. Essuman VA, Tagoe N N, Ndanu T A, Ntim-Amponsah C T. Dermis-Fat Grafts and Enucleation in Children in a West African Population. *PlastReconstr Surg.* 2013;131(3):457e-458e. doi: 10.1097/PRS.0b013e31827c7365. [PubMed] [Cross Ref]
- [10]. Sami D, Young S, Petersen R. Perspective on Orbital Enucleation Implants. *Surv Ophthalmol.*2007;52(3):244-265. [PubMed]
- [11]. Martin P, Rogers P, Billson F. Dermis-fat: evolution of a living prosthesis. *Aust and N Z J Ophthalmol.*1986;14(2):161-165. [PubMed]
- [12]. Al-Mujaini Abdullah, Ganesh Anuradha, Al-Zuhaibi Sana. Autogenous Dermis-Fat Orbital Implant for Anophthalmic Socket. *Sultan QaboosUniv Med J.* 2007;7(2):145-148. [PMC free article] [PubMed]
- [13]. Mitchell KT, Hollsten DA, White WL, O'Hara MA. The Autogenous Dermis-Fat Orbital Implant in Children. *J AAPOS.* 2001;5(6):367-369. [PubMed]
- [14]. Reza V M, McMullan TFW, Burroughs JR, Isaacs DK, Tsirbas A, White GL, Jr, Anderson RL, McCann JD. Autologous dermis graft at the time of evisceration or enucleation. *Br J Ophthalmol.* 2007;91(11):1528-1531. [PMC free article] [PubMed]
- [15]. Paris GL, Spohn WG. Correction of enophthalmos in the anophthalmic orbit. *Ophthalmology.* 1980;87:1301-8.
- [16]. Li T, Shen J, Duffy MT. Exposure rates of wrapped and unwrapped orbital implants following enucleation. *OphthalPlastReconstr Surg.* 2001;17:431-5.
- [17]. McNab A. Hydroxyapatite orbital implants. Experience with 100 cases. *Aust N Z J Ophthalmol.* 1995;23:117-23.

Dr.Mvdl Satyanarayana "ACLINICAL STUDY OF EFFICACY OF DERMIS FAT GRAFT AS PRIMARY ORBITAL IMPLANT FOLLOWING EVISCERATION AND EUCLEATION".IOSR Journal of Dental and Medical Sciences (IOSR-JDMS), vol. 17, no. 9, 2018, pp 45-50.