

Role of Alloplast in Alveolar Ridge Preservation

Dr Ravish Mishra¹, Dr Snigdha Shubham², Dr Deepak Yadav³, Dr Laxmi Kandel⁴, Dr Shashank Tripathi⁵, Dr B. K. Chakrovorty⁶, Dr S. K. Lall⁷

¹(Department of Oral and Maxillofacial Surgery, Universal College of Medical Sciences/ Tribhuwan University, Nepal)

²(Department of Conservative Dentistry and Endodontics, Universal College of Medical Sciences/ Tribhuwan University, Nepal)

^{3,4,5,6,7}(Department of Oral and Maxillofacial Surgery, Universal College of Medical Sciences/ Tribhuwan University, Nepal)

Corresponding author: Dr Ravish Mishra

Abstract : Introduction: Extraction involves bone resorption and soft tissue contraction, events that can compromise the ideal implant placement along with other future prosthesis with functional and aesthetics limitations. Following tooth extraction, socket preservation techniques can limit bone resorption. The present study compared non grafted versus grafted extraction socket with hydroxyapatite clinically and radiographically at subsequent time interval. **Materials and methods:** A total of 40 patients with posterior extraction sockets were divided into two groups: 20 sockets received hydroxyapatite bone graft as a test group and 20 sockets were left for secondary healing as control group. At subsequent time intervals of 1 week, 1 month, 3 months and 6 months; alveolar ridge from both groups were evaluated clinically and radiographically. Statistical analysis was performed. **Results:** The mean changes in clinical width post operatively 6 months was from 10.46mm(±1.51) to 7.15mm(±1.45) in control group whereas 10.32mm(±1.51) to 8.31mm(±1.20) in test group ($p < 0.05$). The mean radiographic height changes in control group was 17.66mm(±1.03) preoperatively to 14.52mm(±1.19) at 6 months follow up whereas changes was only from 17.37mm(±1.33) to 16.68mm(±1.40) in test group ($p < 0.05$). Pain was more in test group than in control group at 1 month follow up ($p < 0.05$). No pain was observed in both groups at 3 months and 6 months follow up. Infection was not present in both groups. **Conclusion:** Ridge preservation with hydroxyapatite bone graft can be used as an alternative treatment for maintaining ridge dimensions.

Key words: extraction, hydroxyapatite, ridge preservation, socket preservation

Date of Submission: 30-08-2018

Date of acceptance: 15-09-2018

I. Introduction

Alveolar ridge resorption is a phenomenon observed following the removal of teeth in an otherwise healthy individual. The condition appears to be progressive and irreversible, resulting in a host of prosthodontic, esthetic, and functional problems. Postextraction bone loss is accelerated in the first 6 months, followed by a gradual modeling (change in size or shape) and remodeling (turnover of existing bone) of the remaining bone, with as much as 40% of the alveolar height and 60% of alveolar width lost in the first 6 months. Loss of ridge height results in prosthetic instability as the crest of the ridge approaches muscle attachments and mobile mucosa.[1]

Johnson (1969) first demonstrated 40 years ago that a reduction from 2.5 to 7 mm in height and up to 3 mm in width could follow a tooth extraction. It was observed that most changes occurred during the first month, while a minor additional decrease in the ridge continued over periods ranging between 10 and 20 weeks.[2] A greater amount of tissue attenuation occurs in the buccal wall of the molar area rather than frontal zone.[3] A reduction in residual alveolar ridge up to 50% in width may occur 12 months after tooth extraction.[4]

Anatomically buccal (labial, facial) alveolar bone ridge is thinner than lingual (palatal). Alveolar sockets are lined by cortical bone (alveolar bone proper or bundle bone, which radiologically appears as 'lamina dura') – the thin layer which forms a big part of fine coronal alveolar socket wall as well.[4, 5] It is important that 1-2 mm of lamina dura form an alveolar bone ridge which is a part of periodontium (bundle bone of lingual wall is thinner). When a tooth is extracted, periodontium is destroyed so resorption of bundle bone follows.[6] In addition, resorption increases because of mucoperiosteal flap elevation.[3]

Therefore, to modify bone remodeling after extraction, various ridge preservation techniques have been followed. As a matter of principle, ridge preservation is defined as a procedure undertaken at the time of tooth extraction, which is designed to minimize external resorption of the ridge and to maximize bone formation

within the socket. The scientific literature indicates that preservation techniques have succeeded in maintaining ridge height and width when compared with tooth extraction alone.[5] Hence, in present study ridge preservation potential of hydroxyapatite grafted socket was compared with non grafted extraction socket radiographically and clinically.

II. Materials and Methodology

A prospective clinical trial was carried out in patients who came for extraction of maxillary and mandibular teeth in Department of Oral and Maxillofacial Surgery, UCMS College of Dental Surgery. 40 medically fit patients were selected for the study. Informed consent was taken prior to procedure and the source data was collected in enclosed proforma. All patients were randomly categorized into two groups i.e. test and control with 20 patients in each group.

The patients were divided into Group 1 and Group 2 randomly irrespective of age, sex, caste or religion.

Group 1: Patient undergone extraction of teeth followed by grafting with hydroxyapatite bone grafts and primary closure.

Group 2: Patient undergone extraction of teeth without hydroxyapatite bone graft and left the socket for secondary healing.

Demographic variables and relevant clinical and radiological findings were noted on standardized data sheet. The patients were investigated for routine pre-operative hematological investigations (Bleeding Time, Clotting Time, Haemoglobin percentage, Random Blood Sugar Level).

Pre-operative intraoral periapical radiograph (IOPAR) was taken to assess the alveolar bone height. Along with it, alginate impression was made to obtain study cast for the assessment of alveolar ridge height and width at pre-operative and 6 month time subsequently.

The surgical procedure was carried out after obtaining an informed consent from the patient. Following a standard basic surgical preparation, local anaesthetic solution containing adrenaline (1:200,000) was injected to attain local anaesthesia. Atraumatic extraction of teeth followed by socket irrigation with povidone iodine was done.

Extraction socket was filled with hydroxyapatite granules (G – Bone®) of average particle size of 0.8 – 1.8 mm and mucosa was sutured with non resorbable suture material. Non grafted socket which was filled with blood clot was assigned as a control. All patients were given post operative antibiotics ; amoxycillin 500 mg for 5 days and analgesic ibuprofen 400 mg per oral for 3 days. Patients were reviewed regularly post operatively at 1 week, 1 month, 3 months and 6 months interval for re-evaluation both clinically and radiographically. The pre and post operative measurements were compared and evaluated on following parameters:

- i. Pain- evaluated using VAS(Visual analogue scale)
- ii. Infection- evaluated on the clinical presentation such as presence of any inflammatory changes, purulent discharge, and graft exposure.
- iii. Clinical width in millimeters (mm) - measured preoperatively and postoperatively six months after performing bone sounding in patients and then preparing a diagnostic casts. The preoperative measurement was compared with post operative measurement.
- iv. Radiographic height in millimeters (mm) - Paralleling technique was used for measurement of radiographic height of alveolar ridge with the help of a software Foxit Reader at 90 degree angulation from defined anatomic reference such as superior border of inferior alveolar canal in case of mandibular molars, inferior lining of maxillary sinus in case of maxillary molars, etc.

Data were collected and statistical analysis of results was performed using unpaired t- test for quantitative analysis and chi - square test for qualitative analysis.

III. Result

40 patients were enrolled and followed up for 6 months postoperatively for evaluation of clinical width, radiographic height,pain and infection. Mean changes in clinical width was from 10.46 (± 1.51) to 7.15 (± 1.45) in post operative 6 month follow up in control group whereas mean changes in test group was only 10.32 (± 1.51) to 8.31 (± 1.20) as shown in Fig(1).Radiographic height in control and test group was statistically significant($p < 0.05$) only after 3 weeks of follow up as shown in Table(1).Mild pain was prolonged in test group for 1 month duration whereas in control group pain subsided after only 1 week as shown in Fig(2 and 3).No sign of infection was present in either control or test group.

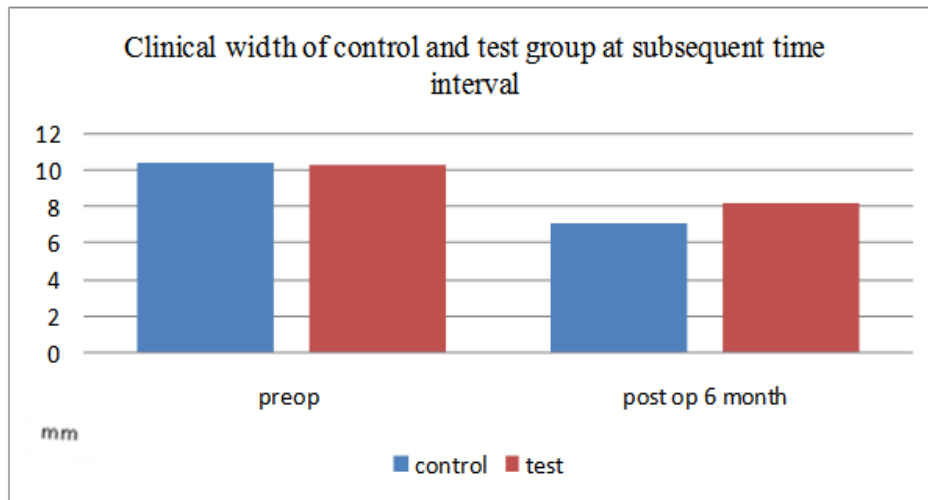
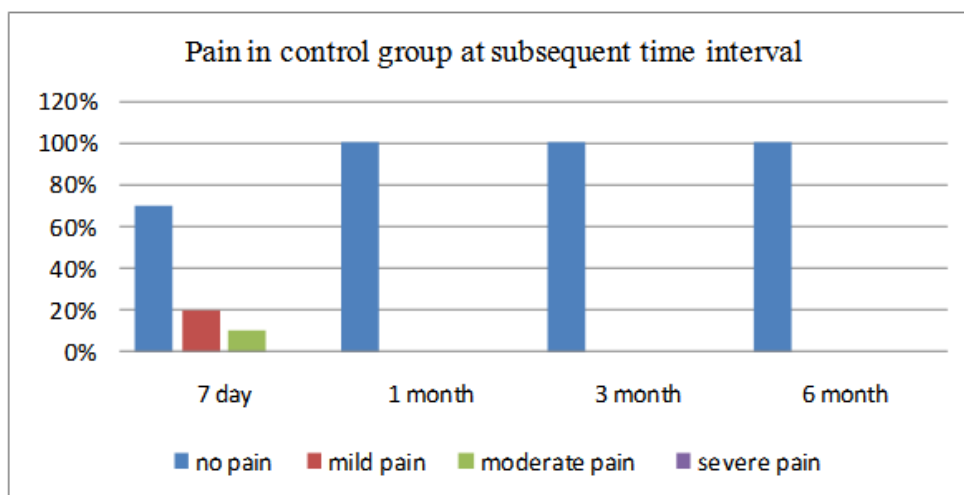


Figure 1: The changes in clinical width of alveolar ridge of control and test group at subsequent time interval.

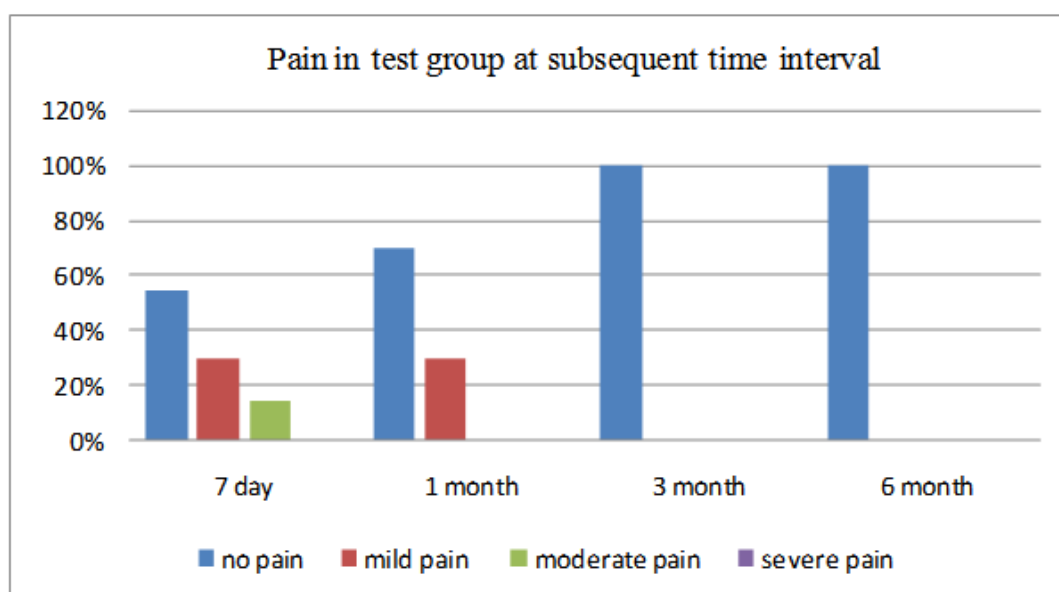
Table 1: Association of non grafted and grafted extraction socket with radiographic height at subsequent time intervals.

Time interval	RADIOGRAPHIC HEIGHT		p value
	Control mean (\pm SD)	Test mean(\pm SD)	
Pre-operative	17.66 (\pm 1.03)	17.37 (\pm 1.33)	0.44
Post-op 1 week	17.12 (\pm 1.07)	16.89 (\pm 1.43)	0.58
Post-op 1 month	16.16 (\pm 1.17)	16.74 (\pm 1.46)	0.17
Post-op 3 month	15.56 (\pm 1.17)	16.70 (\pm 1.43)	0.009
Post-op 6 month	14.52 (\pm 1.19)	16.68 (\pm 1.40)	0.001

Table 1 shows mean radiographic height changes in control group was 17.66 (\pm 1.03) preoperatively to 14.52 (\pm 1.19) at 6 month follow up whereas in test group changes was only from 17.37 (\pm 1.33) to 16.68 (\pm 1.40).



Graph 1: Pain in control group (non grafted extraction socket) at subsequent time interval.



Graph 2: Pain in test group (grafted extraction socket) at subsequent time interval.

IV. Discussion

Preclinical and clinical studies have demonstrated that postextraction alveolar ridge volume loss is an irreversible process that involves both horizontal and vertical dimensional reduction. Alveolar ridge atrophy may have a considerable impact on tooth replacement therapy, particularly when implant-supported restorations are planned. Therefore, alveolar ridge preservation (ARP) has become a key component of contemporary clinical dentistry [7].

Literatures have revealed different measures taken for ARP with different biomaterials, which is very important for maintaining the volume and dimension of alveolar ridge height and width for subsequent dental implantology and future prosthetic restorations. In present study the mean loss in clinical ridge width is 3.31 mm in non grafted socket whereas in grafted socket it was only 2.01 mm 6 months postoperatively which is in agreement with the study done by Antonio Barone et al (2012) in which the mean loss in clinical width was 3.6 mm in control group and 1.6 mm in test group[5]. Moreover Fridus Van der Weijden et al (2009) also showed that during post extraction healing period, the mean clinical width change is 3.87 mm which was greater than loss in height assessed both clinically as well as radiographically thus confirming the present study where mean clinical width change was 2.01mm which is greater than change in mean radiographic height i.e. 0.69 mm[8].

The meta-analyses review by Hammerle et al (2012) summarized that alveolar ridge undergoes a mean horizontal reduction in width of 3.80 mm and a mean vertical reduction in height of 1.24 mm within 6 months after tooth extraction without ridge preservation therapies. Regarding the various materials applied to retain alveolar ridge width evaluated in the clinical studies, the systematic reviews did not show significant differences except for the collagen plug alone, which revealed negative results. Moreover, the group advocated that to maximize maintaining ridge volume following tooth extraction, one should consider raising a flap, placing a biomaterial with a low resorption/replacement rate, and trying to obtain primary closure if possible[9]

A systematic review performed by Heggeler et al (2011) on the effect of socket preservation therapies following tooth extraction in nonmolar regions in humans and found that with natural healing after extraction, a reduction in width ranging between 2.6 and 4.6 mm and in height between 0.4 and 3.9 mm was observed in an agreement to the present study. With respect to socket preservation, the freeze-dried bone allograft group performed best with a gain in height and concurrent loss in width of 1.2 mm[10].

Due to scarce of sufficient publication the type of best biomaterial for ARP technique has not been proven but often the literature has revealed hydroxyapatite grafting has shown significant result as for a study by V. Checchi et al (2011) who evaluated two different types of hydroxyapatite (HA) grafting materials i.e. biomimetic HA and nanocrystalline HA placed into fresh extraction sockets, 6 months after tooth extraction, histologically, clinically and radiographically. The authors did not find any differences between biomimetic and nanocrystalline HA and assume that, within the limits of this study, both these materials could be applied into fresh extraction sockets to limit bone resorption [11].

D. Rothamel et al (2008) evaluated the histological response and dimensional ridge alterations following application of a nanocrystalline hydroxyapatite paste (NHA) into fresh extraction sockets in dogs. Histological evaluation showed no statistically significant differences between the corresponding aspects of test

and control sites. Both groups revealed higher alveolar wall resorption on the buccal than on the lingual side at both time periods [12].

In present study, there was gradual decrease in mean radiographic height preoperatively and at subsequent time intervals in both test and control group. At postoperative 7th day and 1 month, gradual resorption of bone i.e. reduction in radiographic ridge height was seen ($p > 0.05$). Whereas at postoperative 3 months and 6 months there was significant radiographic loss in ridge height in control group i.e. 2.1 mm and 3.14 mm respectively and in test group 0.67 mm and 0.69 mm respectively ($p < 0.01$).

Heggeler et al (2011) performed a systematic review on the effect of socket preservation therapies following tooth extraction in nonmolar regions in humans and found that mean loss in height was between 0.4 mm and 3.9 mm which is similar to the present study. With this he also concluded that placing a graft material into a socket has been one proposed method of preserving the natural tissue contours at extraction sites for possible reconstruction with implant supported prosthesis [10].

In a study done by Antonio Barone et al (2012), the mean change in alveolar ridge height i.e. midbuccal region was 3.6 ± 1.5 mm and 0.7 ± 1.4 mm respectively in control and test group which is similar to the present study. With this result they revealed a strong positive ridge preservation effect in favor of the test group (ARP via socket grafting)[5].

Grafting of extraction with hydroxyapatite limits normal resorptive process due to its ability to preserve the space required for new bone formation and its osteoconductive property to serve as scaffold for viable bone healing which further allows for the ingrowth of neovasculature and infiltration of osteogenic precursor cells into graft site. Thus it preserves ridge height and width [13].

Likewise Cardaropoli et al (2012) [14] showed similar result in compared to the present study. But as mentioned earlier, D. Rothamel et al (2008) evaluated the histological response and dimensional ridge alterations following application of a nanocrystalline hydroxyapatite paste (NHA) into fresh extraction sockets in dogs. Histological evaluation showed no statistically significant differences between the corresponding aspects of test and control sites. Both groups revealed higher alveolar wall resorption on the buccal than on the lingual side at both time periods [12]

Furthermore as for correlation of pain, 20% and 10% of control had mild pain and moderate pain respectively while 30% and 15% of test group had mild and moderate pain respectively at 7 day postoperatively ($p > 0.05$). Whereas at 1 month follow up control group had no pain while 30% of test group had mild pain ($p < 0.05$). This could be attributed to greater surgical manipulation of extraction socket in cases where grafting was done. As study done by V. Checchi et al (2011) [11], Daniele Cardaropoli et al (2007)[14], as well as systematic review done by Fridus Van der Weijden et al (2009)[8], G. Avila-Ortiz et al (2014)[7] and pain was statistical insignificance with grafted and non grafted extraction socket.

In the present study, no signs of infection were seen either in control group or in test group which was similar to study done by Susanne Nahles et al (2012)[15], Mazen Almasri et al (2010)[16], V. Checchi et al (2011)[11].

V. Conclusion

The result of the present study showed that ARP via socket grafting with hydroxyapatite can be an effective therapy to prevent physiologic bone loss after extraction, in both the horizontal and the vertical dimension. Nevertheless, a certain degree of ridge volume loss should be expected even if ARP is applied because of continuous remodeling procedure after extraction. Hence, ARP may significantly prevent alveolar bone remodelling postextraction, but this effect is variable, likely due to the influence of local and systemic factors that are not fully understood. While in certain cases ARP could result in the maintenance of sufficient bone volume to place an implant in an ideal restorative position without the need of ancillary implant site development procedures, while in others it would provide a sound bony base for prosthetic rehabilitation.

References

- [1]. Barteck BK. Alveolar Ridge Preservation - Part I. *Journal of Oral Implantology*. XXVII(Four),2001,187-93.
- [2]. Johnson K. A study of the dimensional changes occurring in the maxilla following tooth extraction. *Australian Dental Journal*. 14,1969;; 241-4.
- [3]. Jung R, Philipp A, Annen B, Signorelli L, Thoma D, Hammerle C, et al. Radiographic evaluation of different techniques for ridge preservation after tooth extraction: a randomized controlled clinical trial. *J Clin Periodontol* 40,2013, 90–8.
- [4]. Schroff L, Wenzel A, Kostopolous L, Karring T. Bone healing and soft tissue contour changes following single-tooth extraction: a clinical and radiographic 12-month prospective study. *International Journal of Periodontics and Restorative Dentistry*. 23,2003, 313-23.
- [5]. Barone A, Ricci M, Tonelli P, Santini S, Covani U. Tissue changes of extraction sockets in humans: a comparison of spontaneous healing vs. ridge preservation with secondary soft tissue healing. *Clin Oral Impl Res*. 2012, 1-7.
- [6]. Fickl S, Zuhr O, Wachtel H, Bolz W, Huerzeler M. Tissue alterations after tooth extraction with or without surgical trauma: a volumetric study in beagle dog. *J Clin Periodontol*. 35,2008, 356-63.
- [7]. Ortiz GA, Elangovan S, Kramer KWO, Blanchette D, Dawson DV. Effect of Alveolar Ridge Preservation after Tooth Extraction: A Systematic Review and Meta-analysis. *J Dent Res*. XX(X) 2014, 1-9.

- [8]. Weijden FVd, Dell'Acqua F, Slot DE. Alveolar bone dimensional changes of post-extraction sockets in humans: a systematic review. *J Clin Periodontol.* 36, 2009, 1048-58.
- [9]. Hammerle CH, Araujo MG, Simion M. Evidence - based knowledge on the biology and treatment of extraction sockets. *Clin Oral Impl Res.* 23(5), 2012, 80-2.
- [10]. Heggeler JT, Slot D, Weijden GVd. Effect of socket preservation therapies following tooth extraction in non-molar regions in humans : a systematic review. *Clin Oral Implants Res.* 22(8), 2011, 779-88.
- [11]. Checchi V, Savarino L, Montevecchi M, Felice P, Checchi L. Clinical-radiographic and histological evaluation of two hydroxyapatites in human extraction sockets: a pilot study. *Int J Oral Maxillofac Surg.* 40,2011,526-32.
- [12]. Rothamel D, Schwarz M F, Herten, Engelhardt E, Donath K, Kuehn P, et al. Dimensional ridge alterations following socket preservation using a nanocrystalline hydroxyapatite paste. A histomorphometrical study in dogs. *Int J Oral Maxillofac Surg.* 37, 2008, 741-7.
- [13]. Horowitz R, Holtzclaw D, Rosen PS. A review on alveolar ridge preservation following tooth extraction. *J Evid Base Dent Pract.* 12, 2012, 149-60.
- [14]. Cardropoli D, Cardaropoli G. Preservation of the post-extraction alveolar ridge: a clinical and histologic study. *International Journal of Periodontics Restorative Dentistry.* 28,2008, 469-77.
- [15]. Nahles S, Nack C, Gratecap K, Lage H, Nelson JJ, Nelson K. Bone physiology in human grafted and non-grafted extraction sockets - an immunohistochemical study. *Clin Oral Impl Res.* 2012, 1-8.
- [16]. Almasri M, Altalibi M. Efficacy of reconstruction of alveolar bone using an alloplastic hydroxyapatite tricalcium phosphate graft under biodegradable chambers. *British journal of Oral and Maxillofacial Surgery.* 49, 2011, 469-73.

Dr Ravish Mishra” . Role of Alloplast in Alveolar Ridge Preservation."IOSR Journal of Dental and Medical Sciences (IOSR-JDMS), vol. 17, no. 9, 2018, pp 43-52.