

Antenatal Diagnosis of Upper Airway Obstruction with Bilateral Renal Agenesis: A Rare Case

Dr. Pooja Prajapati, Dr. Rashesh Patel, Dr. N D Bhojwani

Corresponding author: Dr. N D Bhojwani

Abstract: Congenital high airway obstruction syndrome (CHAOS) is the obstruction of the fetal upper airways, which may be partial or complete. It is usually incompatible with life. Prenatal recognition of the disease is quite important due to the recently described management options. Bilateral renal agenesis is also an uncommon prenatal diagnosis. It is a lethal anomaly with 50% of the fetuses being stillborn; the rest would die shortly after birth. It is also associated with many other congenital anomalies many of which have autosomal dominant or recessive inheritance. Absence of kidneys in renal fossae with pulmonary hypoplasia and oligohydramnios or anhydramnios strongly suggests the diagnosis of bilateral renal agenesis.

Keywords: hyperechoic lungs, oligohydramnios, congenital anomalies, fetus, Sonography

Date of Submission: 30-08-2018

Date of acceptance: 14-09-2018

I. Introduction

Congenital high airway obstruction syndrome (CHAOS) is defined as complete or partial obstruction of the fetal upper airways. This clinical condition was brought into notice firstly by Hedrick in the late 1900s. CHAOS is usually caused by atresia or stenosis of the larynx or trachea. The true incidence of CHAOS is unknown. If the syndrome is unrecognized during the prenatal period, it usually results in stillbirth or death shortly after delivery. Fortunately, more cases can be recognized in utero nowadays, as there are significant technical improvements in prenatal imaging. Bilaterally enlarged hyperechoic lungs, dilated airways, and flattened or inverted diaphragm are the typical prenatal sonographic findings. Fetal ascites and nonimmune hydrops may also be associated with the clinical condition. It can be associated with many other congenital anomalies including FRASER syndrome, CRI-DU-CHAT syndrome, TACRD syndrome etc. Due to the recently described management options, prenatal definition of fetal airway obstruction has come into prominence with the hope of neonatal outcome improvements.

CASE REPORT

A 27-year-old multigravida (G3P2A0L2) presented at 22 weeks of gestation (by last menstrual period) for routine antenatal care. Her medical and obstetric histories were unremarkable. She was subjected for routine antenatal ultrasound examination. Ultrasonographic examination showed a single live intrauterine fetus with mean gestational age of 22 weeks and five days, with amniotic fluid index of zero. Evaluation with ultrasound revealed fetal lungs were hyperechoic with inverted diaphragm. Evaluation of fetal abdomen revealed absence of both kidneys in renal fossae as well as in the pelvic cavity with presence of lying down adrenal sign. The fetal urinary bladder could not be delineated during the entire study period. The pregnancy was terminated few days after the ultrasound examination, and a stillborn baby was delivered.

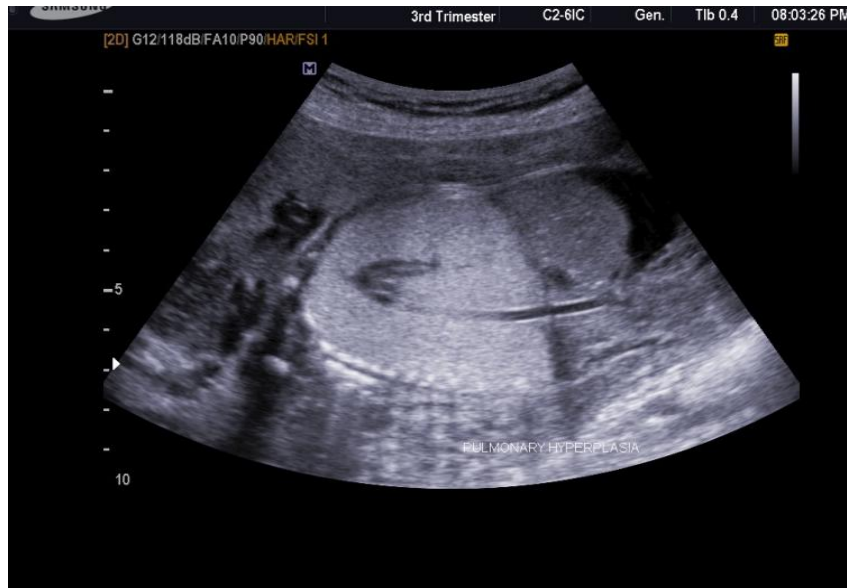

Fig 1

Figure 1: Bilateral lung hyperplasia and echogenic lung with everted diaphragm

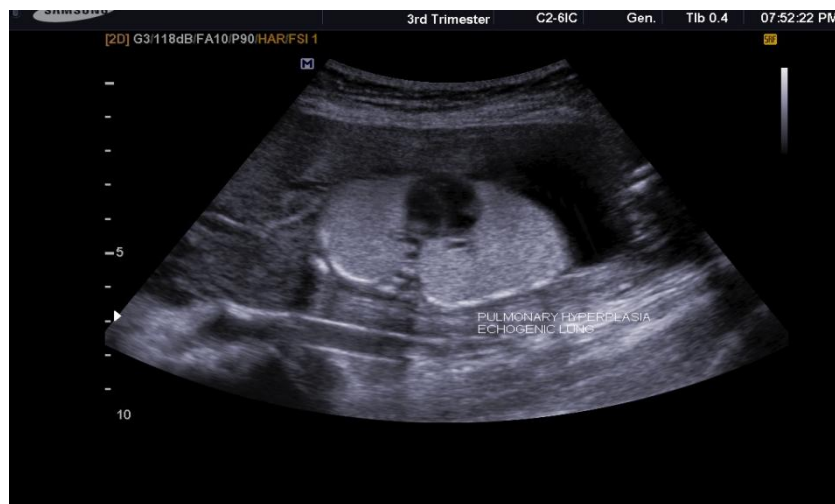

Fig 2

Figure 2: Compressed centrally placed heart

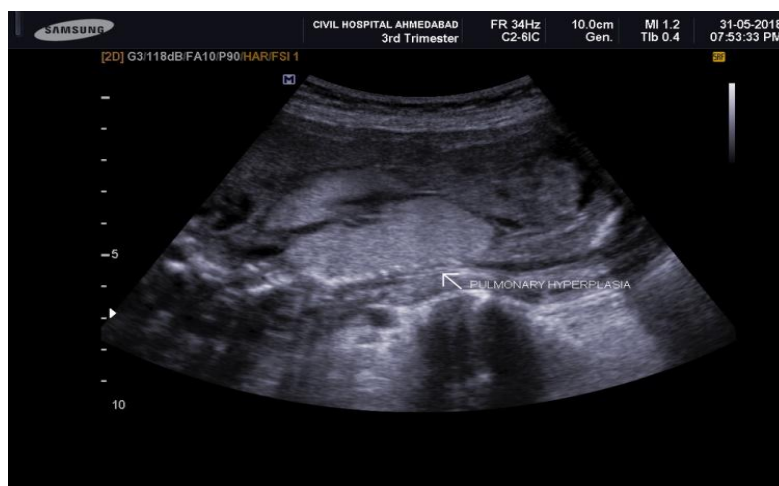

Fig 3

Figure 3: Pulmonary hyperplasia with dilated trachea

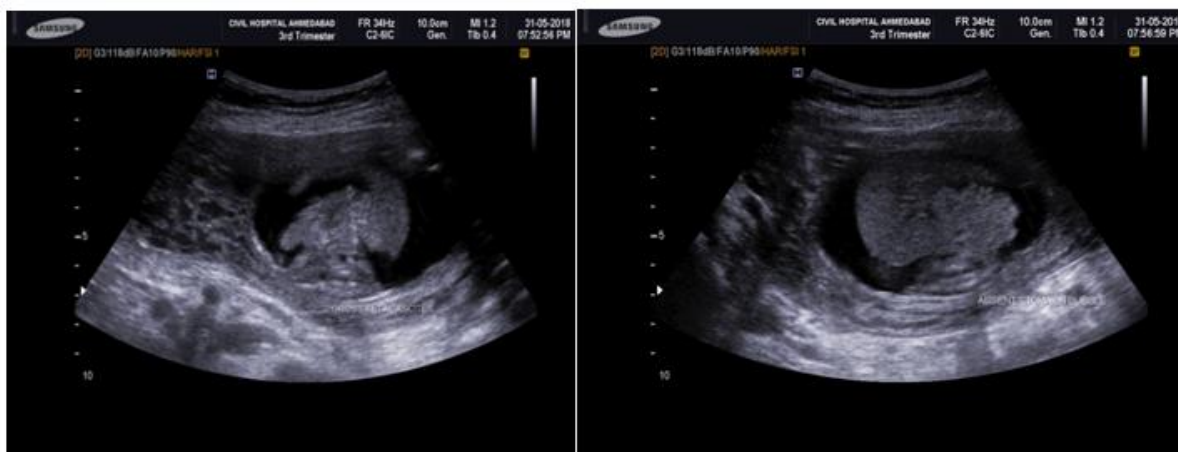


Fig 4 (a)

Fig 4 (b)

Figure 4(a,b): Gross fetal ascites

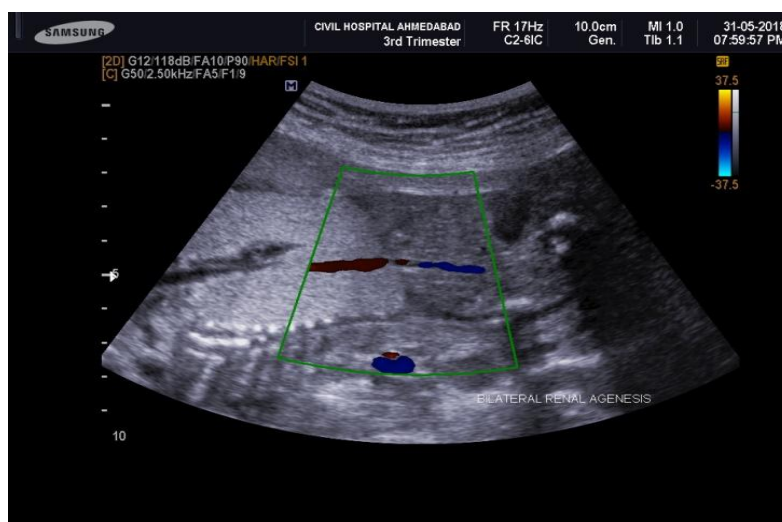


Fig 5

Figure 5: Absence of both kidneys in renal fossae, bilateral renal arteries are also absent with severe oligohydramnios.

II. Discussion

Tracheal atresia is a very rare congenital malformation which takes place by deficient recanalization of the upper airways around the 10th week of gestation resulting in a clinical spectrum defined as congenital high airway obstruction syndrome (CHAOS)¹. In a healthy fetus, the fluid secreted by fetal lung is absorbed through the tracheobronchial tree. However, in case of any obstruction in the tracheobronchial tree, this fluid cannot be cleared. The accumulation of the fetal lung fluid results in gradual increase of intratracheal pressure leading to enlargement of the lungs. It is the beginning of a chain reaction: the enlarged lungs cause compression of the heart and great veins. Due to the compression, the heart replaces centrally and becomes small and dysfunctional. Decreased venous return and dysfunctional cardiovascular system end in ascites and hydrops. The diaphragm flattens or inverts according to the severity of the process². Besides tracheal atresia, the other rare underlying causes of CHAOS are laryngeal agenesis, subglottic stenosis or atresia, and laryngeal webs or cysts. However, the obstruction is mostly secondary to laryngeal atresia^{1,4}.

The main diagnostic tool for prenatal diagnosis of CHAOS is sonography which has typical findings on evaluation. As a natural conclusion of the pathological process, bilateral large hyperechoic lungs, small, compressed, and centrally replaced heart, flattened or inverted diaphragm, and ascites are characteristic findings on sonographic examination³. Regarding the amniotic fluid index, compression of the esophagus by dilated airways may lead to polyhydramnios, as the fetal swallowing of the fluid is disrupted. On the other hand, impaired swallowing of the fetus may also cause oligohydramnios². In our case amniotic fluid index is ZERO, may be due to bilateral renal agenesis. The typical sonographic findings can also be recognized on MRI including voluminous lungs, centrally displaced small heart, inverted diaphragm, and ascites. Sonography is

first-line diagnostic imaging tool due to its low cost and widespread use. However, especially if any fetal surgical intervention is planned, MR imaging can be used additionally by following the dilated airway up to the level of obstruction, as it is more effective for detecting the exact level of obstruction⁵.

CHAOS is most often misdiagnosed as bilateral congenital cystic adenomatoid malformation (CCAM)¹. CCAM (especially type III) and upper airway obstruction secondary to intrinsic causes such as tracheal or laryngeal atresia or stenosis and tracheal webs similarly have bilateral uniform hyperechogenic appearance of the fetal lungs on sonographic examination⁶. In order to make a differentiation between CHAOS and CCAM type III, the obstruction site with distal airway dilatation (present in CHAOS) and the systemic arterial supply (present in CCAM type III) must be clearly seen.

Congenital high airway obstruction syndrome should be also differentiated from extrinsic causes of tracheolaryngeal obstruction. Some of these extrinsic causes are lymphatic malformation, cervical teratoma, and vascular rings like double aortic arch^{1,3}.

Although most cases of CHAOS are sporadic, some cases have been linked to genetic syndromes, the commonest being Fraser's syndrome. This comprises of laryngeal or tracheal atresia, cryptophthalmos, microphthalmia, renal agenesis, orofacial clefting, mental retardation, musculoskeletal anomalies and syndactyly or polydactyly.

However in our case bilateral renal agenesis found but other anomalies like musculoskeletal anomalies and orofacial clefting is not found. Other syndromes which have reported in association with CHAOS are Cri-du-chat syndrome, short-rib polydactyly syndrome, and velo-cardio-facial syndrome. It has been proposed that CHAOS may be a part of an association, which has been given the acronym TACRD (Tracheal Agenesis, complex Cardiac anomalies, Radial ray defects, and Duodenal atresia). This is distinct from the more common VACTERL (Vertebral, Anorectal, Cardiac, Tracheo-Esophageal, Renal, Limb anomalies) association which has tracheoesophageal fistula and not tracheal agenesis as a component. Hence, a suspicion of CHAOS on imaging should prompt a search for associated anomalies too. Antenatally diagnosed cases of CHAOS may be offered an EXIT (ex utero intrapartum treatment) procedure which consists of delivery of the foetal head and chest to secure an airway while simultaneously maintaining the uteroplacental circulation, with tracheostomy being necessary in most cases. Cases of spontaneous antenatal improvement in CHAOS due to spontaneous perforation also suggest that intrauterine foetoscopic laser laryngotomy may be beneficial in a small subset of these patients

In the past, CHAOS was thought to be equivalent to a certain fetal death. However, nowadays, especially if CHAOS due to incomplete obstruction is diagnosed in the late 2nd or in the 3rd trimester and if severe hydrops has not occurred yet, the EXIT procedure (ex utero intrapartum treatment) can be offered. The common objective of the procedure is to settle an intact airway for the baby before the fetomaternal circulation is stopped⁸.

As a result, CHAOS is a rare and fatal cause of congenital airway obstruction if unrecognized during prenatal period. Antenatal sonographic imaging shows typical findings which can lead to a diagnosis.

Management:

With the use of the ex utero intrapartum treatment (EXIT) procedure, a marked improvement in survival can now be accomplished. The EXIT procedure involves partial delivery of the fetus via a hysterotomy while both the placenta and umbilical cord remain intact. Halogenated agents are administered to the mother in order to promote uterine relaxation. The fetus remains hemodynamically stable, as the uteroplacental gas exchange is maintained. Mean times of hemodynamic stability have ranged from 18 to 45 min⁹. This allows for a controlled environment to manage the airway, as opposed to a more emergent attempt at airway access at birth⁹. A common strategy is to first attempt intubation via direct laryngoscopy. If the airway is not adequately visualized then rigid bronchoscopy is attempted. If an endotracheal tube is unable to be passed, tracheotomy is the final option. Although the EXIT procedure was initially developed to deliver fetuses with congenital diaphragmatic hernia after tracheal occlusion, it has also demonstrated success in the treatment of fetuses with obstructing neck masses and cleft lip and palate^{10,11,12}.

In a study by Wagner and Harrison¹¹, an airway was established in 79% of the 29 cases reviewed using the EXIT procedure, with an overall survival rate of 69%. Another study with 13 patients treated with the EXIT procedure for obstructive neck masses resulted in only one death⁹. Successful management of CHAOS has been achieved with a combination of fetal tracheostomy and delivery using the EXIT procedure¹¹. Fetal MRI has demonstrated its value in the facilitation of treatment planning in fetal upper airway obstruction. With a large field of view and high soft-tissue contrast, MRI can produce images that are easily understood by clinicians. Prenatal MRI can be used to delineate tumor extent, evaluate facial involvement and demonstrate the relationship of the mass to the trachea. Similarly, prenatal MRI can be used to confirm the diagnosis of CHAOS prior to undertaking fetal surgery.

III. Conclusion

To conclude we have described a case of CHAOS with bilateral renal agenesis in utero. CHAOS has characteristic sonographic features, can be detected in the prenatal period and is associated with a poor prognosis

References

- [1]. J. L. Roybal, K. W. Liechty, H. L. Hedrick et al., "Predicting the severity of congenital high airway obstruction syndrome," *Journal of Pediatric Surgery*, vol. 45, no. 8, pp. 1633–1639, 2010.
- [2]. P. Joshi, L. Satija, R. A. George et al., "Congenital high airway obstruction syndrome-antenatal diagnosis of a rare case of airway obstruction using multimodality imaging," *Medical Journal Armed Forces India*, vol. 68, no. 1, pp. 78–80, 2012.
- [3]. M. Garg, "Case report: antenatal diagnosis of congenital high airway obstruction syndrome. Laryngeal atresia," *Indian Journal of Radiology and Imaging*, vol. 18, no. 4, pp. 350–351, 2008.
- [4]. J. Courtier, L. Poder, Z. J. Wang, A. C. Westphalen, B. M. Yeh, and F. V. Coakley, "Fetal tracheolaryngeal airway obstruction: prenatal evaluation by sonography and MRI," *Pediatric Radiology*, vol. 40, no. 11, pp. 1800–1805, 2010.
- [5]. F. V. Coakley, H. Hricak, R. A. Filly, A. J. Barkovich, and M. R. Harrison, "Complex fetal disorders: effect of MR imaging on management: preliminary clinical experience," *Radiology*, vol. 213, no. 3, pp. 691–696, 1999.
- [6]. S. J. King, D. W. Pilling, and S. Walkinshaw, "Fetal echogenic lung lesions: prenatal ultrasound diagnosis and outcome," *Pediatric Radiology*, vol. 25, no. 3, pp. 208–210, 1995.
- [7]. P. Vanhaesebrouck, K. De Coen, P. Defoort et al., "Evidence for autosomal dominant inheritance in prenatally diagnosed CHAOS," *European Journal of Pediatrics*, vol. 165, no. 10, pp. 706–708, 2006.
- [8]. P. Walker, J. Cassey, and S. O'Callaghan, "Management of antenatally detected fetal airway obstruction," *International Journal of Pediatric Otorhinolaryngology*, vol. 69, no. 6, pp. 805–809, 2005.
- [9]. . Woodward PJ, Sohaey R, Kennedy A, et al. From the archives of the AFIP: a comprehensive review of fetal tumors with pathologic correlation. *Radiographics*. 2005;24:215–242. doi: 10.1148/rg.251045156.
- [10]. Hirose S, Farmer DL, Lee H, et al. The ex utero inpartum treatment procedure: looking back at the EXIT. *J Pediatr Surg*. 2004;39:375–380. doi: 10.1016/j.jpedsurg.2003.11.011.
- [11]. Wagner W, Harrison MR. Fetal operations in the head and neck area: current state. *Head Neck*. 2002;24:482–490. doi: 10.1002/hed.10083.
- [12]. Bouchard S, Johnson MP, Flake AW, et al. The EXIT procedure: experience and outcome in 31 cases. *J Pediatr Surg*. 2002;37:418–426. doi: 10.1053/jpsu.2002.30839.

Dr. N D Bhojwani, "Antenatal Diagnosis of Upper Airway Obstruction With Bilateral Renal Agenesis: A Rare Case." *IOSR Journal of Dental and Medical Sciences (IOSR-JDMS)*, vol. 17, no. 9, 2018, pp 68-72.