

Magnetic Resonance Imaging in Carcinoma of Cervix

Dr. Mahak Sood, Dr. Ankita Boricha, Dr. Anjana Trivedi, Dr. Chetna Dodiya

Assistant Professor, Department of Radiodiagnosis, PDU Medical College & Govt. hospital, Rajkot

Resident doctor, Department of Radiodiagnosis, PDU Medical College & Govt. hospital, Rajkot

Professor & Head, Department of Radiodiagnosis, PDU Medical College & Govt. hospital, Rajkot

Tutor, Department of Radiodiagnosis, PDU Medical College & Govt. hospital, Rajkot

Corresponding Author: Dr Mahak Sood

Abstract: Cervical carcinoma is the third most common gynecological malignancy (after endometrial and ovarian carcinoma) and is typically seen in younger women , often with serious consequences. MR imaging has become essential in the pretreatment evaluation of the extent and depth of disease to help decide the appropriate management strategy and indicate prognosis. The multiplanar capabilities and excellent soft-tissue contrast on magnetic resonance imaging (MRI) of the pelvis provide superb depiction of the female pelvic anatomy and often lead to specific diagnosis without ionizing radiation. MRI is often used as a problem-solving tool in patients where ultrasound is inconclusive or suboptimal. It is optimal for evaluation of important prognostic factors such as lesion volume and metastatic lymph node involvement that will help determine the treatment strategy. Although the International Federation of Gynecology and Obstetrics (FIGO) staging system is clinically based, the revised 2009 FIGO staging encourages imaging as an adjunct to clinical staging. MRI can stratify patients to the optimum treatment group of primary surgery or combined chemotherapy and radiotherapy. Tumours stage IIa and below are treated with surgery. This review aims to familiarize the radiologist with the MR imaging features of cervical cancer that influence in accurately staging these tumors, decide management and analyse post surgical recurrence rate. The study was done on 50 patients diagnosed clinically with cervical cancer between December 2017 to May 2018 on a 1.5 Tesla MRI machine.

Key words: Cervix, Tumor, Pelvis, Magnetic resonance imaging

Date of Submission: 28-08-2018

Date of acceptance: 10-09-2018

I. Introduction

Cervical carcinoma is the third most common gynecologic malignancy and is typically seen in younger women often with serious consequences. There are many risk factors associated with it. A significant association between Human Papilloma virus (HPV) and development of cervical cancer is there, HPV can be found in 90%-95% of patient with cervical cancer most frequently HPV-16(50%), HPV-18(15%), HPV-45(8%) and HPV-31(5%). Other risk factors are cigarette smoking, low immune system, Chlamydia infection, Intrauterine device and Oral Contraceptive Pills use, multiple sexual partners , high parity, Diethyl Stilbestrol exposure.

Patient typically presents with vaginal bleeding and/ vaginal discharge and sometimes subclinical detection by cervical screening test.

Histological types include Squamous cell carcinoma, Adenocarcinoma which include clear cell carcinoma, endometrioid carcinoma, mucinous and serous carcinoma, mesonephric carcinoma, Neuroendocrine tumour which include small cell carcinoma and Adenosquamous cell carcinoma.

Correct identification of the factors influencing prognosis is crucial for treatment planning. Many of these factors are well depicted at MR imaging.

The most important prognostic factors for cervical cancer are tumor stage and size. The presence and extent of nodal involvement is another important prognostic factor.

The most important issue in staging of cervical cancer is to distinguish early disease (stages I and IIA) that can be treated with surgery from advanced disease (stage IIB or greater) that must be treated with radiation alone or combined with chemotherapy. MRI is the best single accurate imaging investigation that can accurately determine tumor location (exophytic or endocervical), tumor size, depth of stromal invasion, and its extension into the surrounding structures. MRI is also useful in the evaluation of lymph node metastases.

II. Aims & Objectives:

- Studing the radiological findings in patients with cervix cancer.
- Staging of cervical cancer by looking its extent.
- To establish role of MRI in management of patients
- To look for recurrence rate of the cancer.

III. Materials And Methods:

The present study was conducted on patients who were clinically diagnosed with cervical cancer and sent to Radiology department of Pandit Deendayal Upadhyay Medical College, Rajkot, Gujarat .

Study design : Retrospective observation study

Study duration : December 2017 to May 2018.

Sample size : 50 patients

Inclusion criteria:

Suspected cases of cervical carcinoma

Cases with recurrence in previously treated carcinoma

Exclusion criteria:

Patient with cardiac pacemaker or implants where MRI is contraindicated

Claustrophobic or uncooperative patient

Methodology: Each patient underwent MRI of Pelvis by 1.5 Tesla GE MRI machine. MR imaging of pelvis were performed using T1, T2 & STIR sequences with serial sections obtained in the sagittal, axial and coronal planes using a dedicated torso-array surface coil. In some cases the post-contrast study was performed after I.V. injection of gadolinium. Reporting was done by a single consultant radiologist with expertise in reading MRI Pelvis.

MRI PROTOCOL FOR CANCER OF CERVIX:

Sequence	Plane	Technical characteristics
T2-W TSE	Axial(renal hium-pubis)	TR/TE:3500/90,NSA:2,SL/G:4.5/1,Matrix:340x350,FOV:38
	Sagittal	TR/TE:3500/90,NSA:3,SL/G:3.5/1.2,Matrix:348x276,FOV:25
	Axial oblique(perpendicular to cervical axis)	TR/TE:3900/125,NSA:6,SL/G:45/0.4,Matrix:256x176,FOV:18
T1-W TSE	Axial(renal hilum-pubis)	TR/TE:400/13,NSA:1,SL/G:6/2,Matrix:300x205,FOV:36
DWI-EPI	Axial	TR/TE:3000/68,NSA:12,SL/G:6/1,Matrix:124x174,FOV:35
DCE	Sagittal;one native,post contrast images every 17s, total acquisition time about 3 min	TR/TE/FA:15/4.2/45°,NSA:2,Matrix:228x75,FOV:17
T2-W TSE FS	Axial	TR/TE,1650/70,NSA:2,SL/G:4.5/1,Matrix:288x250,FOV:35
T1-W FS(SPIR)+/-CE	Axial or sagittal	TR/TE,400/20,NSA:2,SL/G:4.5/1,Matrix:360x252,FOV:38

Abbreviations: T2-W: T2-weighted, FS:Fat-Suppressed, DCE:Dynamic Contrast-Enhanced, CE:Contrast-Enhanced, TR(msec):repetition time, TE(msec):echo time, FA(°):flip angle, NSA: Number of Signal Averages, SL(mm):slice thickness, G(mm):interslice gap, FOV(cm):Field of view(right-left)

IV. Statistics:

50 Patients affected with different levels of involvement by disease were identified and percentages obtained.

Table 1: Age Ratio

Age	No. of patients	Percentage
40-50	12	24
50-60	22	44
60-70	16	32

Table 2: Staging

Stage	No of patients	Percentage
I	03	6
II	29	58
III	15	30
IV	03	6

Table 3: Histology subtype

Type	No. of patients	Percentage
Squamous cell carcinoma	44	88
Adeno carcinoma	6	12

Table 4: Recurrence rate

Stage	No of patients	Percentage
I	0	0
II	14	28
III	6	12
IV	1	2

V. Results:

Out of 50 patients, the age at presentation ranged from 40 year to 70 years. The mean age was 54 years and the most commonly affected age group ranged 50-60 years. In this study 6% cases were diagnosed with stage I, 58% with stage II, 30 % with stage III, and 6 % with stage IV. According to histological type, 88% presented with squamous cell carcinoma and 12% with adenocarcinoma. According to recurrence rate, stage I shows 0%, stage II 28% , stage III 12% and stage IV 2% of recurrence rate.

VI. Figures:

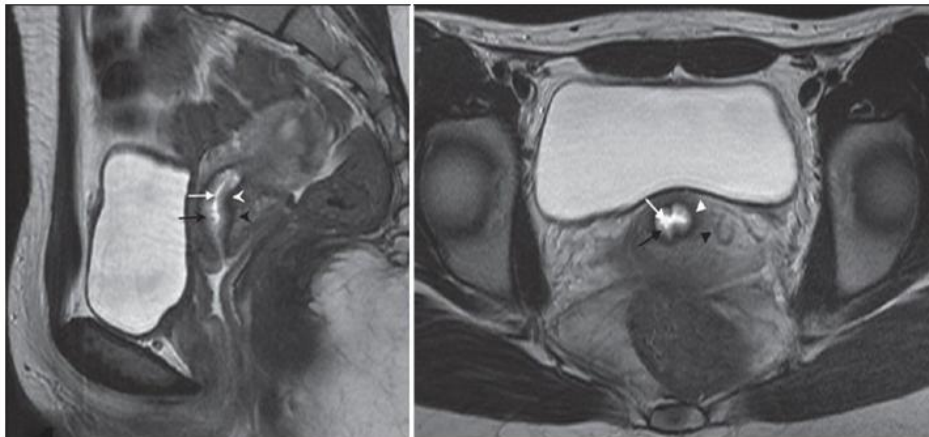


Figure 1: Normal MR anatomy of cervix

MRI T2W image high signal intensity endocervical canal (white arrow), intermediate signal intensity plicae palmatae(black arrow), low signal intensity fibrous stroma(white arrow head), intermediate signal intensity outer smooth muscle(black arrow head)

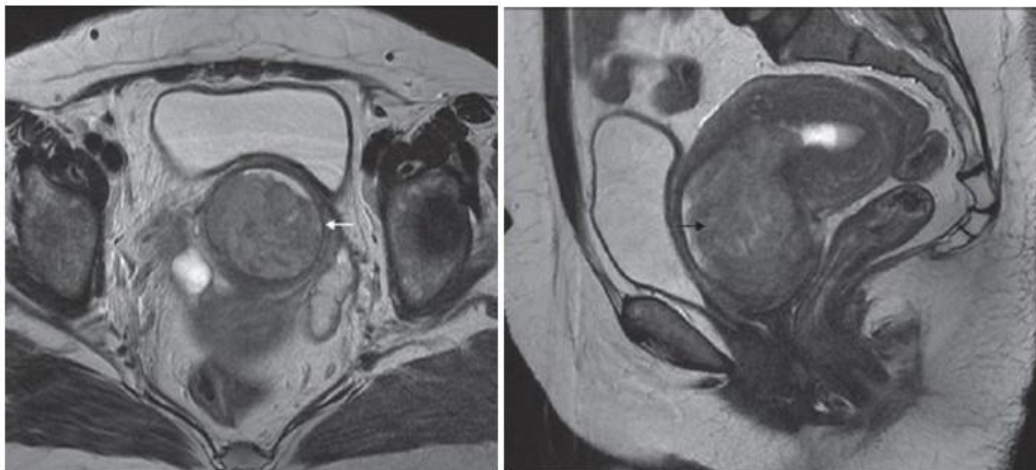


Figure 2: Stage 1B

T2W Axial and Coronal image show polypoidal cervical mass extending into endometrial cavity(black arrow) with preserved peripheral hyperintense stromal ring(white arrow)

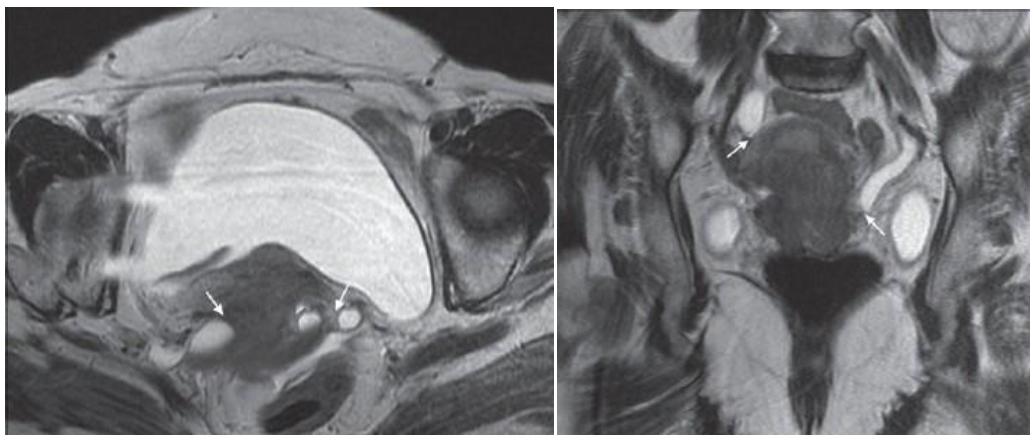


Figure 3: Stage III B - Axial and coronal T2W images show intermediate signal intensity cervical tumour with parametrial invasion and involvement of distal ureter bilaterally(white arrow), leading to proximal hydronephrosis

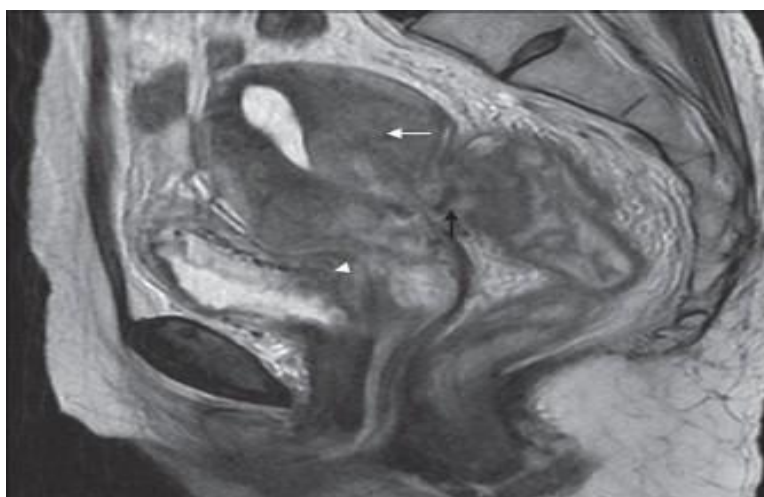


Figure 4: Stage IV A - Sagittal T2W image shows a large mass arising from the cervix and involving uterine myometrium (white arrow) with invasion in rectum demonstrated as loss of T2 low signal intensity rectal wall(black arrow), infiltration in posterior bladder wall(white arrow head)

VII. Discussion:

Anatomy

Cervix on T2WI shows the following distinct zones (Figure 1):

- Central hyperintense mucous
- High-signal intensity endocervical mucosa and glands (contains numerous folds and clefts as the plicae palmate). Combined thickness of zones 1 and 2 is 2 to 3 mm
- Hypointense fibrous stroma is 3 to 8-mm thick
- *Outer intermediate signal intensity loose stroma*

Diagnosis

MRI is the imaging modality of choice to depict the primary tumour and assess local extent. Distant metastatic disease is best assessed with CT or PET, where available. In order to be radiographically visible, tumours must be at least stage Ib or above .

On MRI, tumor confined to cervix is **stage I** :Cervical carcinoma has intermediate signal intensity at T2-weighted imaging and is seen disrupting the normal low signal-intensity fibrous stroma . The tumor can demonstrate a wide variety of morphologic features and may be exophytic , infiltrating , or endocervical with a

barrel shape . In young women, cervical carcinoma usually originates from the squamocolumnar junction and tends to be more exophytic, whereas in older women it originates more often in the endocervical canal. The bulk of the lesion is centered at the level of the cervix, with either protrusion into the vagina or invasion of the lower myometrium. In general, cervical carcinoma is better defined at T2-weighted imaging, but small tumors may be more readily identified by their early enhancement after dynamic injection of gadopentetate dimeglumine. A visible tumor indicates stage IB or higher. The size of the tumor has a great impact on the choice of therapy. The shape and direction of growth should be noted because they are important for brachytherapy planning .

Upper two-third vaginal or lower uterine segment invasion is **stage IIA**, Vagina disruption of the hypointense vaginal wall with hyperintense thickening at T2-weighted imaging and contrast enhancement at T1-weighted imaging are signs of vaginal invasion.

Parametrial invasion is **stage IIB**, Complete disruption of the parametrial fibrous ring with nodular or irregular tumor signal intensity extending into the parametrium are reliable signs of invasion.

Lower one-third of vaginal invasion is **stage IIIA**.

Pelvic Wall invasion with hydronephrosis is **stage IIIB**. Tumor extending to involve the internal obturator, piriform, or levator ani muscles, with or without a dilated ureter, indicates pelvic wall invasion. Ureteral obstruction at the level of the tumor is considered to be an indication of wall invasion.

Bladder and Rectum invasion is **stage IVA**. Bladder or rectal invasion is present when disruption of their normal hypointense walls is seen at T2-weighted imaging, with or without a mass protruding into the lumen . Dynamic gadolinium-enhanced T1weighted sequences are helpful for confirming invasion and identifying fistulous tracts.

Distant metastasis indicate **stage IVB**.

FIGO Staging

0 Carcinoma in situ

I : Confined to cervix

IA: Microscopic

IA-1 Stromal invasion <3 mm

IA-2 >3 mm, <5-mm invasion, <7mm width

IB : Clinically visible (>5 mm)

IB-1 <4 cm

IB-2 >4 cm

II Extends beyond uterus but not to pelvic wall or lower one-third of vagina

II A : Vaginal extension, no parametrial invasion

II B: Parametrial invasion

III Extension to lower one-third of vagina or pelvic wall invasion with hydronephrosis

III A: Extension to lower one-third of vagina

III B: Pelvic wall invasion with hydronephrosis

IV Located outside true pelvis

IV A : Bladder or rectal mucosa

IV B : Distant metastasis

Lymph node disease detection is based on size criterion, the most widely accepted being a transverse diameter exceeding 10 mm. Involvement of lymphnode in cervical cancer: parametrial(77%), paracervical(31%), inguinal(8%), external iliac(27%), hypogastric(31%), common iliac(31%), sacral(23%), Aortic (27%).

VIII. Conclusion:

Cervical carcinoma is the third most common gynecologic malignancy, with an average patient age at onset of 54 years. The revised 2009 FIGO staging encourages imaging as an adjunct to clinical staging. This system is based on findings at clinical examination (performed with the patient under anesthesia), chest radiography, intravenous urography, barium enema studies, cystoscopy, and proctoscopy. There are significant inaccuracies in the FIGO staging system, with a 24%–39% error rate in gynecologic examinations . Without crosssectional imaging, there is poor evaluation of deep pelvic invasion. Moreover, lesion volume and nodal metastasis, two significant prognostic factors, are not assessed . Therefore, magnetic resonance (MR) imaging is now widely accepted as optimal for evaluation of the main prognostic factors and selection of therapeutic strategy.

References

- [1]. American Cancer Society. Cancer facts and figures 2008. Atlanta, Ga: American Cancer Society, 2008.
- [2]. Miller AB, Lindsay J, Hill GB. Mortality from cancer of the uterus in Canada and its relationship to screening for cancer of the cervix. *Int J Cancer* 1976;17(5):602–612.
- [3]. DevesaSS, YoungJLJr, BrintonLA, Fraumeni JF Jr. Recent trends in cervix uteri cancer. *Cancer* 1989;64(10):2184–2190.
- [4]. Benedet JL, Anderson GH, Matisic JP. A comprehensive program for cervical cancer detection and management. *AmJ Obstet Gynecol* 1992;166(4):1254–1259.

- [5]. Koyama T, Tamai K, Togashi K. Staging of carcinoma of the uterine cervix and endometrium. *Eur Radiol* 2007;17(8):2009–2019.
- [6]. Van Nagell JR Jr, Roddick JW Jr, Lowin DM. The staging of cervical cancer: inevitable discrepancies between clinical staging and pathologic findings. *Am J Obstet Gynecol* 1971;110(7):973–978.
- [7]. Hricak H, Lacey CG, Sandles LG, Chang YC, Winkler ML, Stern JL. Invasive cervical carcinoma: comparison of MR imaging and surgical findings. *Radiology* 1988;166(3): 623–631.
- [8]. Togashi K, Nishimura K, Itoh K, et al. Uterine cervical cancer: assessment with high-field MR imaging. *Radiology* 1986;160(2): 431–435.

Dr Mahak Sood." Magnetic Resonance Imaging in Carcinoma of Cervix". "IOSR Journal of Dental and Medical Sciences (IOSR-JDMS), vol. 17, no. 9, 2018, pp 23-29.