

Proptosis-An Otorhinological Perspective

Dr Anjani Kumari M.S;Dr Jaina Divya M.S;Dr Ambati Surekha ;

Dr Vyshanavi B

Corresponding Author :Jaina Divya

Date of Submission: 15-09-2018

Date of acceptance: 29-09-2018

I. Introduction:

The eye is an area of considerable interest to the layman as well as the ophthalmologist. But it's apparently deceptive sense of irrelevance to the otolaryngologist is what makes it more interesting. It is an area where many of the structures related to otolaryngologist seem to converge. Hence an otolaryngologist is usually to be consulted even for an obviously ocular lesion to rule out or establish that cryptic lesion in his domain. Every otolaryngological examination which might even remotely suggest an ocular involvement should be followed by an adequate clinical examination of the eye. Most often sophisticated techniques of investigation are required to establish the extent or degree of lesion which might then surprisingly reveal an ocular involvement. The various therapeutic modalities that such cases demand on account of their complex anatomical and functional properties is a constant source of stimulation to the surgeon to further sharpen his surgical acumen. This is more so when an interdisciplinary approach with the ophthalmic surgeon and less often with the neurosurgeon is called upon. Hence in the light of above view it seems amply justifiable to conduct a study of such cases with regard to their presentation, diagnosis and management.

This study is a fairly sincere attempt in this direction and is believed to serve as an appraisal of the basic facts regarding such cases.

II. Material And Methods:

Aims And Objectives

1. To evaluate the etiopathogenesis of proptosis.
2. To emphasize on thorough otorhinolaryngological examination in all cases of proptosis.
3. To evaluate the use of radio-imaging techniques mainly CT scans
4. To evaluate the various modalities of treatment in the management of proptosis

Materials And Methods

This study comprises of cases that presented to the outpatient Department of Government ENT Hospital, Osmania Medical College, Koti, Hyderabad.

Most of the cases presented themselves directly to the out patient department. Few were referred from other hospitals. Some cases were referred by the otolaryngologists who felt the need for specialized care in a tertiary care institution.

A sizable number of cases were referred from the Eye Hospital which is a tertiary care institution for eye diseases. They were referred to confirm and assist in the management of eye problems that arose out of ENT disorders. Most patients in whom intervention was contemplated were admitted for evaluation.

A thorough otolaryngological examination was performed. It included examination of the ear, nose, throat, neck and cranial nerves and signs of raised intracranial tension.

A more detailed examination of eye was done by taking the services of the ophthalmologist. When need arose and where more was felt necessary, an ophthalmologist opinion was sought.

Routine investigations including complete blood examination, urine analysis, blood grouping and typing, blood urea, serum creatinine, random blood sugar, HIV, HbsAg were done.

They presented with mass in the nose. They were biopsied under local anesthesia directly and sent for HPE.

Next CT scan or MRI scan of the region involved was performed to know the extent of the lesion, to plan for the appropriate treatment.

Surgery was the main stay of treatment and excision with adequate clearance of the disease was often given.

Postoperative radiotherapy and chemotherapy were given in appropriate cases.

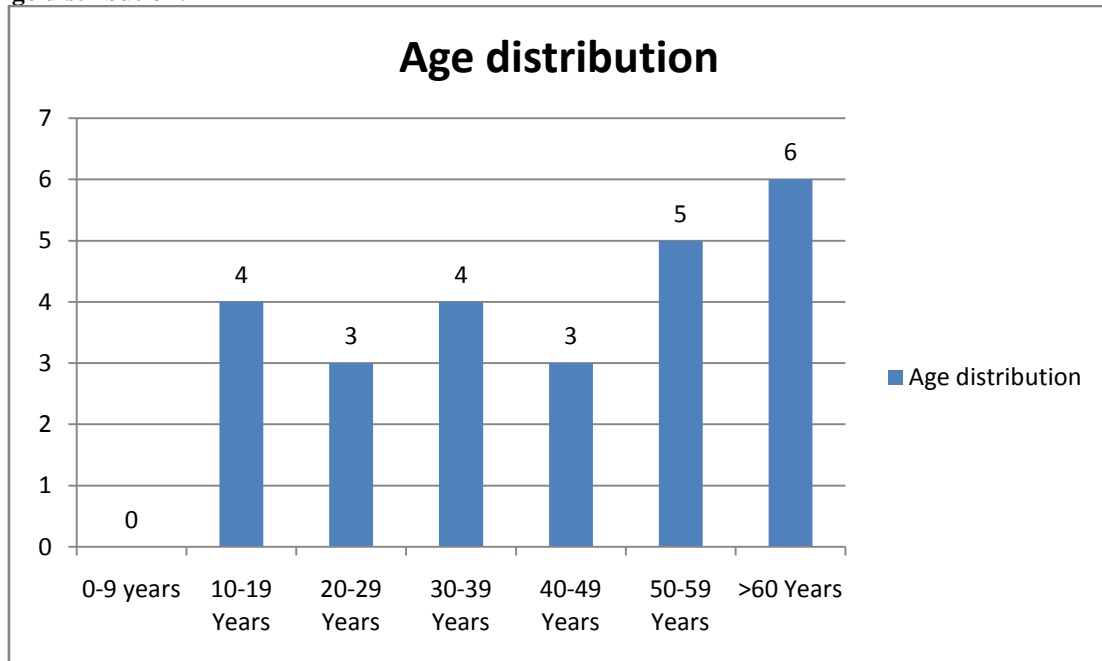
Few inoperable cases were referred to MNJ cancer hospital, Hyderabad for radiotherapy and chemotherapy.

III. Results

This study was done on patients presenting with proptosis of eye. This was done from the December 2014 to August 2016. The study was conducted in a tertiary referral hospital Government ENT Hospital, Koti Institute's Ethical Committee approval was taken before starting the study. Patients' consent was taken to publish the details in our study.

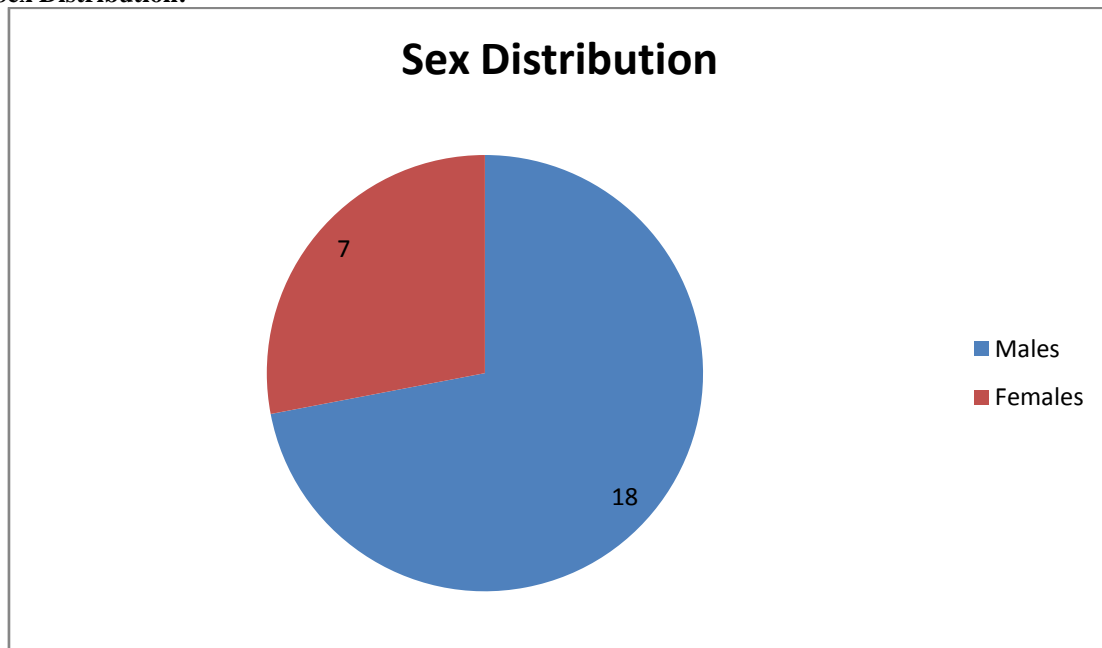
A total of 25 patients were included who presented with the chief complaints of proptosis. After thorough ENT examination and relevant tests the diagnosis was established. The results are presented as follows.

1) Age distribution:



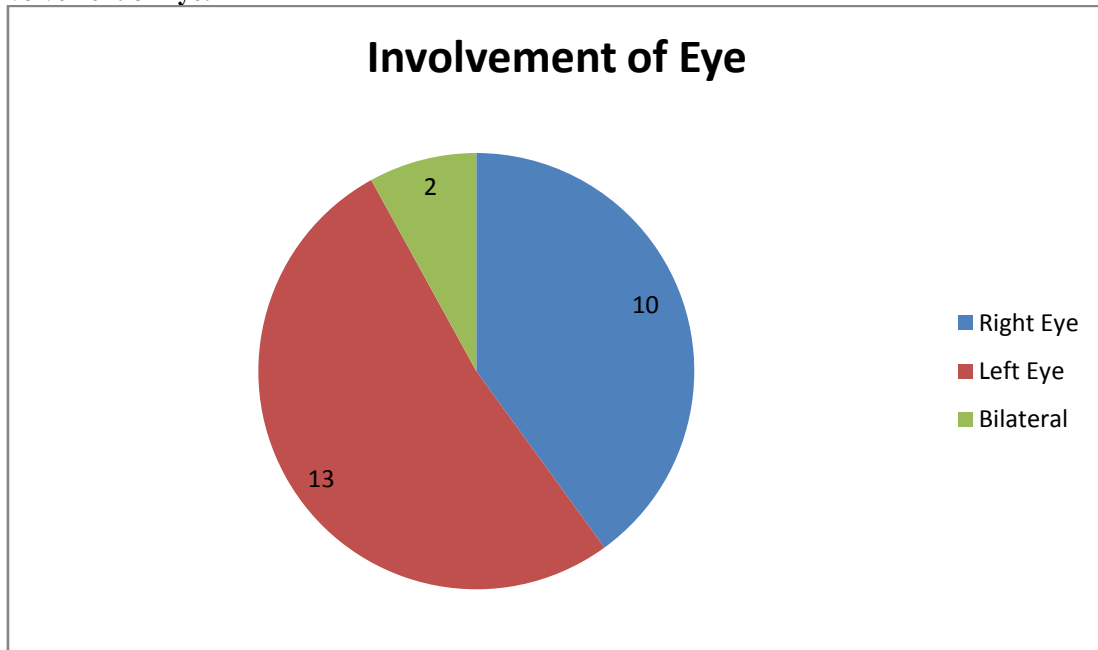
Major age group presenting with proptosis was above 60 years accounting for 24%. No cases were reported between the age group of 0 to 9 years.

2) Sex Distribution:



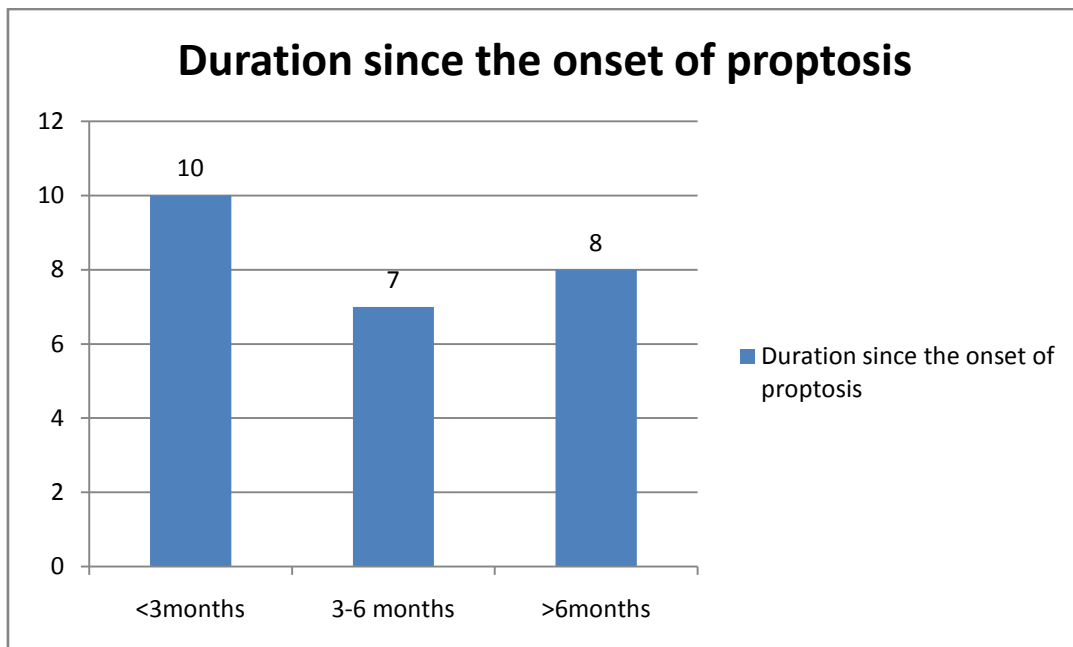
18 cases were male constituting 72% and females were 7 accounting to 28%.

3) Involvement of Eye:



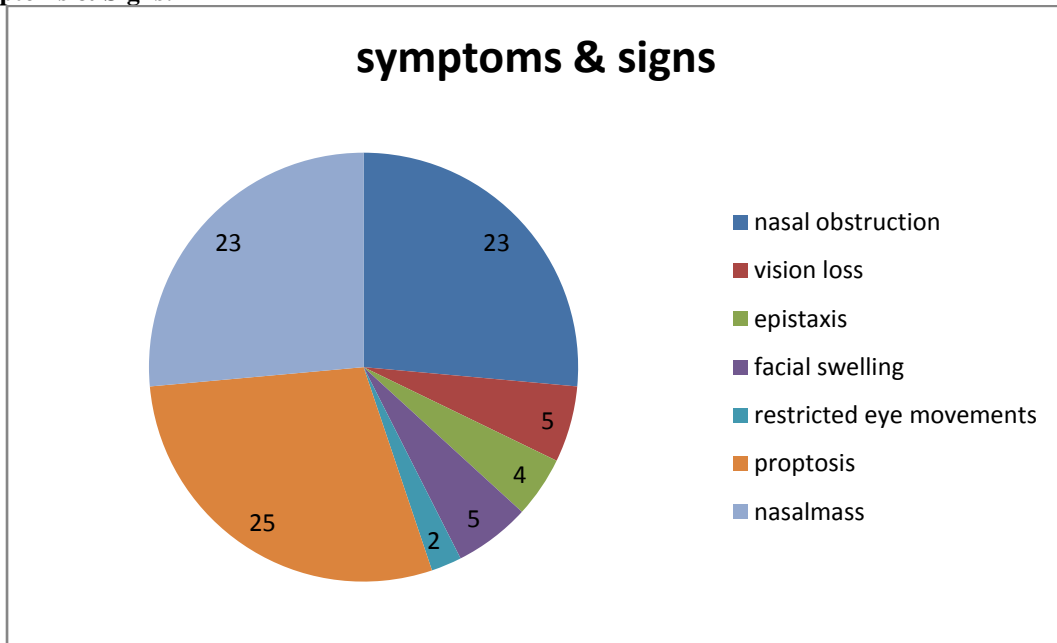
13 cases presented with right eye proptosis with 52%. 10 presented with left eye proptosis constituting 40%. 2 cases had bilateral proptosis accounting for 8% and both the cases were due to invasive fungal sinusitis.

4) Duration since the onset of Proptosis:



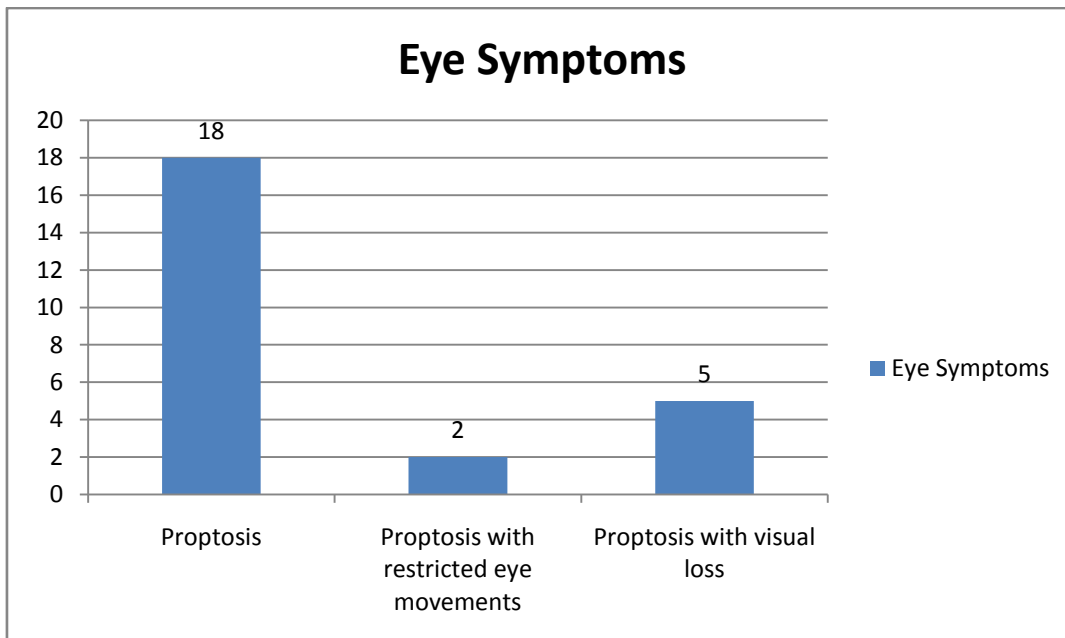
Majority of patients presented to us within 3 months of onset of symptoms accounting for 40%. 7 presented in 3 to 6 months of time and 8 cases presented after 6 months of onset of symptoms.

5) Symptoms & Signs:



Out of 25 patients, all patients presented with proptosis & 92 % patients had nasal obstruction. Nasal mass was the commonest finding found in 23 patients accounting for 92%.

6) Eye Symptoms:



Out of the 25 patients, eighteen patients presented with only proptosis while 2 patients had proptosis with restriction of eye movements. These two patients were diagnosed as carcinoma of maxillary sinus having intraorbital extension.

Five patients presented with proptosis with loss of vision.

Complete visual loss was observed in two patients of which one was diagnosed as recurrent nasopharyngeal Angiofibroma while the other patient had Poorly differentiated squamous cell carcinoma of the maxillary sinus.

Three patients had reduction in visual acuity. One patient was diagnosed to have non Hodgkin's lymphoma of maxillary sinus and another patient had frontal sinus squamous cell carcinoma. One patient had chondrosarcoma of maxillary sinus.

7) Etiology:

Patients were classified into two groups based on their diagnosis. Patients of carcinoma presenting with proptosis and the other due to other causes.

Fifteen patients had underlying carcinoma resulting in proptosis while ten patients had non carcinomatous etiology.

The details of patients with carcinoma presenting with proptosis is as follows:

Etiology	Number of Patients
Poorly differentiated squamous cell carcinoma of maxillary sinus	3
Non Hodgkins lymphoma of maxillary sinus	3
Adenoidcystic carcinoma of maxillary sinus	1
Chondrosarcoma of maxilla	1
Olfactory Neuroblastoma	1
Round Cell Tumour of maxilla	1
Squamous Cell carcinoma of frontal sinus	1
Well differentiated squamous cell carcinoma	2
Myoepithelial carcinoma of maxillary sinus	1
Spindle cell sarcoma of maxillary sinus	1

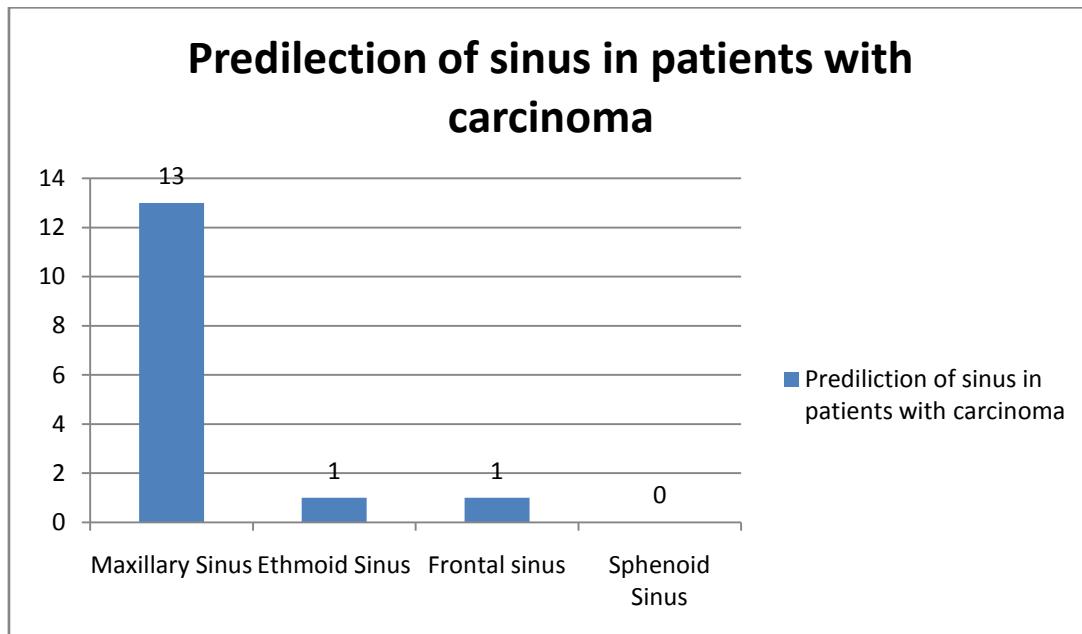
Proptosis due to other causes:

Etiology	Number of patients
Fungal Sinusitis	7
Recurrent nasopharyngeal angiofibroma	1
Fronto ethmoidal mucocoele	1
Fibrous Dysplasia	1

Sinus involvement observed in patients with proptosis:

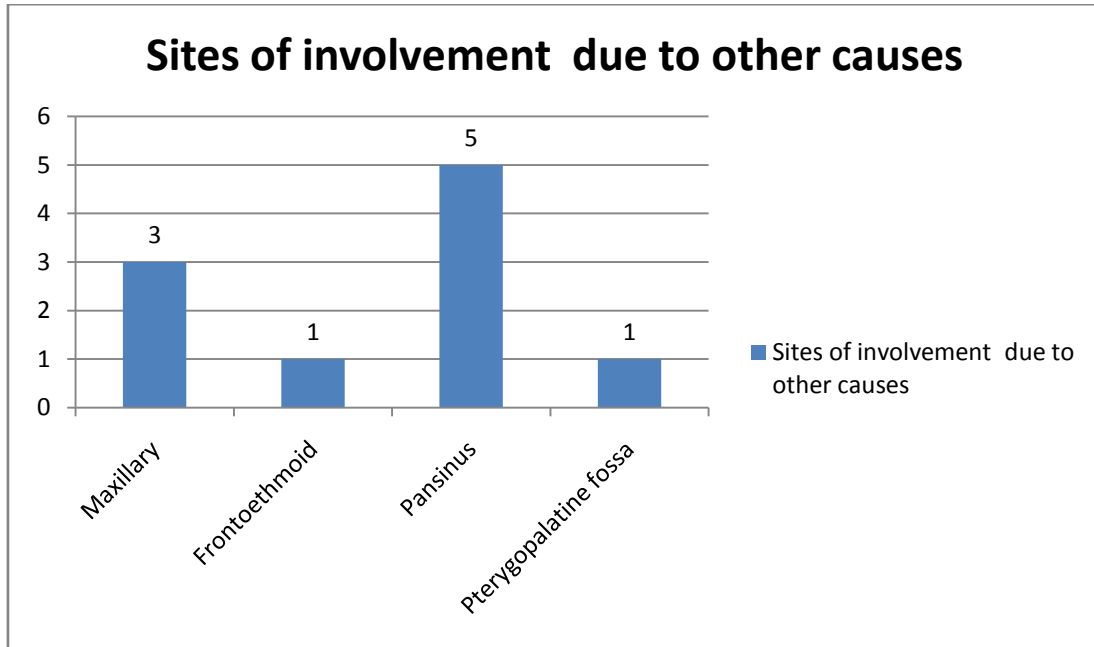
Predilection of sinus in patients with carcinoma:

13 patients had predilection for maxillary sinus accounting for 52%.

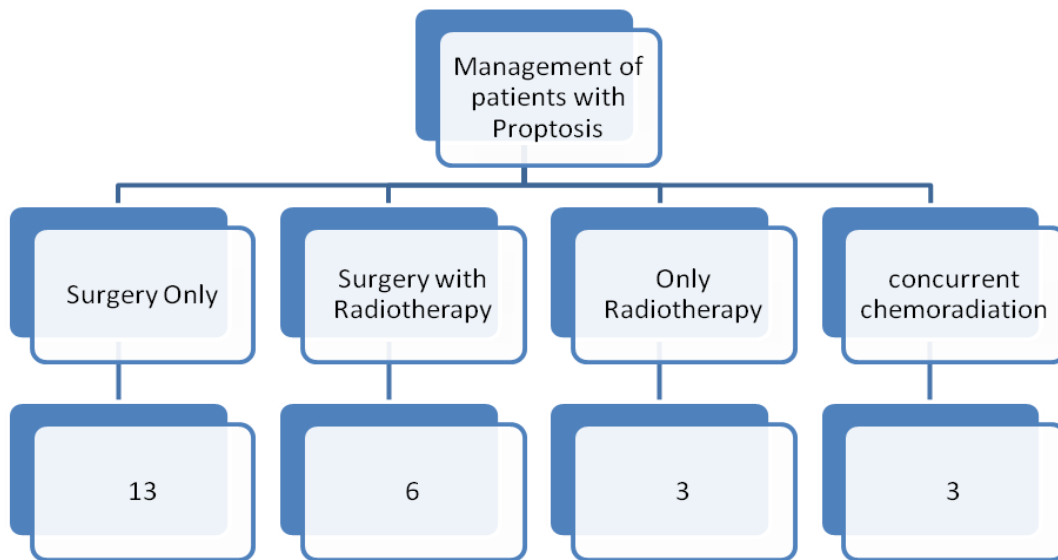


Predilection of sinus in patients due to other cause:

Proptosis due to other causes had pansinus involvement in 5 cases, 3 cases involved maxillary sinus, one case involved frontoethmoid region and the other involved pterygopalatine fossa.



8) Management:



Different modalities of treatment were given according to the type of nature and extent of the disease. Total maxillectomy followed by radiotherapy was given in 6 patients, 13 patients underwent only surgical management, 3 cases were given only radiotherapy and concurrent chemoradiation was given in 3 non Hodgkins lymphoma cases. All the cases of invasive fungal sinusitis were treated with antifungal therapy postoperatively.

9) Complication:

20 out of 25 patients reported no major complications of the therapy. 2 patients who were diagnosed to have poorly differentiated carcinoma of frontal sinus and recurrent nasopharyngeal angiofibroma had recurrence within 6 months of time. 3 patients lost follow up. No deaths were observed in our study.

IV. Discussion

Proptosis is defined as forward displacement of the eye ball. This is regarded as a safety mechanism so as to protect the eyeball from raised intra orbital pressure.

In our study 24% of the patients were above the age group of 60 years followed by 20% of patients in the fifth decade of life. Sixteen percent of patients were between 10-19 years and 30-39 years of age. Twelve percent of the patients were in 40-49 years age and 20- 29 years of age. None of the patients were below 10

years of age . In our study highest incidence of proptosis was observed in patient above 60 years of age. In a study conducted by Venugopal M et al they found the peak age incidence to be between 40 – 50 years of age. ¹

Males were 18 and females were 7. Hence the sex ratio in our study was 2.57. In a study Masud MZ et al they found the ratio to be 1.5. ²

According to Williamsons Noble proptosis is commonly secondary to inflammatory disease in nose and paranasal sinuses. ³

In our study five out of twenty five patients presented with visual loss. In a study by Matsuba Y et al four out of seventy three patients presented with visual loss. ⁴

Among the rhinological causes neoplasm accounted to 60 percent of the patients while the benign and inflammatory pathology accounted for the rest 40 % of the patients.

In our study malignancy accounted for 60 % of the cases. In a study by Venugopal they found 23% of cases of carcinoma as a cause of proptosis. Among the carcinomas squamous cell carcinomas accounted for 20%. This can be compared with the study conducted by Conley and Baker which regarded squamous cell carcinoma as the most common malignancy causing proptosis. ⁵

Rare causes like adenoidcysticcarcinoma, chondrosarcoma, round cell tumour, myoepithelial carcinoma and spindle cell carcinoma also were seen in our study.

Among the other causes excluding malignancy, fungal sinusitis accounted for 28% of the cases. In our study fungal sinusitis was second most common cause of proptosis in comparison with the study by Venugopal where they found frontoethmoidal mucocoele to be the second most common cause and fungal sinusitis to be the third cause of proptosis.

In one patient JNA was the cause for proptosis. In a study by Hodges Et al they report the incidence of proptosis with JNA to be as high as 33.3 % .⁶

Out of the 25 patients who were included in our study 6 patients were offered radiotherapy. One case of spindle cell sarcoma of maxillary sinus, surgery was advised but since the patient refused surgery he was advised radiotherapy as a palliative option. Three patients of Non Hodgkins' lymphoma, One patient with round cell tumour of maxilla and another patient with myoepithelial carcinoma of maxillary sinus were advised radiotherapy.

Thirteen patients underwent surgery. Of these seven patients underwent functional endoscopic sinus surgery. One patient underwent medial maxillectomy and excision of the nasopharyngeal angiofibroma. One patient with chondrosarcoma underwent debulking of the tumour. Transnasal endoscopic excision of the olfactory neuroblastoma was done in one patient. Paring of the fibrous dysplasia was done in one patient.

In six of our patients Surgery with radiotherapy was offered as the treatment. Three of these patients had poorly differentiated squamous cell carcinoma. Among them One patient underwent FESS with enucleation of the eyeball and was diagnosed as a case of poorly differentiated squamous cell carcinoma of the maxillary sinus. The diagnosis was established on the histopathological report following endoscopic sinus surgery. Patient was on regular follow up and doing well postoperatively. Patient was sent for radiotherapy later on .another two patients underwent total maxillectomy followed by radiotherapy.

Three patients underwent total maxillectomy and radiotherapy of which one patient had adenoid cystic carcinoma of maxillary sinus and two had well differentiated squamous cell carcinoma of the maxillary sinus.

A thorough evaluation is needed in all cases of proptosis so as to identify the underlying cause and help in appropriate therapy.

In our study, no major complications of therapy were reported. Two patients of which one was poorly differentiated squamous cell carcinoma of frontal sinus and the other with recurrent nasopharyngeal angiofibroma came with recurrence of the tumour within 6 months of follow up. Out of 20 cases 3 patients were not available for follow up.

V. Conclusion

This study has drawn attention to a few basic points which will be relevant to every otorhinolaryngologist.

1. Primarily, a large degree of cooperation between the Otorhinolaryngologist and the ophthalmologist is needed in dealing with cases of proptosis.
2. In our study, the most common group of diseases that caused the eye manifestations were malignant neoplasms of the nose and the paranasal sinuses. Of them the maxillary carcinoma was more common. Inflammatory disorders were next most common cause of eye manifestations .Fungal sinusitis was the second most common cause in our study.
3. The 18:7 male:female preponderance observed in our study may not be significant because of the small sample size. The most common ENT diseases manifesting with proptosis is seen in elderly people
4. CT scan and DNE examination are useful guide in diagnosis and planning of treatment.

5. Biopsy of the lesion and the histopathological diagnosis will give us the correct plan for the management of the disease for treating the patient surgically or treating the patient with radiotherapy or chemotherapy. Hence biopsy is a very important diagnostic tool before deciding the treatment plan.
6. The treatment modality has to be tailored according to the individual lesion. Surgery, radiation and chemotherapy either singly or in combination was the treatment modality in our study.

Reference

- [1]. Venugopal M, Sagesh M. Proptosis: The ENT Surgeon's Perspective. *Indian J Otolaryngol Head Neck Surg.* 2013;65(Suppl 2):247-50. doi:10.1007/s12070-011-0367-7.
- [2]. Masud MZ, Babar TF, Iqbal A, Khan MT, Zaffar ul Islam, Khan MD. Proptosis: etiology and demographic patterns. *J Coll Physicians Surg Pak.* 2006;16(1):38-41. doi:12.2005/JCPSP.3841.
- [3]. WILLIAMSON-NOBLE FA. Diseases of the orbit and its contents, secondary to pathological conditions of the nose and paranasal sinuses. *Ann R Coll Surg Engl.* 1954;15(1):46-64. Available at: <http://www.ncbi.nlm.nih.gov/pubmed/13189324>. Accessed September 11, 2016.
- [4]. Matsuba Y, Strassen U, Hofauer B, Bas M, Knopf A. Orbital complications: diagnosis of different rhinological causes. *Eur Arch Otorhinolaryngol.* 2015;272(9):2319-26. doi:10.1007/s00405-014-3338-2.
- [5]. Conley J, Baker DC. Management of the eye socket in cancer of the paranasal sinuses. *Arch Otolaryngol.* 1979;105(12):702-5. Available at: <http://www.ncbi.nlm.nih.gov/pubmed/508195>. Accessed September 11, 2016.
- [6]. Hodges JM, McDevitt AS, El-Sayed Ali AI, Sebelik ME. Juvenile nasopharyngeal angiofibroma: current treatment modalities and future considerations. *Indian J Otolaryngol Head Neck Surg.* 2010;62(3):236-47. doi:10.1007/s12070-010-0073-x.

Jaina Divya "Proptosis-An Otorhinological Perspective " *IOSR Journal of Dental and Medical Sciences (IOSR-JDMS)*, vol. 17, no. 9, 2018, pp 25-32.