

Right paraduodenal hernia: A rare cause of small bowel obstruction in younger individual

Chellappa Vijayakumar¹, Nagarajan Raj Kumar^{1*}, Harish Kumar L¹,
Manoj Kumar P¹, Shankar H¹

¹Department of Surgery,

Jawaharlal Institute of Postgraduate Medical Education & Research (JIPMER),
Puducherry -605006, India.

*Corresponding author: Nagarajan Raj Kumar

Abstract: Paraduodenal hernias are unusual conditions, accounting for 0.9% of all intestinal obstructions due to internal abdominal hernias.¹ Small bowel contents herniate into either left fossa (commonly) or right fossa (very rarely) and produce features of intestinal obstruction.² Pre-operative diagnosis is an arduous task, unless a vigilant approach is entertained.

A 19 year old male presented with intestinal obstruction of three days duration. After the initial resuscitation, patient was taken up for laparotomy. A hernial sac with coiled small bowel loops was found in the right paraduodenal region. The hernial orifice was widened and flimsy adhesions were released from the posterior part of the membrane. Ladd's procedure was done. The patient made an uneventful recovery.

Small bowel obstruction due to internal hernia especially right para duodenal hernia is extremely uncommon and can pose a diagnostic challenge. This case report highlights a right paraduodenal hernia as an incidental finding in a young patient who underwent laparotomy for suspected acute intestinal obstruction. The complexity in early diagnosis makes paraduodenal hernia a challenging scenario.

Keywords: Internal hernia, paraduodenal hernia, small bowel obstruction

Date of Submission: 01-08-2018

Date of Acceptance: 16-08-2018

I. Introduction

Internal hernia is the protrusion of abdominal contents through an opening in the peritoneal or mesenteric fold. Paraduodenal hernia constitutes 50% of internal hernias. This congenital anomaly occurs due to malrotation of midgut through a normal or abnormal colonic mesenteric opening.³ In the majority, it remains asymptomatic in early stages. If neglected further, it may complicate as an acute intestinal obstruction or a life threatening perforation peritonitis. Paraduodenal hernia is classified into left (fossa of Landzert) and right (fossa of Kolb) depending on the direction of the hernial sac.² Right sided hernia is very rare compared to left, with a male preponderance.⁴⁻⁵ If the diagnosis is made preoperatively, laparoscopic hernia reduction and excision of the sac offers a viable treatment option. It is unfortunate that a majority of cases are diagnosed intra-operatively.

II. Case report

A 19-year-old male presented to the emergency department with complaints of acute onset diffuse abdominal pain, distention and vomiting for three days. He also reported obstipation and constipation for two days. On examination, he was conscious and dehydrated with stable vitals. His abdomen was tense and distended with sluggish bowel sounds. Digital rectal examination revealed a collapsed and empty rectum. Abdominal X-ray showed multiple fluid levels suggestive of acute intestinal obstruction (Figure 1).

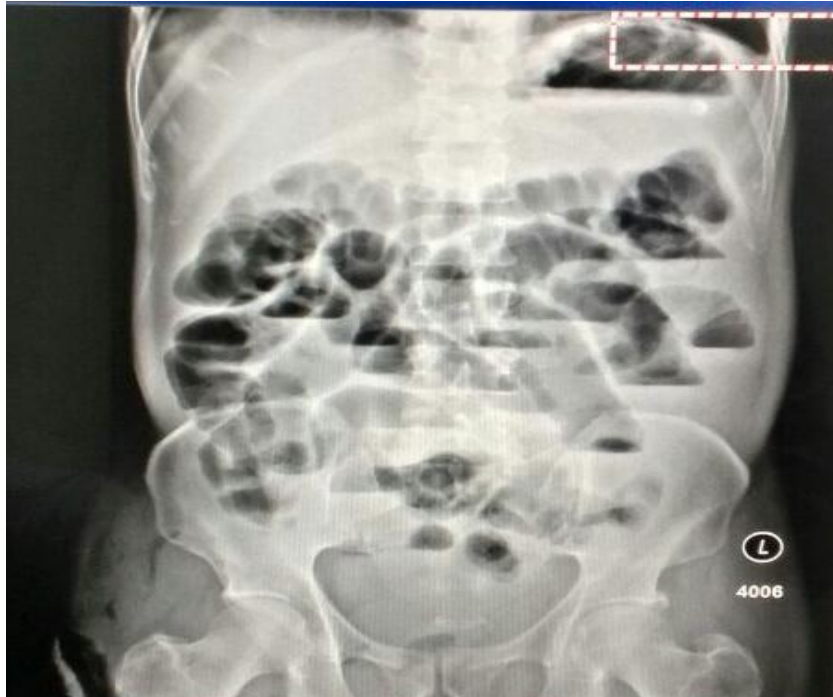

Figure 1: Abdominal X-ray with multiple fluid levels

Ultrasound abdomen showed dilated hypo-peristaltic small bowel loops with maximum calibre of around 3.7 cm. There was no free-fluid in the peritoneal cavity and rest of the findings were unremarkable. A clinical diagnosis of acute intestinal obstruction was made, and the patient was taken up for emergency laparotomy after initial fluid resuscitation.

Intraoperatively, half of the small bowel was held in a separate thin peritoneal sac on the right side of the abdominal cavity. Inside the hernial sac, small bowelloops were found to be dilated. The bowel loops were collapsed distal to the sac and rest of the colon was normal. The mouth of the hernial sac was located on the right of the inferior mesenteric vein. The hernial sac was opened laterally and flimsy adhesions were removed. Half of the small bowel loops were delivered out from the sac (Figure 2).

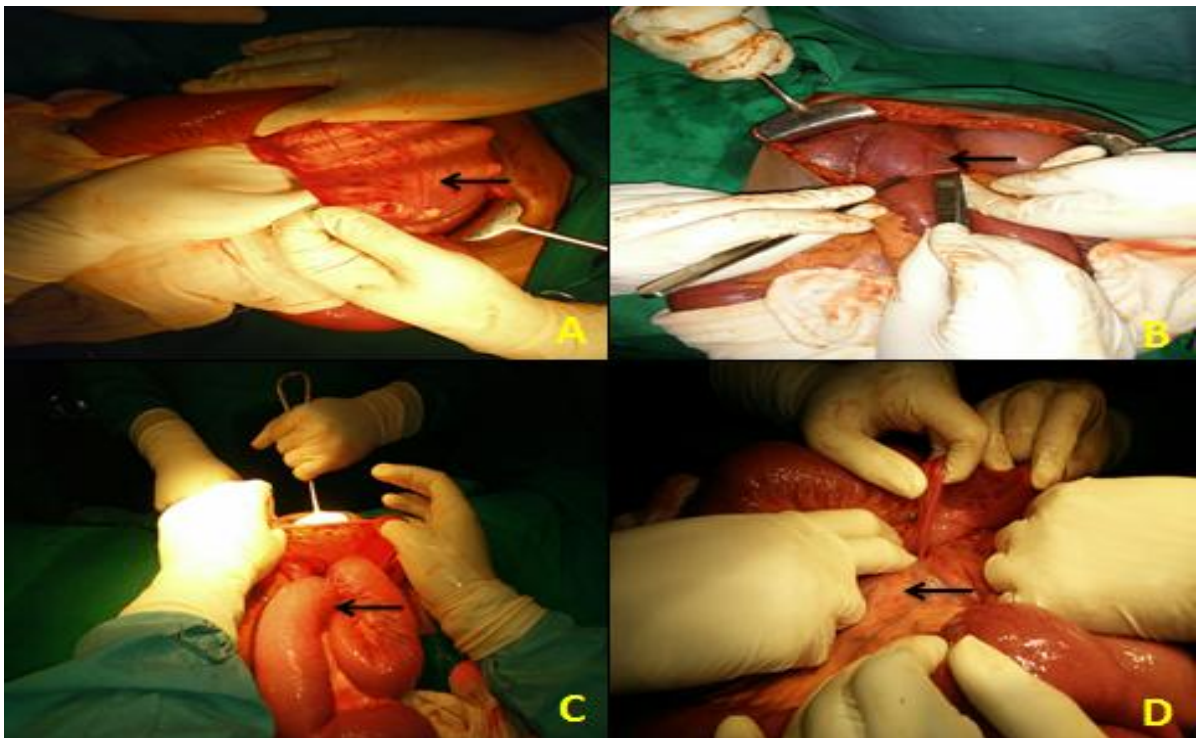


Figure 2: A) Thin peritoneal sac (arrow) on the right side of the abdominal cavity; B) Hernial sac with dilated small bowel loops (arrow); C) Collapsed colon (arrow) distal to the sac; D) Mouth of the hernial sac was located on the right of the inferior mesenteric vein(arrow).

The bowel loops were collapsed distal to the sac and rest of the colon was normal. The mouth of the hernial sac was located on the right of the inferior mesenteric vein. The hernial sac was opened laterally and flimsy adhesions were removed. Half of the small bowel loops were delivered out from the sac. A thick fibrous membrane was observed in the posterior aspect of the sac and it seemed to offer resistance while releasing the remaining bowel loops. The hernial sac was cut open and excised adequately from the duodenal jejunal flexure to the ileocaecal junction, preserving the superior mesenteric vessels. The proximal jejunal loops appeared to emerge from beneath a peritoneal fold, and possibly contained the inferior mesenteric vein.

The inferior mesenteric vein, which was situated on the left of the hernial sac, was meticulously preserved. The remaining hernial sac was completely excised and plicated. The neck of the hernial sac was sutured to the posterior abdominal wall. The ascending colon and descending colon were mobilised completely. Finally, Ladd's procedure was done and the abdomen was closed with a right pelvic drain. The postoperative period was uneventful. According to our institute protocol, per-operative antibiotics were continued till the fifth day following surgery. The patient was started on oral feeds on the second postoperative day and was discharged on the eighth postoperative day. On follow-up, an oral contrast study was done, which deciphered a normal bowel pattern.

III. Discussion

Neubauer, in 1786, is credited with the first description of paraduodenal hernia in medical history.⁶ Two standard theories for development of paraduodenal hernia are Moynihan's Theory and *Andrews' Theory*. According to the former theory, paraduodenal hernias are physiological adhesions which occur in embryological life, at the time of return of the bowel to the abdomen and fusion of the common dorsal mesentery with the posterior abdominal wall.⁷ This leads to formation of folds and fossae which predispose to paraduodenal hernia. According to the second one, paraduodenal hernias are developmental fusion defects of peritoneum, with incarcerated small bowel beneath the developing colon.⁸

In cases of right paraduodenal hernia, the counter-clockwise rotation of the midgut during embryological development is arrested on the right side. The small bowel becomes entrapped in a hernial sac formed by the peritoneum, behind the colonic mesentery, and the caecum and ascending colon rotate anteriorly.⁹

Liew and associates described around 25 different anatomic sites of internal hernias.² Paraduodenal hernia constitutes a rare subtype of internal hernia. Though majority of the cases are congenital, patients usually present around 4th and 5th decades of life.¹ In our case, the presentation was in the late second decade. Preoperative diagnosis is difficult and unusual.² Plain X-ray and ultrasound of the abdomen are crucial investigations in case of emergency situations like intestinal obstruction. Barium contrast studies, Computed Tomography and Celiac arteriography are the modalities available in case of an elective workup. Paraduodenal hernia is a clinical diagnosis and surgery should not be delayed pending radiological imaging.

Once the diagnosis is made, treatment should be energetic and appropriate. Urgent surgical intervention is ideal since obstruction of the entrapped bowel can lead to ischemia and perforation, which signals high mortality.¹¹ The hernial sac, should be adequately incised to remove all the contents, after which the sac should be completely excised and plicated. In this case, the mouth of the hernial sac was sutured to the posterior abdominal wall. In view of recurrence, Ladd's procedure was done. Removal of the sac remains controversial as it is part of the mesocolon and may prove as a harbinger for colonic vascular impairment.¹ Patient should be followed up with barium contrast study on a regular basis.

IV. Conclusion

Paraduodenal hernia remains a diagnostic challenge and a prompt diagnosis relies on a high index of suspicion. It can present with features of acute intestinal obstruction in a younger patient. An adequate anatomical knowledge of the peritoneal and mesenteric folds is mandatory for the operating surgeon. Radiological investigations are only corroborative evidence and should not delay early surgical intervention.

References

- [1]. Khan MA, Lo AY, Vande Maele DM. Paraduodenal hernia. *Am Surg* 1998; 64:1218-22.
- [2]. Liew KL, Choong CS, Shiau GF, et al. Descending mesocolon defect herniation: case report. *Changeng Yi Xue Za Zhi* 1999; 22:133-7.
- [3]. Moran JM, Salas J, Sanjuán S et al. Paramesocolic hernias: consequences of delayed diagnosis. Report of three new cases. *J Pediatr Surg* 2004; 39: 112– 6
- [4]. Desjardins AU. Left paraduodenal hernia. *Ann Surg*.1918; 67: 195– 201
- [5]. Khan MA Lo AY Vande Maele DM. Paraduodenal hernia. *Am Surg*1998; 64: 1218– 22.

- [6]. Brigham RA. Paraduodenal hernia. In: Nyhus LM Condon RE (ed.) *Hernia*. 4th ed. Philadelphia: Lippincott Williams and Wilkins, 1995.
- [7]. Moynihan GBA. *On retroperitoneal hernia* New York: William Wood and Co, 1906
- [8]. Andrews E. Duodenal Hernia: a misnomer. *Surg Gynecol Obstet*.1923; 37: 740.
- [9]. Rohit Mehra Aswini Kumar Pujahari. Right paraduodenal hernia: report of two cases and review of literature. *Gastroenterology Report* 2106; 4:168–171.
- [10]. Vytauras Kuzinkovas, Koroush Haghighi, Rishi Singhal, Nigel J. Andrews. Paraduodenal hernia: a rare cause of abdominal pain. *Can J Surg*. 2008 Dec; 51(6): E127–E128.
- [11]. Manji R, Warnock GL. Left paraduodenal hernia: an unusual cause of small-bowel obstruction. *Can J Surg* 2001;44:455-7

Chellappa Vijayakumar "Right paraduodenal hernia: A rare cause of small bowel obstruction in younger individual." *IOSR Journal of Dental and Medical Sciences (IOSR-JDMS)*, vol. 17, no. 8, 2018, pp 76-79.