

## Stiffness after Total Elbow Arthroplasty, What Is the Ideal Method of Release, A Comparative Study between Manipulation under Anesthesia and Arthrolysis.

Dr. Suhasish Roy

Orthopaedic And Spine Surgeon Bellevue Clinic, Kolkata.

Corresponding author: Dr. Suhasish Roy

---

**Abstract:** Total Elbow Replacement (TER) is considered as the ultimate salvage operation to recreate a functional Range of Motion (ROM) in a stiff elbow after malunited distal Humerus Fracture. Post TER stiffness is not uncommon. It is usually extrinsic stiffness which may occur after variable time difference. Manipulation under Anesthesia (MUA) or Arthrolysis have been documented to be the effective procedures to regain functional ROM after post TER stiffness. In this case series 16 patients operated with linked semi-constrained non-custom Total Elbow implant developed post surgical stiffness at a mean of 45.25 months post TER and were treated to attain functional ROM by MUA or open arthrolysis. This level IV therapeutic, non control, cohort prospective study was done to compare whether Manipulation Under Anesthesia or Arthrolysis is a better method for regaining functional ROM in post TER stiffness.

**Key Words:** Total Elbow Replacement; extrinsic stiffness; Manipulation Under Anesthesia; Arthrolysis; functional Range Of Motion.

---

Date of Submission: 02-08-2018

Date of acceptance: 17-08-2018

---

### I. Introduction:

Total Elbow Replacement is considered as ultimate treatment in salvaging a stiff elbow which has failed conservative and operative therapeutic procedures to overcome the stiffness and return the elbow to an effective functional arc. There has been modifications in implant design and operative techniques, total elbow replacement (TER) is a reliable long-term option for many pathological conditions leading to elbow stiffness.[1] Of them malunited distal Humerus fracture is a dreaded cause of elbow stiffness which can be effectively managed with TER after other therapeutic techniques of restoring the functional ROM is extinguished.[2]. Many orthopaedic literature has demonstrated the usefulness of joint replacement for certain types of distal humeral fractures. There is considerable improvement in function, low complications, and decreased morbidity.[3],[4],[5]. But this salvage procedure too is replete with complications, one amongst them though rare is postsurgical stiffness. According to Antuana and Morrey two patients returned for MUA 8 weeks after TER and two had repeat arthrolysis. Three elbows were manipulated under anaesthesia for post-operative stiffness.[6]. Figgie et al.[7] presented a study comprising 19 elbows with various diagnoses treated with several implants. Their 26% complication rate and 26% manipulation rate lend voice to our experience that post TER contracture/stiffness is not uncommon though less reported. Most common cause of post TER elbow stiffness is extrinsic stiffness [8],[9],[10],[11]. Morrey explained the pathoanatomy of elbow stiffness as either extrinsic or intrinsic.[12],[13]. Extrinsic stiffness include the capsule, collateral ligaments, and the extra-articular soft tissues surrounding the joint (muscles, subcutaneous tissue, and skin). Extra-articular malunions and heterotopic ossification (HO) fall into this category. The intrinsic factors are articular problems like intra-articular adhesions, articular incongruity and malunions, posttraumatic arthritis, and osteophytes causing mechanical blocks or soft tissue in the coronoid or olecranon fossae. A mixed contracture is when patients have both intrinsic and extrinsic sources limiting their motion.

### II. Aims And Objectives:

Study and compare the methods between Manipulation under Anesthesia and Arthrolysis to regain functional Range of Motion after stiffness following Total Elbow Replacement. It is an experimental Level 4 retrospective study (non historical, non control, cohort case series).

### **III. Materials And Methods:**

16 patients in whom stiffness occurred after variable period (mean = 45.25 months) following Total Elbow replacement (4 by author) done between April 2004 – November 2011 due to stiff elbow caused due to malunited distal humerus (A2=1, A3=3, B2=3, B3=2, C1=3, C2=2, C3=2; ATO Classification) fracture were the subjects of this prospective clinical experimental study. In 7 men and 9 women with a mean age of 50.75 years total elbow arthroplasty were performed 11 on right and 5 on left elbow, except three, rest being on the dominant side. Linked semi-constrained non-custom total elbow implant was included in the study. Only those replaced with Bakshi sloppy hinge linked semi-constrained prosthesis were included in the study. The approach to operation and technique were all of similar and standard professed technique. None of the patients had any post operative complications. They developed extrinsic stiffness at a variable period after the replacement procedure. Though extrinsic, the exact cause of secondary stiffness development was beyond the scope of this study. The mean Arc post stiffness was 52.5\*, mean VAS pain score for elbow and hand was 7.375, mean Mayo elbow performance score was 33.75. After taking consent from the ethics committee of the respective centres where the studies were held, explaining in full the methodologies of release, their adverse effects and obtaining written fully explanatory consent from the subjects, 8 patients were subjected to Manipulation Under Anesthesia followed by MORREY'S sequential Splinting regime, while rest 8 patients underwent open arthrolysis through posterior approach at a mean period of 45.25 months from the replacement procedure. The procedural technique was decided by author without any bias, confounding or reason. It was absolutely patient's choice after having explained both processes and their effects and side effects. Inclusion criteria were those with only one type (Bakshi Sloppy-Hinge elbow prosthesis) of implant used were chosen, those with a minimum follow up of 2 years and those arthrolysed only through posterior approach, and those following Morrey's sequential splinting program supervised. Exclusion criteria were any associated complications related to the replacement either early or late, pre or post release, unable to maintain the rehabilitation protocol or perform regular follow up. All of them were secondarily checked by 2 different physicians doubly blinded to author again randomly distributed every 3 months regarding post operative arc of movement, VAS Score, MAYO elbow activity score and other complications like

heterotopic ossification, neurovascular deficit and so on. blinded to author to prevent bias. The patients were allotted to each physician without finding any definite criterion or revealing the surgeon each time in two different groups assigned to be examined again minimizing possibility of confounding bias. A minimum follow up of 24 months was done and final score vis-à-vis the initial score was sent for clinical and statistical review. The follow up for a minimum period of 2 years after the procedure (30 months -128 months, avg. 70.375 months).

Data were analyzed by SPSS (Statistical Package for Social Scientists) version 18.0, IBM, Chicago, USA. Mann-Whitney U test and Wilcoxon signed ranks test were applied to compare mean scores. Spearman's correlation test was also applied. A p value of  $\leq .05$  was considered significant.

### **IV. Results:**

Majority of the study subjects were females (56.2%). For Manipulation under anesthesia group, mean post- VAS score was significantly lower than the mean pre-VAS-score ( $p = .010$ ), mean post-operative MAYO score was significantly higher than the mean pre-operative MAO-score ( $p = .012$ ). For arthrolysis group mean post VAS score was significantly lower than pre VAS scores, ( $p = .010$ ), mean post op MAYO score was significantly higher than preop MAYO score ( $p = .012$ ). There was no significant difference in VAS scores of either procedures before and after the events ( $p = .637$ ). There was no significant difference in MAYO scores of either procedures before or after the events ( $p = .125$ ). Thus it can be effectively inferred that either of the procedures of Manipulation under anesthesia or posterior arthrolysis to the post TEA stiff elbow is equally effective.

### **V. Discussion:**

Rationale of manipulation: Araghi and colleagues (2010) have used a technique of elbow manipulation under anesthesia in select patients. 51 consecutive patients who underwent an examination under anesthesia. 44 patients with a minimum of 12 months follow-up revealed a mean pre-examination arc of 33 degrees, which improved to 73 degrees at the final assessment. Manipulation under anesthesia was meticulous followed by Morrey's splinting program regime. [15] Tan et al. looked at 52 patients who underwent open surgical treatment for post-traumatic elbow contracture at an average of 14 months from the time of injury (Tan et al. 2006). The authors concluded that recurrence of post-traumatic stiffness in the postoperative period is common but is responsive to manipulation under anesthesia and repeat releases. Antuna et al. reported in a study for ulnohumeral arthroplasty for primary degenerative arthritis of the elbow that 2 patients underwent elbow manipulation under anesthesia to improve the range of motion after the ulnohumeral arthroplasty. (Antuna 2002). Techniques of posterior approach arthrolysis elbow-All the

patients underwent surgery in the lateral decubitus position in hanging arm position. through posterior approach. Skin incision was started postero-medially, from distal one-third of the humerus to 5 cm distal to the olecranon tuberosity After the fascia, the triceps muscle was exposed and ulnar nerve decompressed. If any concern about excessive tension on the ulnar nerve, we transposed the nerve anteriorly. The triceps muscle adhesions from medial and lateral and also from the distal end of the arm separated the articular capsule from the olecranon tuberosity to release intra-articular arthrofibrosis. If the appropriate range of motion was not achieved, the articular capsule was opened and the adhesions of the collateral ligaments were released and the range of motion was also revised. The posterior midline approach allows joint access posteriorly, medially and laterally. Through this approach we can release the posterior capsule, decompresses the ulnar nerve and releases the posterior band of MCL which is an important inhibitor of flexion and perform 110\*. Anteriorly we are able to detach the common extensor origin off the capsule and perform capsulectomy. Detaching the triceps is not recommended during the procedure. Adhesiolysis is enough to achieve a good triceps release.

## VI. Conclusion:

Stiffness after Total elbow replacement is not uncommon. Peden and Morrey reported 3 stiffnesses out of 13 TER [15]. Figgie, Antuana and Morrey and various other authors have elaborated on instability/stiffness as a documented complication. Manipulation under Anesthesia /Arthrolysis have been the standard therapeutic regime to overcome post TER stiffness. Arthrolysis may be very rewarding when conservative treatment fails, but manipulation under anesthesia with sequential splinting is equally rewarding especially when it is carried out within a year of the insult. In this case series a mean time difference of 45.25 months after replacement poses a question regarding the operative selection, procedure, rehabilitation procedure, and post operative follow up. However these being not the focus of this study it can be said with emphasis that both MUA and Arthrolysis through posterior approach gives equal and effective results when stiffness occurs after variable duration post elbow replacement without fear of implant breakage, loosening, instability, infection provided they are followed according to rule and keeping in mind the implant, neurovascular structures, collateral ligaments and tendo muscular structures.

## References:

- [1]. Jupiter J.B., Forthman C.L.; Surgical Approach to the Posttraumatic Stiff Elbow; Techniques in Shoulder and Elbow Surgery 5(4):219–230, 2004.
- [2]. Kamineni.S, Morrey B. F; Distal Humeral Fractures Treated with Noncustom Total Elbow Replacement. JBJS: May 2004 - Volume 86 - Issue 5 - p 940–947.
- [3]. Cobb TK, Morrey BF. Total elbow arthroplasty as primary treatment for distal humeral fractures in elderly patients. J Bone Joint Surg Am. 1997;79:826–32.
- [4]. Gambirasio R, Riand N, Stern R, Hoffmeyer P. Total elbow replacement for complex fractures of the distal humerus. An option for the elderly patient. J Bone Joint Surg Br. 2001;83:974–8.
- [5]. Morrey BF. Total elbow arthroplasty for traumatic conditions. In: Morrey BF, editor. The elbow and its disorders. 3rd ed. Philadelphia: WB Saunders; 2000.
- [6]. Total elbow replacement for the management of the ankylosed or fused elbow. J. P. Peden, B. F. Morrey. J Bone Joint Surg [Br] 2008;90-B:1198-204.
- [7]. Figgie MP, Inglis AE, Mow CS, Figgie HE 3rd. Total elbow arthroplasty for complete ankylosis of the elbow. J Bone Joint Surg [Am] 1989;71-A:513-20.
- [8]. Deburge A, Valentin P. Post-traumatic stiffness and ankylosis of the elbow: arthrolysis. Rev Chir Orthop Reparatrice Appar Mot. 1971;57(suppl 1):41–61.
- [9]. Valentin P. Post-traumatic stiffness and ankylosis of the elbow: surgical indications. Rev Chir Orthop Reparatrice Appar Mot. 1971;57(suppl 1):80–81.
- [10]. Glynn JJ, Niebauer JJ. Flexion and extension contracture of the elbow: surgical management. Clin Orthop. 1976: 289–291.
- [11]. Tucker K. Some aspects of post-traumatic elbow stiffness. Injury. 1978;9:216–220.
- [12]. Morrey BF. In: Morrey BF, ed. The Elbow and Its Disorders, 2nd ed. Philadelphia: WB Saunders, 1993:476–491.
- [13]. Morrey BF. Post-traumatic contracture of the elbow: operative treatment, including distraction arthroplasty. J Bone Joint Surg Am. 1990;72:601–618.
- [14]. Shoulder and Elbow Trauma and its Complications: Volume 2: The Elbow. By Michael Greiwe.
- [15]. Peden JP, Morrey B; Total elbow replacement for the management of the ankylosed or fused elbow. J Bone Joint Surg Br. 2008 Sep;90(9):1198-204.

## Tables And Charts And Figures

**Table I: Age and sex distribution of the patients (n = 16)**

Age-group (years)	Sex		Total
	Male	Female	
1	3 (100)	-	3
2	4 (100)	-	4
3	-	4 (100)	4
4	-	5 (100)	5
Total	7(43.8)	9 (56.2)	16

\*Figures in parentheses indicate percentage

Comment: Majority of the study subjects was female (56.2%).

**Table II: Comparison between pre- and post-VAS scores in case of MUA**

VAS score	N	Mean score	Std. Deviation
Pre	8	7.38	.744
Post	8	2.13	.835

Comment: Mean post- VAS score was significantly lower than the mean pre-VAS-score (p = .010)

**Table III: Comparison between pre- and post-MAYO scores for MUA**

MAYO score	N	Mean	Std. Deviation
Pre	8	35.63	9.425
Post	8	84.38	10.836

Comment: Mean post-operative MAYO score was significantly higher than the mean pre-operative MAO-score (p = .012)

**Table IV: Comparison between pre- and post-VAS scores for arthrolysis**

	N	Mean	Std. Deviation
Prevas	8	7.38	.744
Postvas	8	1.88	.641

Comment: Mean post VAS score was significantly lower than pre VAS scores, (p =.010)

**Table V: Comparison between pre- and post-MAYO scores for arthrolysis**

	N	Mean	Std. Deviation
Premayo	8	34.38	11.160
Post mayo	8	94.38	7.763

Comment: Mean post op MAYO score was significantly higher than preop MAYO score(p=.012)

**Table VI: Comparison between difference in VAS scores before and after the two procedures**

Procedure	N	Diff. of Mean	Std. Deviation
MUA	16	-5.38	.719
Arthro	16	1.50	.516

Comment; There was no significant difference in VAS scores of either procedures before and after the events (p = .637).

**Table VII: Comparison between difference in MAYO scores before and after the two procedures**

Procedure	N	Diff of Mean	Std. Deviation
MUA	16	54.38	14.592
Arthro	16	1.50	.516

Comment: There was no significant difference in MAYO scores of either procedures before or after the events.(p = .125).

BAR GRAPH COMPARING PRE INTERVENTION AND POST INTERVENTION MAYO ELBOW SCORE RESULTS

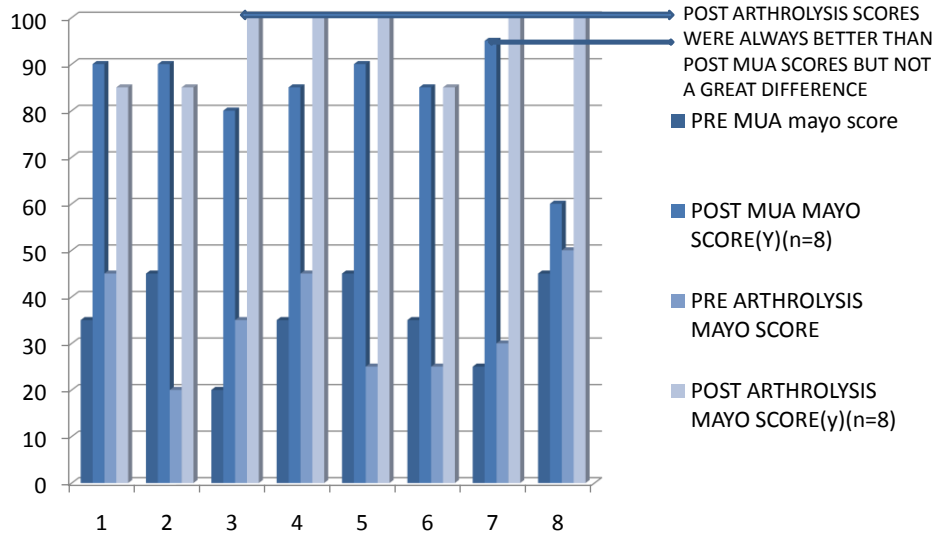


Fig I: Bar Diagram comparing pre and post intervention Mayo Scores.

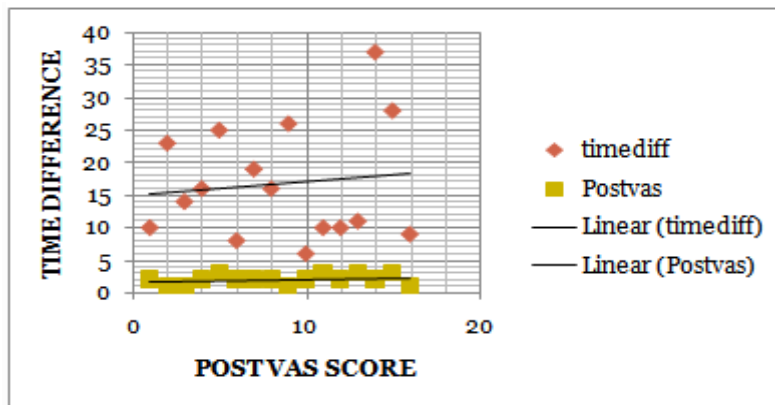


Fig II: SCATTER CORRELATION DIAGRAM BETWEEN POST VAS SCORE AND TIME DIFFERENCE

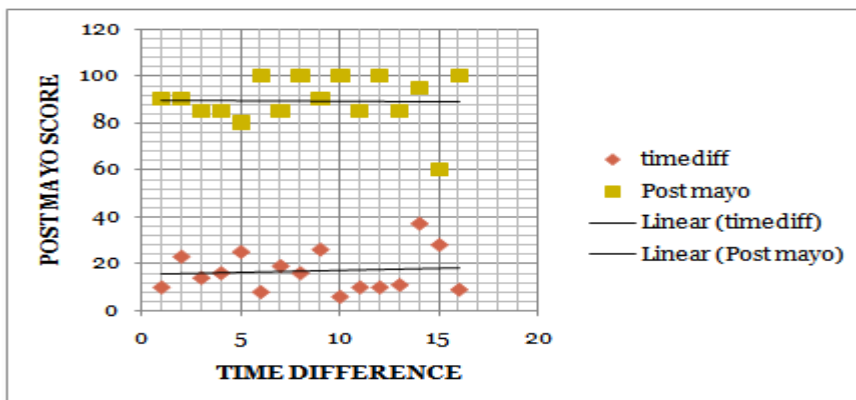
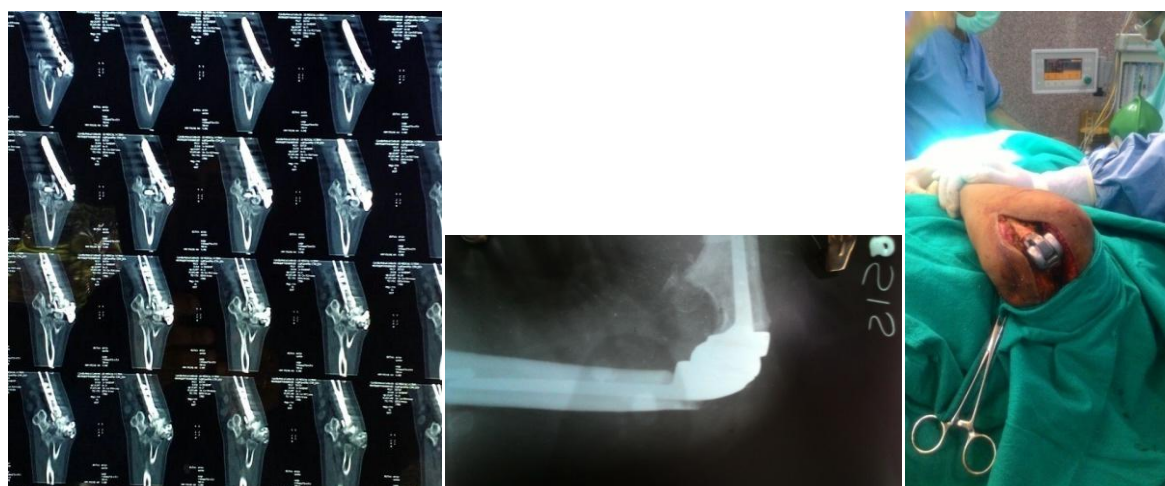


Fig III: SCATTER DIAGRAM WITH CORRELATION LINE BETWEEN POST MAYO ELBOW SCORE AND TIME DIFFERENCE

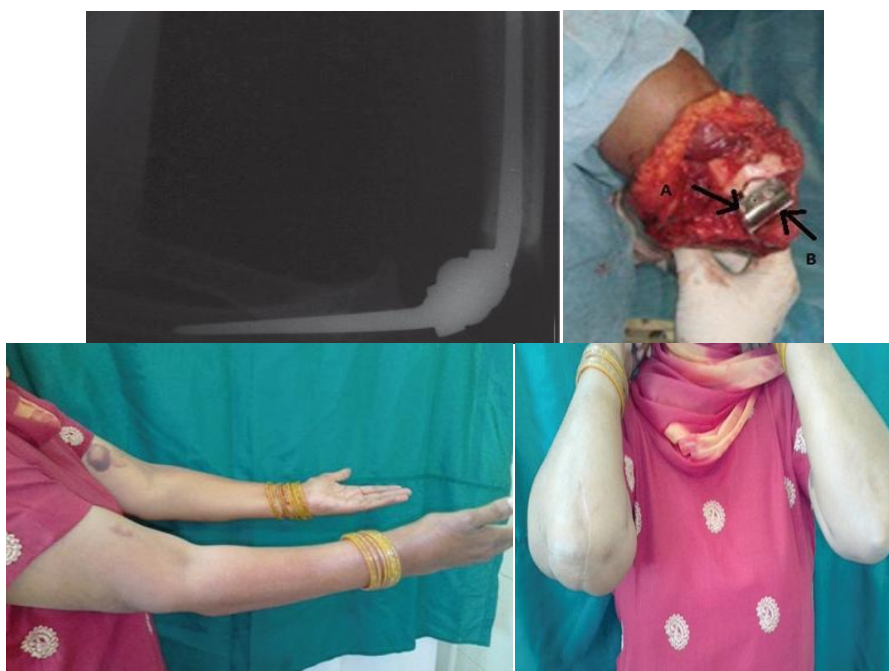**CLINICAL AND RADIOLOGICAL PICTURES**



**Fig IV: TER Having Developed Late Stiffness Released By MUA.**



**Fig V:TER Performed After Malunited 13C 2 Fracture- Stiffness Released By Open Arthrolysis Procedure.**



**Fig VI: Open Arthrolysis in stiffness post TER-post release ROM.**

Dr. Suhasish Roy." Stiffness after Total Elbow Arthroplasty, What Is the Ideal Method of Release, A Comparative Study between Manipulation under Anesthesia and Arthrolysis.."IOSR Journal of Dental and Medical Sciences (IOSR-JDMS), vol. 17, no. 8, 2018, pp 40-45.