

A Comparative Study on Postoperative Chronic Groin Pain in 'Suture' Vs 'Glue' Mesh Fixation in Open Hernia Repair

Dr. Rajkamal Kanojiya¹, Dr Mudunuri Ravi Teja², Dr Sanjay Singhal³,
Dr Siddharth Sinha⁴

Corresponding Author: Dr. Mudunuri Ravi Teja

Date of Submission: 30-07-2018

Date Of Acceptance: 13-08-2018

I. Introduction

Inguinal hernias are very commonly encountered by surgeons throughout the world. Inguinal hernias are usually repaired either by open or laparoscopic approaches. Though laparoscopic hernia repair has gained popularity in recent times, open inguinal hernia repair is still preferred by many surgeons due to lesser rates of recurrence and technical simplicity (1). Amongst the open surgical techniques for open inguinal hernia repair, Lichtenstein hernioplasty which was introduced in 1989 is very popular and widely accepted.

Lichtenstein tension-free repair, though showed good results had a high incidence of chronic groin pain (CGP) postoperatively. The average incidence as reported in many studies has been between 10-40% (2). There are a lot of factors which may be considered for the development of CGP post-herniorrhaphy such as surgeons experience & the surgical technique of fixing the mesh. The various causes proposed for the origin of CGP post-herniorrhaphy are nerve entrapment in sutures or due to mesh fibrosis, injury to nerves of inguinal region, periosteal reaction to sutures taken on pubic tubercle.

Many new techniques were developed to tackle the issue of CGP. Studies show that the use of light weight mesh reduces the incidence of CGP. Use of non-traumatic techniques for mesh fixation have become popular in recent years. Fibrin or butyl -2 -cyanoacrylate glues are being used for mesh fixation. It has been postulated that ideally such glue/adhesive should be-

1. biocompatible
2. cheap
3. easy to store and use

Though, fibrin glue showed good results (3,4,5) it did not fulfil criterion 2 and 3. So cyanoacrylate glue is a better choice for mesh fixation in open inguinal hernia repair. The aim of this study is to see if glue fixation technique is better than suture fixation of mesh in terms of chronic groin pain in inguinal hernia patients postoperatively.

II. Materials and methods

This study is carried out in Mahatma Gandhi medical college, Jaipur. Adult male aged between 40-60 years with unilateral inguinal hernia were selected as subjects in the study. All the surgeries were done by experienced surgeons under spinal anesthesia.

Exclusion criterion : 1. Bilateral hernia

2. recurrent hernia

3. complicated, obstructed or strangulated hernia

4. patient on treatment for psychiatric disorders, anticoagulants, steroids.

Patients enrolled into the study are categorized into 2 groups

- a. Classical Lichtenstein repair
- b. Suture-less technique with use glue for mesh fixation.

20 patients were randomly allotted into each group. The initial part of surgery was same in both the groups according to description of Lichtenstein (6). After separating the cord structures and lateralizing them inguinal canal is prepared by identifying anatomical land marks. The hernial sac is identified, dissected and contents reduced. In group A mesh was fixed with suture taken over tissue over pubic tubercle with about 1cm mesh overlap over pubic tubercle. Prolene sutures were used to fix the posterior wings of the mesh.

In group B mesh fixation was done with cyanoacrylate glue over pubic tubercle. 1ml of glue was used for each patient. Single stitch was taken from the 2 posterior wings of the mesh, taking care that the tissue below doesn't come in the stitch. The same polypropylene mesh was used for all patients in the study. The fascia and skin are closed in layers.

Diclofenac injection was given intramuscularly upon request of patient during hospital stay and postoperative pain was measured using Visual analogue scale (VAS) at 3h, 24h, 48h, 10days, 1 month, 3 month, 6 months, 1 year. Chronic pain was defined as pain even after 3 months postoperatively(7). Statistical analysis was done with Mann-Whitney test and Chi square test. P value of <0.05 was considered significant.

III. Results

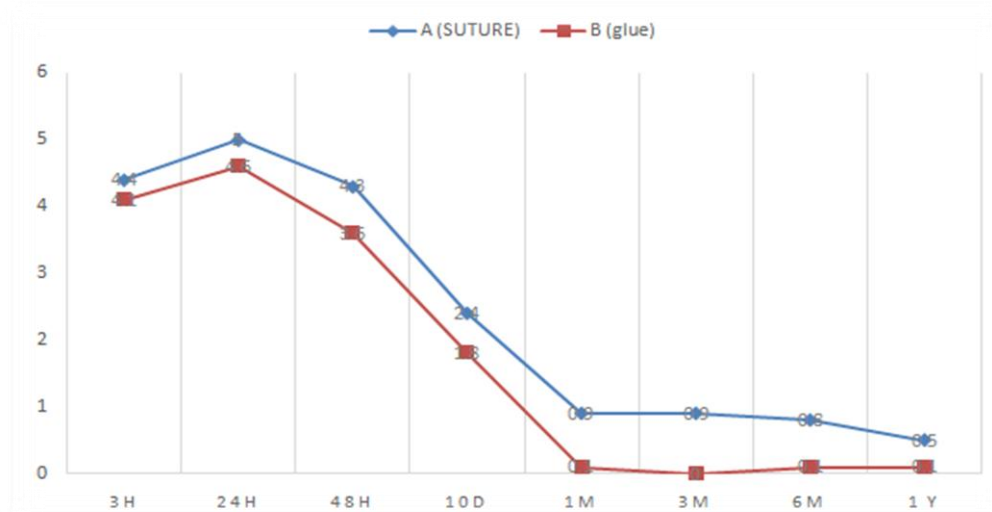
Table 1 demographics

	A (suture)	B(glue)	P
Number of patients	19	20	0.088
Age	50.2±8	48± 9.2	0.392
Type of hernia	A	B	
1	0	0	
2	2	3	
3a	5	7	
3b	10	9	
4	2	1	

Table 2 Mean pain scores

	3h	24h	48h	10days	1m	3m	6m	1 year
A (suture)	4.4± 2.1	5± 2.1	4.3± 1.8	2.4±2.1	0.9± 1.8	0.9± 1.9	0.8±2	0.5±1.5
B (glue)	4.1±2	4.6± 2	3.6± 1.6	1.8±0.8	0.1 ±0.2	0	0.1 ±0.4	0.1±0.2
P	0.029	0.228	0.051	0.020	0.4	0.195	0.238	0.197

40 patients were enrolled in the study of which 1 patient was lost in follow up. 19 patients were allotted in group A and 20 patients in group B. Both groups are matched for age and type of hernia. Throughout the study postoperative pain was less in group B patients as compared to group A, although both groups showed similar trend. Peak intensity of pain was observed after 24 hours of surgery in both groups of patients which decreased in intensity progressively over a period of time. There was not much difference in early postoperative pain in both groups. From 48 hours to 1 year period there is significant difference in pain scores but not statistically significant, probably due to limited number of cases in the study. Only 2 cases in group A had chronic groin pain. General morbidity in group A was 26.3% including chronic groin pain, 2 patients had urinary retention and 1 patient had recurrence in group A. Morbidity in group B was only 5%, only 1 patient had urinary retention.



IV. Discussion

Open mesh hernioplasty for inguinal hernia is one the most frequently performed surgery worldwide(8). It is documented that unacceptable number of patients may suffer from chronic groin pain, discomfort and reduced quality of life(9-12). The technique of mesh fixation is a factor that is often blamed for postoperative chronic groin pain. The reason may be due to nerve entrapment, foreign body reaction or injury.

Tissue glues are in use in surgical practice for over 20 years for various indications. In the recent times the use of tissue glues for mesh fixation in hernia repair has become popular. The use of tissue glues has shown promising results in reducing postoperative chronic groin pain in patients of mesh hernia repair. The ideal tissue adhesive should have following requirements

- 1.biocompatible
- 2.cheap
- 3.easy to store and use

Two types of tissue adhesives are used for mesh fixation in inguinal hernia repair. A) Fibrin B) Cyanoacrylate Though fibrin glues showed very good results(13-15), they do not fulfil requirements 2 and 3, so cyanoacrylate glues are relatively better choice for mesh fixation in open hernia repair. The study aims to compare fixation of mesh with glue vs suture material in reduction of postoperative chronic groin pain. Though statistical significance was not observed in the results due to limited number of cases in the study, there is clinical superiority of glue fixation over suture fixation of mesh was observed.

Alfieri et al defined chronic pain as pain for more than 3 months postoperatively(7). In the present study we have observed similar trend in pain but different levels of pain scores. In both the groups subjects had peak pain 24 hours after surgery, with almost similar pain scores probably due to trauma during the surgery itself and local release of inflammatory mediators. Some studies suggested that there is reduction in acute pain also due to glue fixation (16). There is gradual decrease in pain 48hours to 1 year period in both the groups but significant decrease of pain scores is seen in group B. Randomized control trial by Dabrowiecki et al(17) and Paajanen et al(18) did not show any difference in long term pain. Some recent studies suggest that there is evidence of decrease in chronic groin pain and early return to normal activities is noticed with use of glue for mesh fixation. Kim-Fuchs et al demonstrated less pain in glue groups in a longer follow up study of 5 years (19). General morbidity was also less in glue fixation group (5%) when compared to suture fixation group (26.3%). In a study conducted by Testini et al overall morbidity was reported as 39% in "suture" patients and 11% in "glue" patients(15). In our study overall morbidity is 26.3% and 5% respectively. Few number of cases and short follow up period are evident drawbacks of this study.

V. Conclusion

This study demonstrates that mesh fixation with glue causes less morbidity and postoperative pain than suture fixation though statistical significance could not be elicited. A study with larger sample size and long term follow up could give more definitive results.

References

- [1]. Awad S, Fagan S (2004) Current approaches to inguinal hernia repair. *Am J Surg* 118:9S-16S
- [2]. Kumar S, Wilson RG, Nixon SJ et al (2002) Chronic pain after laparoscopic and open mesh repair of groin hernia. *Br J Surg* 89:1476-1479
- [3]. Campanelli G, Champault G, Pascual MH, Hoferlin A, Kingsnorth A, et al. (2008) Randomized controlled blinded trial of Tissucol/Tisseel for mesh fixation in patients undergoing Lichtenstein technique for primary inguinal hernia repair: rationale and study design of the TIMELI trial. *Hernia* 12(2): 159-165.17.
- [4]. Lovisetto F, Zonta S, Rota E, Mazzilli M, Bardone M, et al. (2007) Use of human fibrin glue (Tissucol) versus staples for mesh fixation in laparoscopic transabdominal preperitoneal hernioplasty: a prospective, randomized study. *Ann Surg* 245(2): 222-231.18.
- [5]. Schwab R, Schumacher O, Junge K, Binnebosel M, Klinge U, et al. (2006) Fibrin sealant for mesh fixation in Lichtenstein repair: biomechanical analysis of different techniques. *Hernia* 11(2): 139- 145.
- [6]. Lichtenstein IL, Shulman AG, Amid PK, Montllor MM (1989) The tension-free hernioplasty. *Am J Surg* 157(2): 188-193.
- [7]. Alfieri S, Amid PK, Campanelli G, Izard G, Kehlet H, et al. (2011) International guidelines for prevention and management of post-operative chronic pain following inguinal hernia surgery. *Hernia* 15(3): 239-249
- [8]. Bay-Nielsen M, Kehlet H, Strand L, Malmstrom J, Andersen FH, Wara P, et al. (2001) Quality assessment of 26,304 herniorrhaphies in Denmark: a prospective nationwide study. *Lancet* 358(9288): 1124-1128
- [9]. Erhan Y, Erhan E, Aydede H, Mercan M, Tok D (2008) Chronic pain after Lichtenstein and preperitoneal (posterior) hernia repair. *Can J Surg* 51(5): 383-387.
- [10]. Franneby U, Sandblom G, Nordin P, Nyern O, Gunnarson U (2006) Risk factors for long-term pain after hernia surgery. *Ann Surg* 244(2): 212-219.
- [11]. Hetzer FH, Hotz T, Steinke W, Schlumpf R, Decurtinis M, et al. (1999) Gold standard for inguinal hernia repair: Shouldice or Lichtenstein? *Hernia* 3(3): 117-120
- [12]. Kumar S, Wilson RG, Nixon SJ, Macintyre IM (2002) Chronic pain after laparoscopic and open mesh repair of groin hernia. *Br J Surg* 89(11): 1476-1479.
- [13]. Campanelli G, Champault G, Pascual MH, Hoferlin A, Kingsnorth A, et al. (2008) Randomized controlled blinded trial of Tissucol/Tisseel for mesh fixation in patients undergoing Lichtenstein technique for primary inguinal hernia repair: rationale and study design of the TIMELI trial. *Hernia* 12(2): 159-165.

- [14]. Lovisetto F, Zonta S, Rota E, Mazzilli M, Bardone M, et al. (2007) Use of human fibrin glue (Tissucol) versus staples for mesh fixation in laparoscopic transabdominal preperitoneal hernioplasty: a prospective, randomized study. *Ann Surg* 245(2): 222-231
- [15]. Schwab R, Schumacher O, Junge K, Binnebosel M, Klinge U, et al. (2006) Fibrin sealant for mesh fixation in Lichtenstein repair: biomechanical analysis of different techniques. *Hernia* 11(2): 139-145.
- [16]. Colvin HS, Rao A, Cavali M, Campanelli G, Amin AI (2013) Glue versus suture fixation of mesh during open repair of inguinal hernia: a systematic review and meta-analysis. *World J Surg* 37(10): 2282-2292
- [17]. Dabrowiecki S, Piersciński, Szczęsny W (2012) The Glubran 2 glue for mesh fixation in Lichtenstein's hernia repair: a double-blind randomized study. *Wideochirurgia Tech Maloinwazyjne* 7(2): 96-104.
- [18]. Paajanen H, Kössi J, Silvasti S, Hulmi T, Hakala T (2011) Randomized clinical trial of tissue glue versus absorbable sutures for mesh fixation in local anaesthetic Lichtenstein hernia repair. *Br J Surg* 98(9): 1245-1251.
- [19]. Kim-Fuchs C, Angst E, Vorburger S, Helbling C, Candinas D, et al. (2012) Prospective randomized trial comparing sutures with sutureless mesh fixation for Lichtenstein hernia repair: long term results. *Hernia* 16(1): 21-27.
- [20]. Testini M, Lissidini G, Poli E, Gurrado A, Lardo D, et al. (2010) A single-surgeon randomized trial comparing sutures, N-butyl-2-cyanoacrylate and human fibrin glue for mesh fixation during primary inguinal hernia repair. *Can J Surg* 53(3): 155-160.

Dr. RajkamalKanojiya et al "A Comparative Study on Postoperative Chronic Groin Pain in 'Suture' Vs 'Glue' Mesh Fixation in Open Hernia Repair." *IOSR Journal of Dental and Medical Sciences (IOSR-JDMS)*, vol. 17, no. 8, 2018, pp 26-29.