

## A Prospective Study of Gastrointestinal perforations Leading to Acute Peritonitis

Dr.Ramesh Kumar Korumilli<sup>1</sup>, Dr.Jakkula Srikanth<sup>2</sup>, Dr .Muvva Sri Harsha<sup>3</sup>.  
Dr. Md Raheemuddinkhan<sup>4</sup>, Dr.Kanmathareddy Amulya<sup>5</sup>

<sup>1</sup>(Professor and HOD, General surgery, SVS Medical college, KNR university of Health sciences, INDIA)

<sup>2,3,4,5</sup>(Post-Graduates of General Surgery, SVS Medical college, KNR university of Health sciences, INDIA)

Corresponding Author: Dr.Ramesh Kumar Korumilli

### Abstract:

**Introduction :** Perforation is defined as an abnormal opening in any organ or viscous. Perforation of hollow viscous is one of the common surgical emergency in India ..Chronic alcoholism, Smoking, chronic use of Non steroid anti-inflammatory drugs (NSAIDS) are major risk factors for perforations

**Materials and methods :** This study was hospital based prospective study conducted from September 2016 to January 2018. A total number of 171 cases were included in our study. The details of age, sex, anatomical location of perforation, signs and symptoms, complications and etiology were analyzed.

**Results:** In our study, out of 171 patients, 133 were males (77.78%). 20 to 40 years of age group are most susceptible for perforation (47.37%). Gastro-duodenal perforation (48.54%) followed by appendicular (33.92%) perforation is the most common. Pain abdomen is universal symptom and tenderness is universal sign in our study (100%). Chronic alcoholism and peptic ulcer disease is most commonly associated with gastric and duodenal perforation. Delayed presentation >48 hours associated with co-morbidities are leading causes of septicemia and death.

**Conclusion:** Early diagnosis along with appropriate preoperative management followed by the required surgical procedure decides the outcome of patients. As and when post operative complications arise they should be treated with utmost care

**Keywords:** Acid peptic disease, chronic alcoholism, developing country, iatrogenic, wound gapping.

Date of Submission: 28-07-2018

Date Of Acceptance: 12-08-2018

### I. Introduction

Perforation (derived from 'perforatus', a latin word means to bore through) is defined as an abnormal opening in an organ or viscous. Perforation of hollow viscous is one of the common surgical emergency in india.<sup>[1]</sup> Etiology and spectrum of perforations vary widely between developing and developed countries. Upper gastro intestinal perforations are more common in India/developing countries, where as lower gastro intestinal perforations are more common in western part/developed countries.<sup>[2,3,4]</sup> perforations are still associated with higher mortality and morbidity even with all the advances in preoperative care, anti-microbial therapy and intensive care facilities, this is mainly due to delay in presentation of the patient to hospital<sup>[5,6]</sup>. Perforation of stomach, duodenum and small bowel forms majority of hollow viscus perforations in our country, where as large bowel perforations with underlying malignancy and diverticulitis are more common in developed countries.<sup>[7]</sup> Smoking, chronic use of Non steroid anti-inflammatory drugs (NSAIDS) are major risk factors for perforations<sup>[8,9]</sup>. Even though perforation of large bowel is less commonly encountered in our country, it is a very fatal condition because of sepsis caused by both anaerobic and aerobic enteric pathogens. It is extremely important to diagnose hollow viscous perforations early as the mortality and morbidity increases with delay in establishing a diagnosis<sup>[10,11]</sup>.

### II. Materials and Methods

This is a institutional based prospective study of 171 patients conducted in Department of General Surgery, SVS medical college, Mahabubnagar from September 2016 to January 2018. The study protocol was approved by the ethical committee and research review board of our institute. A written and informed consent was taken from all the patients. All the patients irrespective of age and gender with gastrointestinal perforations were included in the study. Patients diagnosed with peritonitis because of esophageal, pancreato-biliary & genitor-urinary perforations, anastomotic leak and faecal fistula were excluded from the study.

All patients who presented to our emergency department with suspicion of peritonitis were thoroughly examined clinically after obtaining proper history. After initial resuscitation with crystalloids and blood

wherever necessary, radiological investigations like x-ray erect abdomen, and ultrasound abdomen were done. In diagnostic uncertainty, CECT abdomen with water soluble contrast was done. Other investigations like complete blood picture, viral screening, blood urea, serum creatinine, serum electrolytes, electrocardiography and blood sugars were done. After taking informed and written consent, all the patients underwent exploratory laparotomy with vertical midline incision. Site of the perforation was identified and the necessary surgical procedure (appendectomy, primary closure with omentopexy, resection & anastomosis) was performed by the operating surgeon. Patients were discharged after they are able to take oral feeding, have good ambulation and kept on regular followup. Patients with complications were managed accordingly.

Complete data of the patient from the time of admission till discharge was obtained after informed consent. Analysis of age, sex, site of perforation, symptoms, signs, etiology, duration, complications and treatment was done in our study. Data was analyzed by Microsoft Excel software. Data was summarized by Mean ± SD for continuous data and percentages for categorical data. Chi-square test was done to compare variable and P value <0.005 is taken as statistically significant.

### III. Results

One seventy one patients presented to SVS MEDICAL COLLEGE AND HOSPITAL,, Mahaboobnagar with acute peritonitis secondary to gastrointestinal perforation were studied.

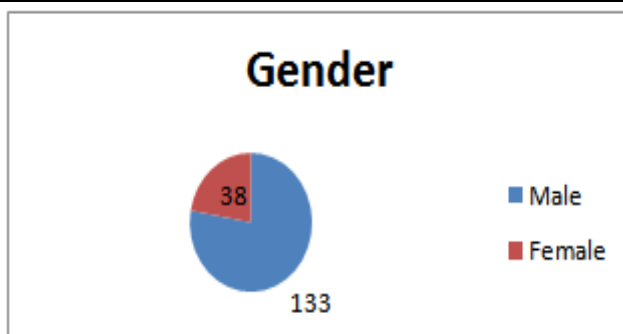
#### GENDER AND AGE:

Out of 171 cases, 133 (77.78%) were males and 38(22.22%) were females ,(TABLE-1,FIGURE-1 ).In our study, majority of the people belong to the age group of 21-30years which accounts to 25.73%.The incidence according to age group in 1-10years were a total of 6cases(3.51%),11-20years were 20cases(11.70%),21-30 years were 44 cases(25.73%),31-40 years were 37 cases(21.64%),41-50 years were 31 cases(18.13%),51-60 years were 22 cases(12.87%),61-70 years were 11 cases(6.43%).(TABLE-2,FIGURE-2 ).The youngest patient in our study was 7 years who presented with ileal perforation due to trauma and the oldest patient was 68 years old.

**Table-1: the gender distribution of all subjects**

<i>Gender</i>	<i>No. of subjects</i>	<i>% of subjects</i>
Male	133	77.78
Female	38	22.22
<b>Total</b>	<b>171</b>	<b>100.00</b>

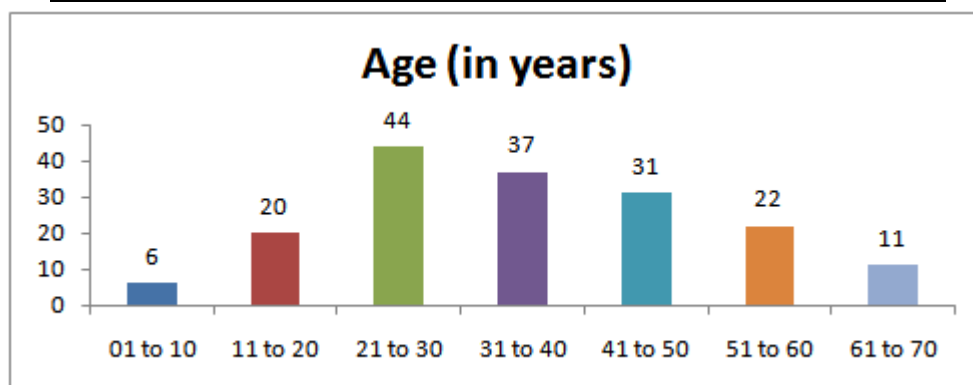
**Figure-1: the pie diagram for the gender distribution of all subjects**



**Table-2: the age (in years) distribution of all subjects**

<i>Age (in years)</i>	<i>Male</i>	<i>% of male</i>	<i>Female</i>	<i>% of female</i>	<i>Total subjects</i>	<i>% of total subjects</i>
01 to 10	5	3.76	1	2.63	6	3.51
11 to 20	15	11.28	5	13.16	20	11.70
21 to 30	32	24.06	12	31.58	44	25.73
31 to 40	32	24.06	5	13.16	37	21.64
41 to 50	25	18.80	6	15.79	31	18.13
51 to 60	17	12.78	5	13.16	22	12.87
61 to 70	7	5.26	4	10.53	11	6.43
<b>Total</b>	<b>133</b>	<b>100.00</b>	<b>38</b>	<b>100.00</b>	<b>171</b>	<b>100.00</b>

**Figure-2: the simple bar diagram for the age (in years) distribution of all subjects**



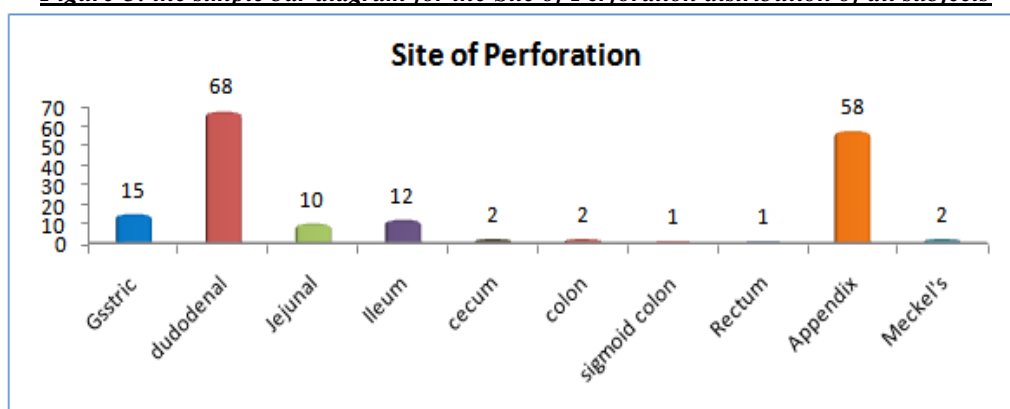
**SITE:**

Most common site of perforation was first part of duodenum which totals to 38 cases(39.77%) in which majority were males. The second most common site for perforation is appendix(58 cases-33.92%) in which majority of them were females. Rectum and sigmoid perforations were rare which accounts to 0.58 and 0.58% respectively(TABLE-3,FIGURE-3).

**Table-3: the Site of Perforation distribution of all subjects**

Site of Perforation	Male	% of male	Female	% of female	Total subjects	% of total subjects
Gastric	14	10.53	1	2.63	15	8.77
Duodenal	63	47.37	5	13.16	68	39.77
jejunal	9	6.77	1	2.63	10	5.85
Ileum	9	6.77	3	7.89	12	7.02
Cecum	0	0.00	2	5.26	2	1.17
Colon	2	1.50	0	0.00	2	1.17
Sigmoid Colon	0	0.00	1	2.63	1	0.58
Rectum	0	0.00	1	2.63	1	0.58
Appendix	35	26.32	23	60.53	58	33.92
Meckel's	1	0.75	1	2.63	2	1.17
<b>Total</b>	<b>133</b>	<b>100.00</b>	<b>38</b>	<b>100.00</b>	<b>171</b>	<b>100.00</b>

**Figure-3: the simple bar diagram for the Site of Perforation distribution of all subjects**



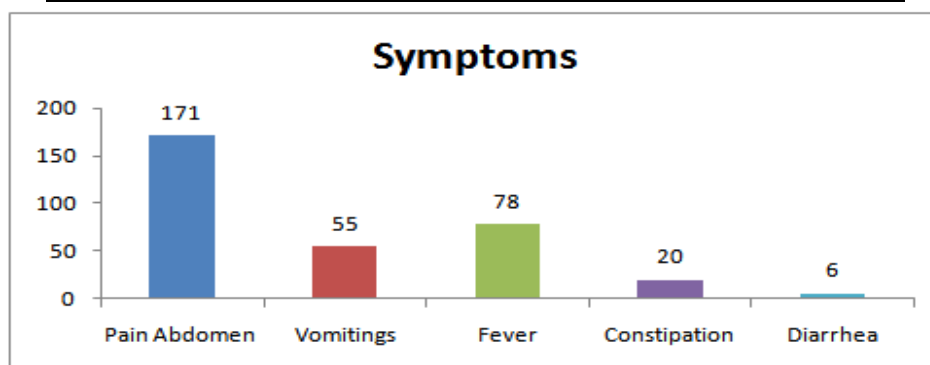
**SYMPTOMS:**

Abdominal pain(171 cases) being the most common symptom tops the chart followed by fever(78 cases) and vomitings(55cases).(TABLE-4, FIGURE-4)

**Table-4: the Symptoms distribution of all subjects**

Symptoms	Total subjects	No. of subjects	% of subjects
Pain Abdomen	171	171	100.00
Vomiting	171	55	32.16
Fever	171	78	45.61
Constipation	171	20	11.70
Diarrhea	171	6	3.51

**Figure-4: the simple bar diagram for the Symptoms distribution of all subjects**



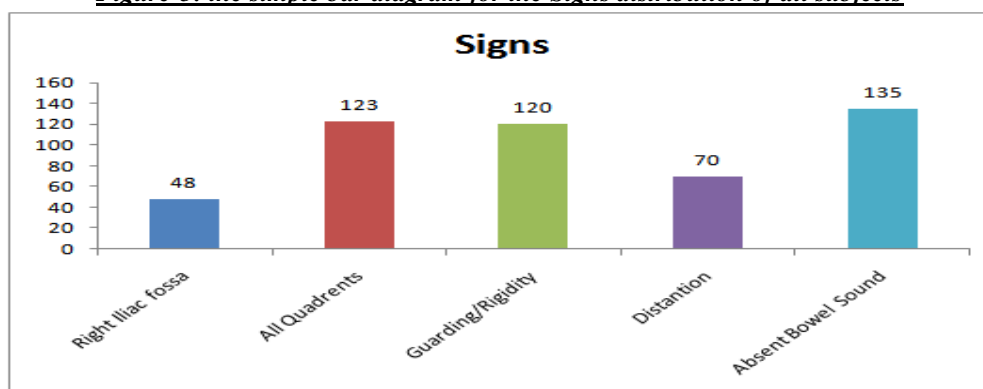
**SIGNS:**

The majority of appendicular perforations present as right iliac fossa tenderness(48 cases-28.07%).All quadrant tenderness is noted in 71.93%In our study , tenderness being the most common sign in all the gastrointestinal perforations followed by Guarding and rigidity ,distention and absent bowel sounds constitutes to 70.18%,40.94%,78.95% respectively.(TABLE-5,FIGURE-5).

**Table-5: the Signs distribution of all subjects**

	Signs	Total subjects	No. of subjects	% of subjects
Tenderness	Right Iliac fossa	171	48	28.07
	All Quadrants	171	123	71.93
	Guarding/Rigidity	171	120	70.18
	Distention	171	70	40.94
	Absent Bowel Sounds	171	135	78.95

**Figure-5: the simple bar diagram for the Signs distribution of all subjects**



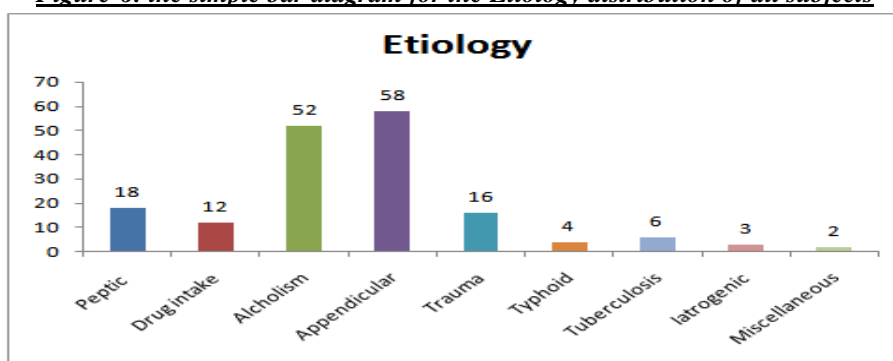
**ETIOLOGY:**

Chronic alcoholism is the leading cause of duodenal perforation in our study(30.41%) followed by peptic ulcer disease and chronic drug abuse accounting to 10.53%,7.02% respectively. Trauma is the prime cause for perforation in children.In elderly patients ,malignancy is the cardinal cause for perforation.(TABLE-6,FIGURE-6).

**Table-6: the Etiology distribution of all subjects**

Etiology	No. of subjects	% of subjects
Peptic	18	10.53
Drug intake	12	7.02
Alcoholism	52	30.41
Appendicular	58	33.92
Trauma	16	9.36
Typhoid	4	2.34
Tuberculosis	6	3.51
Iatrogenic	3	1.75
Miscellaneous	2	1.17
<b>Total</b>	<b>171</b>	<b>100.00</b>

**Figure-6: the simple bar diagram for the Etiology distribution of all subjects**



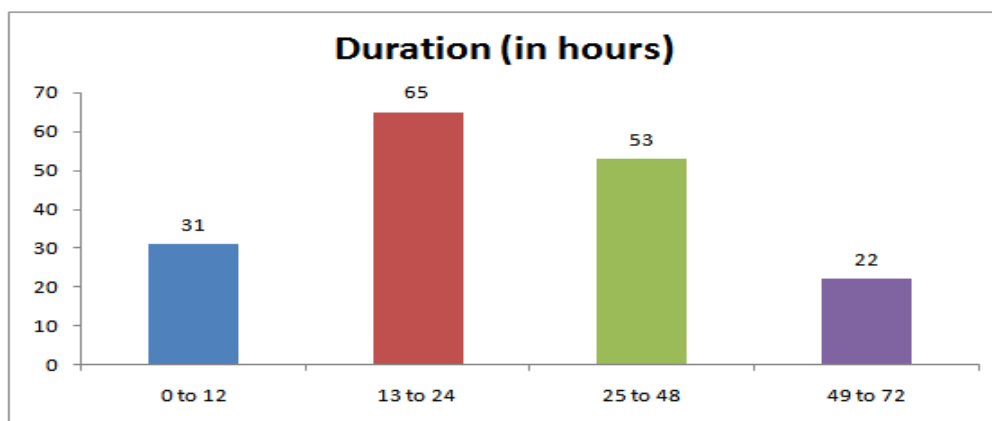
**Duration :**

65 out of 171 patients i.e 38.01% presented to hospital within 13-24 hours. 30.99% presented between 24 to 48 hours, 18.13% presented within first 12 hours and 12.87% presented after 48 hours. (TABLE -7, FIGURE-7)

**Table-7: the Duration (in hours) distribution of all subjects**

Duration (in hours)	No. of subjects	% of subjects
0 to 12	31	18.13
13 to 24	65	38.01
25 to 48	53	30.99
49 to 72	22	12.87
<b>Total</b>	<b>171</b>	<b>100.00</b>

**Figure-7: the simple bar diagram for the Duration (in hours) distribution of all subjects**



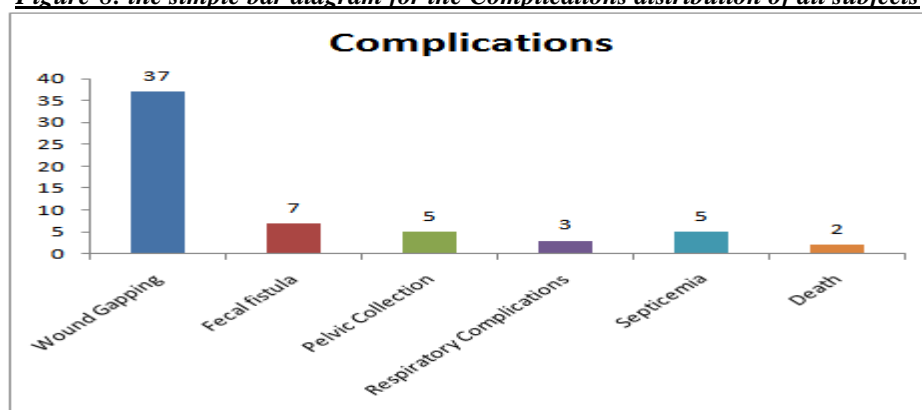
**Complications:**

Wound gaping (37 cases, 62.71%) is the most common complication in our study, followed by faecal fistula (7 cases, 11.86%), pelvic collection (5 cases, 8.47%), Respiratory complications (3 cases, 5.08%), septicemia (5 cases, 8.47%) and death (2 cases, 3.39%). Death and septicemia are associated with delayed presentation of the patient to hospital. (TABLE - 8, FIGURE - 8)

**Table-8: the Complications distribution of all subjects**

Complications	No. of subjects	% of subjects
Wound Gapping	37	62.71
Fecal fistula	7	11.86
Pelvic Collection	5	8.47
Respiratory Complications	3	5.08
Septicemia	5	8.47
Death	2	3.39
<b>Total</b>	<b>59</b>	<b>100.00</b>

**Figure-8: the simple bar diagram for the Complications distribution of all subjects**



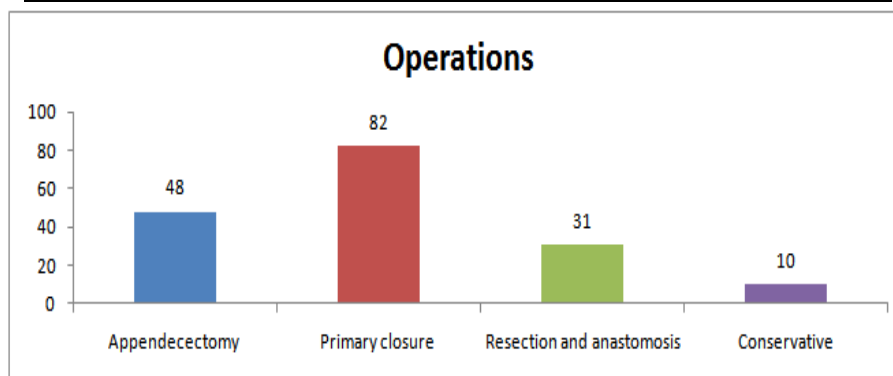
### Treatment

Patients with perforated appendicitis and without any mass formation were treated with Appendectomy (48 cases, 28.07%) & those with mass formation were treated conservatively (10 cases, 5.85%). Exploratory laparotomy followed by primary closure of perforation with omental patch was done in 82 cases, 47.95%. 31 cases, 18.13% underwent resection & anastomosis. (TABLE-9, FIGURE -9)

**Table-9: the Operations distribution of all subjects**

Operations	No. of subjects	% of subjects
Appendectomy	48	28.07
Primary closure	82	47.95
Resection and anastomosis	31	18.13
Conservative	10	5.85
<b>Total</b>	<b>171</b>	<b>100.00</b>

**Figure-9: the simple bar diagram for the Operations distribution of all subjects**



### IV. Discussion

Hollow viscous perforation is a common emergency situation faced in surgical departments especially in our country. Amongst the 171 cases we have studied, 77.78% are males where as 22.22% were females. Majority of the perforation peritonitis show clear male preponderance<sup>[12]</sup>. Commonest reason for male preponderance in our study is due to smoking and chronic alcoholism. In our study majority of perforation peritonitis is seen below 45 years of age, this is in contrast to western countries where perforation peritonitis is most common in elderly age group. This is due to prevalence of H.pylori infection, alcoholism, Chronic NSAID usage and due to socioeconomic conditions of a developing country when compared to western countries where common causes are secondary to malignancies, radiotherapy and diverticulitis<sup>[13,14,15]</sup>.

According to our study, duodenal perforation is most common i.e. 39.77% followed by appendicular (33.92%), gastric (8.77%), ileal (7.02%). Large bowel perforations are relatively rare in our country. Our findings are consistent with jhobta et al<sup>[3]</sup>, Thirumalagiri VR et al<sup>[13]</sup>. Pain abdomen is universal finding in all of our cases followed by fever and vomiting. Diffuse pain is present in all of the perforation peritonitis except for appendicular perforation where the pain is more localized to right iliac fossa. Tenderness (regional/all quadrant) present in 100% cases. Guarding/rigidity is seen in 70% of cases and it is more pronounced in duodenal/gastric perforations when compared to appendicular. Bowel sounds are absent in 78% of cases. Distention is seen in

40.94 % of cases. These findings are consistent with findings of Meena, et al<sup>[12]</sup>. Majority of gastro intestinal perforations are diagnosed by free air under diaphragm/pneumoperitoneum, however this finding is not commonly seen in case of appendicular perforations. Bansal et al reported that free air under diaphragm has overall positivity rate of 89.20% in detecting hollow viscous perforation, it is highest for gastric/duodenal i.e. 94.19% and least for appendicular 7.69%<sup>[16]</sup>

Chronic alcoholism is commonest cause in our study at 30.41% followed by peptic ulcer and chronic NSAID usage. 10% of patients who presented with peritonitis had a previous history of recurrent acid peptic disease. There is strong relation between alcoholism and duodenal perforation in our region. Ulcer history of varying period in patients presenting with perforation was recorded by Mishra SB et al<sup>[4]</sup> and Bharathi RC<sup>[17]</sup> et al. Ileal perforation is more common in cases associated with trauma, typhoid and Tuberculosis. Enteric fever associated perforation usually occurs between 2<sup>nd</sup> and 3<sup>rd</sup> of fever. In a study done by purohit<sup>[18]</sup>, majority of perforations were seen in first week of fever in contrast to study done by eggleston and santoshi<sup>[19]</sup> which reported that 33% occur in 2<sup>nd</sup> week of fever.

The choice of operation in our study depended on the site of perforation, general condition of the patient, peritoneal contamination and choice of the operating surgeon. Majority of the patients underwent primary closure of defect with modified graham's omentoplasty. All of those with appendicular perforation were managed by appendectomy. Majority of rectal and other large bowel perforations were treated with resection & anastomosis along with a proximal stoma. Similar observations were noted by Meena et al<sup>[12]</sup> and Jhobta et al<sup>[3]</sup>. Wound gaping was the most common and frequent complication in our study despite maintaining strict aseptic protocol. Delayed presentation > 48 hours has strong association with wound gaping and poor outcome. Wound gaping has been managed conservatively by regular dressings, upgrading the antibiotic according to the culture and sensitivity and improving the overall nutritional status of the patient. When needed, wound closed by secondary suturing. Increased age and respiratory complications are commonly associated with mortality in our study. Rajesh et al<sup>[20]</sup> has noted similar findings in their study.

## V. Conclusion

Hollow viscous perforation leading to peritonitis one of the common surgical emergencies worldwide. However, the etiology, site of perforation and age group varies between developing countries and the developed countries due to underlying socio-economic factors. Early diagnosis along with appropriate preoperative management followed by the required surgical procedure decides the outcome of patients. In our study, appendicular perforation followed by duodenal perforation forms majority of the peritonitis due to hollow viscous perforation. Proper post-operative care is important for better outcome.

## References

- [1]. Ramakrishnan K, Salinas RC. Peptic ulcer disease. *Am Fam Physician* 2007;76:1005-12.
- [2]. Dorairajan LN, Gupta S, Deo SV, Chumber S, Sharma LK. Peritonitis in India – A decade's experience. *Trop Gastroenterol* 1995;16:33-8.
- [3]. Jhobta RS, Attri AK, Kaushik R, Sharma R, Jhobta A. Spectrum of perforation peritonitis in India – Review of 504 consecutive cases. *World J Emerg Surg* 2006;1:26.
- [4]. Danapat MC, Mukherjee SB, Mishra PC. Howlader Gastro-intestinal perforations. *Indian J Surg.* 1991;53(5):189-93.
- [5]. Agarwal N, Saha S, Srivastava A, Chumber S, Dhar A, Garg S. Peritonitis: 10 years' experience in a single surgical unit. *Trop Gastroenterol* 2007;28:117-20. 3.
- [6]. Gupta S, Kaushik R. Peritonitis - The Eastern experience. *World J Emerg Surg* 2006;1:13.
- [7]. Mathur SN, Khandelwal R. 1991. "Peptic perforation A clinical study of prognostic factors", *Ind J Surg.*, 53 (6): 251 -253.
- [8]. Inderbir S. 1991. "Alimentary system Gastrointestinal tract" in *Human embryology*, 5th edition, McMillan India press. 174-197.
- [9]. Swanes C, Soreide JA, Soreide O, Bakke P, Vollset SE. A skarstein smoking and ulcer perforation. *Gut.* 1997;41:177-80.
- [10]. Sadler TW. 1994. "Digestive system" in *Langman's medical embryology*, 7th edition, Williams and Wilkin Company., 242-271.
- [11]. Sorsi GA, Richard H, Turnage. 2002. "Appendicitis in Gastrointestinal and liver disease. *Pathophysiology and diagnosis / management* 7th edition edit by Sleisenger and Fordtran's., 2: 2089-2096.
- [12]. Meena LN, Jain S, Bajjya P. Gastrointestinal perforation peritonitis in India: A study of 442 cases. *Saudi Surg J* 2017;5:116-21
- [13]. Thirumalagiri VR, Reddy SRJ, Chandra TH. Acute peritonitis secondary to hollow viscous perforation: a clinical study. *Int Surg J* 2017;4:2262-9.
- [14]. Mahajan G, Kotru M, Sharma R, Sharma S. Usefulness of histopathological examination in nontraumatic perforation of small intestine. *J Gastrointest Surg* 2011;15:1837-41.
- [15]. Wani RA, Parray FQ, Bhat NA, Wani MA, Bhat TH, Farzana F. Nontraumatic terminal ileal perforation. *World J Emerg Surg* 2006;1:7.
- [16]. Bansal J, Jenaw RK, Rao J, Kankaria J, Agrawal NN. Effectiveness of plain radiography in diagnosing hollow viscus perforation: Study of 1,723 patients of perforation peritonitis. *Emerg Radiol* 2012;19:115-9.
- [17]. Bharti RC, Marwaha DC. Immediate definitive surgery in perforated duodenal ulcer: A comparative study between definitive surgery and simple closure. *Indian J Surg.* 1996;58(10):275-9
- [18]. Purohit PG. Surgical treatment of typhoid: perforations Experience of 1976 Sangli epidemic *Indian J Surg.* 1978;40:227-38.
- [19]. Eggleston FC, Santoshi B. Typhoid perforation: choice of operation. *Br J Surg.* 1981;68:341-2.
- [20]. Rajesh V, Chandra SS, Smile SR. Risk factors predicting operative mortality in perforated peptic ulcer disease. *Trop Gastroenterol* 2003;24:148-50.

Dr.Ramesh Kumar Korumilli "A Prospective Study of Gastrointestinal perforations Leading to Acute Peritonitis." *IOSR Journal of Dental and Medical Sciences (IOSR-JDMS)*, vol. 17, no. 8, 2018, pp 51-57