

## Computed Tomography Evaluation of Root Canal Desobturation of Lower Human Incisors

Gilmar Correia\*, Antônio Henrique Brait\*, Alexandre Sigrist De Martin\*\*, Carlos Eduardo Da Silveira Bueno\*\*, Carlos Eduardo Fontana<sup>+</sup>, Caio Cesar Souza<sup>++</sup>, Geórgia Machado<sup>++</sup>, Hugo Bastos<sup>++</sup>, Sérgio Paulo Hilgenberg<sup>#</sup>, Ana Grasiela Da Silva Limoeiro\*.

\*Department of Endodontics, Faculdade de Ilhéus, Ilhéus, Bahia, Brazil.

\*\*Department of Endodontics, São Leopoldo Mandic Dental Research Center, Campinas, São Paulo, Brazil.

<sup>+</sup>Department of Endodontics, School of Dentistry, Pontifícia Universidade Católica de Campinas, SP, Brazil.

<sup>++</sup>Department of Endodontics, CORE School of Dentistry, Vitória da Conquista, BA, Brazil.

<sup>#</sup>Department of Orthodontics, União da Vitória, Paraná, Brazil.

Corresponding Author: Ana Grasiela Limoeiro

---

### Abstract:

**Introduction:** The purpose of endodontic treatment is cleaning and shaping the root canal system, but despite the technological advances, failures can occur. On this, non-surgical endodontic retreatment is the first option for solving the problem. **Materials and methods:** Twenty human mandibular incisors were instrumented with the Pro Design S system up to instrument 25.06 and filled with AHPlus (Dentsply / Maillefer, Ballaigues, Switzerland) cement using the single cone technique. The teeth were divided into two groups (n = 10) according to the instrument used for the retreatment. Group 1: Pro Design S 25.08 (PDS) and group 2: Reciproc 25.08 (REC). A master in endodontics prepared the teeth. The analysis of the remaining filling material was made by cone beam computed tomography (CBCT). **Results:** Student's t-test was used for comparison between groups. The two groups efficiently removed the obturator material, and there was no statistical difference between the groups (P > 0.05). **Conclusion:** Although it is a consensus in the literature that no technique is able to completely remove the obturator material from the canal system, in this study it was possible to observe in some samples the absence of material in the final tomography.

**Keywords:** Root Canal retreatment. Dentistry. Computed tomography.

---

Date of Submission: 27-07-2018

Date Of Acceptance: 09-08-2018

---

### I. Introduction

The purpose of endodontic treatment is the cleaning and shaping of the root canal system, but despite the technological advances in endodontics, failures can occur. Non-surgical endodontic retreatment is the first option for the solution of these problems (1). The unsatisfactory result of endodontic treatment occurs when the resolution of periapical radiolucency does not occur in four years, or clinical signs and symptoms are present in periods inferior to those mentioned (2). The possibilities of endodontic failure may arise due to the microbial persistence in the root canal system, due to the lack of aseptic control, unsatisfactory access surgery, insufficient cleaning, inadequate filling, or the occurrence of infiltration of the restorative material (3). Retreatment consists of the removal of the restorative material, re-instrumentation, and re-filling of the canal system, to overcome the deficiencies of previous endodontic therapy (4).

The success percentages of primary endodontic treatments are considered high since they reach failure rates of less than 15%. It is believed that the primary etiology of these failures is the persistence of bacterial infection, which implies the need for endodontic reintervention (5). The primary objective of the retreatment is the access to the apical foramen through the removal of the obturator material so that adequate cleaning and shaping of the entire root canal system can be performed, providing a satisfactory final filling (6).

The first option in cases of failure in endodontic treatment is non-surgical retreatment. The literature presents numerous techniques that are applied for the removal of gutta-percha and cement in endodontic retreatments, being the majority of them with the use of solvents. The solvents are used with the purpose of favoring the root canals, but in their chemical properties they present substances that cause high irritation to the periapical tissues, leaving large amounts of gutta-percha and cement residues in the wall of the root canals after cleaning, in addition, they favor the apical extrusion of debris during the unsealing process (7).

Many techniques have been indicated for the removal of the obturator materials: the use of endodontic instruments, heated instruments, solvents, mechanical or ultrasonic devices. In many cases, the combination of different techniques may be the fastest and most efficient method to promote the cleaning (8). The preparation of the root canal is the phase that most requires time spent in the treatment. For this time to be reduced, automated shaping systems have been developed to enable the treatment process further (9).

The objective of this research was to evaluate through cone beam computed tomography the amount of obturator material remaining after the use of mechanized Ni-Ti instruments.

## **II. Materials and Methods**

This study was submitted to the Research Ethics Committee of the Dental Research São Leopoldo Mandic - Campinas / SP because it is a study involving biological material. Moreover, the teeth were donated by the Ilhéus faculty bank.

Twenty recently extracted human lower incisors were selected and maintained in 0.1% thymol solution until the beginning of the study. The study included teeth with complete rhizogenesis, excluding teeth with anterior endodontic treatment, pulp calcifications, resorptions, root fractures and canals whose patency was not achieved after the access surgery. The teeth were washed in running water, and the root surface was cleaned by ultrasound and kept hydrated in saline solution until the beginning of the experiment. The size of the teeth was standardized at 18 mm using the caliper, by leveling its occlusal surfaces using a diamond disk (FKG Dentaire, La Chaux-de-Fonds, Switzerland). The teeth were radiographed in the ortho-radial direction with a # 15 instrument (Dentsply - Maillefer, Ballaigues, Switzerland), by a radiographic apparatus (Procion, Ribeirão Preto - SP) coupled to a digital sensor (Elite - Schick, SP) with 10 cm tooth-to-film distance and using the following exposure parameters (0.08s; 70 kV, 8 mA).

### **Instrumentation:**

The canals were instrumented with the ProDesign S system (Easy Dental Equipment, Belo Horizonte, Brazil), up to instrument 25.06. The patency was maintained with the use of instrument K#10 (Dentsply Maillefer, Ballaigues, Switzerland), passing 1 mm beyond the working length (WL). A single operator performed the instrumentation in strict accordance with the manufacturer's recommendation for speed and torque through an electric motor with torque control (Easy Dental Equipment).

The initial exploration of the canals was performed by a K #10 instrument (Dentsply Maillefer, Ballaigues, Switzerland), 2 mm from the WL, which was defined by placing the same instrument inside the canal until its tip appeared at the end, subtracting 1 mm. Each instrument was used four times and then discarded. At each instrument change, irrigation was performed with 5 mL of 2.5% NaOCl (Formula e Ação, São Paulo, Brazil). The smear layer was removed at the end of the instrumentation with 17% EDTA optimized using Easy clean, obeying the protocol of three times of 20 seconds, neutralized at the end with distilled water. The teeth were dried with absorbent paper tips and sealed by the single cone technique and AHPlus cement. The cement was placed in the cone and inserted into the canal with a single movement. The excess cone was cut with compactor and the crowns sealed with temporary cement Coltosol (Coltene-Whaledent, Cuyahoga Falls, OH) and stored at 100% humidity at 37 ° for 30 days.

New radiographic shots were performed with the same parameters in the mesio-distal and vestibular-lingual directions to evaluate the quality of the obturation. The teeth were divided into two groups (n = 10) according to the instrument used for the desobturation. Group 1: Pro Design S 25.08 (PDS) and group 2: Reciproc 25.08 (REC).

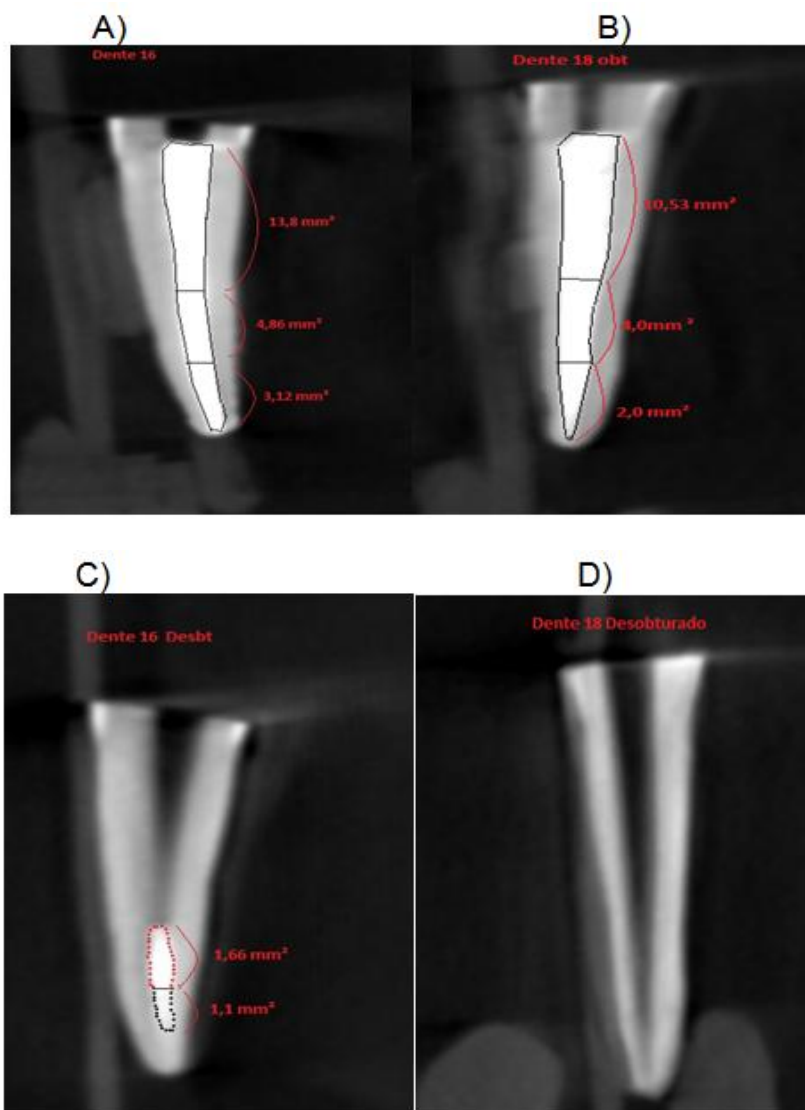
### **Retreatment:**

The removal of the sealing material was performed with the aid of the VDW Silver motor for the REC instruments with the Reciproc ALL program and the Easy motor for the PDS files, where each instrument was used only once. The in-and-out movement with brushing motion was performed until the removal of the obturator material was verified through the microscope with the increase of 8x. Irrigation was performed with 2 mL of 2.5% NaOCl at each withdrawal of the canal instrument, after three in-and-out movements. In the final irrigation protocol 5mL of 2.5%, NaOCl was used with the aid of a disposable hypodermic syringe (Injex Indústrias Cirúrgicas Ltda) and 30G needle (NaviTip, Ultradent, South Jordan, UT, USA).

### **CBCT Scans:**

After endodontic treatment and retreatment procedures, microtomographic examinations were performed to allow a non-destructive evaluation of the amount of obturator material remaining in the canals throughout its length, as well as in the cervical, middle and apical thirds (Figure 1).

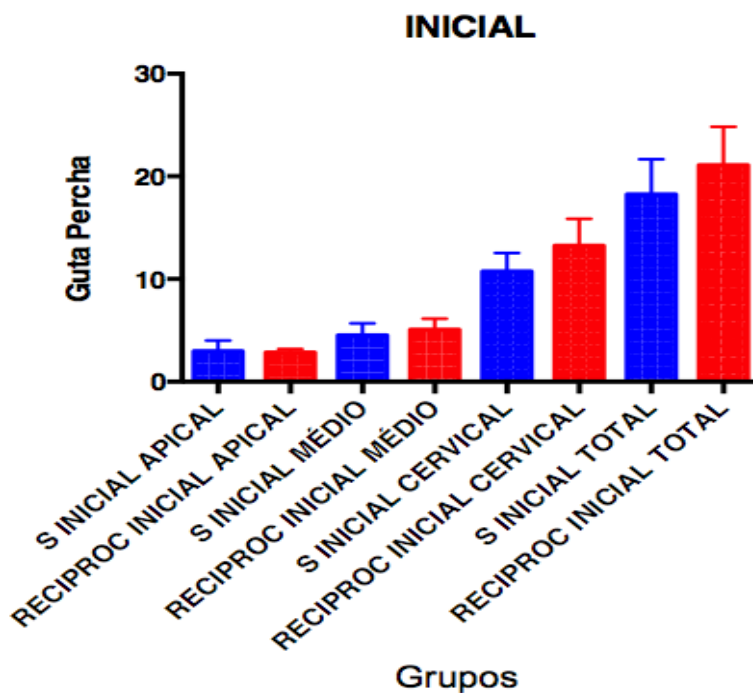
Figure 1. Cone Beam Computed Tomography (CBCT) representing Reciproc (A-C) and Pro Design S (B-D) groups. The figures show the final obturation (A-B) and the remaining obturator material (C-D).



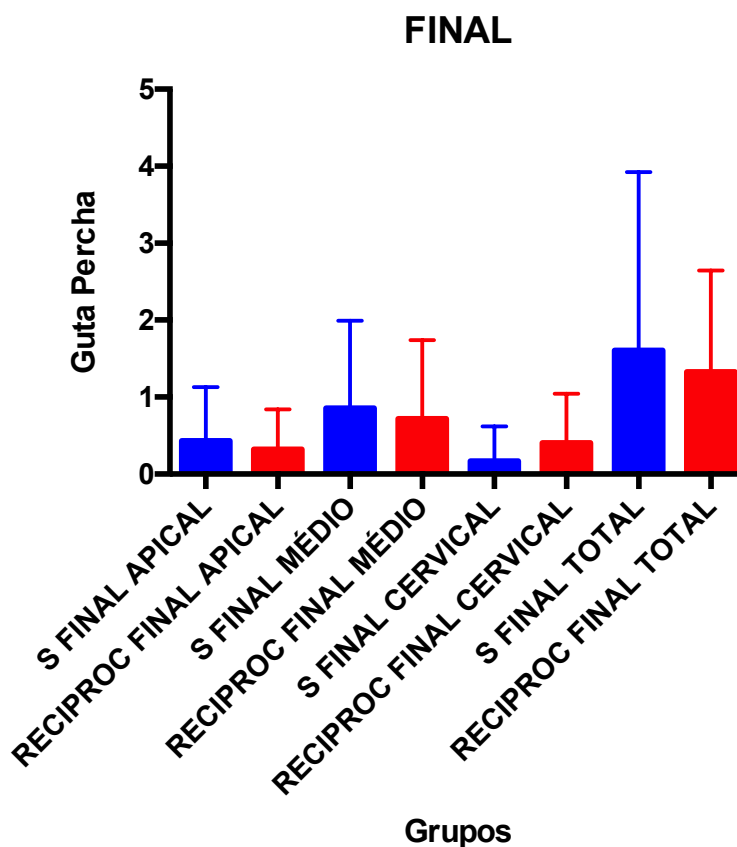
### III. Results

The groups were submitted to the D'Agostino & Pearson normality test ( $p = 0.05$ ), which demonstrated that the data obtained follow a normal distribution. The data were then submitted to the paired t-test ( $p = 0.05$ ), where no significant statistical difference was found between the groups ( $p > 0.05$ ), also in the thirds analyzed. (Graphics 1 and 2).

Graphic 1. Mean and standard deviation of the analyzed data, before retreatment procedures.



Graphic 2. Mean and standard deviation of analyzed data, after retreatment procedures.



#### IV. Discussion

The purpose of endodontic retreatment is to correct the failures occurring in the primary treatment, i.e., to obtain a bacteria-free tooth with canals wholly filled with the obturator material, and a proper coronal restoration for healing to occur. It is known that some potential factors influence endodontic treatment outcomes

such as the elimination of root canal infection present when treatment is initiated and the prevention of contamination during treatment (10). Although these systems were not recommended for use in retreatment the Reciproc system has already been tested in previous studies (11,12) with successful. The ProDesign S system is a rotating system and as far as we know has never been tested in retreatment. In this study, this system presented promising results, having completely removed the gutta percha in 6 samples.

Although the ProDesign S and Reciproc systems have the same tip/taper (25/08), they have different movements (rotating and reciprocating) and different cross sections (triple and double helix) respectively. Grampiero et al. (13) concluded that rotating and reciprocating systems exhibit the same ability to remove obturator material from the root canal system and that there were no differences between the reimaged and conventional files. The reciproc system was inferior in the ability to remove gutta-percha when compared to rotational systems according to some studies (14-16), while other studies showed that there were no differences (17-18), corroborating this research.

In contrast to some studies (11,19), it was possible to observe in this work the complete removal of the obturator material in some samples. At the significance level of 5%, there is insufficient evidence to conclude that there are differences between the Reciproc and ProDesign S systems in the removal of the obturator material.

## V. Conclusion

Although it is a consensus in the literature that no technique can completely remove the obturator material from the root canal system, in this study, it was possible to observe in some samples the absence of material in the final computed tomography. It is important to emphasize the importance of improving the techniques and especially the carrying out of advanced research in the development of new instruments that allow greater safety in the application of treatment and endodontic retreatment, as well as the success and minimization of procedural errors.

## References

- [1]. Yilmaz F; Koç C; Kamburoglu K et al. Evaluation of 3 different retreatment techniques in maxillary molar teeth by using micro-computed tomography. *J Endod* 2018;44:480-4.
- [2]. EUROPEAN SOCIETY OF ENDODONTOLOGY. Quality guidelines for endodontic treatment: consensus report of the European Society of Endodontology. *Int Endod J* 2006; Dec;39(12):921-30
- [3]. Giuliani V; Cochetti R; Pagavino G. Efficacy of protaper universal retreatment files in removing filling materials during root canal retreatment. *J Endod* 2008; 34(11):1381-1384.
- [4]. Lopes HP; Siqueira Junior JF. *Endodontia: Biologia e Técnica*. 2. ed. Guanabara Koogan. Rio de Janeiro. 2004.
- [5]. Song M; Kim HC; Lee W et al. Analysis of the Cause of Failure in Nonsurgical Endodontic Treatment by Microscopic Inspection during Endodontic Microsurgery. *J Endod* 2011;37(11):1516-19.
- [6]. Trope M. Flare-up rate of single visit endodontics. *Int Endod J* 1991;24:24-27.
- [7]. Tasdemir T; Yildirim T; Çelik D. Comparative study of removal of current endodontic fillings. *J Endod* 2008;34(3): 326-9
- [8]. Tanomaru FILHO M; Yamashita JC; LeonardoMR et al. In vivo microbiological evaluation of the effect of biomechanical preparation of root canals using different irrigating solutions. *J Appl Oral Sci* 2008; 14(2):105-10.
- [9]. Seeman FS; Fagundes FS; Haragusiko et al. Endodontia mecanizada: a evolução dos sistemas rotatórios contínuos. *RSBO* 2009;6(3).
- [10]. Chandra A. Discuss the factors that affect the outcome of endodontic treatment. *Aust Endod J* 2009;35:98-107.
- [11]. Rios MA; Vilela AM; Cunha RS et al. Efficacy of 2 Reciprocating Systems Compared with a Rotary Retreatment System for Gutta-percha Removal. *J Endod* 2014;40:543-546.
- [12]. Fruchi LC; Ordinola-Zapata R; Cavenago BC et al. Efficacy of Reciprocating Instruments for Removing Filling Material in Curved Canals Obtured with a Single-cone Technique: A Micro-computed Tomographic Analysis. *J Endod* 2014; 40(7):1000-1004.
- [13]. Rossi-Fedele G; Ahmed HM. Assessment of Root Canal Filling Removal Effectiveness Using Micro-computed Tomography: A Systematic Review. *J Endod*. 2017; 43(4):520-526.
- [14]. AlvesFR. and Marceliano-AlvesF. and Sousa, JCN et al. Removal of Root Canal Fillings in Curved Canals Using Either Reciprocating Single- or Rotary Multi-instrument Systems and a Supplementary Step with the XP-Endo Finisher. *J Endod* 2016; 42(7):1114-1119.
- [15]. Crozeta, BM; Silva-SousaYT; Leoni, GB et al. Micro-Computed Tomography Study of Filling Material Removal from Oval-shaped Canals by Using Rotary, Reciprocating, and Adaptive Motion Systems. *J Endod*. 2016; 42(5):793-797.
- [16]. Özyürek T; Demiryürek Eo. Efficacy of Different Nickel-Titanium Instruments in Removing Gutta-percha during Root Canal Retreatment. *J Endod*. 2016; 42(4):646-649.
- [17]. Nevares G; De Albuquerque DS; Freire LG et al. Efficacy of ProTaper NEXT Compared with Reciproc in Removing Obturation Material from Severely Curved Root Canals: A Micro-Computed Tomography Study. *J Endod* 2016; 42(5):803-808.
- [18]. Martins MP; DuarteMAH; CavenagoBC et al. Effectiveness of the ProTaper Next and Reciproc Systems in Removing Root Canal Filling Material with Sonic or Ultrasonic Irrigation: A Micro-computed Tomographic Study. *J Endod*. 2017; 43(3):467-471.
- [19]. Zuolo AS; Mello JE; Cunha RS et al. Efficacy of reciprocating and rotary techniques for removing filling material during root canal retreatment. *Int Endod J* 2013;46(10):947-53.

Gilmar Correia "Computed Tomography evaluation of Root Canal Desobturation of Lower Human Incisors." *IOSR Journal of Dental and Medical Sciences (IOSR-JDMS)*, vol. 17, no. 8, 2018, pp 60-64.