

Morphometry of Vermiform Appendix: A Human Cadaveric study

Jagdish P¹, Ashoka RK²

¹. Dr. Prerna Jagdish, Assistant Professor, Department of Anatomy, KD Medical College, Mathura

². Dr. R. K. Ashoka, Professor & Head, Department of Anatomy, KD Medical College, Mathura

Corresponding Author – Dr R. K. Ashoka,

Date of Submission: 15-08-2018

Date Of Acceptance: 03-09-2018

I. Introduction:

Vermiform appendix is the only organ in the body that has no constant anatomical position. It is so named because of its worm like appearance. It is located in the lower right quadrant of the abdomen¹. Vermiform appendix is attached dorsomedially to the end of the caecum where all three taeniae converge. It is 2 to 15 cm long and lies often intraperitoneally retrocaecal (65%) or in the lesser pelvis (30%). The appendix is attached to the posterior abdominal wall by the mesoappendix. The vermiform appendix is attached dorsomedially to the end of the caecum where all three taeniae converge. It is 2 to 15 cm long and lies often intraperitoneally retrocaecal (65%) or in the lesser pelvis (30%). The appendix is attached to the posterior abdominal wall by the mesoappendix². The attachment of the base of appendix to the caecum remains constant. The tip of the 'worm' can be found in a retrocaecal, subcaecal, paracolic, pelvic, preileal and post ileal position. It is connected by a short mesoappendix. Mesoappendix is a triangular fold of peritoneum extending to the appendicular tip. It runs along the whole length of tube. The mesoappendix has a free border which carries the blood supply to the organ, by the appendicular artery, a branch from the ileocolic artery³. Variation in different positions of appendix is very important for surgeons and radiologist as it may be associated with the diagnosis uncertainty by virtue of its inflamed tip not reaching up to the average length and delay can lead to early perforation and gangrene. Acute appendicitis is mainly diagnosed by medical examination and clinical evaluation. There is no definitive diagnostic laboratory test or imaging. Knowing common position(s) of the appendix helps on-time diagnosis of acute appendicitis. Variable positions of the appendix may mislead physicians to make a wrong decision or diagnosis of other diseases. Delayed diagnosis of acute appendicitis may lead to its perforation and subsequent abscess or peritonitis. So, accurate information about the anatomical location of appendix can improve prognosis of the disease⁴.

Materials & Methods: The study was conducted on 40 cadavers in the Department of Anatomy KD Medical College, Mathura. The position of appendix was noted and further confirmed by the direction of the tip of the appendix. The length and external diameter of appendix was measured using thread and measuring scale.

II. Results:

Exposure of the abdominal cavity was done following the dissection steps of Cunningham's practical manual. The vermiform appendix was identified like a worm like structure seen evaginating from the caecal pouch and its position was noted. The commonest position encountered in the current study was Retrocaecal (45%). Others positions of vermiform appendix also seen were, Pelvic (22.5%), Mid-inguinal (20%), Pre-ileal (5%), Post-ileal (2.5%), Paracolic (2.5%) and Promonteric (2.5%). The average length and external diameter of vermiform appendix in female cadavers was found to be 61.72 and 5.743 mm respectively. The average length and external diameter of vermiform appendix in female cadavers was found to be 64.785 and 6.1675 mm respectively.

Table 1: Position of Vermiform Appendix

Position of Appendix	Number of Specimen	Percentage (%)
Mid-inguinal	08	20
Retrocaecal	18	45
Pelvic	09	22.5
Pre-ileal	02	5
Post-ileal	01	2.5
Paracolic	01	2.5
Promonteric	01	2.5

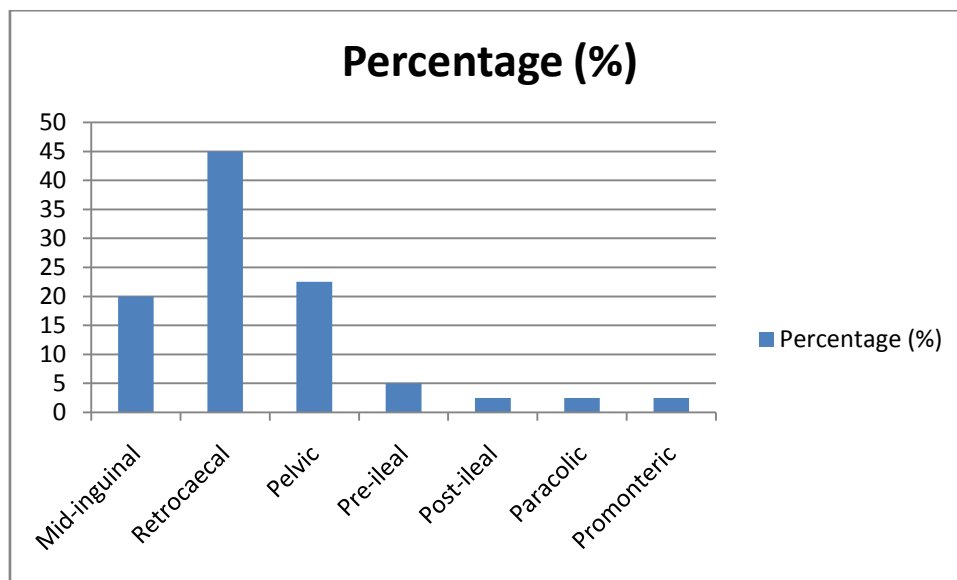


Table 2: Measurement of Vermiform Appendix in Female cadavers

S.No.	Length (mm)	External diameter (mm)
1	62.8	5.42
2	60.8	5.3
3	50.6	5.7
4	64.3	5.8
5	61.5	6.1
6	63.2	6.1
7	60	6
8	55	5.9
9	58.8	5.9
10	55	6
11	55.7	5.7
12	63.7	6.4
13	64.2	6.6
14	63.6	6
15	61.8	5.5
16	55	5.4
17	59.3	6
18	59.6	5.6
19	60	5.8
20	63	4.8
21	60	5.1
22	62.1	5
23	65	6.1
24	63	6.2
25	58.9	5.8
26	72	6.6
27	58.4	5.7
28	59.6	4.9

29	69.8	7
30	61	5.3
31	62.5	6
32	67.4	6
33	80	6.5
34	62.7	5.5
35	62.9	5.1
36	57.8	5
37	64	5.9
38	58	5.7
39	65.8	5.3
40	60	5
Mean	61.72	5.743

Table 3: Measurement of Vermiform Appendix in Male cadavers

S.No.	Length (mm)	External diameter (mm)
1	65.2	6
2	70.5	8
3	62.2	6.8
4	63	6.9
5	65	7
6	60.4	6
7	68.7	6.8
8	64	6.2
9	64	6
10	65.7	5.8
11	65.2	5.5
12	63.6	6.1
13	72	8
14	69	6.7
15	64	6.3
16	64.6	6
17	59.6	5.4
18	70	6
19	66	5.7
20	65.6	6
21	68	6.4
22	66	6
23	69	6
24	68	6.1
25	69.3	7
26	69.6	7
27	62	5.3

28	62	5.5
29	66	5.7
30	70	6.4
31	60	6
32	60.4	6
33	61.3	6
34	61	5.4
35	61	5.2
36	62	5
37	65	5
38	61	6.4
39	60	6.1
40	61.5	7
Mean	64.785	6.1675

III. Discussion:

Acute appendicitis, a surgical emergency, requires a detailed understanding of its presentation and diagnosis which is of crucial importance in its overall surgical management. The morbidity and mortality are related to the presenting stage of the disease and are substantially higher in cases of perforation.

The commonest position encountered in the current study was Retrocaecal (45%). Others positions of vermiform appendix also seen were, Pelvic (22.5%), Mid-inguinal (20%), Pre-ileal (5%), Post-ileal (2.5%), Paracolic (2.5%) and Promonteric (2.5%). Geethanjali et al studied 52 cadavers for variations in position and length of vermiform appendix and observed that pelvic position was commonest 36.52%, retrocaecal 32.69%, post ileal 11.53%, preileal 9.62%, subcaecal 5.77%, right paracolic 1.9%. The average length of appendix was found to be 6.47cms in males and 5.34cms in females⁵. In a study conducted by Patel et al, the variations in position of vermiform appendix were 64% retrocaecal, 30% pelvic, 4% post ileal and 2% subcaecal, pre ileal and paracolic varieties were not found⁶. This study was similar with the study of Uttam Kumar who also recorded the retrocaecal position as highest (65%) followed by pelvic (31.7%) and post ileal (3.3%)⁴. In a study undertaken by Golalipour, M. J, the pelvic position was the commonest position. He recorded that the incidence of pelvic position of appendix (33.3%) was the highest, accounting for 33.9% in males and 32.8% in females³. These results are similar to a study conducted by Katzurskj et al, in which the pelvic position was observed to be the commonest (43%)⁷.

In the current study, the average length and external diameter of vermiform appendix in female cadavers was found to be 61.72 and 5.743 mm respectively. The average length and external diameter of vermiform appendix in female cadavers was found to be 64.785 and 6.1675 mm respectively. Pooja et al found out in a study undertaken that the most common type of appendix was pelvic in position. The average length of appendix was found to be 75.02 mm in males and 63.27 mm in females and average diameter of appendix was noted to be 8 mm in males and 7.8 mm in females¹. In a study conducted by Setty et al, 33 male adult specimens showed the length of appendix varying from 45mm to 100mm with average length of 65.2mm and breadth at base was from 5mm to 10mm with average of breadth of 6mm. In 7 female specimens, the length of the appendix ranged from 55mm to 80mm with average length of 62.8mm and breadth at base was from 4mm to 7mm with average of breadth of 5.42mm⁸.

Knowledge of Anatomical Variation of different positions, shapes, location, parameters, dimensions of caecum and appendix is very important for surgeons to perform accurate operations. These parameters are alters depending upon race, sex, age and population, so the present observations in this study given the knowledge of morphometry of caecum and appendix in Indian population.

IV. Conclusion:

Meticulous knowledge of possible variations in positions of appendix is very important to surgeons for early valuable help in the management of appendicitis and prevention early perforation and gangrene of appendix. The commonest position encountered in the current study was Retrocaecal (45%). Others positions of vermiform appendix also seen were, Pelvic (22.5%), Mid-inguinal (20%), Pre-ileal (5%), Post-ileal (2.5%), Paracolic (2.5%) and Promonteric (2.5%). In the current study, the average length and external diameter of vermiform appendix in female cadavers was found to be 61.72 and 5.743 mm respectively. The average length

and external diameter of vermiform appendix in female cadavers was found to be 64.785 and 6.1675 mm respectively.

Acknowledgement:

We are grateful to Mr. Ram Ikbal Kushwaha, Sr. Technician, Department of Anatomy, for his technical assistance.

References:

- [1]. Garg P, Potaliya P, Dixit SG, Ghatak S, Saxena D. Journal of Research in Human Anatomy and Embryology. 2016; 2(2); 1-3.
- [2]. Susan Standing. Gray's Anatomy. Anatomical basis of clinical practice. 39th ed. Churchill Livingstone, 2005; 1189-1190.
- [3]. Golalipour, M. J.; Arya, B.; Azarhoosh, R; Jahanshahi, M. Anatomical variations of vermiform appendix in south –east caspion sea. J Anat. Soc. India .2003;52(2);141-143 .
- [4]. Uttam Kumar Paul¹, Humaira Naushaba², Tahmina Begum³, Md. Jahangir Alam⁴, Afshan Jesmin Alim⁵, Jesmin Akther⁶..Position of Vermiform Appendix: A Postmortem Study. Bangladesh Journal of Anatomy January 2009, Vol. 7 No. 1 pp;34-36.
- [5]. Geethanjali HT. A Study of variations in the position of vermiform appendix. Anatomica Karnataka. 2011;Vol 5(2):17-23.
- [6]. Patel S, Naik A. Anatomical variations in the position of vermiform appendix. IOSR Journal of Dental and Medical Sciences. 2016;15(4);106-109.
- [7]. Katzarski M, Dutta CR. The vermiform appendix in Ghananians. Ghana Med J 1971; (13). 4: 96-99.
- [8]. Setty SNRS, Katikireddi RS. Morphometric study of human cadaveric caecum and vermiform appendix. International Journal of Health Sciences & Research. 2013; 3(10); 48-55.

Jagdish P, Ashoka RK." Morphometry of Vermiform Appendix: A Human Cadaveric study."IOSR Journal of Dental and Medical Sciences (IOSR-JDMS), vol. 17, no. 8, 2018, pp 72-