

Stamp technique for posterior composite restorations-A case report.

Nishad SV¹ and Utsav Sharma²

Department of Conservative Dentistry and Endodontics, College of Dental Sciences, Davangere, Karnataka 577004.

Corresponding author – Nishad SV

Abstract

AIM

To introduce a new “Stamp” technique for placing a large composite restorations in class I cavity with buccal extension.

METHODS AND MATERIALS

Newer methods are developed with an intention to overcome the preceidious problems and to reduce the time required. Stamp technique is a novel method which helps in mimicking the original and natural occlusal topography of the teeth using composite restorations where the preoperative anatomy of the teeth is intact and not destroyed due to caries. Here, an occlusal matrix is fabricated from an unhindered occlusal surface of tooth with an intention to reproduce a precise tooth like restoration. Thus helps in obtaining the original contact and contour of the tooth with an accurate functional occlusion. Also the time required for finishing and polishing is minimized.

CONCLUSION

The stamp technique is a unique and biomimetic procedure to restore class I cavities with buccal extension by reproducing the exact anatomy of the tooth.

KEY LEARNING POINTS

Stamp technique, Composite resin, Class I restoration with buccal extension, Occlusal topography.

Date of Submission: 15-08-2018

Date Of Acceptance: 02-09-2018

I. Introduction

The era of amalgam is now replaced with more esthetically pleasing restorations. Since amalgam is having a lot of disadvantages including mercury toxicity and non-esthetic restoration, posterior composite resin restorations is a norm among modern dentistry today which is progressing towards an era of Bio-mimetic dentistry. Bio-mimetic literally translates to mimicking nature¹. Also the minimal invasive dentistry which is dependent on conservation of sound tooth structure is replacing the older principle of extension for prevention.

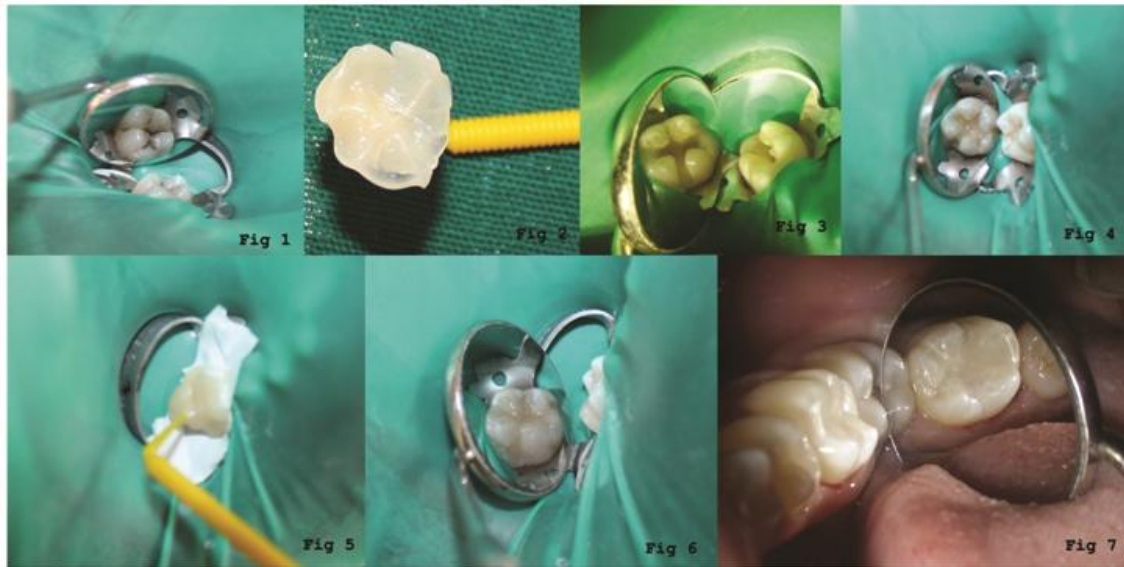
Although composite restorations have become popular among dentists, crafting an esthetic direct composite restoration manually requires experience and excellent operator’s dexterity. Direct restorations may be technique sensitive and not necessarily result in precise reproduction of tooth form and occlusion. Also the time needed for finishing and polishing of the restoration is double compared with the amalgam restoration². With the aim to achieve an amalgamation of function and esthetic, a newer technique that is Stamp technique was introduced by Dr. Waseem Riaz³.

This new technique of stamp includes fabrication of an index before the cavity preparation which can be considered as a negative replica or mini impression of the occlusal topography. It can be used in cases where there is no frank cavitation or tooth structure loss but caries evident radiographically. This index is later pressed against final composite increment before curing and its positive replica is obtained. The pre existing condition is mimicked with an advantage of reduced time required for removal of excess and polishing of restorations⁴.

II. Report

A 21 year old male patient reported to the clinic with a complaint of black stains on his lower right back tooth region. Clinically occlusal caries with buccal pit involvement was detected without gross destruction of 46 after thorough examination (fig 1). The extent of caries was determined by intraoral periapical radiograph. There was no involvement of marginal ridge. The tooth was isolated with rubber dam followed by application of separating medium (Zartex, Zarir & Zaida Industries, Malaysia) on the tooth surface using a brush. A stamp was made with application of flowable composite (Ivoclar Tetric N-Flow) on the intact occlusal and buccal surface of tooth (fig 2). A tip of microbrush was cut which acted as handle and immersed into composite followed by

polymerization through light curing for making the stamp. Carious lesion was removed completely and a class I with buccal extension cavity was prepared (fig 3). Glass ionomer (GC Fuji Lining LC, GC America Inc.) was used as a cavity lining (fig 4). Etching was done using 37% orthophosphoric acid (Tetric N Etch Ivoclar vivadent) for 30 seconds followed by rinsing and air dried using 3-way syringe. Later bonding agent (Tetric N Bond, Ivoclar vivadent) was applied and light cured for 20 seconds. Incremental restoration of composite (Tetric N ceram, Ivoclar vivadent) was done in the cavity upto 1mm lower the occlusal surface and light curing for 20 seconds. The last layer of composite was added and before curing, a piece of Teflon tape was laid on the occlusal and buccal surface. Then the microbrush occlusal stamp was sealed in place over the tape (fig 5) and later it was removed. The excess material was removed and polymerization of composite was done (fig 6). Minimal finishing and polishing was done using Soflex Spiral Wheel (3M-ESPE) (fig 7).



III. Discussion

The ultimate goal of any restoration is to restore the normal form and function which will also promote patient's compliance and acceptance towards dental treatment. This case helps in achieving the above goal and maintains a harmonious cusp fossa relation to the antagonist and adjacent teeth. This technique is indicated in conditions where the tooth structure is intact and caries beneath (class I and class II). To reduce microleakage of composite resin, LC GIC was used as a liner material⁵. Alternative to Teflon tape can be use of cling film which does not requires removal while curing. It also protects composite material from being exposed to ambient light multiple times⁶.

The main advantage of this technique is perhaps, once mastered, requires reduced overall time because of instant desired cusp fossa relation. This is a boon for the practitioners and helps improve their reputation amongst patients⁷. Also the degree of porosities present in final restoration is considerably reduced. Its because of the fact that pressure is exerted by stamp matrix on the composite, thereby decreasing formation of microbubbles as well as interference of oxygen with polymerization of the final layer of composites⁸. These factors have been shown to be major determinants for long term success of composites⁹.

While the disadvantage of the technique is that it requires skill and clinical acumen in order to be correctly performed. Also the technique is cost effective since it requires microbrush and flowable composite as they are expensive. To overcome this cons, expired flowable composite or transparent acrylic resin can be used¹⁰.

IV. Conclusion

The stamp technique is a unique and biomimetic procedure to restore class I with buccal extension given the operator is skillful. The precision and accuracy of occlusal topography is much better than the manual method with an added advantage of reduced overall time for post restoration adjustments.

Conflict of interest: None

References

- [1]. Alexey Murrashkin. Direct posterior composite restorations using stamp technique-conventional and modified: A case series. *IJDR* 2017; 2:3-7.
- [2]. Diley DC, Vann WF Jr., Oldenburg TR, Crisp RM. Time required for placement of composite versus amalgam restorations. *ASDC J Dent Child* 1990; 57:177-83.
- [3]. Geena Mary, Ambily Jayadevan. Microbrush stamp technique to achieve occlusal topography for composite resin restorations- A Technical Report. *Journal of Scientific Dentistry* 2016; 6:76-82.
- [4]. Jose Guilherme Ferrer Pompeu, Rhoana Coelho Morais. Occlusal stamp technique for direct resin composite restoration: A Clinical Case Report. *International Journal of Recent Scientific Research* 2016; 7:12427-30.
- [5]. Gary Alex. The use of resin modified glass ionomer liners under composite resins: should they be used to help control microleakage? *Inside Dentistry* 2005 1.
- [6]. Neha Joshi Tambake, Sumit Tambake, Neha Gandhi, Yogesh Jadhav, Kumari Madhu, Pratik Burad Stamp technique- New perspective of aesthetic dentistry: A Case report. *IOSR Journal of Dental and Medical Sciences* 2017; 16:49-51.
- [7]. Alshehadat SA, Halim MS, Carmen, Fung CS The stamp technique for direct class II composite restorations: A case series. *J Conserv Dent* 2016; 19:490-3.
- [8]. Pompeu JGF, Morais RC, Ferreira TO, et al. Occlusal stamp technique for direct resin composite restoration: A clinical case report. *Int J Recent Sci Res.*2016; 7:12427-30.
- [9]. Hamilton JC, Krestik KE, Dennison JB. Evaluation of custom occlusal matrix technique for posterior light cured composites. *Oper Dent* 1998; 23:303-07.
- [10]. Liebenberg WH. Occlusal index-assisted restitution of esthetic and functional anatomy in direct tooth colored restorations. *Quintessence Int* 1996; 27:81-88.

Sonal Nishad. " Stamp technique for posterior composite restorations-A case report..."*IOSR Journal of Dental and Medical Sciences (IOSR-JDMS)*, vol. 17, no. 8, 2018, pp 13-15.