

A rare case of *Penicillium Marneffe* infection in an HIV infected individual with Immune Reconstitution Inflammatory Syndrome (IRIS) along with possible penicillium meningitis in the Northeast Indian state of Manipur: A case report

Ugen Gyatso N. Bhutia, Kshetrimayum Silpa, Banteilang Challam,
Dhanaraj Singh Chongtham

Corresponding Author: Ugen Gyatso N. Bhutia

Abstract: *Penicillium marneffe* is a dimorphic fungus that is endemic to Southeast Asia & the Northeast Indian state of Manipur. Manipur is one of the six high HIV prevalence states in India. We report a rare case of newly diagnosed HIV patient who was started on antiretroviral therapy & later on developed Immune Reconstitution Inflammatory Syndrome (IRIS) with penicilliosis as well. Patient also developed meningitis during his hospital stay & investigations for the same turned out to be negative for commonly tested opportunistic infections. The possibility of penicillium meningitis was taken into account. The clinical presentation & preliminary cerebrospinal fluid findings resembled those of penicillium meningitis cases studied elsewhere. Further definitive investigations could not be undertaken as the patient's condition deteriorated & the patient eventually expired. This case report aims at stressing the need to take into account the possibility of penicillium infections of the nervous system, which are not seen commonly.

Key words: *Penicillium marneffe*, HIV, IRIS, ART

Date of Submission: 14-08-2018

Date Of Acceptance: 30-08-2018

I. Introduction

Penicillium marneffe is the only penicillium species that is a dimorphic fungus. It causes systemic mycosis in human beings.(1)It is endemic in Southeast Asia especially Thailand, Myanmar, Vietnam, Laos, Malaysia & Southern China.(2) It has also been reported from the Northeast Indian state of Manipur, which shares a border with Myanmar.(3) Penicilliosis happens to be the presenting AIDS-defining illness in 6.8% of HIV infected patients from endemic areas & is seen to occur with CD4count <100/mm³.(4,5)The clinical manifestations include classical generalized papules or nodules with central umbilication, in addition to fever, hepatosplenomegaly, lymphadenopathy, fatigue, weightloss, anaemia, dyspnea etc.(6) Poor outcomes have been observed in the absence of timely & appropriate management.(7)

Immune reconstitution inflammatory syndrome (IRIS) may occur after initiating antiretroviral therapy (ART) & manifests as a paradoxical exacerbation of previously treated opportunistic infections (paradoxical or worsening IRIS) or as an unmasking of subclinical and untreated infections (unmasking IRIS).(8) To our knowledge, there has been no reported case of penicillium meningitis from India. We report a rare case of a newly diagnosed HIV patient who developed IRIS after initiation of ART & developed penicilliosis with meningitis, whose clinical presentation & laboratory investigations bore marked resemblance with those of 21 cases of penicillium meningitis who were studied in Vietnam.(9)

II. Case Report

A 45 year old was evaluated following complains of fatigue and decreased appetite for 3 weeks. He was diagnosed to be HIV positive with CD4 count of 17/mm³.He was initiated on anti-retroviral therapy with Lamivudine, Tenofovir and Efavirenz along with prophylaxis for pneumocystis jiroveci pneumonia after completion of baseline investigations, which happened to be normal. Two weeks later, he was brought to our hospital after he developed fever (evening rise),night sweats,headache,decreased urine output along with generalized papules with central umbilications (some of which were necrotic) on the face, trunk, upper and lower limbs.[Figure 1] Examination revealed neck rigidity. Kernig's sign was absent. The patient developed altered sensorium on the next day.

Investigations revealed pancytopenia with haemoglobin concentration of 6.4g/dL (normocytic normochromic), white blood cell count of 3500/mm³, platelet count of 90000/mm³ and ESR of 90mm/1st hour. The concentrations of serum urea - 86 mg%, serum creatinine - 2.1 mg%, SGOT - 403 units/L, SGPT -123

units/L and serum potassium – 2.7 meq/L. Total bilirubin was normal at the time of admission and increased later to 5.3mg/dL. The patient's haematological, renal and hepatic parameters were seen to be considerably deranged as compared to the pre-ART period. VDRL and Mantoux test were negative. Chest X-ray did not reveal any abnormality. MRI brain showed mild cerebral atrophy. Skin biopsy was done and histopathological examination revealed yeast forms of a fungus, few of which were dividing by binary fission and diagnosed as penicilliosis. [Figure 2]

CSF analysis revealed presence of coagulum, total protein of 113mg/dL, sugar of 66 mg/dL, total cell count of 8/mm³ with 100% lymphocytes and ADA was normal. It was negative for AFB, India Ink preparation, cryptococcal antigen, herpes simplex virus antibodies and toxoplasma antibodies. It was positive for CMV IgG antibody. Ultrasound of the abdomen revealed hepatosplenomegaly and normal corticomedullary differentiation of both the kidneys. Blood culture did not identify any pathogenic organism.

The patient was initiated on anti-tubercular therapy without rifampicin along with switching over to second line ART drugs, after necessary dose adjustments in view of creatinine clearance of 35 ml/min. He was also administered liposomal amphotericin B after necessary dose adjustments. However, the patient condition continued to deteriorate and he died 7 days later.

III. Discussion

Penicilliosis has a reported incidence of 25% amongst HIV-infected patients in Manipur state. Human beings and bamboo rats are the only known animal hosts of *penicillium marneffeii*. Bamboo grooves in the immediate vicinity of human dwellings in Manipur along with consumption of raw & fermented bamboo shoots on regular basis by the people explains the increased incidence in Manipur. [3] The patient had a history of intravenous drug abuse in the past and was found to have a very low CD4 count at the time of diagnosis, which in turn has been found to adversely affect life expectancy & prognosis. [10]

Initiation of antiretroviral therapy with very low CD4 counts is associated with the risk of developing IRIS, as was seen in this case. *Penicillium marneffeii* infection manifesting as IRIS in HIV-infected individuals has also been reported earlier. [11] The patient also developed acute kidney injury, which could be attributed to tenofovir. [12] CSF analysis was done to evaluate the cause of meningitis. ATT was started empirically in view of TB being the most common cause of CNS infection in HIV-infected individuals in the country. [13] However the patient's condition continued to deteriorate & the possibility of fungal meningitis was considered.

In a case series of 21 HIV-infected patients of *penicillium marneffeii* meningitis in Vietnam a few years ago, it was noticed that the CSF of only 7 patients revealed pleocytosis & 71% patients showed high protein levels, with glucose levels being either normal or slightly reduced. 17 of the above 21 patients died eventually. Our patient's CSF did not reveal pleocytosis, showed high protein content & normal glucose levels. Owing to the patient's deteriorating condition and unwillingness of the relatives to perform further investigations, repeat examination of CSF for fungal culture could not be done. [9] Our differentials also include tuberculosis & histoplasmosis.

IV. Conclusion

IRIS is seen to occur most commonly in the setting of tuberculosis. However, in endemic areas, penicilliosis can also manifest as IRIS. In addition to routine testing for common opportunistic infections of the nervous system in HIV- infected individuals, it would be worthwhile to consider the possibility of *penicillium marneffeii* meningitis as well and proceed with CSF fungal culture so as to identify cases and initiate appropriate therapy, which may eventually benefit the patient. Regular follow-up for IRIS & compliance of patients to ART need to be ensured. Our case also highlights the need to continue pursuing rigorous awareness programmes so that potentially infected people can be detected and started on treatment earlier, thereby reducing morbidity and mortality in addition to improving the quality of lives of the patients and their families.

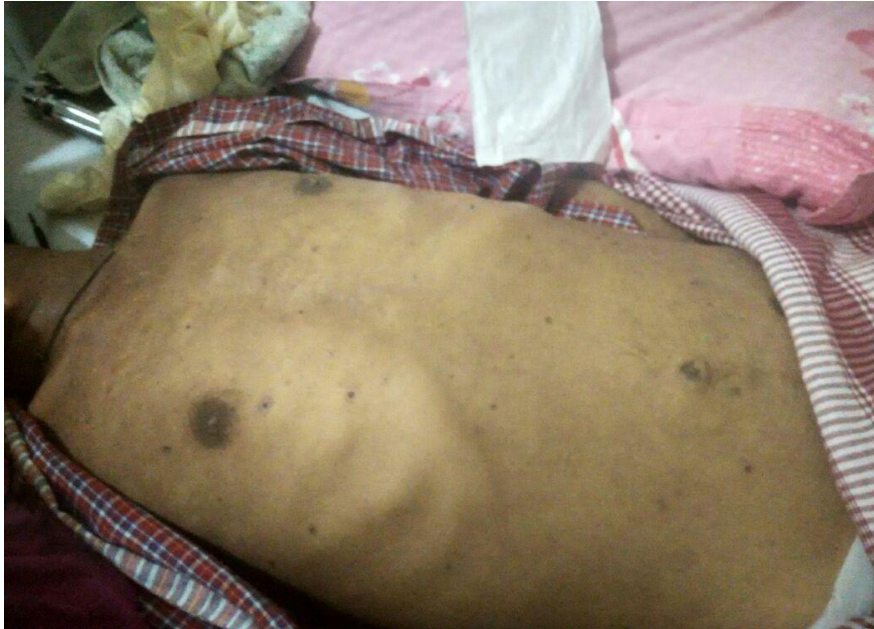

Figure 1

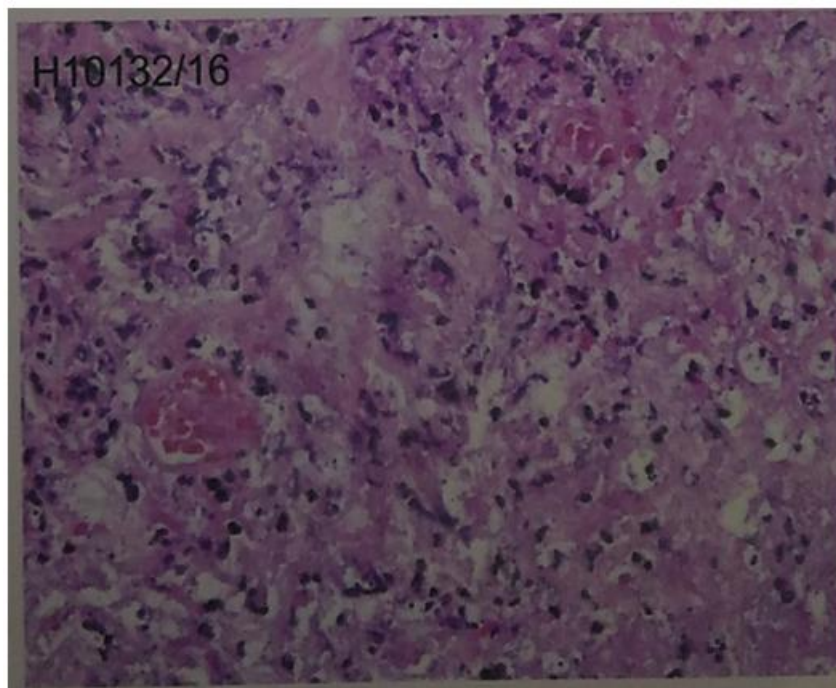


Figure 2

References

- [1]. Wartman PD. Infection with *Penicillium marneffeii*. *Int J Dermatol*. 1996;35:6.
- [2]. Sirisanthana T, Supparatpinyo K. Epidemiology and management of penicilliosis in human immunodeficiency virus-infected patients. *International journal of infectious diseases*. 1998 Jul 1;3(1):48-53.
- [3]. Ranjana KH, Priyokumar K, Singh TJ, Gupta CC, Sharmila L, Singh PN, Chakrabarti A. Disseminated *Penicillium marneffeii* infection among HIV-infected patients in Manipur state, India. *Journal of infection*. 2002 Nov 1;45(4):268-71.
- [4]. Chariyalertsak S, Sirisanthana T, Saengwonloey O, Nelson KE. Clinical presentation and risk behaviors of patients with acquired immunodeficiency syndrome in Thailand, 1994–1998: regional variation and temporal trends. *Clinical infectious diseases*. 2001 Mar 15;32(6):955-62.
- [5]. Supparatpinyo K, Chiewchanvit S, Hirunsri P, Uthammachai C, Nelson KE, Sirisanthana T. *Penicillium marneffeii* infection in patients infected with human immunodeficiency virus. *Clinical infectious diseases*. 1992 Apr 1;14(4):871-4.
- [6]. Deesomchok A, Tanprawate S. A 12-case series of *Penicillium marneffeii* pneumonia. *JOURNAL-MEDICAL ASSOCIATION OF THAILAND*. 2006 Apr 16;89(4):441.
- [7]. Supparatpinyo K, Khamwan C, Baosoung V, Sirisanthana T, Nelson KE. Disseminated *Penicillium marneffeii* infection in southeast Asia. *The Lancet*. 1994 Jul 9;344(8915):110-3.

- [8]. French MA, Price P, Stone SF. Immune restoration disease after antiretroviral therapy. *Aids*. 2004 Aug 20;18(12):1615-27.
- [9]. Le T, Huu Chi N, Kim Cuc NT, Sieu TP, Shikuma CM, Farrar J, Day JN. AIDS-associated *Penicillium marneffeii* infection of the central nervous system. *Clinical infectious diseases*. 2010 Dec 15;51(12):1458-62.
- [10]. May M, Gompels M, Delpech V, Porter K, Post F, Johnson M, Dunn D, Palfreeman A, Gilson R, Gazzard B, Hill T. Impact of late diagnosis and treatment on life expectancy in people with HIV-1: UK Collaborative HIV Cohort (UK CHIC) Study. *Bmj*. 2011 Oct 11;343:d6016.
- [11]. Nizami AI, kumar Rama S, Biradar CI, Akambadiyar R, Chakraborty D, Handique F. *Penicillium marneffeii* infection manifesting as immune reconstitution inflammatory syndrome (IRIS) in HIV Infected soldier on HAART. *Journal of Medical and Dental Science Research*. 2016;3(3):09-13.
- [12]. Patel SM, Zembower TR, Palella F, Kanwar YS, Ahya SN. Early onset of tenofovir-induced renal failure: case report and review of the literature. *The scientific world journal*. 2007;7:1140-8.
- [13]. Sharma SR, Hussain M, Habung H. Neurological manifestations of HIV-AIDS at a tertiary care institute in North Eastern India. *Neurology India*. 2017 Jan 1;65(1):64.

Ugen Gyatso N. Bhutia. " A rare case of *Penicillium Marneffeii* infection in an HIV infected individual with Immune Reconstitution Inflammatory Syndrome (IRIS) along with possible *penicillium meningitis* in the Northeast Indian state of Manipur: A case report.."IOSR Journal of Dental and Medical Sciences (IOSR-JDMS), vol. 17, no. 8, 2018, pp 72-75.