

Utilizing the Neutral Zone: Concept and Technique for Stabilizing Complete Denture - Case Report

Dr Anil Kumar^{1*}, Dr. Nilmani Paswan², Dr. Surendra Prasad³, Dr. Neeta Sinha⁴,
Dr. Sarita Singh⁵, Dr. Rakhi Kumari⁶, Dr. Ankitha Priya⁷

¹Associate Professor, Department Of General Surgery (Trauma & Emergency), All India Institute Of Medical Sciences, Patna.

²Senior Resident, General Surgery, AIIMS, Patna.

³Professor & H.O.D, Department Of Prosthodontics, Buddha Institute Of Dental Sciences, Patna.

⁴Professor, Department Of Prosthodontics, Buddha Institute Of Dental Sciences, Patna

⁵Senior Lecturer, Department Of Prosthodontics, Buddha Institute Of Dental Sciences, Patna.

⁶Post Graduate Trainee, Buddha Institute Of Dental Sciences, Patna.

⁷Post Graduate Trainee, Department Of Prosthodontics, Buddha Institute Of Dental Sciences, Patna.

Corresponding author: Dr Anil Kumar

Abstract: Resorption of mandibular ridges is a multifactorial and biomechanical disease that is chronic, progressive, irreversible, and cumulative leading to loss of sulcular depth, vertical dimension loss, and decreased lower facial height. Some common neurological, hormonal, and metabolic disorders affect the adaptability of dentures, and this can be diagnosed by a trained prosthodontist with proper history-taking and clinical examination. The denture becomes passive due to complex neuromuscular control and causes difficulties in impression-making, mastication, and swallowing, which in turn leads to loss of retention and stability in complete dentures. Hence, residual ridge resorption becomes a challenging scenario for a clinician during fabrication of complete dentures. The neutral zone concept plays a significant role in overcoming these challenges. The neutral zone is the area where the outward forces from the tongue are neutralized or nullified by the forces of the lips and cheeks acting inward during functional movements. The neutral zone technique is an alternative approach for the construction of lower complete dentures. The technique aims to construct a denture that is shaped by muscle function and is in harmony with the surrounding oral structures.

Keywords: Prosthodontic Rehabilitation, Neutral Zone, Impression Technique

Date of Submission: 12-08-2018

Date Of Acceptance: 29-08-2018

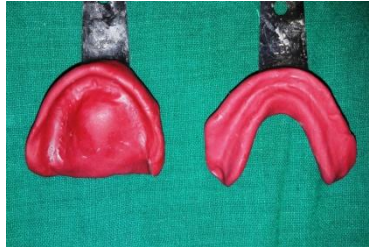I. Introduction

The major goals of providing complete denture prosthesis to an edentulous patient include the provision of functionally aesthetic substitutes and the replacement of associated structures within the oral cavity. The complete dentures should use the spaces available and redefine the retention. When it is achieved, the complete denture prosthesis occupies substantial volume in the oral cavity. As the area of the impression surface decreases due to alveolar ridge resorption, less influence it has on the denture retention and stability. Retention and stability of the complete denture becomes perfect after positioning of the teeth and polished surface of the dentures. Therefore these surfaces should be so contoured that horizontally directed forces applied by the perid denture muscles should act to seat the denture in this well balanced muscular space². This space is known as neutral zone.

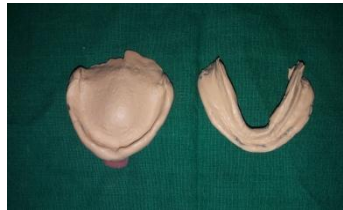Case Report

A 58 year aged female patient reported with complete edentulous maxillary and mandibular arches. She wanted replacement of the same. On clinician examination it was found that maxillary and mandibular arches severely resorbed.

The diagnostic impression were made with the help of impression compound and cast poured with dental plaster. On the diagnostic cast custom tray was made.



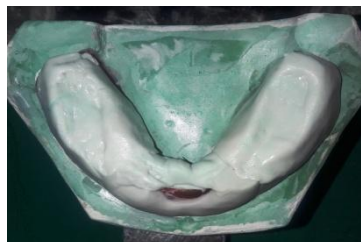
Secondary impression was made on custom tray with zinc oxide eugenol impression material. While making secondary impression the patient was asked to do all the functional movements. This impression was poured with dental stone.



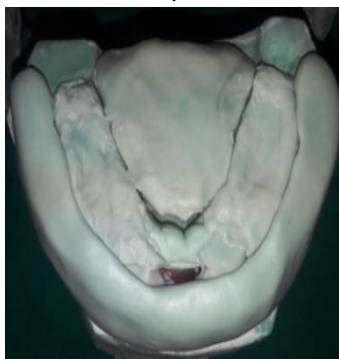
The record bases were fabricated with modelling wax and tentative jaw relation was recorded and mounted, which helped in maintaining the vertical jaw relation.



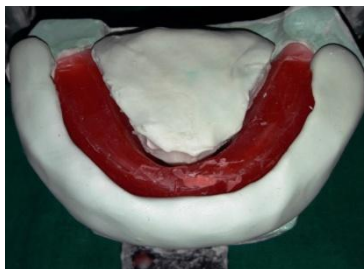
With the help of elastomeric impression material neutral zone was recorded. This impression material was placed in patients mouth and the functional and physiological movements like swallowing, sucking, pursing lips, sipping water, pronouncing vowels and protruding tongue several several times. During these movements the muscles of lips, cheeks, and the tongue, exerted forces on the impression material which molds it. The vertical height was adjusted and the procedure was repeated several times. Once the neutral zone was recorded on the impression it was placed on the master cast.



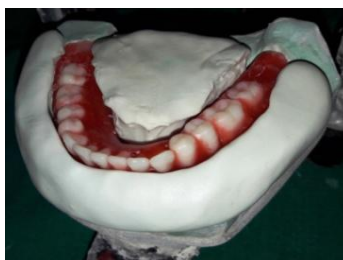With the help of elastomeric impression material the index was made of the neutral zone



Wax occlusal rim was replaced and with the help of index which helped to provide the neutral zone space the teeth arrangement was carried .



The position of the teeth was checked by placing the index together back on the master cast and wax up was done for the trial in patient's mouth. Once the trial denture was ready, then it was checked in the patient's mouth for occlusion, aesthetics, phonetics and function.



II. Discussion

The main goal of prosthodontic treatment is to restore the function and aesthetics. Complete denture is influenced by not only the ridge but also by the surrounding oral cavity, occlusion, biting forces and many others.

Fish pointed that out of the three surfaces of the denture the polished surface is bounded by the tongue and the cheeks. These are involved in normal physiologic movements such as speech, mastication, swallowing, smiling, and laughing. Complete denture must be fabricated with function because physiologically unacceptable denture will have poor prosthesis stability and retention, insufficient tissue support and compromised phonetics.

Wright and associates pointed out that the borderseal area for the mandibular denture extends downward to the floor of the mouth and posteriorly into the lateral throat form. Rinaldi and Sharry refer to a study that indicated that the tongues of aged persons showed no atrophic tendencies, which is not true of other tissues. It is advantageous to record the positions of the tongue during sucking, swallowing, and movement.

A thorough understanding of the anatomy and physiology of structures can help the Clinicians to attain complete denture without any discomfort and without wasting any extra clinical sitting to obtain neutral zone that impact prosthesis stability.

III. Conclusion

The neutral zone for complete denture fabrication utilizes the surrounding oral tissues, as an advantage to stabilize the denture. Retention and stability of dentures has been greatly improved. When implant overdenture therapy is not the treatment option, the neutral zone technique is of great help. Using the modern technique that are being developing like the CAD/CAM and virtual registration and option of the tooth positions and denture base contours the limitations of natural zone technique can be met. This technique may be incorporated in regular prosthodontic treatment of edentulous patients.

References

- [1]. Haroon R, Fahim A V, Tasneem Z H, Geeta D K Stabilizing mandibular complete dentures using the neutral zone impression technique. J Pak Dent Assoc 2013(2)154-159 May 2013
- [2]. Chandni J, Roshni G, Prince K, Harkanwal P S. Neutral Zone approach for severely atrophic ridges;Avenues beyond implants and surgeries – A Case Report International Journal Of Clinical Dental Science, Vol 2, No 3 (2011)
- [3]. Lott F, Levin B. Flange technique, an anatomic and physiologic approach to increased retention, function, comfort, and appearance of denture. J Prosthet Dent 1996;16:394-413
- [4]. Opinder PS, Ravneet K, Sonia MN: Residual ridge resorption: A major oral disease entity inrelation to bone density. Indian J Oral Sci. 2016, 7:3-6. 10.4103/0976-6944.176383
- [5]. Jacobson TE, Krol AJ: A contemporary review of the factors involved in complete dentures. Part II: stability. J Prosthet Dent. 1983, 49:165-72.
- [6]. Gahan MJ, Walmsley AD : The neutral zone impression revisited . Br Dent J. 2005, 198:269-72.
- [7]. Kursoglu P, Ari N, Calikkocaoglu S: Using tissue conditioner material in neutral zonetechnique. N Y State Dent J. 2007, 73:40-2.
- [8]. Patil V, Hallikerimath RB, Magadum S: Enhancement of stability for mandibular completedenture prosthesis in atrophied ridge with neutral zone technique-A case report.. J Adv OralRes. 2011, 2:73-6.
- [9]. Agarwal S, Gangadhar P, Ahmad N, Bharadwaj A: A simplified approach for recording neutralzone. J Indian Prosthodont Soc. 2010, 10:102-04. 10.1007/s13191-010-0019-82017

Dr. Ankita Priya " Utilizing the Neutral Zone: Concept and Technique for Stabilizing Complete Denture - Case Report."IOSR Journal of Dental and Medical Sciences (IOSR-JDMS), vol. 17, no. 8, 2018, pp 26-29.