

Osteoma involving Condyle and mandible: Case reports and review of literature

Dr. Mukund Gupta¹, Dr. Nupur Gogia Reader², Dr. Abhay T. Kamath³, Dr. Rakesh Sharma⁴

¹Reader, Department of Oral and Maxillofacial Surgery KDCRC, Moradabad, U.P., India

²Reader, Department of Oral Medicine and Radiology, KDCRC, Moradabad, U.P., India

³Prof & HOD, Department of Oral and Maxillofacial Surgery, MCOCS, Manipal

⁴Ass. Prof, Oral and Maxillofacial Surgery, LHMC

Corresponding Author: Dr. Mukund Gupta

Date of Submission: 29-06-2018

Date of acceptance: 14-07-2018

I. Introduction

Osteomas considered by many as benign tumors and by others as only a reactionary response of body to chronic irritation or trauma via formation of mature bones at sub- periosteal or endosteal locations^{1,2}, are relatively common in the jaws but fairly uncommon in the condylar region³. They may occur as part of Gardner syndrome wherein they are multiple in number and associated with multiple intestinal polyposis⁴. Multiple Osteomas may prove to be the first sign of Gardner syndrome and hence warrant thorough assessment of the patient.

This article describes a patient with isolated osteoma involving the left condyle of mandible associated with stretching and dull aching pain and another with isolated osteoma of left body of mandible region associated with decayed lower left first molar.

Case 1

A 28 year old female patient reported with complains of dull aching pain associated with stretching sensation in front of her left ear for the past one and half to two years. For the past six months she had noticed a bony hard swelling in front of her left ear. There was an occasion when she had developed mild restriction in jaw movement because of the feeling of stretch from the same region. The patient did moist heat fermentation and took analgesics which relieved her of the symptoms but she continued to notice bony hard growth in the same region. Thorough clinical examination revealed an isolated, non-tender bony hard swelling approx 1 X 1.5 cm involving the lateral aspect of the left condyle with normal overlying skin and range of mandibular movement. Orthopantomogram revealed a more radio-opaque left condyle compared to the right side. A 3D reconstruction view of the left condyle revealed an enlarged lateral segment of left condyle with normal appearing bone. The patient was taken for surgery - open excisional biopsy under general anaesthesia. An Alkayat and Bramley incision was used followed by dissection in layers to expose the left lateral condylar growth. The medial extent of the growth was marked via the postage stamp technique with 701 bur followed by sequential osteotomy to retrieve the enlarged growth in total. The specimen was sent for histopathological analysis which revealed compact trabecular bone with multiple areas of calcification consistent with an osteoma. An endoscopic examination of the colon was done to rule out intestinal polyps (Gardner syndrome). There was no evidence of any other osteoma in the body.

Case 2

A 41 year old female patient reported with complains of severe pain from her lower left back tooth for past 2 to 3 days. On examination a grossly decayed lower left first molar was seen. An associated bony hard tent like swelling, well demarcated approx 1.5cm in size was palpated along the lower third of left body of mandible region along the first molar region. An orthopantomogram revealed well defined approx 5mm diameter radio opacity in relation to the peri apex of lower left 1 molar. Lower occlusal view showed a tent like radio opaque growth in the region of lower left first molar approx 1 cm in length. The patient was taken up for surgery under local anaesthesia. A crevicular incision was given from 34 to distal aspect of 37 with anterior release incision. Full thickness muco- periosteal flap was raised and swelling was identified. Her lower first molar was extracted followed by removal of the growth along the buccal cortical margins. Entire growth was removed and sent for histopathological examination. Histopathological findings were consistent with cortico- cancellous osteoma.

Patient was not willing for any further endoscopic examination , so she was only evaluated for presence of any other site with osteoma involvement.

II. Discussion -

Osteomas are considered to be benign tumors or reactive bony growths secondary to chronic infection. Whatever may be the aetiology osteomas are generally made up of varying amounts of mature compact and cancellous bone. Osteomas rarely involve the mandibular condyle with a total of less than 100 reported in literature. Osteomas can be of periosteal variety originating just below the periosteum covering the cortex , sessile or pedunculated or they can be medullary , resting within the medullary bone. Both our patients showed periosteal sessile variety.⁵Osteomas are generally asymptomatic however when large enough they can present with symptoms associated with compression of surrounding vital structures e.g. Compression of inferior alveolar nerve due to the growth may lead to paresthesia along the course of the nerve or may hinder with the functioning due to anatomical obstruction . Large osteomas of face may also present aesthetic concerns for the patient. Radiologically osteomas appear as well defined radio opaque lesions with sclerotic margins . However during the early formation they may appear as mixed radio-lucent and radio opaque lesions with varying degrees of ossification can be seen. the radiographic appearance of osteomas make them extremely difficult to differentiate them from bony exostosis , osteoblastoma , osteo-chondromas , ossifying fibromas.^{6,7}

The exact aetiology of osteomas is not known. It is considered as a reactive response to functional muscular demand or chronic irritation as documented by Kaplan et al . Many however categorise them as true neoplasm or hamartomas.

Osteomas of the condyle are very rare and were first reported by Ivy in 1927⁹. Based on the exact location of the osteomas within the condyle/ temporomandibular joint , there could be a plethora of symptoms. Osteomas growing on the superior aspect of the condyle can lead to early deviation in the jaw both at rest and during motion towards the un- involved side. Later they may be associated with painful jaw movement and occlusal problems . Osteomas on the lateral aspect of condyle do not generally cause significant pain or altered occlusion⁶. However they are visible fairly early as a pre auricular swelling and can have significant aesthetic compromise for the patient.Osteomas in the condylar region can be classified into two types 1) Replacement type wherein the osteoma replaces the actual condyle within the tmj 2) Additive type where the osteoma presents as a sessile or pedunculated mass attached to the actual condyle. Replacement osteoma warrant condylectomy. additive ones can be managed via simple excision.

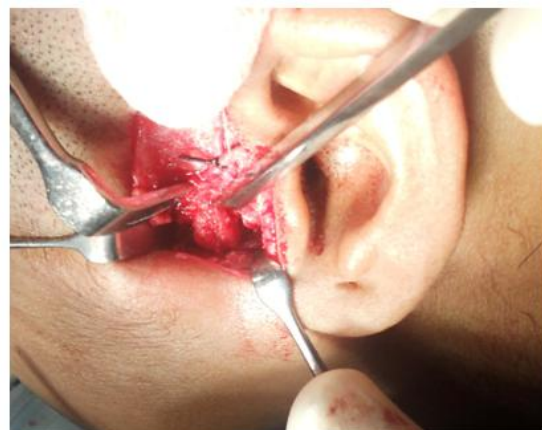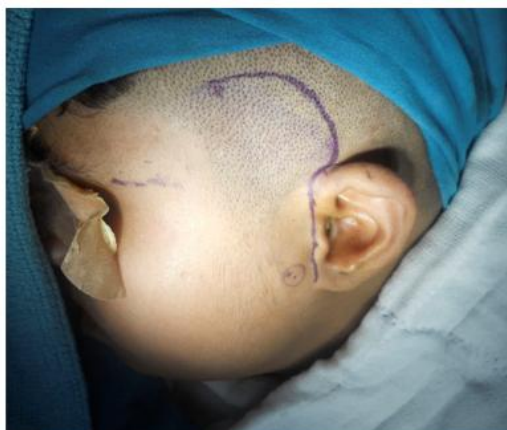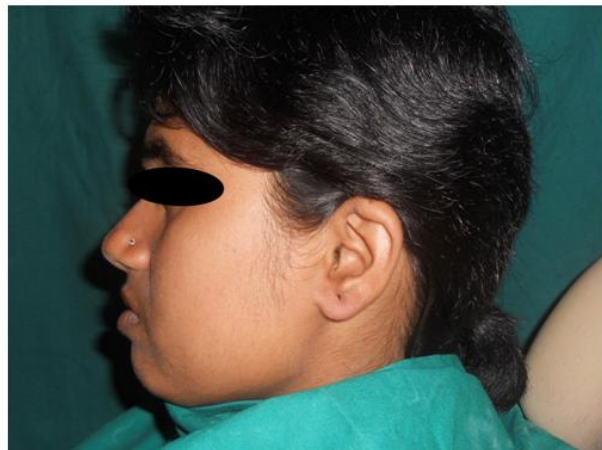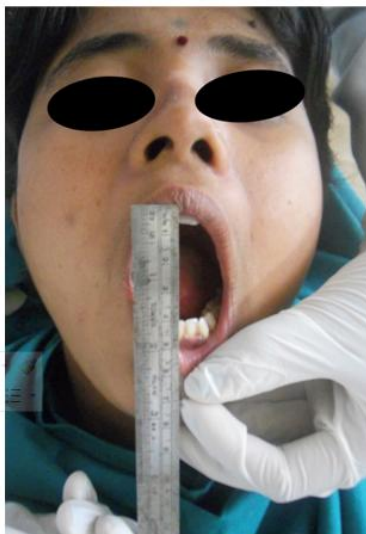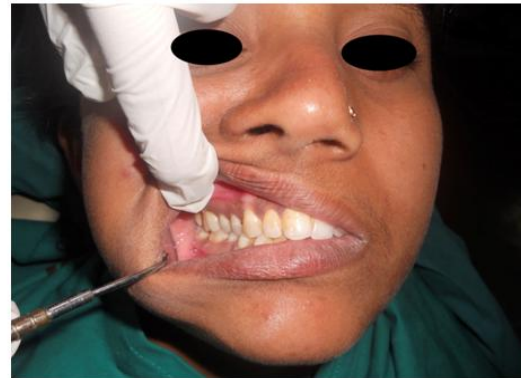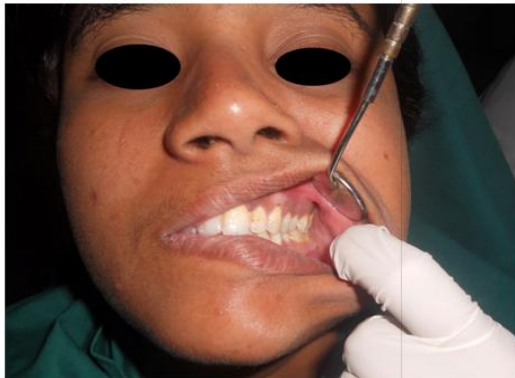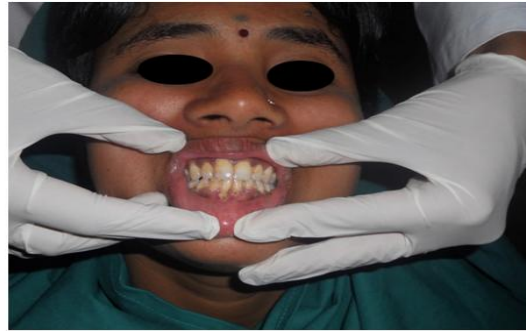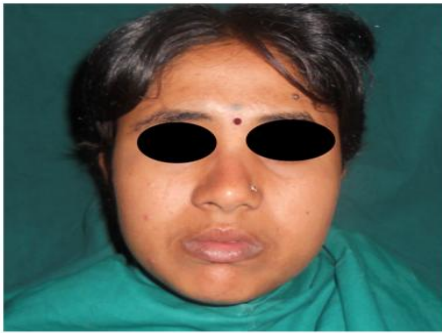Gardner syndrome is caused by a mutation of the APC gene on chromosome 5 (5q21), has an early onset, and has to gender predilection , is an autosomal dominant type of intestinal polyposis associated with multiple osteomas in the body.Thyroid carcinoma, hypertrophy of the pigmented epithelium of the retina, epidermoid cyst, fibromas,sebaceous cyst, desmoid tumors etc may all or in parts be associated with Gardner syndrome and hence require comprehensive examination of all the above symptoms in a patient suspected with Gardner syndrome.Early treatment gives better prognosis . Facial osteomas could be the first sign of the complex syndrome and hence their identification proves to be a key in early detection and management of the syndrome.

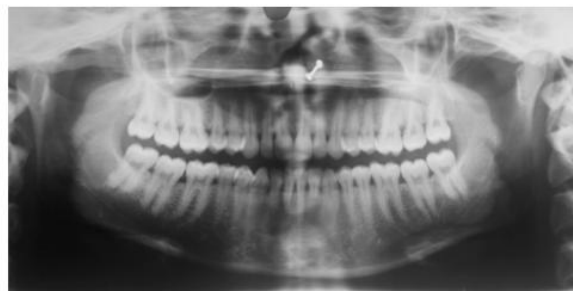
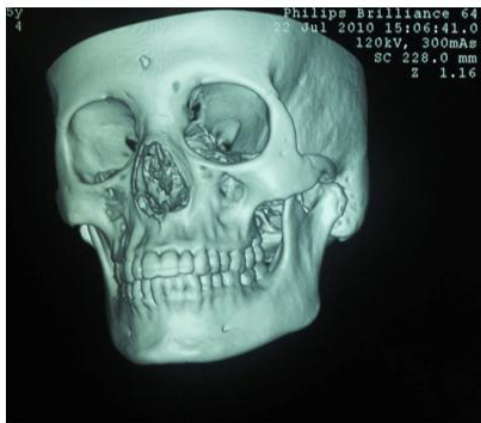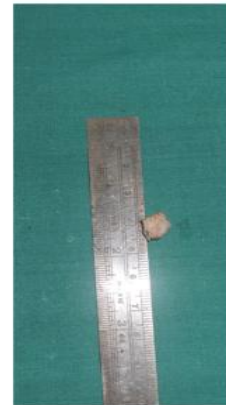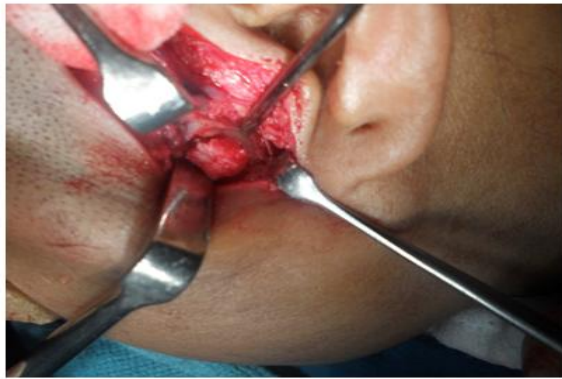References

- [1]. Herford A S , Stoffella E, Tandon R ; Osteomas involving the facial skeleton: a report of 2 cases and review of the literature :Oral Surg Oral Med Oral Pathol 2013;115:e1-e6
- [2]. Ortakog K ,Gunaydin Y, Aydintug Y, Safali M. Osteoma of the mandibular condyle: report of a case with 5-year follow-up.Mil Med 2005;170:117-20
- [3]. Mancini JC, Woltmann M, Felix VB, Freitas RR.Peripheral osteoma of the mandibular condyle Int J Oral Maxillofac Surg 2005;34:92-3
- [4]. Chimenos-Küstner E, Pascual M, Blanco I, Finestres F.Hereditary familial polyposis and Gardner's syndrome: contribution of the odontostomatology examination in its diagnosis and a case description.Med Oral Patol Oral Cir Bucal 2005;10:402-9
- [5]. Yonezu H, Wakoh M, Otonari T, Sano T, Hashimoto S, Uchiyama T.Osteoma of mandibular condyle as cause of acute pain and limited-mouth-opening: case report.Bull Tokyo Dent Coll 2007;48:193-7.
- [6]. Siar CH, Jalil AA, Ram S, Ng KH.Osteoma of the condyle as the cause of limited-mouth opening: a case report.J Oral Sci 2004;46:51-3
- [7]. Swanson KS, Guttu RL, Miller ME, Fliss DM. Gigantic osteoma of the mandible: report of a case.J Oral Maxillofac Surg 1998;56:1446-9.

1. Ivy RH .Benign bony enlargement of the condyloid process of the mandible.Ann Surg 1927;85:27-30

Patient 1 Images

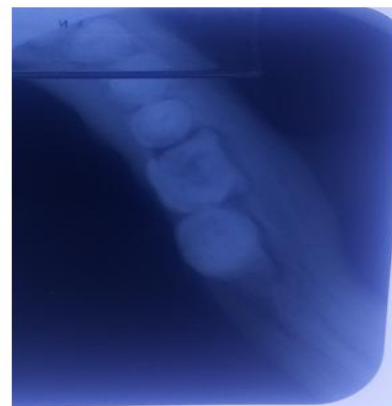
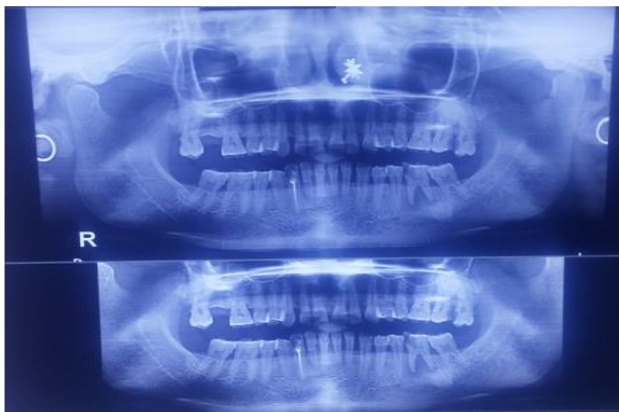
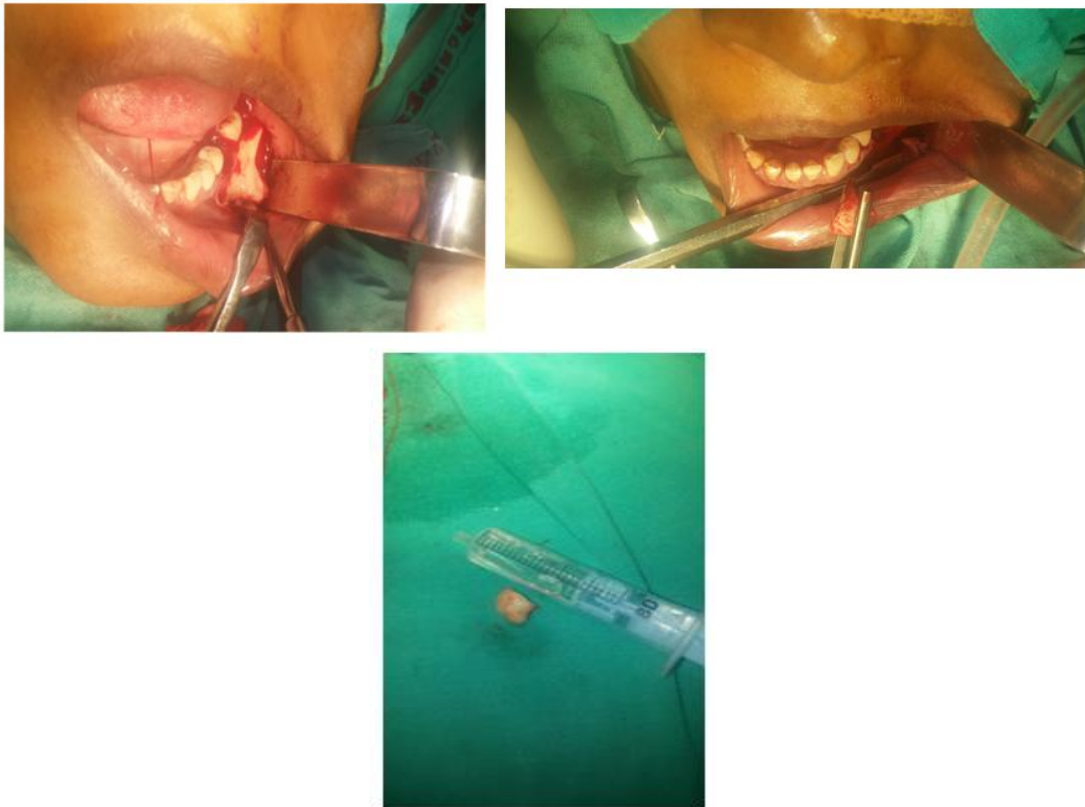


Images in sequence -

1. PATIENT 1 PRE OPERATIVE FRONTAL VIEW
2. PATIENT 1 DENTAL MIDLINE MATCHING
3. PATIENT 1 NORMAL OCCLUSION LEFT SIDE
4. PATIENT 1 NORMAL OCCLUSION RIGHT SIDE
5. PATIENT1 NORMAL PRE OP MOUTH OPENING
6. PATIENT 1 LATERAL PROFILE VIEW
7. PATIENT 1 3D RECONSTRUCTION VIEW SHOWING BONY GROWTH ON LEFT CONDYLE LATERALLY.
8. PATIENT 1 PRE OP OPG SHOWING GREATER RADIO OPACITY ON THE LEFT SIDE CONDYLE
9. PATIENT 1 ALKAYAT BRAMLEY INCISION MARKING WITH BONY GROWTH MARKING.
10. PATIENT 1 LEFT LATERAL CONDYLE GROTH
11. PATIENT 1 OSTETOMIZED LEFT LATERAL CONDYLAR GROWTH
12. PATIENT 1 RETRIEVED MASS

Patient 2





1. PATIENT 2 RADIO-OPACITY AT THE PERIAPEX OF LOWER LEFT FIRST MOLAR
2. PATIENT 2 LOWER OCCLUSAL VIEW
3. PATIENT 2 INTRA OP VIEW SHOWING SESSILE PROJECTING BONY GROWTH, 1 MOLAR HAS BEEN EXTRACTED
4. PATIENT 2 SPECIMEN OSTETOMIZED INTOTO
5. PATIENT2 EXCISED SPECIMEN

Dr. Mukund Gupta Reader "Osteoma involving Condyle and mandible : Case reports and review of literature "IOSR Journal of Dental and Medical Sciences (IOSR-JDMS), vol. 17, no. 7, 2018, pp 45-49.