

## A Study of Bipedicle flap for leg defects in a tertiary care hospital

DR.V.P.Ramanan, DR.A.Kavithapriya,

M.S., M.Ch (Plastic), M.S., M.Ch (Plastic),

Department of Plastic surgery, Coimbatore Medical College Hospital, Coimbatore

Corresponding author-DR.A.Kavithapriya

---

**Abstract** -The reconstruction of the leg defects is one of the most challenging problems for plastic and reconstructive surgeons. The current approaches are still challenging. We show an easy and useful option to obtain the coverage of traumatic pretibial defects of upper, middle and lower third of leg with good aesthetic and functional results. The choice is Bipedicle flap which avoids other surgical procedures that require more stages, operating time, special equipments and adequate training.

**Key words:** Bipedicle flaps, leg defects.

---

Date of Submission: 24-06-2018

Date Of Acceptance: 09-07-2018

---

### I. Introduction

The reconstruction of traumatic soft tissue defects of the leg is one of the most challenging problems in lower limb surgery. The most widely used techniques are local fasciocutaneous flaps either superiorly or inferiorly based, perforator based Propeller flaps, Reverse sural artery flap, Cross leg flap and free flaps for lower third defects, Soleus, Cross leg flaps and fasciocutaneous flaps for middle third defects. Gastrocnemius and Ponten flap for upper third defects.

Usually the low mobility of the surrounding skin does not make direct closure possible in the lower extremity. Local fasciocutaneous flaps can be harvested with careful assessment of length-to-width ratio but still show a considerable necrosis rate in the lower third of the leg due to venous problems.

Reverse sural artery flap is a staged procedure. Even though a good option, RSA is having the problem of venous congestion and high donor site morbidity. Local perforator flaps and free flaps are good options in reconstruction of traumatic defects of lower third of the leg. When local options are ruled out, Cross leg flap is an ideal choice that is also a staged procedure.

We have to sacrifice the functional muscle in muscle flaps. Less Postoperative morbidity of the donor site is noted in Propeller flaps. It is an alternative to the described pedicled flaps. It needs microsurgical expertise for effective survival. The main risk is related to vascular complications associated to pedicle torsion. To reduce this risk, it is necessary to identify perforator with at least 1mm in diameter. Before or during surgery, the handheld Doppler probe and the color Doppler are reliable techniques to determine the size of the perforators. These flaps have a shorter operating time when compared to free flaps. Free flaps require more operating time, special equipments and adequate training. **Melissinos and Parks** reported that success rate of free flap was only 95.6% in reconstruction of defects of lower extremities (versus 96.8%, 100%, and 98.8% of head and neck, trunk, and upper extremities reconstruction).

Keeping in mind all the previous limitations of each technique, we described a simple, effective technique called Bipedicle flap for stable coverage of the leg defects. This simple technique is often not used due to the advent of more complex modalities of tissue transfer.

This case series describe our experience with lower extremity reconstruction using the Bipedicle flap as an alternative to pedicled flaps and free flaps.

### Case series

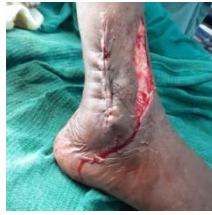We are discussing about twelve cases of post traumatic soft tissue defects of lower leg. Of which six were lower third defects, five were middle third defects and one was upper third defect. All twelve cases were grade III B compound wounds. All are fasciocutaneous flaps.

In all the cases, exposed bones were covered with Bipedicle flaps. The residual raw area and the donor sites were covered with split thickness skin graft.

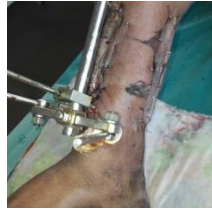Prerequisite for a Bipedicle flap:

1. Vertically oval defect
2. Surrounding skin should be normal.

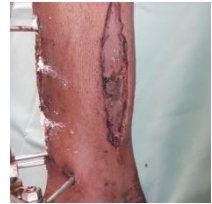**Case1 - Lower 1/3 defect**



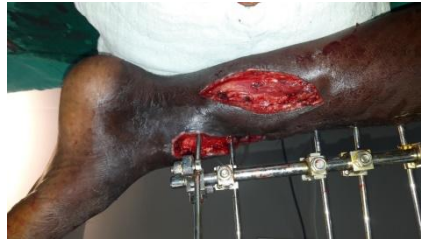**Case2 -Lower 1/3 defect**



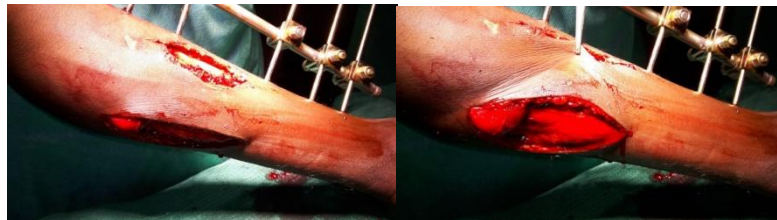
**Case3 - Lower 1/3 defect**



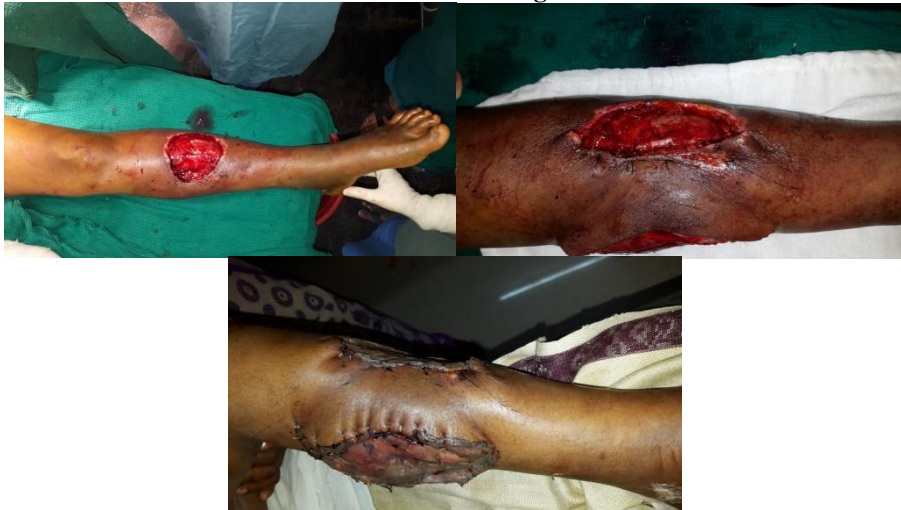**Case 4 -Lower 1/3 defect**



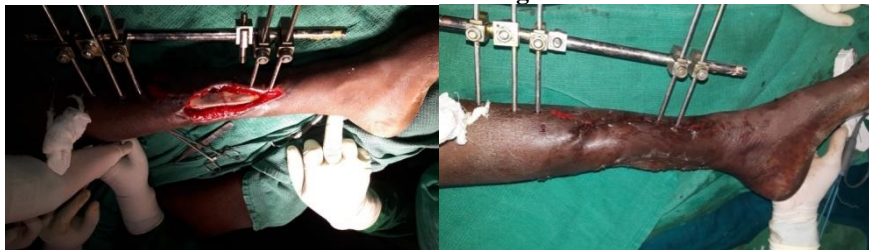**Case 5- Middle 1/3 defect**



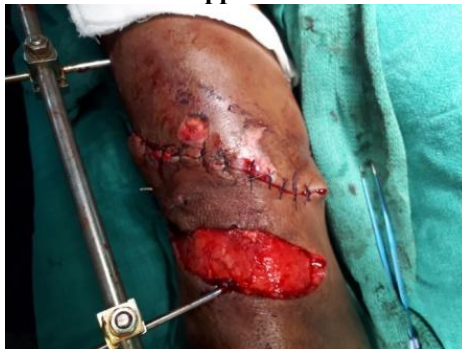**Case 6 - Middle 1/3 leg defect**



**Case 7 - Middle 1/3 leg defect**

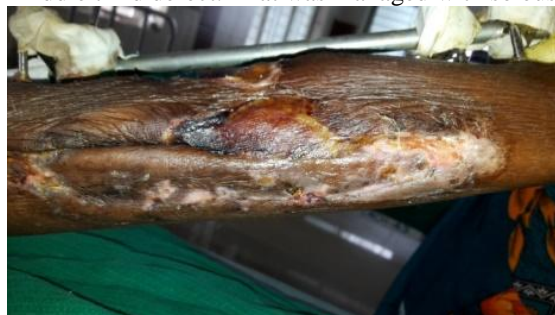

**Case 8 - Upper 1/3 defect**



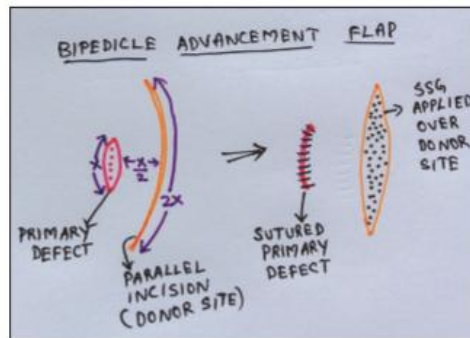
**Complications**

There was one flap necrosis in middle third defect. That was managed with soleus muscle flap.



## II. Discussion

### Bio geometry of a Bipedicle flap



Lower extremity trauma, with open soft tissue and tibial injuries, frequently occurs due to road traffic accidents and usually requires a plastic surgery intervention. The relatively unprotected anatomy of tibia leads to frequent bone exposure, which requires soft tissue coverage.

Open fractures of the tibia have high incidences of malunion and infection and require emergency irrigation and debridement. Management of the mangled lower extremity requires the meticulous teamwork of the trauma, vascular, orthopedic and plastic surgeons.

Closure of defects of the lower limb is still a significant problem when tendon or bone is exposed. Complex soft tissue defects of lower limb pose a significant challenge to the plastic surgeon in reconstruction. It requires the use of free flaps, which is demanding on the patient as well as the operating surgeon.

Bipedicle flaps are random flaps with blood supply from two pedicles. It allows the surgeon to use local tissue with an augmented blood flow. Bipedicled flaps are simple to elevate and need shorter operating time.

There has been a major switchover in the treatment of soft tissue defects in open fractures. A strong inclination has developed towards non-micro vascular flaps rather than the time-consuming and tedious free flaps. The advent of reliable, robust and technically less demanding techniques have allowed covering small and moderate sized soft tissue defects, which was once considered as a territory for a micro vascular flap. The sharp decline in the usage of micro vascular flaps in the management of acute lower limb trauma is also due to fairly high incidence of failure, needs expertise and the expense of the treatment.

The injured limbs are even more difficult to salvage when they face failure of free flap. These factors reveal that free flaps are useful only when the loco regional flaps are not possible either because of the large size of the defect or extensive local tissue trauma.

In 1996 Schwabegger et al. reported 12 cases of successful wound closure on the lower leg with the versatile Bipedicled flap. Their study showed a low incidence of minor complications, whether it was used as a cutaneous, fasciocutaneous or as a myofasciocutaneous flap. They concluded that though it is an old method, it is less complicated.

Saleh et al. in 2008 studied the various therapeutic options in the reconstruction of lower extremity injuries. They found that the local random fasciocutaneous flaps are simple to raise and replace like with like tissue, appropriate for minor defects and do not need unusual surgical skills except for the disadvantage of unsightly donor site. Hence, they remain one of the useful methods of skin cover for lower extremity defects.

## III. Conclusion

In Plastic and reconstructive surgery, the pedicled fasciocutaneous and myocutaneous flaps are often used to treat larger defects of the lower leg. Bipedicled advancement flaps offer a safe, swift and a simple alternative for covering complex open wounds of the lower extremities.

As a result of the above procedure, soft tissue cover, marked functional recovery and good cosmetic results are achieved with the least morbidity to the donor site due to dual blood supply provided the case selection is good. Post-operative lymphedema is less since it has got intact lymphatic tissue. Post-operative morbidity is less. This again emphasizes the fact that in spite of being a conventional procedure, it is a gold standard method.

In addition, the operative technique is relatively short and simple to perform. It doesn't need the use of microsurgical skills and instruments. If it is applied to selected indications and appropriate patients, the Bipedicled flap is certainly a reliable alternative to the other more sophisticated modern methods of tissue transfer.

### References

- [1]. Rios-Luna A, Fahandezh-Saddi H, Villanueva-Martínez M, López AG. Pearls and tips in coverage of the tibia after a high energy trauma. *Indian J Orthop* 2008;42:387-94.
- [2]. Kadam D. Limb salvage surgery. *Indian J Plast Surg* 2013;46:265-74.
- [3]. Tobin GR. Myocutaneous and muscle flaps: Refinements and new applications. *Curr Probl Surg* 1986;23:315-93.
- [4]. Dujon DG, Khan UD, Aslam S. Bipedicle flaps: simple solutions for difficult problems in the extremities. *Br J Plast Surg* 1997;50:641-5.
- [5]. Parrett BM, Pribaz JJ. Lower extremity reconstruction. *Rev Med Clin Condes* 2010;21:66-75.
- [6]. Granzow JW, Li A, Suliman A, Caton A, Goldberg M, Boyd JB. Bipedicled flaps in posttraumatic lower-extremity reconstruction. *J Plast Reconstr Aesthet Surg* 2013;66:1415-20.
- [7]. Kamath JB, Shetty MS, Joshua TV, Kumar A, Harshvardhan, Naik DM. Soft tissue coverage in open fractures of tibia. *Indian J Orthop* 2012;46:462-9.
- [8]. Schwabegger A, Ninković M, Wechselberger G, Anderl H. The bipedicled flap on the lower leg, a valuable old method? Its indications and limitations in 12 cases. *Scand J Plast Reconstr Surg Hand Surg* 1996;30:187-93.
- [9]. Saleh Y, Waheeb B, Abd-Elaziz MA, El-Oteify M. A suggested algorithm for post-traumatic lower limb soft tissue reconstruction. *Egypt J Plast Reconstr Surg* 2007;31:87-96.
- [10]. Zayakova YK. Application of pedicle flaps for wound coverage of lower leg. *J IMAB* 2013;19:382-6.

DR.A.Kavithapriya "A Study of Bipedicle flap for leg defects in a tertiary care hospital. "IOSR Journal of Dental and Medical Sciences (IOSR-JDMS), vol. 17, no. 7, 2018, pp 19-23.