

Effect of UV Light on Diabetic Retinopathy in Pseudophakic Eye

Dr. P. Tidake¹, Dr. Rohit Agrawal²

Corresponding Author: Dr. Rohit Agrawal

Abstract: Introduction: Increased retinopathy progression has been reported after cataract surgery in patients with diabetes mellitus [1]. Light has toxic potential and the eye has adapted several mechanisms to protect the retina from light-induced injury. The two most important sources of tissue absorption through which electromagnetic radiation may be propagated are the cornea and the lens [2]. After cataract surgery and IOL implantation amount of UV light entering the eye increases and leads to retinal damage and increase in pre-existing diabetic retinopathy. So in this study we studied the effect of UV light on DR in pseudophakic eye. **Material And Method** S-30 patients with immature senile cataract and NPDR in both the eyes were selected. One eye was operated for cataract and PMMA lens was implanted. Patient were followed up for 6 months and progression of DR was compared in operated and non-operated eye. **Results-** Diabetic retinopathy showed rise in severity in operated eye over the period of 6 months. 44% patients Showed Increase In NPDR In 6 Months Follow Up In Operated Eye. **Conclusion-** PMMA lens do not efficiently block the UV light compared to normal crystalline lens leading to damage to the retina and increase in progression of NPDR.

Date of Submission: 10-07-2018

Date of acceptance: 27-07-2018

I. Introduction

Light damage to the eye has been recognized since ancient times; references to solar retinopathy is given in the writings of Plato, in legends of American indigenous peoples, and throughout the European classical period [3-4]. The anterior portions of the eye i.e., the cornea and lens, are highly susceptible to UV exposure, but because of the strong absorption of wavelengths below 360 nm in the ocular lens, retina remains protected from the harmful UV rays [5-7]. Ultraviolet light has been further classified into three subgroups, UVA (315–400 nm), UVB (260–315 nm), and UVC (100–260 nm). The cornea absorbs almost all ultraviolet radiation below 295 nm. This includes all UVC and most UVB light. The natural crystalline lens absorbs most light near UVB (300–315 nm) and all UVA light [2]. After cataract surgery and IOL implantation amount of UV light entering the eye increases. This leads to retinal damage and increase in pre-existing retinal pathologies like diabetic retinopathy.

II. Aims & Objectives

1. To study the effect of UV rays on diabetic retinopathy in post operative cataract patients with PCIOL implantation
2. To study the increase in severity of diabetic retinopathy in pseudophakic eye due to UV rays.

III. Material And Methods

Study Design- Prospective interventional study

Inclusion Criteria:

1. Patients with non-proliferative diabetic retinopathy- **very mild, mild and moderate NPDR** before cataract surgery (according to ETDRS Classification).
2. Both sexes.
3. Patients in which fundus was visible before cataract surgery i.e. grade 3 or less nuclear sclerosis
4. Patients in whom pupils could be fully dilated
5. Patients with uneventful cataract surgery
6. Patients with same diabetic retinopathy status in both eyes were selected.

Exclusion CRITERIA:

1. Patients with very hazy media impairing the visualization of the fundus.
2. Patients in whom dilation of pupil contraindicated.
3. Patients not giving consent.
4. Patients who already had CSME before cataract surgery
5. Patients with **Severe NPDR and proliferative diabetic retinopathy (PDR)**

Pre-Operative: 30 patients with immature senile cataract and NPDR in both the eyes were selected. Proper pre-operative evaluation was done including visual acuity, intra-ocular pressure, anterior segment evaluation, pupillary reflex and fundus examination by direct, indirect and slit lamp biomicroscopy. All the patients which were selected had crystalline lens in both the eyes pre-operatively.

Intra-Operative: All the patients underwent uncomplicated small incision cataract extraction with rigid PMMA lens implantation in posterior capsular bag in one eye.

Post-Operative: All the patients were followed up for a period of 6 months. There were 3 follow ups- 1st month, 3rd month and 6th month.

In all the follow ups patients visual acuity, stage of diabetic retinopathy and glycemic controls were checked.

Post operatively all the patients were given following treatment-

- E/d moxifloxacin 0.5% with dexamethasone 0.1% 2 hourly
- E/d homatropine 2% BD
- E/d nepafenac 0.1% TDS
- T. Ciprofloxacin 500 mg BD x 5 days
- T. Brufen 400 mg BD x 5 days
- T. Rantac 150 mg BD x 5 days

IV. Observation & Results

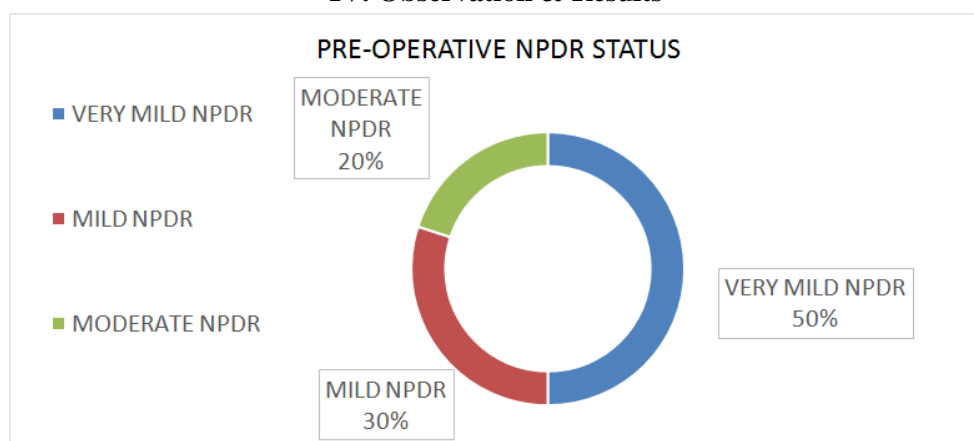


Figure 1

Pre-operatively 15 patients had very mild NPDR (50%), 9 had mild NPDR (30%) and 6 had moderate NPDR (20%) in both eyes.

During the 6 month follow-up in very mild NPDR group, 3 out of 15 patients showed progression to mild NPDR in non-operated eye. Whereas in pseudophakic eyes 4 patients progressed to mild NPDR and 3 to moderate NPDR. (as shown in fig 2&3)

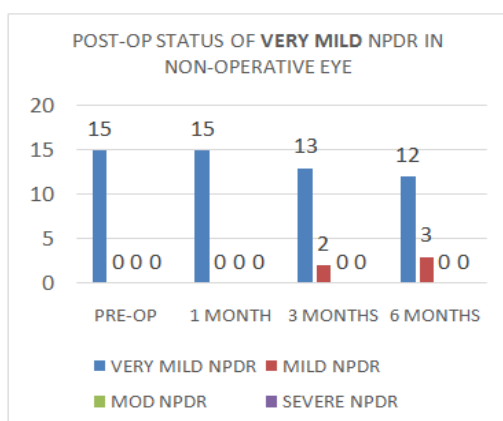


Figure 2

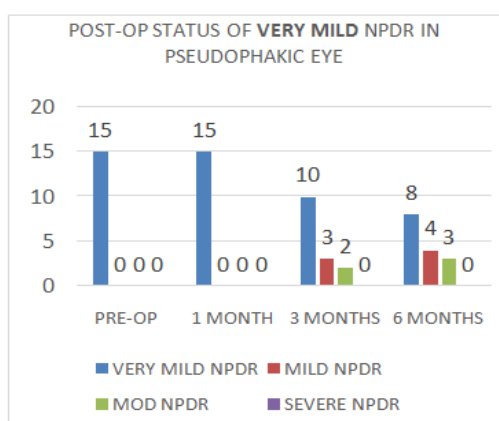


Figure 3

During the 6 month follow-up in mild NPDR group, 2 out of 9 patients showed progression to moderate NPDR in non-operated eye. Whereas in pseudophakic eyes 3 patients progressed to moderate NPDR (as shown in fig 4&5).

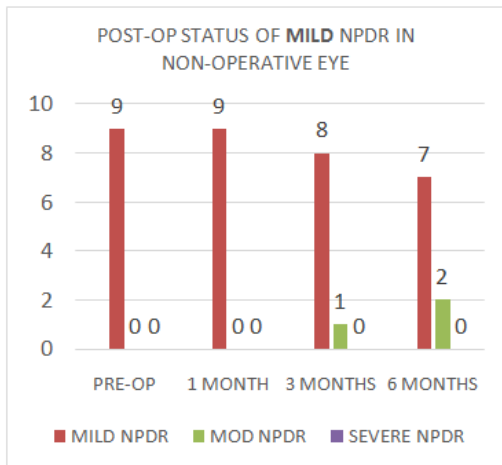


Figure 4

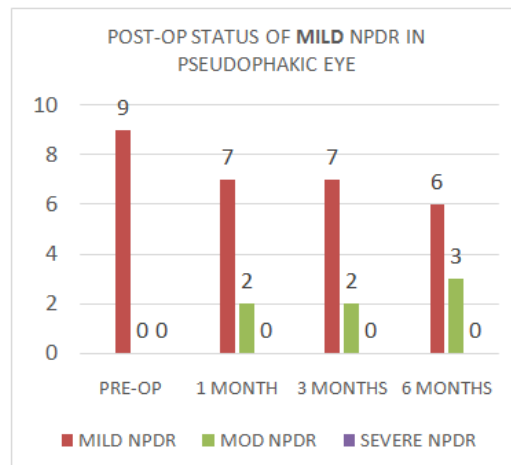


Figure 5

During the 6 month follow-up in moderate NPDR group, none of the patients showed progression in non-operated eye. Whereas in pseudophakic eyes 2 patients progressed to severe NPDR, for which treatment was started (as shown in fig 6&7)

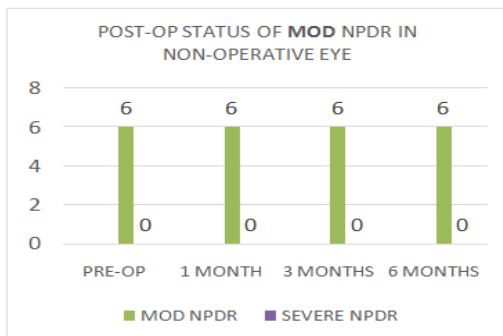


Figure 6

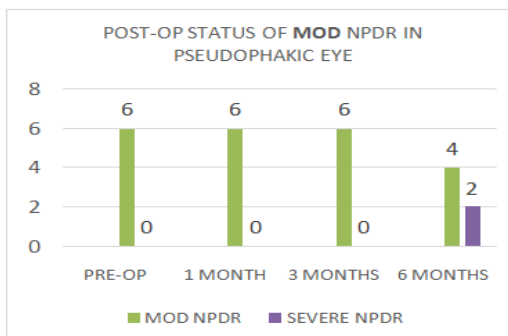


Figure 7

After 6 month follow-up it was observed that only 5 (17%) out of 30 patients showed progression in NPDR status in non-operated eyes. (fig. 8) Whereas 12 (40%) out of 30 patients showed progression in NPDR status in pseudophakic eye. (fig. 9)

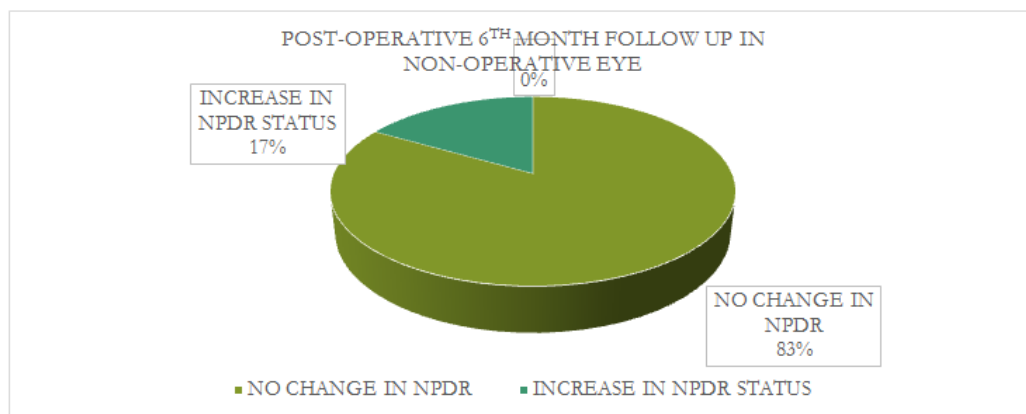


Figure 8

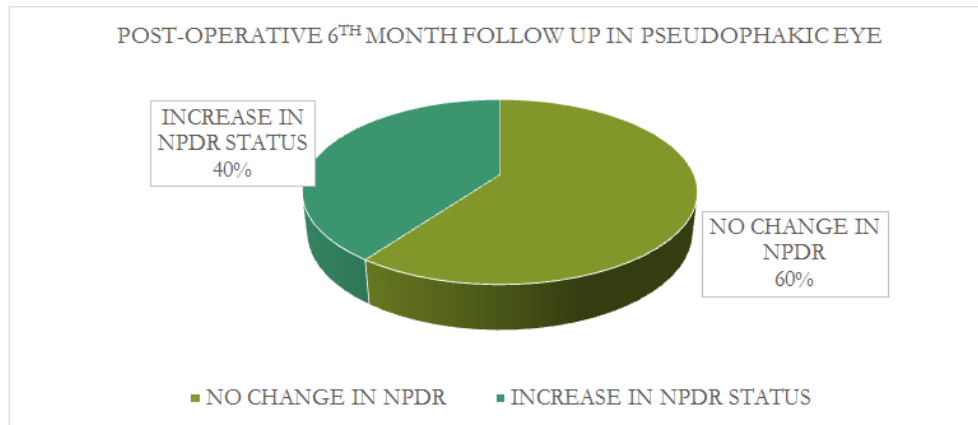


Figure 9

V. Discussion

Jaffe and Burton' and later Schatz et al "emphasised that the retinopathy progressed rapidly in the operated eye compared with the phakic control fellow eye [8-9].

Pollack et al, as well as Cunliffe et al, showed that macular oedema and neovascularisation can worsen after cataract extraction. Pollack et al also demonstrated that 81% of eyes with pre-existing background retinopathy developed clinical cystoid macular oedema after uncomplicated cataract surgery compared with only 32% of eyes without background retinopathy [9-10].

Postel et al showed the presence of cystoid macular oedema, subretinal nodules of hyperplastic RPE, and atrophy of the nerve fibre and ganglion cell layers.

Recent work by Albert et al has shown the development of progressive stages of retinal degeneration and choroidal neovascularization after long-term intense cyclic light exposure in albino rats.

VI. Conclusion

The ability of light to cause injury to the retina has been shown both clinically and experimentally. The following study suggests the role of UV light in progression of diabetic retinopathy following cataract surgery.

Most patients in the study had reasonably good control of blood sugar, which rules out progression due to increased sugar levels. Most of the patients selected in the study were field workers which points towards the role of UV light in progression of NPDR. Though post-operative inflammation is also a cause for increase in diabetic maculopathy but UV light is also a significant risk factor in the progression of diabetic retinopathy.

The study also points towards the use of better UV protected IOLs to reduce retinal damage following cataract extraction.

Bibliography:

- [1]. Klein BEK, Klein R, Moss SE. Prevalence of cataracts in a population-based study of persons with diabetes mellitus. *Ophthalmology* 1985;92:1 191-6.
- [2]. Sample PA, Esterson FD, Weinreb RN, Boynton RM. The aging lens: in vivo assessment of light absorption in 84 human eyes. *Invest Ophthalmol Vis Sci* 1988; 29(8):1306-1311
- [3]. Plato. *Phaedo*. In: Jowett B, translator. *The Dialogues of Plato*. New York, NY, Charles Scribner & Sons, 1911.
- [4]. Mooney J. Myths of the Cherokee. 19th Annual Report of the Bureau of American Ethnology for the Year 1897-1898, Part I. Mineola, NY: Dover Publications, 1996, pp 295-300.
- [5]. Boettner EA, Wolter JR. Transmission of the ocular media. *Invest Ophthalmol [now Invest Ophthalmol Vis Sci]* 1962;1:776-783.
- [6]. Dillon J, Zheng L, Merriam JC, et al. Transmission spectra of light to the mammalian retina. *Photochem Photobiol* 2000;71:225-229.
- [7]. Gaillard ER, Zheng L, Merriam JC, et al. Age-related changes in the absorption characteristics of the primate lens. *Invest Ophthalmol Vis Sci* 2000;41:1454-1459.
- [8]. Jaffe GJ, Burton TC. Progression of non-proliferative diabetic retinopathy following cataract extraction. *Arch Ophthalmol* 1988;106:745-9.
- [9]. Schatz H, Atienza D, McDonald R, Johnson RN. Severe diabetic retinopathy after cataract surgery. *Am J Ophthalmol* 1994;117:314-21.
- [10]. Pollack A, Leiba H, Buckelman A, Oliver M. Cystoid macular oedema following cataract extraction in patients with diabetes. *Br J Ophthalmol* 1992;76:221-4.

Dr. P. Tidake "Effect of UV Light on Diabetic Retinopathy in Pseudophakic Eye "IOSR
Journal of Dental and Medical Sciences (IOSR-JDMS), vol. 17, no. 7, 2018, pp 25-28.