

## Colposcopic Evaluation of Cervix with Persistent Inflammatory Pap Smear

Dr. Kamrun Nahar<sup>1</sup>, Dr. Saria Tasnim<sup>2</sup>, Dr. Mirza Md.Asaduzzaman<sup>3</sup>

<sup>1</sup>Consultant (Obstetrics and Gynaecology), Institute of Child & Mother Health Matuail, Dhaka

<sup>2</sup>Professor, MBBS, FCPS (Obstetrics and Gynaecology), M Med, Diploma in Community Epidemiology, Institute of Child & Mother Health Matuail, Dhaka

<sup>3</sup>Emergency Medical Officer, Upazilla Health Complex, Debidwar, Comilla

Corresponding Author: Dr. Kamrun Nahar

**Abstract:** In women the most common invasive cancer is cervical cancer. The risk factor of cervical cancer is Risk factors can be genetic, but some lifestyle factors, such as alcohol intake. For colposcopy evaluation of cervix Inflammatory Pap smear is commonly use. Our aim of the study is to examine women with persistent inflammation on Pap smear need further evaluation with colposcopy. In this study was conducted in Department of Obstetrics and Gynecology, Institute of Child & Mother Health (ICMH) Dhaka, 2011 January to 2014 January where from total 1457 married non pregnant women only 140 case screened and examine who complained inflammatory cellular changes on pap smear. The patients age was  $\geq 19$  where age between 20-30 shows highest percentage of inflammatory cellular changes on pap smear and multipara was found 93% than primipara. During the study oral contraceptives are taken highest among other contraceptives. In the study Most of the cervixes were broad 78.9% and almost all of the uteri exhibited free fornix. Where size of uterus was normal and Colposcope comment: Positive was 76 and negative was 64. After many analysis and examination , all women with persistent inflammation on Pap smear should be subjected to further evaluation.

**Key Words:** Cervical Cancer, Colposcopic Evaluation, Cervix with persistent inflammatory, Pap Smear

Date of Submission: 22-06-2018

Date Of Acceptance: 05-07-2018

### I. Introduction

Cervical cancer is a cancer arising from the cervixes. It is due to the abnormal growth of cells that have the ability to invade or spread to other parts of the body. The risk factor of cervical cancer is Risk factors can be genetic, but some lifestyle factors, such as alcohol intake. Early on, typically no symptoms are seen. Later symptoms may include abnormal vaginal bleeding, pelvic pain, or pain during sexual intercourse. While bleeding after sex may not be serious, it may also indicate the presence of cervical cancer<sup>[1]</sup> The early stages of cervical cancer may be completely free of symptoms. Vaginal bleeding, contact bleeding (one most common form being bleeding after sexual intercourse), or (rarely) a vaginal mass may indicate the presence of malignancy. Also, moderate pain during sexual intercourse and vaginal discharge are symptoms of cervical cancer. In advanced disease, metastases may be present in the abdomen, lungs, or elsewhere. Symptoms of advanced cervical cancer may include: loss of appetite, weight loss, fatigue, pelvic pain, back pain, leg pain, swollen legs, heavy vaginal bleeding, bone fractures, and (rarely) leakage of urine or feces from the vagina. Bleeding after douching or after a pelvic exam is a common symptom of cervical cancer<sup>[2]</sup>

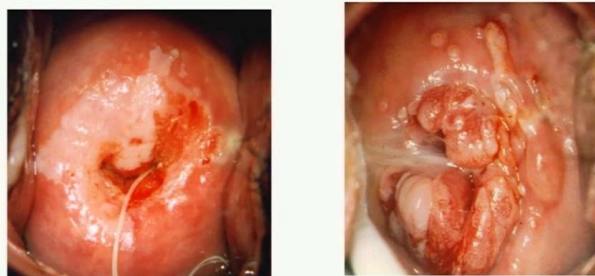


Figure-1: Cervical cancer<sup>[3]</sup>

Inflammatory Pap smear is the most common colposcopic evaluation of cervix with persistent Inflammation Pap smear. The suggested treatment for generous cell changes on Pap spread screening is treatment of contamination took after by a rehash Pap spread in 4 to a half year time. In the event that the

incendiary changes proceed with, the patient is to be subjected to colposcopy.<sup>[4][5]</sup> However, this is scarcely taken after, particularly in asset poor nations, where appropriate cervical screening convention has not been set up yet. Henceforth, a great number of patients in the premalignant arrange (which may experience threatening change amid the slack time) are missed. So the patients with tenacious fiery Pap smears ought to be tentatively assessed utilizing colposcopy. There are not very many examinations in the writing where the frequency of premalignant and dangerous injuries was investigated in instances of incendiary Pap spread. Aggravation can darken couple of dangerous cells and may bring about high false negative rates which might be lessened by utilizing fluid based cytology.<sup>[6]</sup> However, it was accounted for that fluid based cytology was not savvy for creating nations and the ongoing investigations found no measurably critical distinction of exactness between customary Pap test and fluid based cytology.<sup>[7]</sup> Colposcopy of ladies with cytological analysis of incendiary epithelial changes might be a valuable method to distinguish generally unrecognized instances of CIN. In Bangladesh, every year 17,686 women are diagnosed with cervical cancer; of them 10,364 die of the disease. Although services for carcinoma of cervix screening are available in Bangladesh. It is not practically feasible to subject all women with inflammatory pap smear to colposcopy in our country.

## II. Objective

**General Objective:**

- To explore whether women with persistent inflammation on Pap smear need further evaluation with colposcopy.

**Specific Study:**

- To minimize morbidity and mortality from the disease.
- To examine oral contraceptives usage.

## III. Methodology

**Table-1: Study type, place & Duration of the study**

Study type	Place of study	Duration of study
Retrospective study	Department of Obstetrics and Gynaecology, Institute of Child & Mother Health (ICMH), Dhaka	3 Year. 2011 January to 2014 January

**Study Population:**

In this study, Patients with two consecutive reports of inflammatory cellular changes without atypia on Pap smears despite anti-inflammatory therapy were the study population.

**Sample Size:**

In this study total 1457 married non pregnant women (aged 20 years or more) complaining of different gynecological problems underwent Paps test during the study period for gynecological problems. 313 were reported as having 'inflammatory cellular changes. After giving anti-inflammatory treatment most of them were cured leaving 140 cases with repeat report of inflammatory cellular changes on pap smear and hence were included the study.

**Method:**

During study at the age of  $\geq 19$  year with the complaints of excessive vaginal discharge, post coital bleeding etc, they were advised to paps smear. If pap smear test exhibited inflammatory cellular changes without atypia, the patients received treatment of infection with doxycycline daily for 14 or metronidazole. If the inflammatory change persists the patients are subject to colposcopy. To perform colposcopy examination the cervix are cline with saline solution and applied acetic acid. After 60 sec cervix are visualized under low and high magnification. Aceto-white areas and atypical vasculature were determined. Visual inspection with acetic acid (VIA) positivity was considered if there were acetowhite areas in the transformation zone close to squama-columnar junction. Iodine negative areas were determined at cervix by applying legal solution. A biopsy was performed from aceto-white, mosaic, Iodine-negative areas and from punctuations, atypical vasculatures, and erosions.

**Statistical analysis:**

In this study Data were processed and analyzed using distribution of respondents by their Parity computer software SPSS (Statistical Package for (n=140). The test statistics used for analysis of data were Chi-square Test (for comparison of categorical data between groups), other protection measures Almost all Student's t-Test (for comparison of continuous patients complained of persistent leucorrhoea)

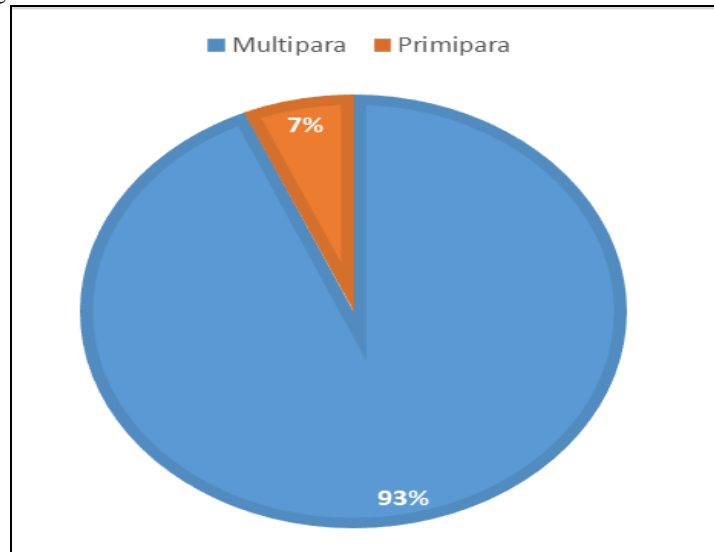
**IV. Result**

In table 2 shows distribution of responds by their age where Age between 20-30 year have highest frequency among all. The following table is given below:

**Table-2: Distribution of responds by their age (n=140)**

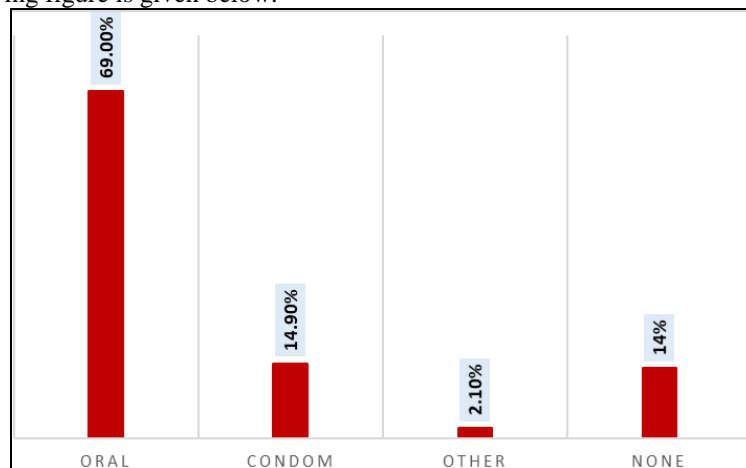
Age	Frequency	Percent
>20	5	3.2
20-30	66	48.5
30-40	55	39.2
≥40	14	9.1

The figure -2 shows that distribution of responds by their parity where multipara has highest percentage. The following figure-2 is given below:



**Figure 2: Distribution of responds by their parity**

Figure-3 shows that distribution of responds of their contraceptives (n=140) where 69% use oral contraceptives among other. Following figure is given below:



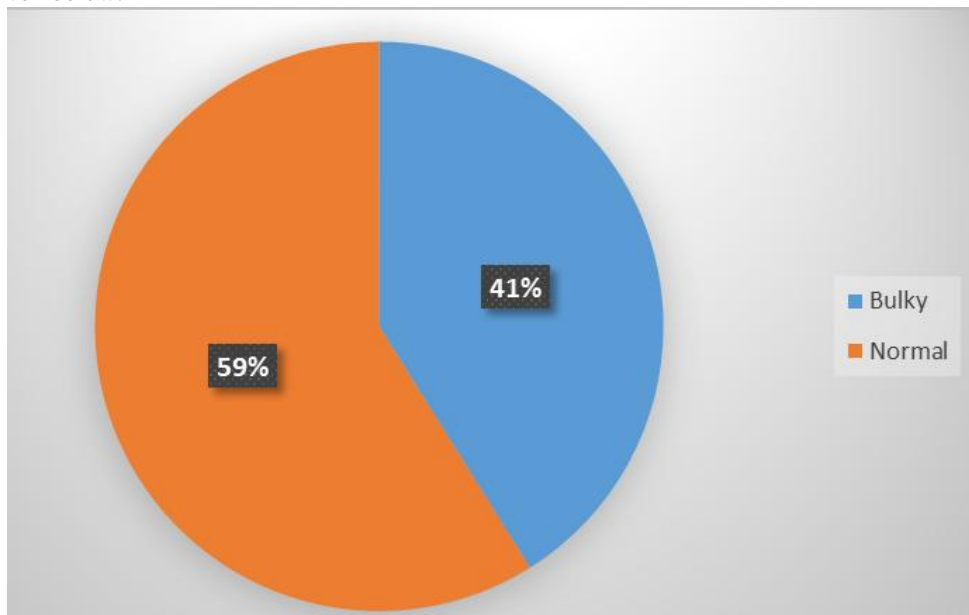
**Figure-3: Distribution of responds of their contraceptives**

Table-3 shows the distribution of subjects by their per speculum examination of cervixes and P/V findings of fornix where Most of the cervixes were broad 78.9%. Almost all of the uteri exhibited free fornix. The following tables shows in details:

**Table 3: Distribution of subjects by their per speculum examination of cervixes and P/V findings of fornix**

per speculum examination, cervixes , Fornix	Frequency	Percent
-Broad	-110	78.9
-Hypertrophy	-20	12.5
-Normal	-10	8.6
<b><u>Fornix</u></b>		
-Free	-130	99.3
-Thickened	-10	0.7

In figure-4 shows size of uterus of patients, where Normal size got highest percentage among all . The following figure is given below:



**Figure 4: size of uterus of patients**

Table -4 shows Distribution of subjects by their colposcopy evolution where, Acetowhite Dense and CIN-1 was maximum among all. Following table is given below:

Table-4 : Distribution of subjects by their Colposcopy

Colposcopy evolution (n=140)	Frequency
Acetowhite Light	37
Acetowhite Dense	95
Mosaicism	8
Total	140
Colposcope comment:(n=140) Positive	76
Colposcope comment:(n=140) Negative	64
Total	140
Colposcope Grading:(n=76) CIN-1	48
Colposcope Grading:(n=76)	20
CIN-2	
Colposcope Grading:(n=76)	8
CIN-3	
Total	76

Table -5 shows Patients Stratified by histopathological comment and grading, where positive comment have maximum percent among all. Following table is given below:

Table-5: Patients Stratified by histopathological comment and grading

Histopathological comment and grading	Frequency	Percent
Histopathological comment: n=76 Positive	31	37.5
histopathological comment: n=76 Negative	45	62.5
Total	76	100%
Histopathological Grading;n=30 CIN-2	20	12
Histopathological Grading ; n=30 CIN-3	8	75
Histopathological Grading ;n=30 Invasive carcinoma	2	13
Total	30	100%

## V. Discussion

For cervix cancer Pap smear test is a major screening test for early diagnosis and treatment. Inflammation on Pap smear is considered a relatively benign finding. However, due to the low sensitivity and high false negative rate of Pap smear, there is a possibility that an inflammatory Pap smear may miss cervical premalignant changes and in rare cases malignant changes as well. In the present study total of 1457 women under-went Pap test during the study period for gynecological problems like vaginal discharge, postcoital bleeding, intermenstrual bleeding and leucorrhoea. Of them 313 were reported as having 'inflammatory cellular changes'. Ant inflammatory treatment given to these patients cured most of them leaving 140 cases with a repeat report of inflammation on Pap smear which also compares well with the other study.<sup>[8][9]</sup> The prevalence of inflammatory Pap smear in many Indian studies is reported to vary between 70% and 80.5%.<sup>[10]</sup> However, in a recent study the reported prevalence was lower is quite consistent with the findings of the present study. Among the persistent inflammatory Pap smear cases, 76 were Colposcopically positive for CIN where CIN-1 is 48, CIN-2 20 and of the 140 women. Various studies have found the possibility of CIN with a report of persistent inflammatory smear to range from to 35%.<sup>[11]</sup> According to various studies, ASCUS (atypical squamous or glandular cells of undetermined significance) on Pap smear has a 10-20% chance of harboring CIN.<sup>[12][13]</sup> This is the reason why we triage women with ASCUS on Pap smear with either repeat cytology, HPV DNA testing, or colposcopy.<sup>[14]</sup> Our study has shown a sizable proportion of women (about 20%) with persistent inflammation on Pap smear could be harboring CIN. Moreover, the incidence of CIN and invasive carcinoma in women with persistent inflammatory Pap repeating the Pap smear may lead to a delay in diagnosis of CIN in a high

percentage of cases. The mechanism involved in the transformation of chronic inflammatory cells to carcinogenic cells is not clear. However, persistent inflammation is thought to increase cellular turnover, especially in the epithelium, and provides a selection pressure that results in the emergence of cells that are at a high risk for malignant transformation. Hence, all women with persistent inflammation on Pap smear should be subjected to further evaluation.

## VI. Recommendation

A large-scale study should be conducted to validate the findings of the present study so that outcomes can be more accurate

## VII. Conclusion

On the basis of the examination and findings of the study, it can be concluded that patients with persistent Inflammatory Pap smear can harbor a high proportion .pap smear report of persistent inflammatory cellular changes should not be considered as a variant of normal, especially when it doctor not respond to adequate recommended therapy. Such patients must be referred to further evaluation by colposcopy.

## References

- [1]. [Cervical Cancer Treatment \(PDQ®\)](#)". NCI. 2014-03-14. [Archived](#) from the original on 5 July 2014. Retrieved 24 June 2014
- [2]. [Cervical Cancer Treatment \(PDQ®\)](#)". National Cancer Institute. 2014-03-14. [Archived](#) from the original on 5 July 2014. Retrieved 25 June 2014
- [3]. [https://www.google.com/search?q=cervical+cancer&source=lnms&tbm=isch&sa=X&ved=0ahUKEwjz1KS34LbbAhUFVH0KHQ SqBIOQ\\_AUICigB&biw=1366&bih=662#imgrc=PiKicBC17-5iGM](https://www.google.com/search?q=cervical+cancer&source=lnms&tbm=isch&sa=X&ved=0ahUKEwjz1KS34LbbAhUFVH0KHQ SqBIOQ_AUICigB&biw=1366&bih=662#imgrc=PiKicBC17-5iGM):
- [4]. ACOG (The American College of Obstetricians & Gynecologists). Practice Bulletin. clinical management guidelines for Obstetrician and Gynecologist Cervical
- [5]. Dasari P, Rajathi S, Kumar SV. Colposcopic evaluation of persistent Inflammatory Pap smear: A prospective analytical study. *Cytojournal*
- [6]. Marchand L, Van Dinter M, Mundt M, Dingel W, Klein G. Current cervical cancer screening practices of Dane Country, Wsconsin Primary care clinicians. *W/MJ* 2003; 102:3540.
- [7]. ACOG Committee on Practice Bulletins Gynecology. Cervical cytology screenIng. ACOG Practice Bulletin no. 109. *ObstetGynecol*
- [8]. Bhutia K, puri M, Gami N, Aggarwa' Y, Trivedi SS. Persistent inflammation on Pap smeaj: warrant evaluation. *Indian J Cancer* 2011
- [9]. Seekin NC, Turban NO, Ozmen S, Ersan F, Avsar F, Ustin H. Routine evaluation of patients with persistent Inflammatory cellular changes on Pap smear. *Int J Gynaecol*
- [10]. Mali BN, Joshi JU, Bhave GG, wagic UD. Cervical cytology in prostitutes of Bombay (India). *Genitourin Med* 1992; 68:62-3.
- [11]. Frisch LE, Parmar H, Buckley LD, Chalem SA. Colposcopy "f patients with Cytologic InfL,omatory epithelial changes. *Acta Cytol* 1990;34:1335.
- [12]. Wright TC, Sun XW, Loulos J. Comparison of management algorithms for the evaluation of women with low-grade cytologic abnormalities. *ObstetGynecol*
- [13]. Lonky NM, Navarre GL, Saunders S, Sadeghi M, WoldeTsadik G. Low-grade Papanicolaou smears and the Bethesda system: A prospective cytohistopathologic analysis. *ObstetGynecol*
- [14]. Wright TC, Massac! LM, Dunton CJ, Spitzer M, Wilkinson E), Solomon D, et al. Consensus guidelines for the management of women with abnormal cervical cancer screen;og tests. *Am J ObstetGynecol* 55

Dr. Kamrun Nahar " Colposcopic Evaluation of Cervix with Persistent Inflammatory Pap Smear. "IOSR Journal of Dental and Medical Sciences (IOSR-JDMS), vol. 17, no. 7, 2018, pp 42-47.