

Compound fractures of hand: Study on fracture fixation and functional recovery

Dr. V.V.Narayana Rao¹, Dr. P.Anil Babu²

¹(Associate Professor, Department of Orthopaedics, Guntur Medical College, Guntur, AP, India)

²(Assistant Professor, Department of Orthopaedics, Guntur Medical College, Guntur, AP, India)

Corresponding Author: Dr P.Anil Babu²

Abstract : A variety of fractures of the hand are occurring due to Road traffic accidents, mechanization and with the tools used in agriculture. It is very common to find a compound fracture of the hand in the Emergency Room. The general principles of trauma management is the same for trauma anywhere in the body, the hand, being a specialized structure interacting with the environment, is sensitive to functional impairment, more so when there is extensive scarring and prolonged immobilization. Careful judgment is required, whether the wound is sufficiently debrided and clean enough to permit primary closure, or whether it should be left open for repeat debridement and irrigation and dressings. If Primary closure is not feasible the wound can be reevaluated in the operating room and plans made at that time for closure. The goal is to close the wound within the first 4 to 5 days before granulation tissues form and contractures develop. The study cohort consist of 105 cases of compound meta carpal and phalangeal fractures from Type I to IIIB Gustilo –Andersons classification. The results are assessed with basically three parameters: The soft tissue healing, retained range of movements, and fracture union.

Keywords– compound fracture, metacarpals, phalanges, debridement, internal fixation.

Date of Submission: 29-05-2018

Date Of Acceptance: 14-06-2018

I. INTRODUCTION

A variety of fractures of the hand are occurring due to Road traffic accidents, mechanization and with the tools used in agriculture. It is very common to find a compound fracture of the hand in the Emergency Room. The general principles of trauma management is the same for trauma anywhere in the body, the hand, being a specialized structure interacting with the environment, is sensitive to functional impairment, more so when there is extensive scarring and prolonged immobilization. That is the reason why in treating the fractures of the hand, anatomical and especially radiographic perfection does not always lead to normal function. As per the literature , often, it is better to accept a less than anatomical position of a fracture and prefer proper splinting and early motion for good function of the hand as a whole. In order to prevent scarring a closed approach to the management of hand fractures and dislocations is preferred to open reduction; when surgery is required, the least complicated procedure to accomplish the desired functional result should be chosen. Though there are few exceptions, prolonged immobilization (>3 weeks) is not indicated in treating the hand injuries.

The clinical union in hand fractures often precedes radiographic evidence of union by many weeks, so early motion can be encouraged when clinical stability is ensured. While reduction of the fracture is attempted, the radiographic findings of angulation and lack of apposition are much more obvious than an error of rotation. The cortical thickness at the fracture site, of both proximal and distal fragments should match for a reduction without rotational deformity. Otherwise rotation at the fracture may become obvious only after the fracture has clinically healed.

Oedema following a traumatic incident, will conceal the anatomical land marks. Percutaneous pinning is better attempted before oedema obliterates external landmarks. Oedema, can be controlled to a large extent by keeping the limb absolutely elevated. Otherwise, oedema once established will take 7-10 days to subside; sometimes a delay in fixation of 7 to 10 days is warranted. As per literature some form of fixation is most often indicated in the following instances: (1) when a displaced fracture involves a significant portion of the articular surface (exact reduction is necessary to restore smooth joint motion); (2) when a fracture is part of a major ligamentous or tendinous avulsion; (3) when a fracture is so severely displaced that interposition of tendons or other soft tissue prevents realignment by manipulation; (4) when multiple fractures are involved, and the hand cannot be held in the position of function without internal fixation; and (5) when a fracture is open (internal fixation allows wound care after surgery without loss of reduction).

Too many fragments in a severely comminuted closed fractures usually should not be opened because internal fixation of multiple fragments may be impossible. Limited percutaneous pinning occasionally is

indicated. Dislocations in the acute phase can be managed readily by manipulation and early function can be restored. Many dislocations can be reduced, and protected function through “buddy taping” to an adjacent finger generally provides a good result. It is important, however, to examine for associated ligamentous injury or tendon avulsion.

Surgical intervention is commonly indicated in these conditions:

Open Fractures and Dislocations: the wounds are thoroughly cleansed, debrided before a decision is taken to opt for permanent fixation or provisional external fixation is done. In open fractures whatever fixation is done, it should allow wound inspection and mobility as far as possible. Non traumatized areas are better preserved, sparing them and not to use them for open fracture reduction and fixation, as the non traumatized areas are free from contaminated planes and thus infections. If the hand is severely traumatized, additional incisions usually are unnecessary to expose the fracture. Fractures should be fixed under direct vision or percutaneously to maintain normal architectural position. In segmental defects of tubular bones, spacers maintain the shape and length and may help prevent collapse while the wound is healing.

Careful judgment is required, whether the wound is sufficiently debrided and clean enough to permit primary closure, or whether it should be left open for repeat débridement and irrigation and dressings. If Primary closure is not feasible the wound can be reevaluated in the operating room and plans made at that time for closure. The goal is to close the wound within the first 4 to 5 days before granulation tissues form and contractures develop.

Most of the intra articular fractures like Bennets fractures are treated with operative fixation, including closed reduction and percutaneous fixation, open reduction and internal fixation.⁽¹⁾ Outcome can be evaluated by experienced pain, functional outcome and radiographic indications for arthritis and functional tests including grip and pinch measurement and radiographic analysis for post-traumatic arthritis, using the modified Eaton-Littler classification. As per a series presented by Greeven AP et.al., patients with extra-articular fractures and patients with intra-articular fractures were treated in groups. No clinically important difference was found for pinch strength. The described fixation procedure results in a stable fixation of the fracture fragments, and no secondary dislocation of the fracture occurred. Fractures consolidated within 32 (26-50) days and no new fractures were observed. These results suggest that this technique of treatment with closed reduction and percutaneous fixation with inter metacarpal Kirschner wires can be safely used in the treatment of extra-articular fractures as well as intra-articular fractures at the base of the first metacarpal⁽²⁾.

Lee SK et. al described a modified retrograde percutaneous intramedullary multiple Kirschner wire fixation for treatment of unstable displaced metacarpal neck and shaft fractures. Their average follow up duration was 13 months and concluded that retrograde intramedullary K-wire fixation technique is an acceptable alternative modality for the treatment of unstable displaced metacarpal fractures. This straightforward technique can facilitate early hand mobilization, correct the deformity, and provide good clinical and radiographic outcomes⁽³⁾.

Neck of fifth metacarpal fractures develop much severe angulation. Deformities or shortening can be a surgical indication for fifth metacarpal neck fracture. However, the outcomes of retrograde intramedullary pinning, have not been compared with those of antegrade intramedullary pinning. Antegrade intramedullary pinning has some clinical advantages during the early recovery period over percutaneous retrograde intramedullary pinning for treatment of displaced fifth metacarpal neck fractures, but the advantages are not evident at 6 months postoperatively. In addition, there are no differences in radiographic outcomes between antegrade and retrograde techniques. For patients who require an early return of hand function, such as athletes, antegrade intramedullary pinning can be recommended. Otherwise, treatment could be decided according to the surgeon's preference and patient status, and based on consideration of the need for an accessory procedure for pin removal after antegrade intramedullary pinning⁽⁴⁾.

The following issues need to be considered while attempting for surgical management of metacarpal fractures, like to determine the need for operative treatment of metacarpal fractures, the position of immobilization for nonoperative treatment of fifth metacarpal fractures, assess the differences between planes for intramedullary pinning and transverse pinning of displaced metacarpal fractures, compare the advantages of plating and pinning for treatment of displaced metacarpal fractures, recognize appropriate timing and treatment of open metacarpal fractures⁽⁵⁾.

II. MATERIALS AND METHODS

The study cohort consist of 105 cases of compound meta carpal and phalangeal fractures from Type I to IIIB Gustilo –Andersons classification. We have the following inclusion and exclusion criterion for the study. The inclusion criterion are Open fractures of hand, fractures of metacarpals and phalanges, fractures with or without bone loss. The exclusion criterion are, traumatic amputation, near total amputations, associated tendon injuries, associated vascular injuries, more than one day old open fractures, severely contused skin margins. The case distribution with the said inclusion criterion is given in Table 1.

Evaluation of cases and pre operative management: Each of the case in the study group is evaluated for any co existing life threatening injuries. The patients are evaluated for their fitness to under go surgery and Radiographs are taken. The time taken for evaluation is utilized to give a thorough lavage to the compound wound in the ER and wound is dressed. Inj. Cefuroxime is given before the lavage. Up on establishing the surgical fitness cases are posted for internal fixation with K wires. The size of the K wire is decided per operatively to follow the clinical and radiological parameters as described in the introduction.

Operative Procedure: The anaesthetized patient is given a thorough lavage again and the intact skin is scrubbed and painted with 10% Povidone iodine. All the planes of the compound wound are explored bluntly to know the exact plane of the compound wound and to explore and to know the extent of comminution and periosteal stripping over the fracture fragments. All the loosely hanging soft tissues and contused soft tissue are excised liberally. Once the tissue of doubtful viability is excised, the fracture reduction is attempted with gentle traction. The diameter of the K wire for appropriate size is determined under image intensifier which fills the medullary canal to produce a snug fit. The maneuver to cause acute angulation at the fracture site, will create an opening at the fracture site and brings the fracture close to the dorsal aspect. Open fractures are reduced and fixation is done with K wire fixation, The K wire is introduced through the fracture site, passes through one fragment in its entirety and then the fracture is reduced and held in position. The K wire is introduced through the fracture site and anchored in the subchondral bone.

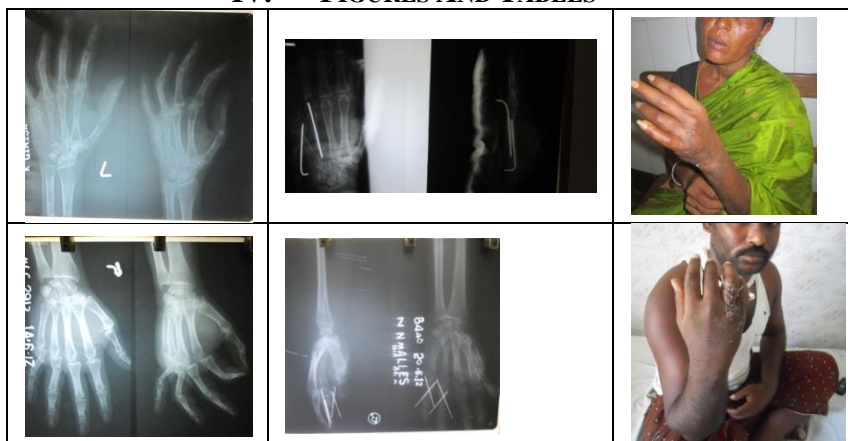
The K wire is anchored to the subcortical bone of the lengthier fragment. The bone defects at the fracture site due to comminution tend to have gap which persist even after K wire fixation, such fracture needs another K wire for parallel fixation to the adjacent meta carpal. The rotational deformity at the fracture site can be prevented by clinical assessment at the nails, and also under image intensifier by aiming for uniform cortical thickness at the fracture site. Both the assessments are done before the final fixation of the K wire. Open fractures which are of Type IIIB and for any type of open wounds where viability is doubtful, are debrided one more time after 48 hours, and same kind of K Wire fixation is done.

All the fractures are followed up with regular dressings and inspection of the compound wound every 48hours. All the dressings are done with ample padding for absorption of inflammatory exudates and to prevent soddening of the skin. Patients are discharged on eleventh post operative day and advised to come for weekly follow ups for two weeks. The patients are advised to continue movements at the interphalangeal and metacarpophalangeal joints which ever is free to move. The k wires are removed after twenty eighth postoperative day.

III. RESULTS

The results are assessed with basically three parameters. The soft tissue healing, retained range of movements, and fracture union. The results are given in the Figures and Tables section. The soft tissue healing is noticed as early as the dressings are turning dry. Type I to Type IIIA wounds are more amenable for closure at the first instance provided they are not associated with largely raised flaps of their attachments. Range of movements are initiated as tolerated by patient within first post operative week, irrespective of wound healing. The study group consisted of following case distribution as per the compound nature of the fractures. Type I-28, TypeII-31, Type IIIA-27, Type IIIB-19. Basing on the fracture site the distribution is Metacarpals- 29, Phalanges-53, Combined-23. The Range of Movements that could be regained are measured at the end of third post operative week and fifth post operative week at different joints. The third post operative week and fifth post operative week results respectively are ROM at MCP Joint 40° & 80° in 23 cases, PIP Joints 30° & 70° in 48 cases, DIP Joints 30° & 60° in 19 cases. The range of movements in remaining cases is very slow to progress beyond 50% of range of movements possible at that particular joint.

IV. FIGURES AND TABLES



GA grade	Fractures	Site	Fractures	ROM at Joints	3 weeks	5 weeks	Fractures
Type I	28	Metacarpal	29	MCP Joint	40	80	23
TypeII	31	Phalanges	53	PIP Joints	30	70	48
Type IIIA	27	Combined	23	DIP Joints	30	60	19
Type IIIB	19						

V. CONCLUSION

The compound fractures of the hand are to be treated with meticulous debridement and internal fixation as soon as the fractures are clean enough or converted to be a clean fracture. Comminuted fractures need to be fixed with additional anchorage to minimize angular deformities that can occur due to loss of bone either due to the fracture pattern or loss of bone during debridement. The range of movements are better started as soon as the patient tolerates pain and fixation is strong enough to allow passive and non weight lifting exercises at MCP and IP joints. In case of extensive compound wounds, another debridement should always be planned before attempting fracture fixation. Repeat debridements are necessary when extensive flap elevation is noted during first debridement. The functional recovery can be achieved if only the fractures are safely fixed with good soft tissue cover.

REFERENCES

Journal Papers:

- [1]. Guss MS, Kaye D, Rettig M., Bennett Fractures A Review of Management. Bull Hosp Jt Dis (2013). 2016 Sep;74(3):197-202.
- [2]. Greeven AP¹, Alta TD, Scholtens RE, de Heer P, van der Linden FM, ICLOSED REDUCTION INTERMETACARPAL KIRSCHNER WIRE FIXATION IN THE TREATMENT OF UNSTABLE FRACTURES OF THE BASE OF THE FIRST METACARPAL., Injury. 2012 Feb;43(2):246-51. doi: 10.1016/j.injury.2011.10.038. Epub 2011 Dec 9.
- [3]. Lee SK¹, Kim KJ, Choy WS, Modified retrograde percutaneous intramedullary multiple Kirschner wire fixation for treatment of unstable displaced metacarpal neck and shaft fractures. Eur J Orthop Surg Traumatol. 2013 Jul;23(5):535-43. doi: 10.1007/s00590-012-1036-6. Epub 2012 Jul 7.
- [4]. KIM JK¹, KIM DJ, ANTEGRADE INTRAMEDULLARY PINNING VERSUS RETROGRADE INTRAMEDULLARY PINNING FOR DISPLACED FIFTH METACARPAL NECK FRACTURES. CLIN ORTHOP RELAT RES. 2015 MAY;473(5):1747-54. DOI: 10.1007/s11999-014-4079-7. EPUB 2014 DEC 11.
- [5]. Bloom JM¹, Hammert WC. Evidence-based medicine: Metacarpal fractures. Plast Reconstr Surg. 2014 May;133(5):1252-60. doi: 10.1097/PRS.0000000000000095.
- [6]. Windolf J1, Rueger JM, Werber KD, Eisenschenk A, Siebert H, Schädel-Höpfner M., [Treatment of metacarpal fractures. Recommendations of the Hand Surgery Group of the German Trauma Society]. Unfallchirurg. 2009 Jun;112(6):577-88; quiz 589. doi: 10.1007/s00113-009-1630-1.
- [7]. Henry MH, Fractures of the proximal phalanx and metacarpals in the hand: preferred methods of stabilization., J Am Acad Orthop Surg. 2008 Oct;16(10):586-95.

Dr V.V.Narayana Rao "Compound fractures of hand: Study on fracture fixation and functional recovery" IOSR Journal of Dental and Medical Sciences (IOSR-JDMS), vol. 17, no. 6, 2018, pp 30-33