

## **The long-term observation of an avulsed tooth and extrusive luxation of teeth: an over 28-year follow-up case report**

**Shiro Kubo**

*Kubo dental clinic 3-2-48 Minato, Wakkanai city, Hokkaido, JAPAN*  
*kubo-shi@sage.ocn.ne.jp*

---

**Abstract:** *External inflammatory resorption and replacement resorption (ankylosis) of the root are complicating factors that may result from traumatic dental injuries during replantation or repositioning of avulsion and extrusive luxation cases. This is a case of a patient who was followed-up for over 28 years following avulsion of a tooth and extrusive luxation of four teeth and outlines factors that influence the occurrence of resorption.*

**Keyword:** *Avulsion teeth, extrusive luxation teeth, root resorption, long-term follow-up*

---

Date of Submission: 18-06-2018

Date of Acceptance: 03-07-2018

---

### **I. Introduction**

Traumatic dental injuries (TDI) are often unexpected. Common causes of TDI include falls, car accidents, violence, and sports, which often cause serious TDI. This case involved alveolar fracture, avulsed tooth, extrusive luxation of teeth, and laceration of soft tissues. Avulsion and extrusive luxation of permanent teeth are common in young dentition, especially those occurring in the maxillary incisors. The outcomes of an eventual replantation procedure are almost entirely dependent upon the extra-alveolar period and extra-alveolar handling (1). However, TDI are often not properly treated in the first few hours following trauma. In the present case, the tooth was not treated with proper extra-alveolar handling immediately following the accident. The replanted avulsed tooth was exfoliated 13 years following replantation due to an inflammatory and replacement resorption of the root. During the healing of the periodontal ligament (PDL) following extrusive luxation of the four incisors, no evidence of external root resorption was found. However, few studies reported long-term successful follow-up. This is an over 28-year retrospective observation of avulsed and extrusive luxation of teeth of a patient. The key factors contributing to positive outcomes included keeping the surface of the root wet, avoiding infection, and prompt management following the accident.

### **II. Case report**

A 15-year-old boy presented to the dental clinic with a history of trauma sustained in a sports accident occurring over an hour prior to his presentation. The accident was caused by a baseball hitting his mouth, which resulted in avulsion of his right maxillary central incisor. The tooth was brought along to the clinic after it was picked up by the patient and kept in a handkerchief. Clinical examination revealed mobility of the two left maxillary and the two left mandibular incisors, indicating that they were nearly avulsed. The fracture of alveolar process involved the maxillary three incisors. An intra-oral periapical radiograph was performed to rule out any broken teeth or bony segments in the sockets. His upper lip was lacerated (Fig. 1).

The root of the avulsed tooth was washed off with a physiological solution and the canal of the right maxillary central incisor was filled with gutta-percha points. The socket was gently irrigated with saline solution and the right maxillary central incisor was replaced in the socket. Following the reposition of the alveolar fracture, the four extrusive luxated teeth were repositioned and fixed using a splint and the upper lip was sutured (Fig.2).

Subsequently, the occlusion was checked to confirm that excessive force was not being exerted on the five injured teeth. Fixation was removed after 6 weeks and the two left maxillary incisors were filled with gutta-percha points 2 months later. Since a periapical lesion was observed on controlled x-ray examination, the two left mandibular incisors were filled with gutta-percha points 4 months afterward (Fig. 3).

The patient was followed-up every 6 months. At the 1-year follow-up examination, no clinical problems were detected (Fig. 4). From year 2 to year 12 following replantation, development of replacement and inflammatory root resorption were observed in the right maxillary central incisor, as indicated by the slowly advancing resorption of the root. The right maxillary central incisor was exfoliated 13 years post-treatment (Figs. 5,6). The resin facing bridge was used to cover the exfoliated missing space. At the 28-year and 8-month

follow-up examination, replacement resorption and resorption of gutta-percha point in the alveolar bone of the right central incisor were observed. The two left maxillary incisors and two mandibular incisors remained intact (Figs. 7,8).

### **III. Discussion**

Avulsion and extrusion of permanent teeth are the most common injuries in young dentition, where root development is incomplete and the periodontium is resilient (1). In the present case, the root of the right maxillary avulsed incisor was covered with sand from the baseball field, where it was picked up by the patient's dirty fingers and kept in a handkerchief until visiting the dental clinic over an hour following accident. It is recommended to place an avulsed tooth in milk when it cannot be replanted immediately. Milk is a reasonable good storage medium due to its osmolarity and pH. In addition, it was reported to preserve PDL cells for up to 8 hours (2). Dental avulsion is a dental emergency, in which prompt management affects the prognosis of the tooth. The outcome of an eventual replantation procedure is almost entirely dependent upon the extra-alveolar period and extra-alveolar handling (1). Most resorptive processes are diagnosed within the first 2-3 years as in this case. However, in rare cases, resorptive processes can be diagnosed 5 or 10 years later (3). The long-term prognosis of teeth replantation can significantly vary greatly.

Following avulsion of permanent incisors there are 3 treatment alternatives including immediate replantation, delayed replantation, or no replantation. In the case of extended extra-alveolar periods in adults, an alternative replantation procedure is possible, whereby the replantation becomes "implantation". In the present case, the canal was filled with gutta-percha points prior to replantation; however, the tooth was not stored in a 20% fluoride solution for 20 minutes in order to make the root surface partly osteoclast resistant. Had the avulsed tooth been treated with a fluoride solution, the tooth may have survived longer than 13 years. The rationale for the fluoride soak is based on evidence that it can delay ankylosis, however, it cannot prevent it (1). However, despite the availability of various treatment, it is currently that avulsed teeth are often exfoliated within a few years post-treatment (4). Another possible reason for replantation failure is bacterial contamination of the PDL. Following accidental trauma, teeth are often covered with debris from sand, glass, and small stones. Bacterial contamination of the necrosed tissues, coupled with damaged cementum, results in external inflammatory resorption of the root (5). This debris must be washed off gently using a physiological solution and not scrubbed. Antibiotic coverage was prescribed in the current case (Cephalosporin 600mg for 5 days) and inflammation was controlled.

The PDL of the avulsed right maxillary incisor, left maxillary, and mandibular incisors, which were neatly avulsed could have stretched and split in half (half staying on the root surface and the other on the inner walls of the alveolar socket). A key distinction between avulsion and extrusive luxation is whether the root surface is dry and infected by debris, which can affect prognosis. In the present case, the four roots with extrusive luxation were protected by blood clots in the mouth, which played a major role in avoiding damage of the PDL and kept the roots moist rather than dry as in case of avulsion. Over 28 years (344 months) later, the four extrusive luxation teeth did not show signs of root resorption or ankylosis. In this case, ideal periodontal healing was performed, thus, complications were not observed. In order to maintain optimal cell metabolism, depleted metabolites should be replaced within 1 hour following avulsion. Delayed replantation can lead to necrosis of the PDL cells, loss of the cementum, and root resorption following implantation. The success of teeth replantation depends on the vitality of the cells remaining on the root surface. Avulsed teeth that are replanted within 15 minutes are reported to have good prognosis (6).

Immediate endodontic therapy with pulpal extirpation and calcium hydroxide root canal dressing commonly arrests inflammatory root resorption (1). The root canal was filled with calcium hydroxide, which exerted an anti-bacteria effect (7). In the present case, endodontic therapy was started 2 and 4 months following replantation of the four extrusive luxation of teeth and the root canals were filled with gutta-percha points. It was late for a root canal treatment; however, the four roots did not affect the prognosis. The prognosis for extrusive luxation of teeth with respect to pulp and periodontal healing depends upon the stage of root development at the time of injury. Generally, in extrusive luxation of teeth, an open apex has better prognosis compared to a closed apex (1). Although the four teeth in this case had closed apices, the prognosis was good.

It was previously believed that keeping the avulsed tooth moist was key to maintaining the vitality of the root cells (8), which gave rise to storage media recommendations including water, mouth saliva, and milk. To maintain the PDL integrity and viability, avulsed teeth should be stored immediately in an appropriate solution until replantation (9). The most popular medium used is called Hank's Balanced Salt Solution (10,11), which has all metabolites such as calcium, phosphate ions, potassium, and glucose that are necessary to maintain normal cell metabolism for long periods of time.

Some dentists recommended immediate replantation as the best treatment for an avulsed tooth. However, this can be difficult for non-experts due to several reasons. When immediate replantation is not possible, the teeth should be placed in an appropriate storage solution until they are brought to the dentist.

Preventive sports medicine has recently attracted a lot of attention. The best method for preventing serious teeth injuries includes using protective gear such as helmets and mouth guards (12). It is important for dentists, primary school teachers, physical education teachers, and primary healthcare professionals to educate patients and students on handling avulsed teeth (13). It is recommended to place an avulsed tooth in milk till it is brought to the dentist when implantation cannot be performed immediately. Although recommended, immediate transplantation of the avulsed tooth is not always possible due to concomitant injuries of patients at the time of accidents and the lack of knowledge for managing such injuries at the site of accidents.

#### IV. Conclusion

An over 28-year follow-up of a replanted avulsed tooth and repositioned extrusive luxation of teeth can result in variable outcomes with the possibility of root resorption and ankylosis, which can occur several years following the procedures. The key to maintaining good outcomes of injured teeth is to avoid the damage of the PDL.

#### References

- [1]. Andreasen JO, Andreasen FM. Essential of traumatic injuries to the teeth. Louis. 2nd Edn. Munksgaard, Copenhagen. 2000; 85-140.
- [2]. Hiltz J, Trope M. Vitality of human lip fibroblast in milk, hanks balanced salt solution and viaspan storage media. Endod Dent Traumatol. 1991;7:69–72.
- [3]. Anreasen JO, Borum MK, Jacobsen HL, Andreasen FM. Replantation of 400 avulsed permanent incisors. 4. Factors related to periodontal ligament healing. Endod Dent Traumatol. 1995;11:76–89.
- [4]. Andreasen JO, Borum KM, Jacobsen HL, Andreasen FM. Replantation of 400 avulsed permanent incisors. 1. Diagnosis of healing complications. Endod Dent Traumatol.1995;11:51-8.
- [5]. Tronstad L. Root resorption – etiology, terminology and clinical manifestations. EndodDent Traumatol.1988;4:241-52.
- [6]. Andersson L, Bodin I. Avulsed human teeth replanted within 15 minutes: a long-term clinical follow-up study. Endod Dent Traumatol. 1990;6:37–42.
- [7]. BvstromA,Claesson R, Sundgavist G. The antibacterial effect of camphorated paramonochlorphenol, camphoratedb phenol and calcium hydroxide in the treatment of infected root canals. Endod Dent Traumatol1985;1:170–177.
- [8]. Andreasen JO. Etiology and pathogenesis of traumatic dental injuries, Eur J Oral Sci. 1970;78:329–342.
- [9]. Gopikrishna V, Thomas T, et al. A quantitative analysis of coconut water: a new storage media for avulsed teeth. Oral Surg Oral Med Oral Pathol Oral Radiol Endod.2008;105:e61-5.
- [10]. Trope M, Freidman S. Periodontal healing of replanted dog's teeth stored in Viaspan, milk, Hank's balanced salt solution. Endo Dent Traumatol. 1992;8:183–1888.
- [11]. Flores MT, Andersson L,Andreasen JO, Bakland LK, Malmgren B, Barnett F et al. Guidelines for the management of traumatic injuries. II. Avulsion of permanent teeth. EndodDent Traumatol.2007 ;23:130-6.
- [12]. Lloyd JD, Nakamura WS, Maeda Y, Takeda T, Leesunngbok R, Lazarchik D et al. B. Mouthguards and their use in sports: Report of the 1<sup>st</sup>international sports dentistry workshop, 2016EndodDent Traumatol.2017;33:421-426.
- [13]. Townsend J, King B, Ballard R, Armbruster P, Sabey K. Interdisciplinary approach to education: preparing general dentists to manage dental trauma. EndodDent Traumatol. 2017;33:143-8.

#### FIGURES

Figure 1: Mouth and radiographic view on arrival at the dental clinic

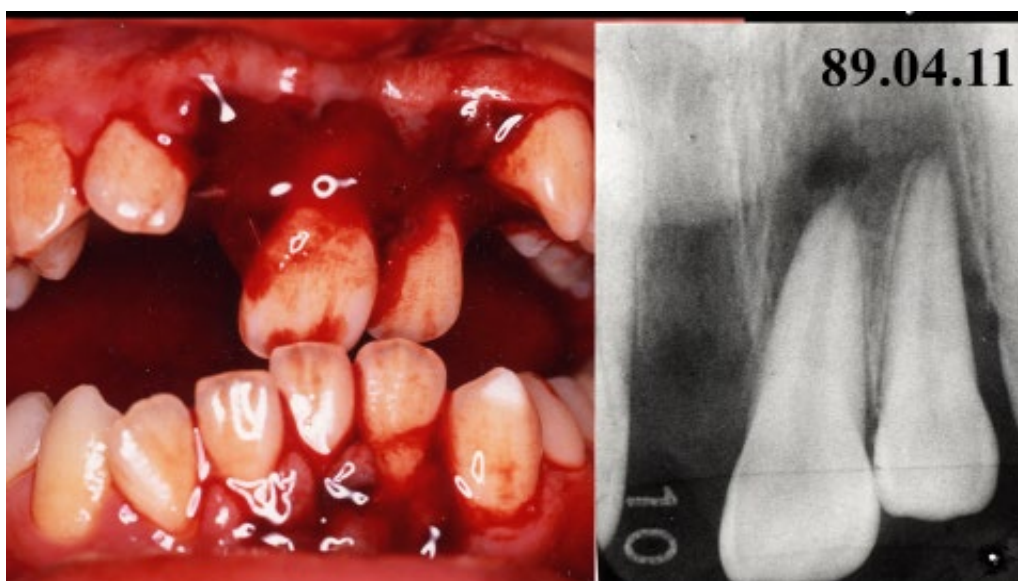


Figure 2: Post-operative photograph of the patient: sutures of the lip and fixed with a splint

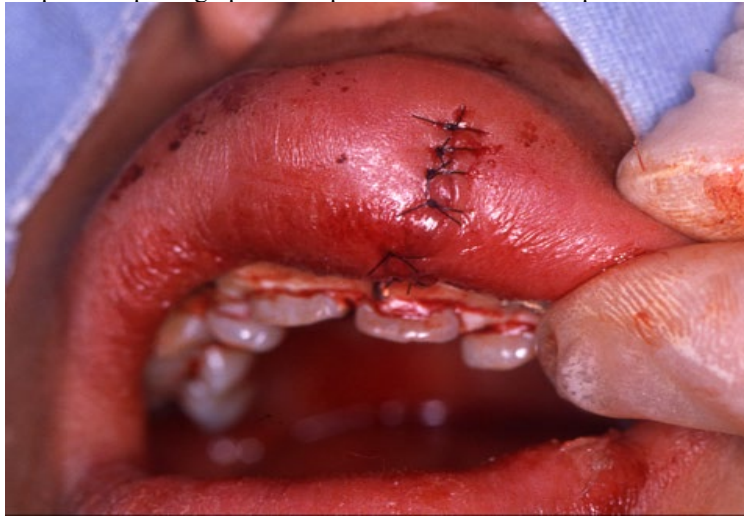

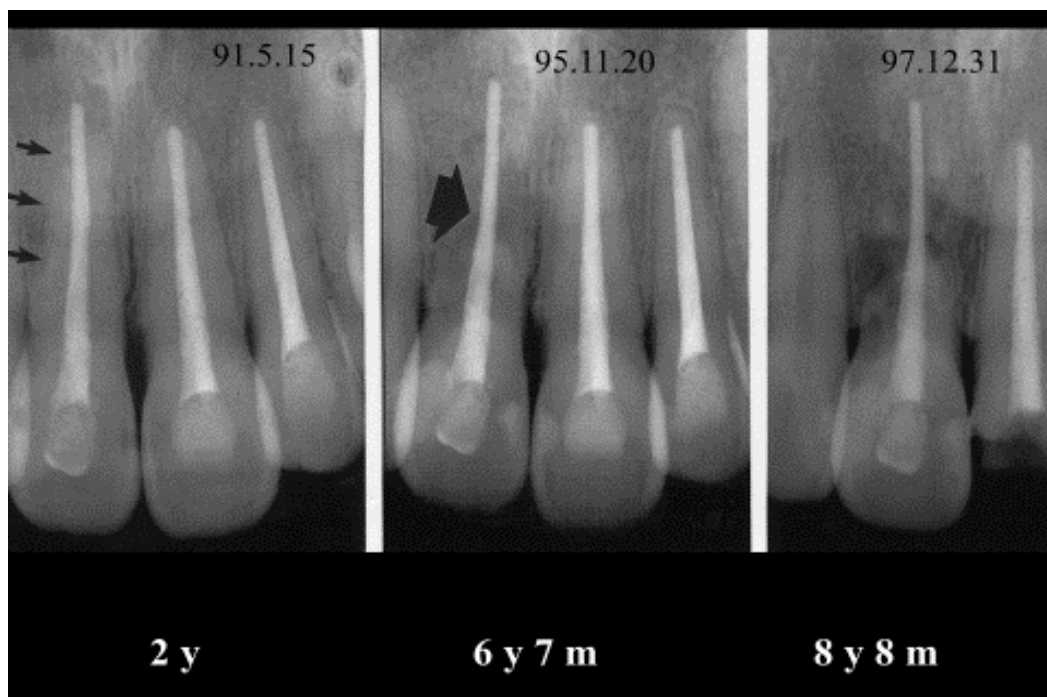
Figure 3: Imaging shows the periapical lesion observed on the two left mandibular incisors, 4 months later

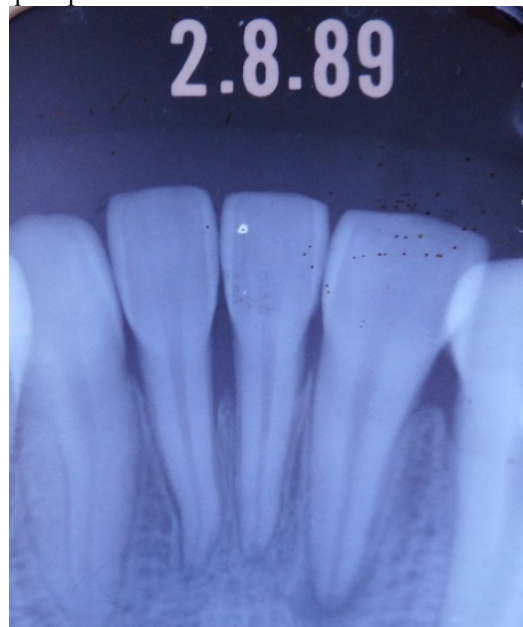
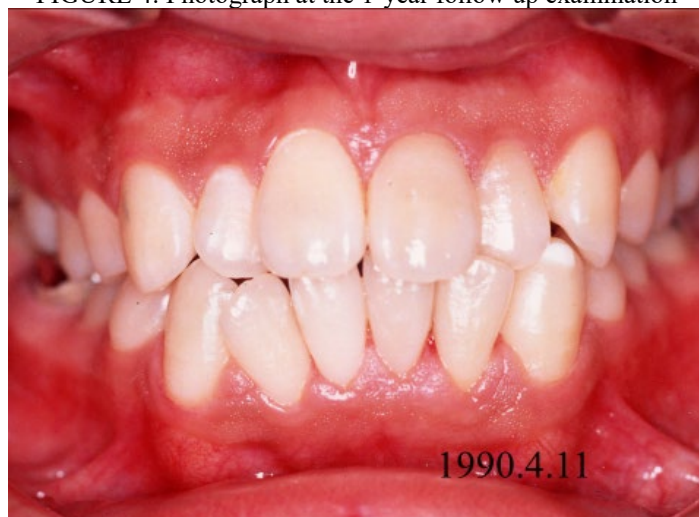
FIGURE 4: Photograph at the 1-year follow up examination



**FIGURE5:** Imaging shows the development of replacement and inflammatory resorption(arrow) from 2 years to 8 years and 8 months



**FIGURE 6:** Exfoliated of the right maxillary incisors after 13 years

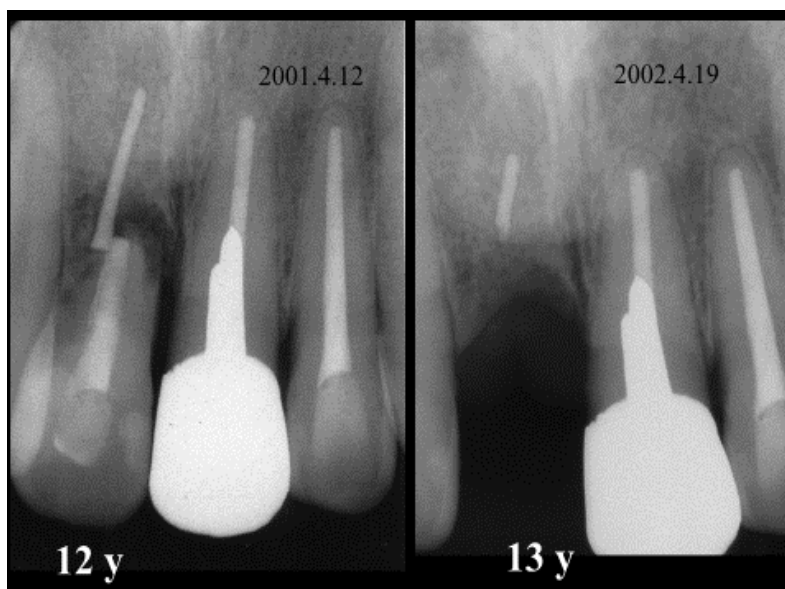




FIGURE 7: At 28 years and 8 months following treatment, the progress of replacement resorption of root and gutta-percha point. The two left maxillary incisors did not show root resorption.

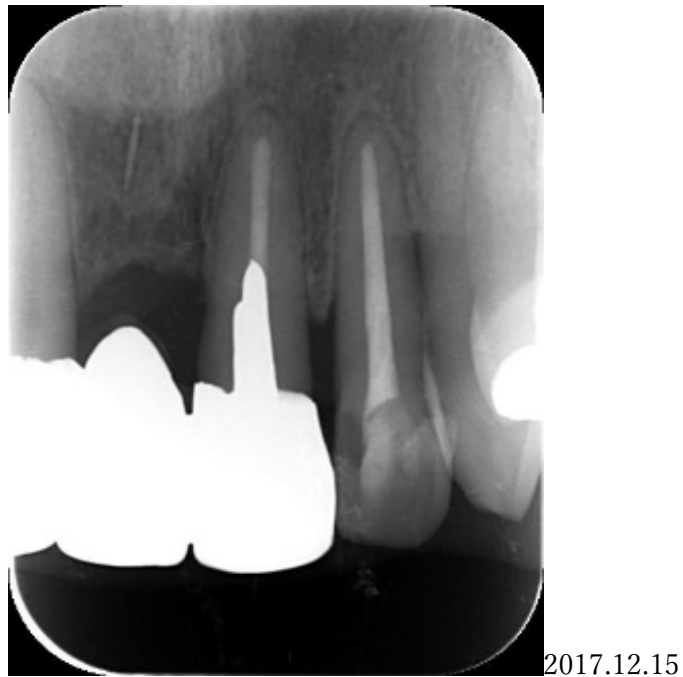

FIGURE 8: Image shows the two left mandibular incisors intact 28 years and 8 months later

