

Chest Wall Tumors of Cartilage Origin

Miktat Arif Haberal, Md,¹ Erkan Akar, Md,² Ozlem Sengoren Dikis, Md³

¹Health Sciences University Bursa Yuksek Ihtisas Training and Research Hospital, Department of Thoracic Surgery, Bursa, Turkey

²Health Sciences University Bursa Yuksek Ihtisas Training and Research Hospital, Department of Thoracic Surgery, Bursa, Turkey

³Health Sciences University Bursa Yuksek Ihtisas Training and Research Hospital, Department of Pulmonary Diseases, Bursa, Turkey

Corresponding Author: Miktat Arif Haberal, Md,

Abstract:

Introduction: Cartilage-forming tumors as a group are the most common primary bone tumors; this is largely due to the common occurrence of asymptomatic benign lesions.

Objectives: The purpose of this study is to retrospectively review our experience with chest wall resections and reconstruction and determine the postoperative complications.

Methods: Among 194 cases of chest wall tumors treated between 2010 and 2016, 26 cases of cartilage origin were retrospectively investigated. The results were analyzed using the Fisher's exact test.

Results: The mean age of the study population was 45.1 (11.1) years. Thirteen (50%) patients were male and 13 (50%) were female. The mass was located on the right side in 19 (73%) patients on the left side in 7 (27%) patients. It was found that 8 patients (31%) masses were located in anterior chest wall, 6 patients (23%) in lateral chest wall, and 12 patients (46%) in posterior chest wall. Nineteen (63%) masses were benign whereas 7 (37%) were malignant.

Conclusions: Malignancy should be strongly considered in chest wall tumors. Detailed history and physical examination are required for diagnosis. Treatment success depends on an adequate tumor resection.

Date of Submission: 16-06-2018

Date Of Acceptance: 02-07-2018

I. Introduction

The chest wall consists of a variety of tissues, including skin, fat, lymphovascular vessels, fascia, muscle, bone, and cartilage. Primary chest wall tumors constitute only 1% to 2% of all thoracic neoplasms.^[1] They are best classified according to their tissue of origin (bone or soft tissue), and are further subdivided as benign or having a malignant potential. Approximately 60% of primary chest wall tumors are malignant, with malignancy risk being increased at the extremes of age.^[2] Approximately 55% of these malignant tumors arise from bone or cartilage and 45% from soft tissue.^[3]

The purpose of this study is to retrospectively review our experience with chest wall resections and reconstruction, and to investigate postoperative complications.

II. Methods

Among 194 chest wall tumor cases treated between 2010 and 2016, 26 cases of cartilage origin were assessed. The patients' medical records were retrospectively analyzed. Age, gender, symptoms and location of disease, radiological examinations, diagnosis and treatment characteristics, complications, length of stay, and morbidity and mortality rates were investigated. Primary lung, pleural, and mediastinal tumors with chest wall invasion as well as metastatic lesions were excluded. The main diagnostic methods included chest X-ray, computed tomography (CT), magnetic resonance imaging (MRI), positron emission tomography (PET-CT), needle aspiration, tru-cut biopsy, and incisional and/or excisional biopsy.

Ethics committee approval was received for this study from the ethics committee as a decision number 2017-10/43/KA EK Uludag University Faculty of Medicine Ethics Committee.

Statistical analysis

Continuous variables were expressed as mean \pm standard deviation and categorical variables as number and percentage. The comparisons were made with Fisher's exact test (4). $p < 0.05$ was considered statistically significant.

III. Results

The mean age of the study population was 45.1 (11.1) years. Thirteen (50%) patients were male and 13 (50%) were female. The mass was located on the right side in 19 (73%) patients and on the left side in 7 (27%) patients. The main symptoms included a painless swelling ([n=16], 62%), a painful swelling ([n=10], 38%), cough ([n=7], 27%), dyspnea ([n=6], 23%), and pleural effusion ([n=4], 15%).

Eight (31%) masses were located in anterior chest wall, 6 (23%) were in lateral chest wall, and 12 (46%) were in posterior chest wall. Three (12%) lesions were located in sternum, 16 (61%) in rib cartilage, and 7 (27%) in the ribs (Figure 1, 2).

The histopathological distribution of lesions with a benign cartilaginous origin (n=19) were as follows: 8 (42%) were chondroma, 1 (5%) were chondroblastoma, and 10 (53%) were osteochondroma. All (100%) of 7 malignant masses of cartilage origin were chondrosarcoma (Table 1).^[5]

Five (19%) patients underwent incisional biopsy and medical treatment, 21 (81%) surgical excision and/or drainage, 5 (19%) tube thoracostomy, 5 (19%) muscle flap insertion, 6 (23%) synthetic graft (mesh) placement, and 2 (8%) reconstruction with myocutaneous flaps (Table 2) (Figure 3).

The morbidity rate was 12% (n=3) but no death was observed. The most common complications were respiratory failure ([n=2], 8%) and wound infection ([n=1], 4%). The average length of hospital stay was 7.5 (2.1) days.

IV. Discussion

Chest wall tumors are grouped into 3 groups, namely malignant, benign, and neoplastic. Although the local invasion of chest wall by any metastatic lesion or adjacent organ tumors constitutes the majority of the chest wall masses, primary chest wall tumors constitute 5% of all thoracic neoplasms and 1-2% of all primary tumors.^[6] Primary malignant tumors are originated from soft tissues, bone, and cartilage.^[7] In our study, 26 masses originated from cartilage. Among these, 19 (73%) were benign cartilaginous masses and the remainders ([n=7], 27%) were malignant masses of cartilage origin.

The incidence of malignant lesions among primary chest wall tumors has been reported to be 50-80%. The percentage of malignant soft tissue tumors is higher than malignant bone and cartilage tumors.^[8] Fifty percent of primary malignant chest wall tumors originating from bone and cartilage involve ribs, 30% involve the scapula, and 20% involve the sternum and clavicle.^[9] They are more common in sternal body, manubrium sterni, and clavicle.^[10] In this study, malignant lesions constitute 27% of masses of cartilage origin. Chondrosarcoma was the most common malignant mass of cartilage origin.

Primary chest wall tumors are two times more common in males than females. Benign chest wall tumors are seen 14 years earlier than malignant chest wall tumors. In other words, the average age of onset is 26 years for benign tumors and 40 years for malignant tumors.^[11] In our study, the number of males and females were equal (n=13 for each), with a male-to-female ratio being 1.00.

Chest wall tumors with subcutaneously location can be asymptomatic but also cause swelling, pain, ulcers, and infections.^[9] Tumors of bone origin may cause pain due to periosteal involvement or stress. In these tumors pain can be the first symptom. Fast-growing lesions are more likely to cause pain and are often indicative of malignancy.^[7] All malignant tumors can produce pain during their course. However, two-thirds of benign tumors are painful.^[6,8,11] In our study, the main symptoms were painless swelling ([n=16], 62%), painful swelling ([n=10], 38%), cough ([n=7], 27%), dyspnea ([n=6], 23%), and pleural effusion ([n=4], 15%).

A detailed history and physical examination are required for diagnosis. The first step of radiological diagnosis is chest X-ray. CT is the most effective imaging method for the diagnosis of chest wall tumors. It is useful for showing masses originating from ribs or damaging bony cortex, calcifications within the mass, and lung metastases. MRI plays an integral role for making the diagnosis and devising the treatment plan. It effectively shows tumor's soft tissue involvement, bone marrow infiltration, intraspinal spread, and relation to mediastinal structures.^[12] PET-CT is an effective method for assessing the spread of tumors, especially sarcoma, and biological heterogeneity, stage, and response to treatment of a variety of tumors.^[7] In our study, the main methods used for diagnosis were chest X-ray, CT scanning, MRI, PET-CT, needle aspiration, tru-cut biopsy, incisional and/or excisional biopsy. However, chest X-ray and CT were used for the majority of cases.

The most common benign tumors of the chest wall are osteochondroma, chondroma, fibrous dysplasia, and eosinophilic granuloma. Osteochondroma constitutes 50% of all benign rib tumors. It originates from the metaphyseal region of rib. Calcification in the periphery of a mass can be radiologically visible. Tumors arise in childhood and will continue to grow until full maturation of the skeletal system is reached. Resection is recommended for osteochondromatosis occurring after puberty. If an asymptomatic mass detected before puberty becomes symptomatic or starts to grow, resection should be performed in contemplation of a malignant degeneration.^[6,9] In our study, while osteochondroma was the most common mass of bone or cartilage origin ([n=10], 53%), the second most common mass of cartilage origin was chondroma ([n=8], 27%).

Although radiographic imaging can identify many types of bone tumors, a tissue biopsy is often used to confirm the diagnosis, to rule out metastatic lesions, or when surgery is not primarily considered. Techniques for obtaining tissue samples include percutaneous core needle biopsy, incisional biopsy, and excisional biopsy. Fine-needle aspiration biopsy is not preferred in the diagnosis of primary bone or cartilage tumors. It is usually used to evaluate chest wall metastases of a known malignancy.^[8] The success rate of percutaneous needle biopsy for making the diagnosis of musculoskeletal tumors has been reported as 92%.^[7,13-16] Incisional biopsy is the ideal choice for the diagnosis of the primary chest wall tumors greater than 5 cm that cannot be diagnosed by needle biopsy. Incisions should be planned considering the surgery to be conducted later. A diagnostic excisional biopsy with at least 2 cm surgical margin can be performed for tumors which are smaller than 5 cm. Benign tumors or malignancies requiring medical therapy (chemotherapy, radiotherapy, or combined) do not require any adjuvant surgery. If a primary malignant tumor is diagnosed, a second surgery with radical excision with wide margins is performed. In addition, reconstruction is applied whenever necessary.^[1]

An incisional biopsy is preferred for tumors with metastatic or hematologic origin and for those not amenable to extensive surgical resection. As it is difficult to differentiate benign and malignant bone and cartilage tumors preoperatively and intraoperatively, a wide resection with an adequate surgical margin should be done. Hence, reconstruction usually becomes necessary after resection. In patients with malignant lesions clinical symptoms are more severe, lesions diameter is greater, and patient age is advanced.^[17] Treatment varies from the one with surgical resection and reconstruction to a multimodality treatment consisting of chemotherapy and radiotherapy.^[15,16] Wide surgical resection represents the most efficacious treatment for most chest wall tumors. Thanks to diagnostic radiological tools, modern reconstruction methods, and perioperative care, wide surgical resection can be accomplished without excess morbidity and mortality. Furthermore, many types of prosthetic materials, muscle flaps, and free tissue flaps provide excellent functional and cosmetic outcomes.^[9,18] Patients can be successfully treated with an accurate diagnosis, wide resection, and appropriate reconstruction of major defects. In our study, 5 (19%) patients underwent incisional biopsy and medical treatment, 21 (81%) surgical excision and/or drainage, 5 (7%) tube thoracostomy, 5 (14%) muscle flap insertion, 6 (14%) synthetic graft insertion (mesh), and 2 (2%) reconstruction with myocutaneous flaps.

Primary-secondary chest wall tumors require a multidisciplinary approach. Biopsy methods should be carefully selected. Early diagnosis and aggressive surgical resection of most primary chest wall tumors result in excellent long-term outcomes, even cure. Long-term survival depends on complete resection with an adequate diameter.

V. Acknowledgments

The study was not financed by any organization.

Funding sources

This research did not receive any specific grant from funding agencies in the public, commercial, or not-for-profit sectors.

References

- [1]. Faber LP, Somers J, Templeton AC. Chest wall tumors. *Curr Probl Surg* 1995;32:661-747.
- [2]. Pass HI. Primary and metastatic chest wall tumors. In: Roth JA, Ruckdeschel JC, Weisenburger TH, editors. *Thoracic oncology*. 2nd edition. Philadelphia: W.B. Saunders; 1995.p.519-37.
- [3]. Burt M. Primary malignant tumors of the chest wall. The Memorial Sloan-Kettering Cancer Center experience. *Chest Surg Clin N Am* 1994;4:137-54.
- [4]. Fisher RA. On the interpretation from contingency tables, and the calculation of P. *J Royal Stat Soc* 1922;85:87-94.
- [5]. Mathew T, Robert Shen K. Primary Tumors of the Osseous Chest Wall and Their Management. *Thorac Surg Clin* 2017;27:181-193.
- [6]. Park BJ, Flores RM. Chest wall tumors. In: *General Thoracic Surgery*, Lippincott Williams&Wilkins. Philadelphia 2005.p.669-677.
- [7]. Refaely Y (Çeviren: Bostanci K). Göğüs Duvarı ve Sternum Tümörleri-Genel Bakış. In: *Erişkin Göğüs Cerrahisi (Adult Chest Surgery)*, Nobel Tıp Kitapevleri, İstanbul 2011.p.954-962.
- [8]. Pairolero PC. Chest wall tumors. In: *Sabiston & Spencer Surgery of the Chest Elsevier Saunders*. Philadelphia 2005.p.395-400.
- [9]. Toker A, Kalayci G, Göğüs duvarı ve sternum tümörlerinde cerrahi tedavi. In: *Göğüs Cerrahisi*. Bilmedya Grup, İstanbul 2001.p.547-557.
- [10]. Fontaine JP, Lukanich JM. (Çeviren: Bostanci K). Sternal ve Klaviküler Göğüs Duvarı Rezeksiyonu ve Rekonstrüksiyonu. In: *Erişkin Göğüs Cerrahisi (Adult Chest Surgery)*, Nobel Tıp Kitapevleri, İstanbul 2011.p.970-977.
- [11]. Graeber GM, Jones DR, Pairolero PC. Neoplasms of the chest wall. In: *Pearson's Thoracic & Esophageal Surgery*. Churchill Livingstone Elsevier Inc 2008;1291-1302.
- [12]. Cipriano A, Burfeind JW. Management of Primary Soft Tissue Tumors of the Chest Wall. *Thorac Surg Clin* 2017;27:139-147.
- [13]. Qasem SA, DeYoung BR. Cartilage-forming tumors. *Seminars in Diagnostic Pathology* 2014;31:10-20.
- [14]. Welker JA, Henshaw RM, Jelinek J, Shmookler BM, Malawer MM. The percutaneous needle biopsy is safe and recommended in the diagnosis of musculoskeletal masses. *Cancer* 2000;89:2677-2686.
- [15]. Yamaguchi U, Chuman H. Surgical Treatment of Primary Bone Chest Wall Tumors. *JSM Clin Oncol Res* 2014;2:1017.
- [16]. Çiledag N, Arda K, Aktas E, Aribas BK. Primary chest Wall tumors. *Turk Med J* 2010;4:65-70.
- [17]. Tukiainen E. Chest wall reconstruction after oncological resections. *Scand J Surg* 2013;102:9-13.
- [18]. Pascal A, Thomas, Brouchet L. Prosthetic Reconstruction of the Chest Wall. *Thorac Surg Clin* 2010;20:551-558.

Table 1. Analysis according to distributions histopatologic of chest wall masses.^[5]

Cartilage tumors	Male	Female	%	P value	Right	Left	P value
Chondroma	3	5	31	1.0000	6	2	0.1319
Chondroblastoma	-	1	4	1.0000	1	-	1.0000
Osteochondroma	6	4	38	0.1086	7	3	0.1788
Chondrosarcoma	4	3	27	0.3691	5	2	0.2861
Total	13	13	100	1.0000	19	7	1.0000

Table 2. Chest wall reconstruction with autogenous and synthetic materials

	number of patients
Primary chest wall closure	13 (50%)
Prosthetic replacements	6 (23%)
Prolene mesh	2 (8%)
Dual mesh	1 (4%)
Marlex mesh	1 (4%)
Mesh/methylmethacrylate composite	2 (8%)
Autogenous replacements	7 (27%)
Pectoralis muscle	5 (19%)
Latissimus muscle	1 (4%)
Serratus muscle	1 (4%)
Total	26

Figure 1. (A) A CT view showing osteochondroma (lower) of the posterior chest wall. (B) Postoperative views showing radical resection of the tumor and ribs.

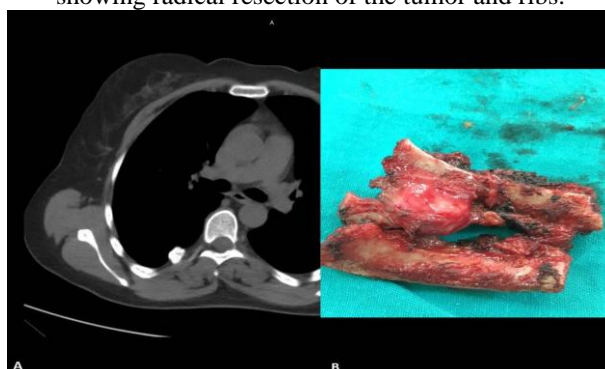


Figure 2. PET scans showing chondrosarcoma of the sternum in an adult.

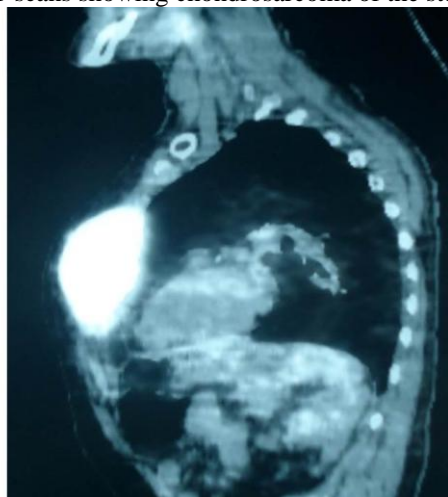
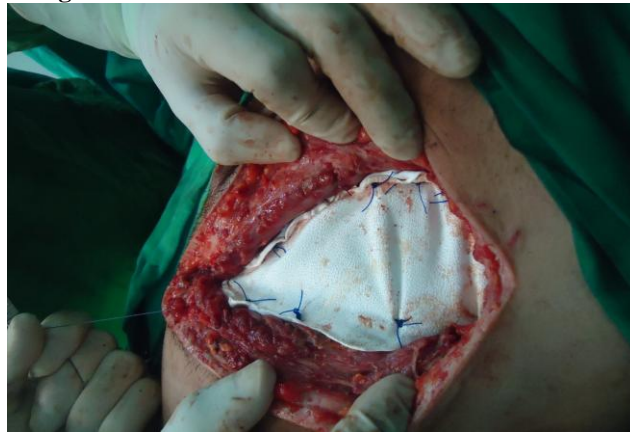

Figure 3. Chest wall reconstruction with a dual mesh.



Miktat Arif Haberal,Md, "Chest Wall Tumors of Cartilage Origin."IOSR Journal of Dental and Medical Sciences (IOSR-JDMS), vol. 17, no. 6, 2018, pp 65-69.