

## Surgical Management of Reinke's Edema: A Retrospective Analysis.

Dr S.P. Singh<sup>1</sup>, Dr Ashwani Sethi<sup>1</sup>, Dr. Deepika Sethi<sup>2</sup>, Dr A.K.Mishra<sup>1</sup>

<sup>2</sup>(Otorhinolaryngology and head & neck surgery, Army College of Medical Sciences, New Delhi, India)

<sup>1</sup>(Otorhinolaryngology and head & neck surgery, Dr BSA Medical College, New Delhi, India)

Corresponding Author: Dr. Ashwani Sethi

**Abstract:** Various treatment modalities have been proposed for the management of Reinke's edema. Conventional cold knife surgery, laser assisted surgery and microdebrider assisted surgeries have been reported in various studies to have variable success rates in term of vocal outcomes. The aim of the present study is to compare the vocal outcomes of microflap based vocal cord reduction using cold knife and CO2 laser for managing patients with Reinke's edema. The study involves a retrospective analysis of 24 consecutive patients meeting inclusion criterion undergoing vocal cord reduction for managing Reinke's edema using cold knife or CO2 laser in our institution. The pre and postoperative VHI and VQE scores were measured and compared. There was a significant improvement in the postoperative scores in both the cold knife as well as the CO2 laser group. However, there was no statistically significant difference in the scores when compared between the two groups ( $p > .05$ , Paired T-Test). In conclusion, both cold knife and CO2 laser assisted reduction of vocal cords for management of Reinke's edema are effective procedures. There is no significantly significant difference in the outcome of this procedure when performed with cold knife vis-à-vis CO2 laser.

**Key words:** Vocal cord, Reinke's edema, Hoarseness, CO2 laser, Microlaryngeal surgery.

Date of Submission: 20-05-2018

Date of acceptance: 04-06-2018

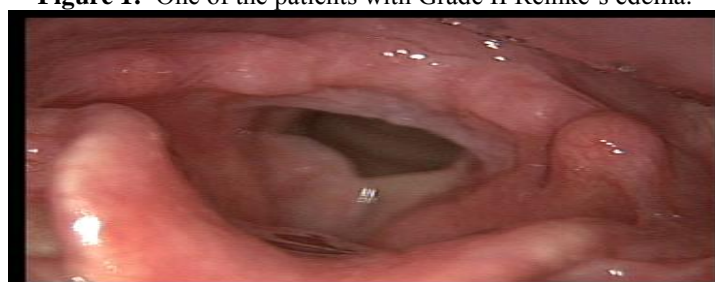### I. Introduction

Reinke's edema is a chronic, benign disease affecting the vocal cords, characterized by collection of fluid within the superficial layer of lamina propria thereby restricting the vibration of the vocal cord causing dysphonia<sup>1</sup>. Smoking, vocal abuse and laryngopharyngeal reflux (LPR) account for a majority of cases<sup>2</sup>. Although surgery is the mainstay of managing these patients, other modalities like speech therapy, intacordal steroid injection and cessation of smoking have also been advocated in the management<sup>1,3,4,5</sup>. The various surgical modalities reported include stripping of the vocal fold, subepithelial aspiration of the fluid, sub epithelial laser coagulation, microflap based laryngeal surgery, application of microsuture techniques and microdebrider assisted removal of subepithelial collection<sup>2,6,7,8,9</sup>. The present study is aimed at comparing the vocal outcomes following stripping of vocal cords using conventional cold knife and CO2 lasers in our patients.

### II. Material And Methods

This retrospective study included 24 patients of either sex meeting the inclusion criteria with age ranging from 22 to 56 years who presented to the ENT department with complaints of hoarseness secondary to Reinke's edema (Grade II or III) (**Figure 1**). Patients with hoarseness secondary to other laryngeal lesions, contraindications to surgery, unwilling for surgery and noncompliant for follow up were excluded. The patients underwent a thorough ENT examination and general physical examination for any associated systemic illness. Patients with history of smoking were counseled for cessation of the same and all the patients were referred to the speech therapist for a pre and postoperative counseling.

**Figure 1:** One of the patients with Grade II Reinke's edema.



The patients also underwent a preoperative voice analysis using objective and subjective parameters such as Voice Handicap Index, Shimmer, Jitter, Harmonic / Noise Ratio and VQE (Voice quality estimate) as a routine institutional protocol. All the patients underwent reduction of the subepithelial gelatinous tissue and redundant mucosa of the vocal cords after raising a medial based flap on the superior surface (sparing the medial edges) using conventional cold knife (14 patients) and CO2 laser (10 patients). All the patients were kept on anti-reflux measures and vocal hygiene measures (as advised by the speech therapist) in the postoperative period. Voice analysis using the same parameters was performed at 6 weeks post procedure. The patients were followed up post procedure for a duration ranging from 06 months to 2 years.

**Statistical Analysis**

The following parameters were statistically analyzed using SPSS version 17:

**VHI Scores**

The average scores of the three domains of VHI (i.e. physical, functional, and emotional) were analyzed.

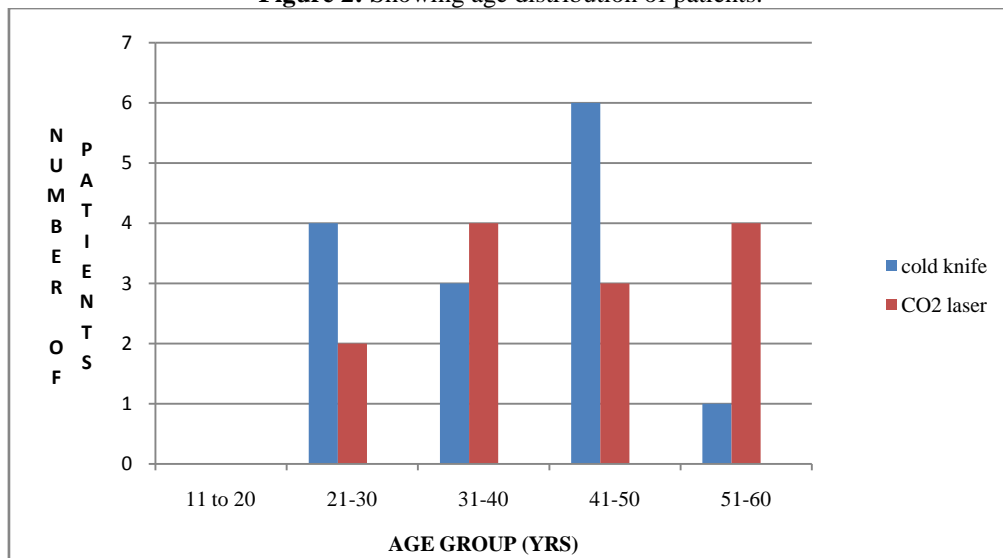
**Acoustic Analysis**

Voice analyses were done in terms of shimmer, jitter, normalized noise energy (NNE), and fundamental frequency (F0) and Voice Quality Estimate (VQE) score was calculated for all the patients using Dr. Speech voice analysis software.

**III. Result**

A total of 14 patients in the age range of 18-53 years (mean age= 38.64 yrs) underwent stripping of the vocal cords using cold knife and 10 of the patients in the age range of 28-56 years (mean age =39.70 yrs) underwent stripping of the vocal cords using CO2 laser (**Figure 2**). Amongst the 34 cases of vocal cord paralysis, 16 were idiopathic, 11 were secondary to thyroid surgery, 04 each were secondary to viral illness and pulmonary tuberculosis, whereas, one patient had sarcoidosis.

**Figure 2:** Showing age distribution of patients.



**VHI Scores**

In the cold knife group, the mean total VHI score for the patients pre operative was 66.7 (SD= 19.8). The post operative VHI score at 6 weeks was 14.8 (SD= 10.2).

In the CO2 laser group, the mean total VHI score for the patients pre operative was 60.1 (SD= 25.2). The post operative VHI score at 6 weeks was 18 (SD= 12.4).

**VQE Scores**

In the cold knife group, the mean VQE score for the patients pre operative was 2.3 (SD=0.8). The post operative VQE score at 6 weeks was 0.5 (SD=0.65).

In the CO2 laser group, the mean VQE score for the patients pre operative was 2.2 (SD= 0.8). The post operative VQE score at 6 weeks was 0.6 (SD= 0.7).

In the cold knife group, there was a significant reduction in the total and individual domain VHI and VQE scores in all 14 patients at 6 weeks post operation as compared to pre operative scores as assessed by paired T – Test (p< .05) (**Table I**).

In the CO2 laser group, there was a significant reduction in the total and individual domain VHI and VQE scores in all 10 patients at 6 weeks post operation as compared to pre operative scores as assessed by paired T – Test (p< .05) (**Table I**).

**Table I:** Comparison of pre and post injection parameters in early and late groups.

	PRE OPERATIVE VALUES		POST OPERATIVE VALUES		Stastical correlation using paired T-Test
	Cold knife	CO2 laser	Cold knife	CO2 laser	
MEAN VHI	66.7	60.1	14.8	18	P<.05
MEAN VQE	2.3	2.2	0.5	0.6	P<.05

However, there was no statistically significant difference in the post operative voice parameters improvement between the cold knife and CO2 laser groups.

**Complications**

No anaesthesia or surgery associated significant preoperative complications were reported in any of our patients. However, a temporary deterioration in voice was noted in 5 of the patients in the cold knife group and 3 of the patients in CO2 laser group. Long-term complication in the form of a glottis web was seen in 2 of the patients in cold knife group and one of the patients in CO2 laser group. All these patients underwent repeat surgical procedure for treatment of the same. Recurrence of Reinke's edema was reported in 3 of the patients in the cold knife group and one of the patients in the CO2 laser group.

**Table II:** Showing the number of patients with complications following surgery.correlation between timing of injection medialization and need for open permanent medialization.

SURGICAL MODALITY	COMPLICATIONS( No. of Patients)			
	Per operative	Temporary hoarseness	Anterior glottic web	Recurrence
COLD KNIFE	nil	05	02	03
CO2 LASER	nil	03	01	01

**IV. Discussion**

Reinke's edema was first decribed in the late 19<sup>th</sup> century by Hajek and Reinke<sup>10, 11</sup>. This condition is characterized by edema affecting the superficial layer of lamina propria of vocal cords. Histologically, it is characterized by a reduced amount of collagen, elastina nd fibronectin in the basement membrane and lamina propria<sup>2</sup>. Clinically, it is classified into 3 grades on the system based by Yonekawa<sup>12</sup>. Grade I is characterized by contact of the anterior third of the vocal cords; Grade II involves contact of the anterior two thirds of the vocal cords; and grade III involves contact of the entire vocal cords. Our study involved patients with grade II and III Rienke's edema.The accumulation of fluid in the Rienk's space hampers the mucosal wave, as well as, increases the subglottic aerodynamic pressure, thus, causing dysphonia<sup>12</sup>. The degree of dysphonia can be assessed by a variety of visual, aerodynamic, acoustic, subjective and perceptual tools<sup>1, 6, 13</sup>. However, we used the validated version of Hindi VHI and VQE for assessing the voice pre- and post operatively in our patients<sup>14</sup>. Recent studies of using high speed imaging for precisely obojectifying these lesions have reported high success rates<sup>15</sup>.The treatment of choice in the majority of patients is endoscopic microlaryngeal surgery with an aim to restore the layers of the vocal cords by exposing them to minimal trauma<sup>1, 16</sup>. The earlier techniques involved stripping of the epithelium from a part of the true vocal cord<sup>17, 18</sup>. However, these techniques were characterized by a lower success rate and high incidence of recurrence owing to exposure of vocal ligament and reduction in the superficial layer of lamina propria. Also, aprolonged period of voice rehabilitation is required in these patients following stripping<sup>19</sup>. Aspiration of the subepithelial contents is confined to patients presenting in early stages<sup>1</sup>. Microflap technique for managing benign vocal cord lesions was introduced by Hirano<sup>20</sup>. Currently, it is considered to be the treatment of choice in managing Reinke's edema<sup>7, 21</sup>. This technique involves lifting an epithelial flap on the affected vocal cord, excising, debriding or coagulating the excess subepithelial tissue and then repositing the flap back. This flap can be lifted using cold knife or laser<sup>7, 20</sup>. We used the similar surgical technique using cold knife (14 patients) and CO2 laser (10 patients). Our results were similar to the studies reported in the past<sup>7, 20, 21, 22</sup>. The other lasers used in the management of Reinke's edema include KTP 432 and phoangiolytic lasers like Pulsed dye laser<sup>23, 24, 25</sup>. Use of a debrider and microsuture are other reported techniques with good outcomes<sup>8,9</sup>.Persistent dysphonia, recurrence, thermal injury, scarring of vocal cords and anterior glottis web formation are some of the reported complications of these procedures<sup>1,7</sup>. Most of these complications are reported with the procedures involving stripping of the vocal cords. Anterior glottis web formation and recurrence was reported in a few of our patients.

## V. Conclusion

Technique of raising mucosal flap and removal of excessive subepithelial tissue is effective for management of patients with Reinke's edema. This can be performed using cold steel and CO2 laser with comparable outcomes.

## References

- [1]. Siupsinskiene N, Skumaniene M. Phonatory characteristics following different surgical techniques in the treatment of Reinke's edema. *Medicina* 2002; 38(10): 982-9.
- [2]. Zeitels SM, Bunting GW, Hillman RE, Vaughan T. Reinke's edema: phonatory mechanisms and management strategies. *Ann Otol Rhinol Laryngol* 1997; 106:533-43.
- [3]. Goswami S, Patra TK. A clinic-pathological study of Reinke's edema. *Ind J Otolaryngol Head Neck Surg* 2003; 55(3): 160-5.
- [4]. Campagnolo AM, Tsuji DS, Sennes LU, Imamura R. Steroid injection in chronic inflammatory vocal fold disorders, literature review. *Rev Bras Otorrinolaringol* 2008; 74(6): 926-32.
- [5]. Lee SW, Park KN. Long-term efficacy of percutaneous steroid injection for treating benign vocal fold lesions: A prospective study. *Laryngoscope*. 2016 Oct;126(10):2315-9.
- [6]. Geyer M, Ledda GP, Tan N, Brennan PA, Puxeddu R. Carbon dioxide laser-assisted phonosurgery for benign glottic lesions. *Eur Arch Otorhinolaryngol* 2010 Jan; 267(1):87-93.
- [7]. Tan NCW, Pittore B, Puxeddu R. The 'M' shaped microflap for treatment of complex Reinke's space edema of the vocal cords. *Acta Otorhinolaryngol Ital* 2010; 30: 259-63.
- [8]. Liu J, Ma L, Zhang P, Wang J. Voice assessment on patients with Reinke's edema of vocal fold by application of micro-suture techniques. *Lin Chung Er Bi Yan Hou Tou Jing Wai Ke Za Zhi*. 2014 Feb;28(3):191-4.
- [9]. Honda K, Haji T, Maruyama H. Functional results of Reinke's edema surgery using a microdebrider. *Ann Otol Rhinol Laryngol*. 2010 Jan; 119(1):32-6.
- [10]. Hajek M. Anatomische Untersuchungen über das Larynxödem. *Langenbecks Arch Chir* 1891; 42:46-93.
- [11]. Reinke F. Untersuchungen über das menschliche Stimmband. *Fortschr med* 1895; 12:469-78.
- [12]. Yonekawa H. A clinical study of Reinke's edema. *Auris nasus larynx* 1988; 15:57-78.
- [13]. Martins RHG, Tavares ELM, Pessin ABB. Are Vocal Alterations Caused by Smoking in Reinke's Edema in Women Entirely Reversible After Microsurgery and Smoking Cessation? *J Voice* 2017 May; 31(3):380.e11-380.e14.
- [14]. Datta R, Sethi A, Singh S, Nilakantan A, Venkatesh MD. Translation and validation of the voice handicap index in Hindi. *J Laryngol Voice* 2011; 1(1): 12-7.
- [15]. Watanabe T(1), Kaneko K, Sakaguchi K, Takahashi H. Vocal-fold vibration of patients with Reinke's edema observed using high-speed digital imaging. *Auris Nasus Larynx*. 2016 Dec; 43(6):654-7.
- [16]. Niimi S, Miyaji M. Vocal fold vibration and voice quality. *Folia Phoniatr Logoped* 2000; 52:32-8.
- [17]. Nielsen VM, Højslet Pe, Karlsmose M. Surgical treatment of Reinke's oedema (long-term results). *J Laryngol Otol* 1986; 100:187-90.
- [18]. Llore JM. Stripping of the vocal cords. *Laryngoscope* 1934; 44:803-16.
- [19]. Lumpkin SM, Bishop SG, Bennett S. Comparison of surgical techniques in the treatment of laryngeal polypoid degeneration. *Ann Otol Rhinol Laryngol* 1987; 96:254-7.
- [20]. Hirano M. Endolaryngeal microsurgery. In: English GM, editor. *Otolaryngology*. Vol 3. Philadelphia, Pa: lippincott; 1988, p. 1-11.
- [21]. Remacle M, Lawson G, Watelet JB. Carbon dioxide laser microsurgery of benign vocal fold lesions: indications, techniques, and results in 251 patients. *Ann Otol Rhinol Laryngol* 1999; 108:156-64.
- [22]. Szkielkowska A, Miałkiewicz B, Włodarczyk E, Wakarowa A, Skarziński H. Assessment of voice in patients with Reinke's oedemas treated with laser microsurgery. *Otolaryngol Pol* 2008; 62(1):82-7.
- [23]. Koszewski JJ, Hoffman MR, Young WG, Lai YT, Dailey SH. Office-Based Photoangiolytic Laser Treatment of Reinke's Edema: Safety and Voice Outcomes. *Otolaryngol Head Neck Surg*. 2015 Jun; 152(6):1075-81.
- [24]. Young VN, Mallur PS, Wong AW, Mandal R, Staltari GV, Gartner-Schmidt J, Rosen CA. Analysis of Potassium Titanyl Phosphate Laser Settings and Voice Outcomes in the Treatment of Reinke's Edema. *Ann Otol Rhinol Laryngol*. 2015 Mar; 124(3):216-20.
- [25]. Sethi A, Das A. Use of pulsed dye laser in the management of laryngeal lesions: the current perspective. *J Laryngol Voice* 2015; 5(2):29-33.

Dr. Ashwani Sethi "Surgical Management of Reinke's Edema: A Retrospective Analysis."  
"IOSR Journal of Dental and Medical Sciences (IOSR-JDMS), vol. 17, no. 5, 2018, pp 56-59"