

Reliability of Different Frankfurt Reference Planes for Three Dimensional Cephalometric Analysis: “An Observational Study”

Nashwa Abdel Mohsen¹, BDS, MSD, Amr Ragab Radwanelbeialy², BDS, MSD, PhD, Hany Salah El-Din Eid³, BDS, MSD, PhD, DSc, Sanaa Abu Zeid⁴, BDS, MSD, PhD.

¹ (Department of Orthodontics, Misr university for science and technology, Egypt)

² (Department of Orthodontics, Cairo University, Egypt)

³ (Department of Orthodontics, Misr university for science and technology, Egypt)

⁴ (Department of Orthodontics, Cairo University, Egypt)

Corresponding author: Nashwa Abdel Mohsen

Abstract: Objective: was to compare the reliability of six Frankfurt Horizontal planes versus the true Horizontal plane in adults having normal occlusion and balanced facial profile. **Material and Methods:** CBCT images were collected from thirty seven Egyptian adult subjects using the I-CAT CBCT machine and Anatomage 5.3 software to generate 3D volumetric reconstructions. A newly constructed coordinate reference system that depends on the true vertical was used for accurate measurements. Six different Frankfurt planes were constructed and were compared to the true Horizontal plane. **Results:** The intra-observer, inter-observer reliability for landmarks showed high concordance with identical ICC and CCC exceeding 0.751 and 0.78 respectively. All the Frankfurt constituting points showed high reproducibility with high correlation values varied from 0.776 to 0.999 in the intra-observer readings and exceeded 0.994 in the inter-observer readings. All proposed Frankfurt planes showed insignificant difference in their mean cant that varied from 0.7 to 1.2 to the true Horizontal plane. All planes showed no statistical significant difference from True Horizontal plane ($p > 0.05$) on their comparison with the True Horizontal plane using McNamaras' analysis. **Conclusions:** All six Frankfurt horizontal planes constructed on 3D volumetric surface were reliable as horizontal reference planes. **Keywords -** CBCT, Coordinate reference system, Normal Occlusion, Reliability of Frankfurt planes, True Horizontal plane,

Date of Submission: 08-05-2018

Date of acceptance: 25-05-2018

I. Introduction

Cone beam computed tomography (CBCT) is one of the most revolutionary innovations in the field of dentistry in the current decade. It provides a solid background for orthodontic diagnosis, treatment planning, more efficient patient management and enhanced treatment outcome. CBCT gained considerable attention as a modern diagnostic tool because it can accurately visualize and analyze the 3D shape and position of soft and hard tissues and hence offer a resolution for the superimposition limitation in 2D imaging.

Since the step of an accurate measurement system derived from identifying reference points and in turn, reference planes emerged, numerous attempts have been made in search for a craniofacial reference line that would provide the most reliable information for cephalometric analysis.

Swennen et al [1] in 2005, operating on 3D CBCT volumes proposed positioning the skull with the Frankfurt horizontal plane parallel to floor in the right profile view during standardized virtual positioning of the skull. He highlighted the presence of a discrepancy between the right and the left Frankfurt horizontal planes due to asymmetrical vertical level of the Porion. Subsequently, three dimensional cephalometric point identification explained that the left Porion is more inferiorly localized than the right Porion. He suggested that in case of uneven Frankfurt horizontal planes, the skull is to be oriented on the right Frankfurt horizontal plane for standardization. Contrastingly, he defined the Frankfurt horizontal plane as a plane passing through both Orbitale landmarks and the mean of the two Porion landmarks. It should be highlighted that, four landmarks (right and left Orbitale and Porion) are available for the construction of the Frankfurt Horizontal plane in 3D analysis, making it feasible to construct that plane based on three alternating landmarks out of the four pre-mentioned points. Accordingly, six Frankfurt horizontal planes could be alternatively constructed, with unknown difference in reliability as a reference plane.

The incorporation of the third dimension into practice of craniofacial imaging has now made it possible to evaluate the reliability of the different Frankfurt horizontal planes for more accurate orthodontic and orthognathic diagnosis and treatment planning.

The aim of the study was to compare the reliability of Frankfurt Horizontal planes generated by alternating its constituting cephalometric landmarks (two Orbitale and two Porion) versus the True Horizontal plane, in Egyptian adult subjects having clinically symmetric, average facial profiles and accepted occlusions.

II. Subjects and Methods

Cephalometric data were obtained from 37 subjects, diagnosed by two experienced orthodontists; one of them was the researcher. The selected subjects were appointed to the orthodontic department for evaluation of personal data, medical history (pregnancy for female subjects), and dental history. Static clinical examination was performed including frontal, profile analysis as well as intraoral examination.

2.1. Inclusion criteria[2, 3]

1. Age range from 18-25 years.
2. Balanced Facial Proportions.
 - a) Class 1 skeletal relationship.
 - b) Symmetric face.
3. Accepted normal occlusion with the following criteria:
 - a) Angle Class I molar relationship.
 - b) Canine Class I relationship.
 - c) Full permanent dentition with the exception of the third molars.
 - d) 1 to 3 mm. arch length discrepancy in each jaw within the three dimensions .
 - e) Overjet (2 to 4 mm.).
 - f) Overbite (20-40%).
4. Coincidental facial and dental midlines.
5. Healthy dental and periodontal condition with a good oral hygiene.
6. Absence of degenerative conditions (e.g. rheumatoid arthritis).

2.2. Sample size calculation

The sample size calculation was based on the ANB angle for normal Egyptian population that was published in a previous study [4], For the ANB angle to be within the normal range 3 ± 2 a sample of 37 is required assuming a standard deviation 0.75 and difference of mean ± 0.35 with a significance level 95% ($\alpha = 0.05$) and Power 0.8 ($\beta = 0.2$). To allow for dropouts, a sample of 40 cases was recommended.

2.3. Power and Sample Size:

Two observers, the researcher (observer1) and a colleague (observer2) carried out the landmarks identification for 10% of the sample, and only for the researcher to do it twice with a gap period of 14 days between them. The landmarks localization was done on the axial, sagittal and coronal planes noting that not all the landmarks needed to use the three cuts to be located. Inter-observer and intra-observer calibrations were obtained and exported to a Microsoft Excel® 2013 sheet with their X, Z and Y coordinates for inter-observer and intra-observer differences and their statistical evaluation before the starting of the study.

2.4. Statistical methods:

- Data collection and their statistical analysis were performed using Statistical Package for Social Sciences (SPSS) vs. 21.
- Numerical data were summarized using means and standard deviations.
- To assess degree of agreement between different observers and overtime for the same observer, correlations analysis was determined by using Pearson test.
- The Paired t-test was done to assess the inter-observer and/ or intra-observer differences for reproducibility of identification of the Frankfurt horizontal planes constituting points especially in the Y coordinate.
- Cants between different Frankfurt planes and the true horizontal were done by single sample t-test.
- The anteroposterior jaw assessment (A-B diff-Nv) depending on the 6 different Frankfurt horizontal planes used, were compared with that depending on the true vertical (gold standard) using paired t-test. All p-values are two-sided. P-values < 0.05 were considered significant.

The correlation between these two sets of measurements is the intra or inter reliability coefficient. If it is reliable, there will be a high positive association between the measurements.

2.5. CBCT imaging

The cone beam computed tomography were obtained by using resolution 0.3/0.3 voxel size, 8.9 seconds total scanning time, exposure time of 4 seconds, 120 Peak Kilo voltage and 5 milliampere. The subject's head was oriented twice, the primary head orientation was made when he was asked to perform the natural head position through looking at a large mirror with a vertical line drawn in the middle of it facing him\her by 4.5 feet distance [2]. After a complete setting of the machine for the proper imaging protocol and the subject's vertical position and his\her head primary orientation, the secondary head orientation was performed by the technician using the vertical laser beam emitted by the machine to adjust the right and left head rotation. The imaging cycle was started inside the CBCT machine room, then three-dimensional image was exported to a DVD with DICOM format. Using "Anatomage in-vivo Dental" version 5.4 software, the three dimensional cephalometric analysis was done through "3DAnalysis" module.

2.6. Steps for construction of the Coordinate system

A-Obtaining the True Vertical Plane:

In order to obtain the true vertical plane imported into each CBCT image and to be the base for the used coordinate system, a novel idea was obtained and described as follows:

1. A 20-cm. metallic chain with suspended weight attached to it serves as a pendulum.
2. The pendulum was put inside a glass box at the center of the CBCT's field of view and making sure that the weight is stable in the air (Fig. 1).
3. Three dimensional tomography was taken to the pendulum.
4. The CBCT image of the pendulum was checked for any motion artifacts.
5. The verified CBCT image of the pendulum was exported into a DICOM file in order to be opened by the same software that was used throughout the study (Fig. 2). Using the Three-dimensional computed tomography software a certain module called "StitchingModule" where the volume of the metal pendulum was stitched to each CBCT representing the true Vertical plane. Using the stitched pendulum, a true vertical line was constructed by picking two Landmarks along the pendulum with a wide distance between them. The true axial plane was then constructed to be perpendicular to this vertical line and passing through the Nasion landmark. The true Midsagittal plane was constructed to be perpendicular on the true Axial plane and passing through the Nasion and mid Zygomatico-frontal suture point. Finally, the true Coronal plane was constructed to be perpendicular on both the true axial and mid-sagittal planes and passing through Nasion landmark. The constructed reference system that was made by the help of the true vertical line was the main reference system for this study (Fig. 3)




Fig 1: CBCT imaging of the metallic pendulum




Fig 2: metallic pendulum CBCT image

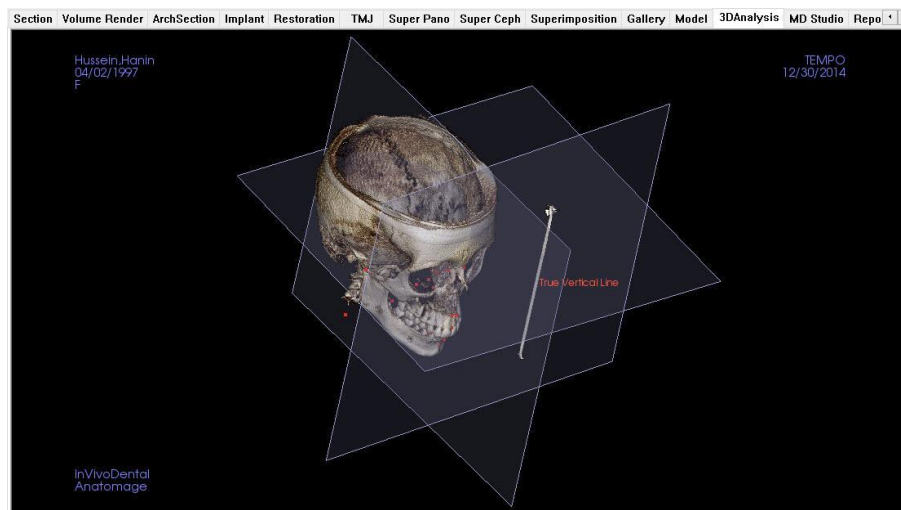


Fig 3: Constructed coordinate reference system related to CBCT image

B-New analysis establishment and construction

Landmarks were added to the new cephalometric analysis through “3DAnalysis setup” option. Before starting of landmarks identification, view settings should be done for each landmark and the landmarks were classified into: Cranial base landmarks, maxillary base landmarks and mandibular base landmarks. Through “create tracing” option then “setup” button reference lines or planes needed for the analysis were reconstructed through “3D Analysis Setup”, by clicking on “reference” tab. All measurements, distances, angles and ratios” were added. A full definition of each landmark and measurement in the three dimensional assessment of the Frankfurt reliability analysis were written in tables (1-7).

2.7. Landmarks, Measurement and Ratios definitions:

Table 1: Cranial landmarks, definition and localization

Landmark	Abbrviation + Figure	Definition	Localization		
			Coronal cut	Sagittal cut	Axial cut
Nasion	N (Fig. 4)	The most anterior midpoint on the suture between the frontal and nasal bones[5].	Midpoint in the center of the radiolucency.	Summit of the radiolucent suture.	Anterior most midpoint of the anterior contour
Porion	Po (Fig. 5)	The most superior posterior point of the external acoustic meatus[1].	Superior-most point of the external acoustic meatus.	Most Superior posterior point of the external acoustic meatus with a full radiopaque rim.	First point that appears.
Orbitale	Or	The most inferior point on		Most superior point on	Anterior-most

	(Fig. 6)	the infraorbital rim[1].	the inferior orbital rim.	point.
Zygomatico-frontal suture	ZF (Fig. 7)	The most superior and medial point on the fronto-zygomatic suture[6].	Medial-superior most point.	Superior-most point.	Anterior-most point.

Table 2:Maxillary landmarks,definitions and localization

Landmark	Abbreviation + Figure	Definition	Localization		
			Coronal cut	Sagittal cut	Axial cut
Sub-spinal point	A-point (Fig. 8)	The most posterior midline point in the concavity between the anterior nasal spine and the prosthion[6]	Middle point of the anteroposterior slice determined by the sagittal and axial views	Posterior –most point on the curve of the maxilla below the anterior nasal spine	Middle-anterior most point on the tip of the premaxilla

Table 3: Mandibular landmarks, definition and localization

Landmark	Abbreviation + Figure	Definition	Localization		
			Coronal cut	Sagittal cut	Axial cut
Supramentale	B-point (Fig. 9)	The most posterior midline point on the facial concavity of the mandible[6].	Midline point.	Deepest most point on the anterior contour.	Anterior most Midline point.

Table 4: Different Frankfurt plane cants relative to the true horizontal plane (Angular)

Serial	Measurement	Abbreviation	Points
#1	Frankfurt 1 to True Horizontal	Fh 1/ Th	OL, OR, PR
#2	Frankfurt 2 to True Horizontal	Fh 2/ Th	OL, OR, PL
#3	Frankfurt 3 to True Horizontal	Fh 3/ Th	PL, PR, OR
#4	Frankfurt 4 to True Horizontal	Fh 4/ Th	PL, PR, OL
#5	Frankfurt 5 to True Horizontal	Fh 5/ Th	OR, OL, P-Mid
#6	Frankfurt 6 to True Horizontal	Fh 6/ Th	PR, PL, O-Mid

Table 5: Anteroposterior maxillary position relative to different coronal planes

Serial	Measurement	Abbreviation
#1	Point A to true vertical	A-Tv
#2	Point A to Coronal 1	A-C1
#3	Point A to Coronal 2	A-C2
#4	Point A to Coronal 3	A-C3
#5	Point A to Coronal 4	A-C4
#6	Point A to Coronal 5	A-C5
#7	Point A to Coronal 6	A-C6

Table 6: Anteroposterior mandibular position relative to different coronal planes

Serial	Measurement	Abbreviation	Figure
#1	Point B to true vertical	B-Tv	Error! Reference source found.21 not
#2	Point B to Coronal 1	B-C1	
#3	Point B to Coronal 2	B-C2	
#4	Point B to Coronal 3	B-C3	
#5	Point B to Coronal 4	B-C4	
#6	Point B to Coronal 5	B-C5	
#7	Point B to Coronal 6	B-C6	

Table 1: Anteroposterior jaw assessment (AB difference) relative to different coronal planes.

Serial	Measurement	Abbreviation
#1	AB difference relative to Tv	AB diff- Tv
#2	AB difference relative to coronal plane 1	AB diff-C1
#3	AB difference relative to coronal plane 2	AB diff-C2
#4	AB difference relative to coronal plane 3	AB diff-C3
#5	AB difference relative to coronal plane 4	AB diff-C4
#6	AB difference relative to coronal plane 5	AB diff-C5
#7	AB difference relative to coronal plane 6	AB diff-C6

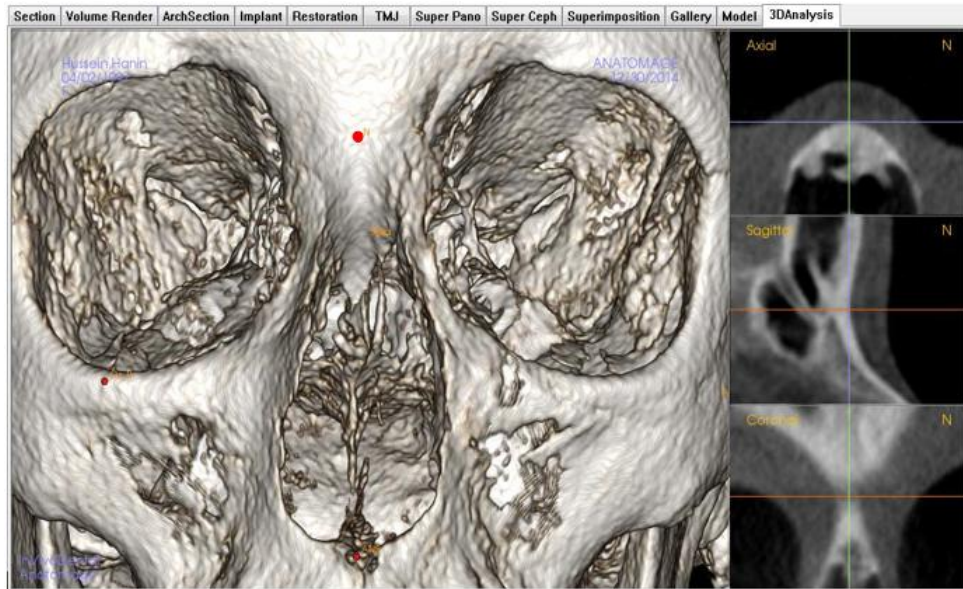


Fig. 4: Nasion localization in volumetric view

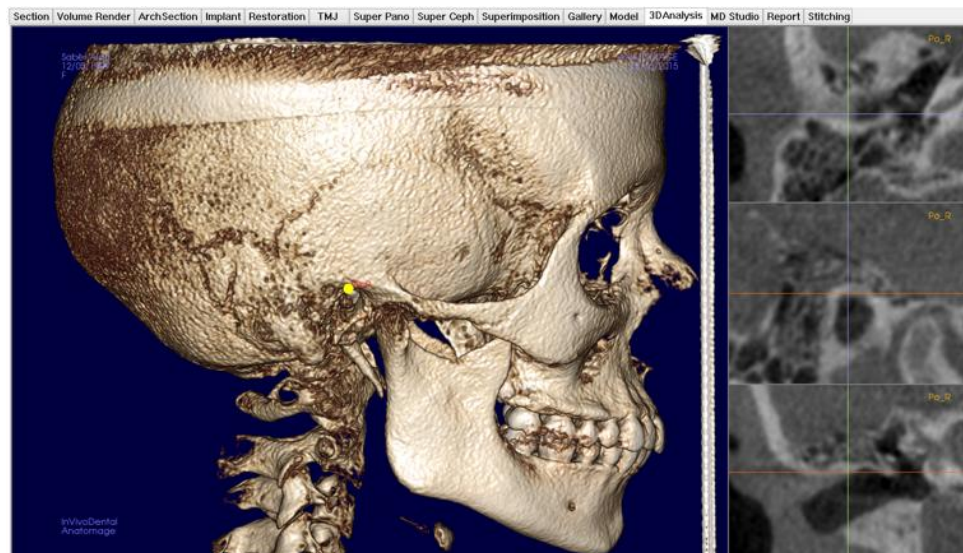


Fig. 5: Porion (Right) localization in volumetric view

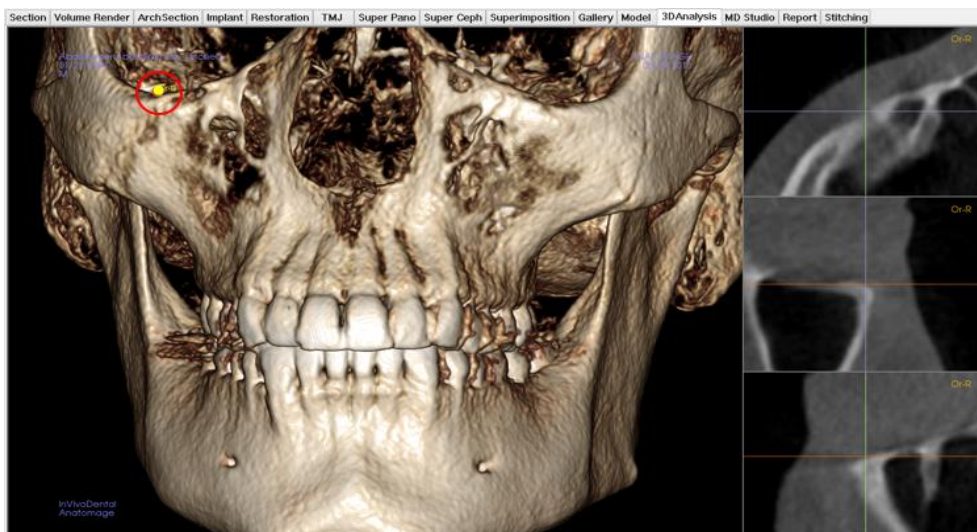


Fig.6: Orbitale (Right) localization in volumetric view

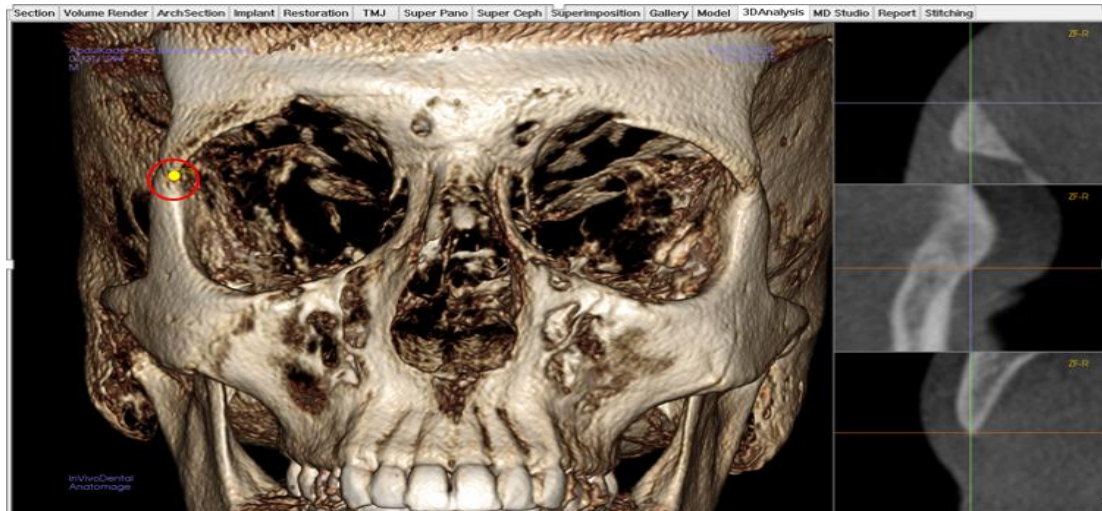


Fig 7: Zygomatico-Frontal suture (Right) localization in volumetric view

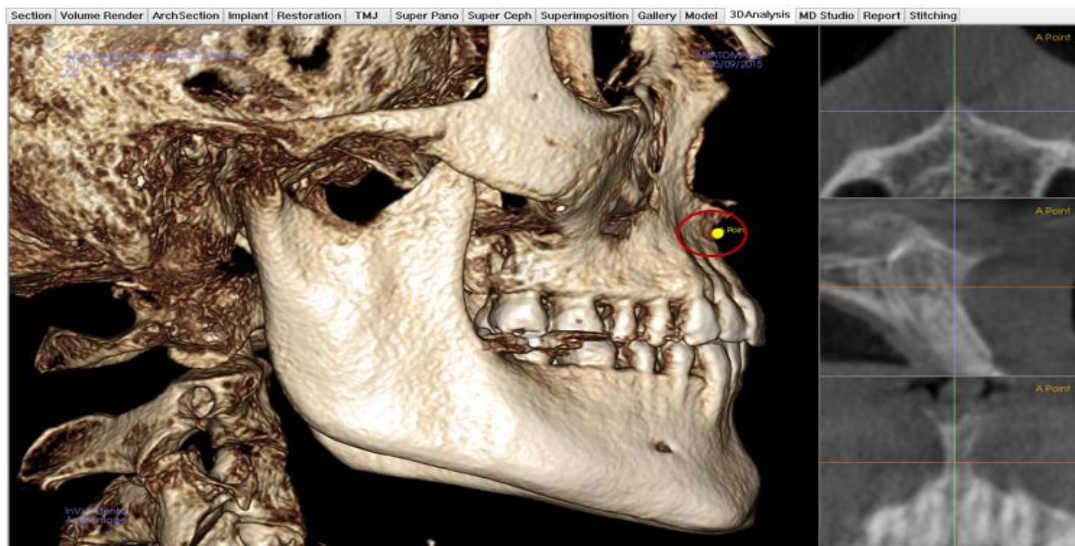

Fig 8: Sub-Spinal localization in volumetric view

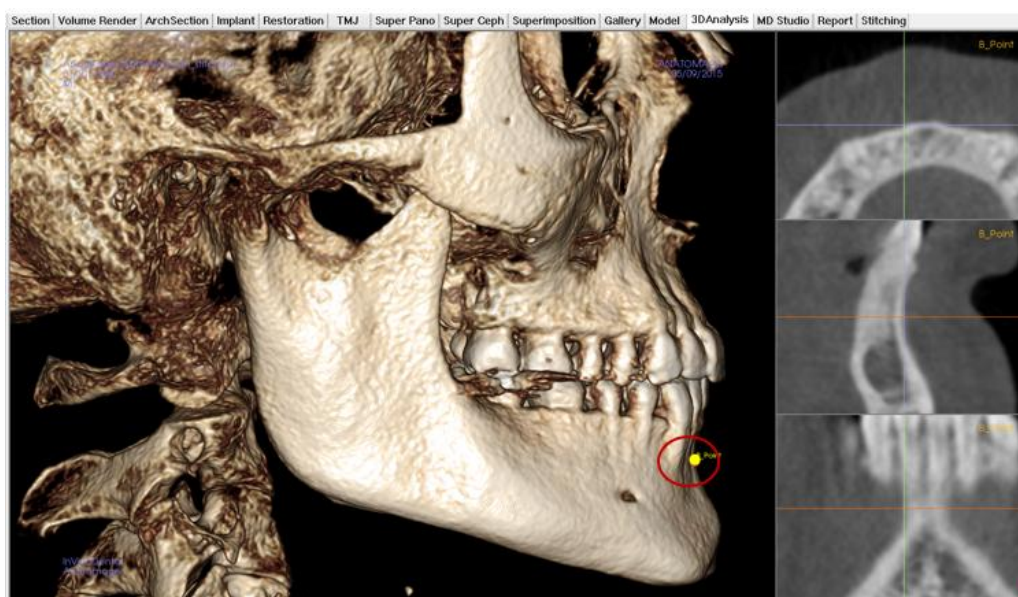


Fig.9: Supra Mental localization in volumetric view

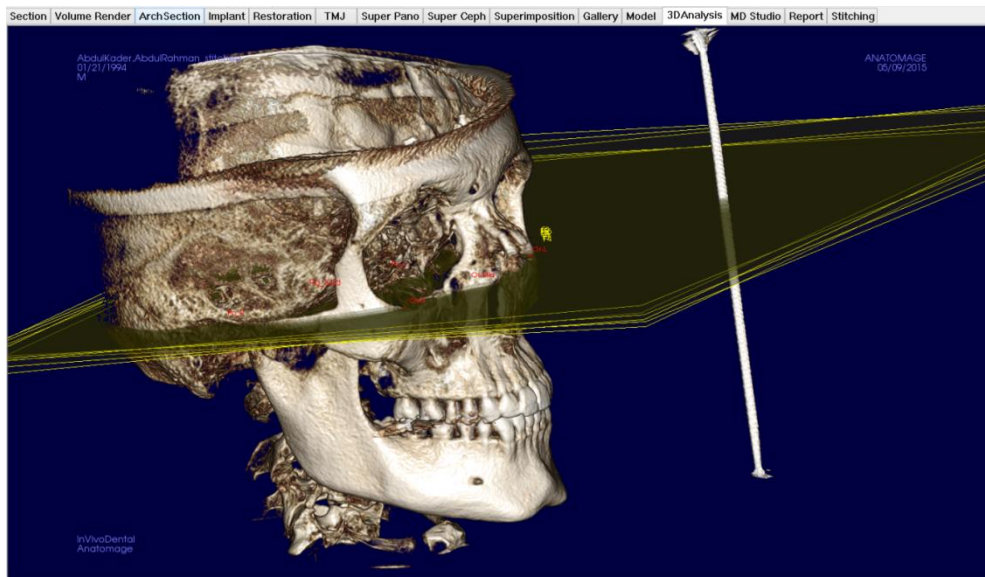


Fig.10: The six Frankfurt horizontal planes used in the study

III. Results

3.1. Intra-observer reliability of the used landmarks identification:

Table 8: Intra-observer reliability of 3D point identification.

	Landmark	A point	B point	ZF_L	ZF_R	ZF_Mid
X	r	.971**	.978**	.969**	.994**	.961**
	P value	0.006	0.004	0.006	0.001	0.009
Z	r	.997**	.990**	.989**	.996**	.997**
	P value	<0.001	0.001	0.001	<0.001	<0.001
Y	r	1.000**	1.000**	.996**	.999**	.999**
	P value	<0.001	<0.001	<0.001	<0.001	<0.001

r : Correlation coefficient, p <0.05 is significant

Table 9: Intra-observer reliability of 3D point identification (continued).

	Landmark	N point	Po-left	Po-right	Or-left	Or-right
X	r	.974**	.999**	.999**	.999**	1.000**
	P value	0.005	<0.001	<0.001	<0.001	<0.001
Z	r	.998**	.971**	0.751	.966**	.991**
	P value	<0.001	0.006	0.143	0.007	0.001
Y	r	1.000**	.999**	.999**	.997**	.997**
	P value	<0.001	<0.001	<0.001	<0.001	<0.001

r : Correlation coefficient, p <0.05 is significant

3.2. Inter-observer reliability of the used landmarks identification:

Table 10: Inter-observer reliability of 3D point identification

	Landmark	A point	B point	ZF_L	ZF_R	ZF_Mid
X	r	.993**	.940*	.963**	.988**	.989**
	P value	0.001	0.017	0.008	0.002	0.001
Z	r	.996**	.959**	.989**	.992**	.987**
	P value	<0.001	0.01	0.001	0.001	0.002
Y	r	1.000**	1.000**	.997**	.999**	.997**
	P value	<0.001	<0.001	<0.001	<0.001	<0.001

r: Correlation coefficient, p <0.05 is significant

Table 11: Inter-observer reliability of 3D point identification (continued)

	Landmark	N point	Po-left	Po-right	Or-left	Or-right
X	r	.964**	1.000**	1.000**	.996**	.999**
	P value	0.008	<0.001	<0.001	<0.001	<0.001
Z	r	.998**	.986**	0.78	0.862	.968**
	P value	<0.001	0.002	0.12	0.06	0.007
Y	r	1.000**	1.000**	.999**	.993**	.997**
	P value	<0.001	<0.001	<0.001	0.001	<0.001

r: Correlation coefficient, p <0.05 is significant

3.3 Reproducibility of the Frankfurt plane constituting points (PR, PL, OL and OR) in X, Z and Y planes.

The intra and inter-observer reliability for the different points constituting the Frankfurt plane showed high concordance in both inter and intra-observer readings. The correlation value in the y-axis varied between 0.776 & 0.999 in the intra-observer readings and exceeded 0.994 in the inter-observer readings. (Table 12)

Table 2: Reproducibility of the Frankfurt plane constituting points in the three coordinate planes

Points	Axes	intra-observer		Inter- observer	
		r	p value	r	p value
PR	X	0.903	<0.001	0.963	<0.001
	Z	0.606	<0.001	0.987	<0.001
	Y	0.819	<0.001	0.998	<0.001
PL	X	0.214	0.204	0.017	0.92
	Z	0.533	0.001	0.999	<0.001
	Y	0.776	<0.001	0.996	<0.001
OL	X	0.634	<0.001	0.868	<0.001
	Z	0.951	<0.001	0.989	<0.001
	Y	0.79	<0.001	0.995	<0.001
OR	X	0.634	<0.001	0.868	<0.001
	Z	0.951	<0.001	0.989	<0.001
	Y	0.79	<0.001	0.995	<0.001
P-Mid	X	0.476	0.003	0.275	0.099
	Z	0.999	<0.001	0.996	<0.001
	Y	0.999	<0.001	0.998	<0.001
O-Mid	X	0.957	<0.001	0.958	<0.001
	Z	0.994	<0.001	0.994	<0.001
	Y	0.998	<0.001	0.994	<0.001

3.4 Means and significance of cant of the different Frankfurt planes relative to the True Horizontal plane

On comparing the cant of different Frankfurt planes relative to the True Horizontal plane as shown in Table 13, all the Frankfurt planes showed closeness or parallelism with the true Horizontal plane without any significant difference between them. The mean of their cant to the true Horizontal ranged from 0.7 to 1.2 degrees.

Table 13: Cant of the different Frankfurt planes relative to the True Horizontal plane and significance of their difference.

Fh/Th (degree)	Mean (degree)	SD	Minimum (degree)	Maximum (degree)	P value	95% Interval of the Difference	
						Lower	Upper
Fh1/Th	1.2	4.8	-8.25	12.02	0.133	-0.4	2.8
Fh2/Th	0.7	4.6	-9.66	9.51	0.373	-0.8	2.2
Fh3/Th	1.2	4.7	-8.41	11.61	0.142	-0.4	2.7
Fh4/Th	0.8	4.5	-9.47	9.83	0.319	-0.8	2.3
Fh5/Th	0.9	4.6	-8.95	10.77	0.221	-0.6	2.5
Fh6/Th	1.0	4.6	-8.94	10.72	0.213	-0.6	2.5

Analysis was repeated by Non-parametric test to ensure robustness of the results

3.5 Anteroposterior jaw assessment using different Frankfurt planes versus true Horizontal plane (McNamaras’ analysis).

On the anteroposterior jaw assessment depending on the different Frankfurt planes in comparison with the True Horizontal plane, using McNamaras’ analysis as shown in (Table 14), all planes showed no statistical significant difference from True Horizontal plane ($p > 0.05$). In other words, all the Frankfurt planes showed validity in the anteroposterior jaw assessment versus True Horizontal plane with insignificant difference.

Table14: Anteroposterior jaw assessment depending on different Frankfurt planes

AB dif-TV (Gold standard)			Difference		95% CI of the Difference		
Mean	SD		Mean (mm)	SD	Lower	Upper	P value
-2.5	3.4	AB dif-C1	-0.80	3.13	-1.85	0.24	0.128
		AB dif-C2	-0.13	3.24	-1.21	0.94	0.804
		AB dif-C3	-0.76	3.09	-1.79	0.26	0.141
		AB dif-C4	-0.50	3.00	-1.49	0.49	0.312
		AB dif-C5	-0.62	3.02	-1.63	0.38	0.218
		AB dif-C6	-0.63	3.01	-1.63	0.37	0.210

Analysis was repeated by Non-parametric test to ensure robustness of the results

IV. Discussion

The use of cephalometric analyses in orthodontics is no doubt of great importance in diagnosis, treatment planning of orthodontic, orthopedic and orthognathic problems. Using a reliable reference plane during the evaluation of various cephalometric analyses is mandatory to allow the accurate evaluation of the involved components and not to mention the growth evaluation. The reliability of these reference planes depends mainly on their reproducibility. A reliable horizontal reference plane is that which joins three cephalometric points reproducible in the vertical dimension (y-axis), while a reliable vertical reference plane is that which joins three cephalometric points reproducible in the horizontal dimension (x-axis).

However, the introduction of 3-dimensional cephalometrics changed many concepts; the inherent deficiencies of 2D presentation of a 3D object has been eliminated and the identification of difficult landmarks due to overlapped structures encountered in 2-dimensional cephalometry is now made feasible. However, with the introduction of 3-dimensional cephalometry, new challenges were faced. Both sides of the skull are obvious with double the number of points to be localized.

Swennen [1] previously noticed a discrepancy between the right and left Porion points, the left being more inferiorly localized. He suggested using the right Frankfurt horizontal plane during orientation of the skulls for standardization. It is also worth mentioning that several previous studies made by Kim et al [7] and Graten et al [8] used the Frankfurt plane constructed from both Porions and the left or the right Orbitale to analyze the craniofacial morphology. Similarly, Terajiima et al [9] and Song et al [10] defined the Frankfurt plane as being constructed from the right Porion, left Porion and midpoint of the Orbitale and used it for measuring 3D skeleton-dental orientations. Cheung et al [11] as well as Damstra et al [12] defined the Frankfurt horizontal plane as being formed using the right and left Orbitale and the midpoint of the Porion, then they used it to develop a 3D cephalometric analysis system to assess Dentofacial deformity. However, Wong et al [13] defined the FHP to be used for 3D CBCT analysis as being constructed by right Orbitale, left Orbitale and left or right Porion.

Therefore, a verdict has to be reached regarding which of these Frankfurt planes is to be used with confirmed reliability and reproducibility. By reviewing the literature, the reliability of each 3D constructed Frankfurt plane was never tested. Hence, the current study aimed at evaluating the reliability of Frankfurt Horizontal planes constructed from several bilateral points.

The reference system used was constructed using a pendulum representing the true vertical that was stitched to each CBCT image on which the rest of the reference planes were constructed. It was noted that CBCT machine at the imaging center was properly mounted in a balanced position to the extent that its coordinates coincided with the true vertical plane of the metal pendulum and the references built on it. It is worth mentioning that if the constructed true vertical was not coincident with the vertical plane of the machine, measurements would have been affected by the type of CBCT machine and it’s built in co-ordinates and the

degree of accuracy of its mounting. Therefore, the constructed true vertical depending on the pendulum allows reproducibility of any analysis regardless of any variations related to the machine.

Ten cephalometric landmarks were localized on each CBCT volume by the same operator. All cephalometric landmarks used were anatomical ones (Nasion, Porion, Orbital, A point, B point, and ZF point). The landmarks used in the current study were anatomical, which facilitated their identification when compared to the localization of the same points on the 2D cephalometry that were even made harder to localize by overlapping of both sides. All landmarks used in this study to represent the Frankfurt plane (OL, OR, PR and PL) showed high inter and intra-observer reliability.

The reliability of the Zygomatico-Frontal suture point [14] on the three dimensional image facilitated the construction of the true mid-sagittal plane which in turn facilitated the construction of the coronal plane at Nasion point. Previous studies noted the high reproducibility of the Nasion [15] landmark, It also showed high inter and intra-observer reproducibility in the current study. In this study, the Nasion landmark was used as the reference point through which the true horizontal plane passes when constructed perpendicular to the constructed true vertical plane. The Coronal planes were constructed perpendicular to the Frankfurt planes at Nasion and used for assessment of McNamara's analysis.

Since the included subjects had balanced facial proportions, several mid-points of bilateral landmarks were computed such as the Fronto-Zygomatic suture, Porion and Orbitale. These mid-landmarks are highly reliable when compared to their counterparts on the 2D cephalograms due to its inherited projection error. The mid-Fronto-Zygomatico suture point was used for construction of the mid-sagittal and finally the mid-Porion and mid-Orbitale were one of the points used in construction of the six Frankfurt planes being evaluated. The six Frankfurt horizontal planes studied for reliability were evaluated, first: in terms of reproducibility, second: closeness to True Horizontal plane and third: in terms of validity.

First, regarding reproducibility of the proposed Frankfurt planes specially in the y-axis, all of them showed high correlation values in both inter-observer ($r < 0.994$) & intra-observer ($r = 0.776-0.999$) readings. (Table 12)

Second, upon evaluation of their parallelism in relation to the True Horizontal plane through calculating the means of the different Frankfurt horizontal planes cants relative to the true Horizontal (Table 13), All Frankfurt planes had approximately close means to each other (mean cant ranged from 0.7 to 1.2) & to the true Horizontal plane without significant difference ($p > 0.05$).

Thirdly, concerning the validity of the Frankfurt horizontal planes, the AB difference of McNamara assessment made using six Coronal planes constructed perpendicular to the six Frankfurt horizontal planes at Nasion point showed no significant difference from the AB difference that relied upon the true vertical plane (pendulum). (Table 14)

Therefore, the unproved preset assumption set in the orthodontic literature as of using any three of the four landmarks for construction of the FHP is now proven valid. The use of any combination of these landmarks will yield a reliable and reproducible FHP.

V. Conclusion

1-All six Frankfurt horizontal planes constructed from alternation of their constituting points (2 Orbitale and 2 Porion) were reliable as horizontal reference planes in terms of reproducibility since they all showed high correlation value (0.776 -0.998) in both inter and intra-observer readings.

2-All the proposed six Frankfurt planes showed parallelism with the true horizontal plane since they showed a mean cant that ranged from 0.7-1.2 degrees without any significant difference.

3-All six Frankfurt horizontal planes were valid as they showed insignificant difference with the true vertical in the assessment of A-B difference of McNamara.

References

- [1]. Swennen, G.R., F.A. Schutyser, and J.-E. Hausamen, Three-dimensional cephalometry: a color atlas and manual. 2005: Springer Science & Business Media.
- [2]. Van Vlijmen, O., et al., A comparison between 2D and 3D cephalometry on CBCT scans of human skulls. International journal of oral and maxillofacial surgery, 2010. **39**(2): p. 156-160.
- [3]. A. S., lateral and frontal cephalometric templates and norms for Egyptian adults: reconstructed cone-beam views- Department of Orthodontics Cairo University, 2011. Thesis submitted in partial fulfillment of the requirements for the Master's Degree in Orthodontics. Faculty of Oral and Dental Medicine. 2011.
- [4]. Katkar, R.A., et al., Comparison of observer reliability of three-dimensional cephalometric landmark identification on subject images from Galileos and i-CAT cone beam CT. Dentomaxillofacial Radiology, 2013. **42**(9): p. 20130059.
- [5]. Sanders, D.A., et al., Quantification of skeletal asymmetries in normal adolescents: cone-beam computed tomography analysis. Progress in orthodontics, 2014. **15**(1): p. 26.
- [6]. Jacobson, A. and R.L. Jacobson, Radiographic Cephalometry: From Basics to 3-D Imaging, (Book/CD-ROM set). 1995.
- [7]. Park, S.-H., et al., A proposal for a new analysis of craniofacial morphology by 3-dimensional computed tomography. American Journal of Orthodontics and Dentofacial Orthopedics, 2006. **129**(5): p. 600. e23-600. e34.

Reliability Of Different Frankfurt Reference Planes For Three Dimensional Cephalometric Analysis: .

- [8]. Gateno, J., J.J. Xia, and J.F. Teichgraeber, New 3-dimensional cephalometric analysis for orthognathic surgery. *Journal of Oral and Maxillofacial Surgery*, 2011. **69**(3): p. 606-622.
- [9]. Terajima, M., et al., A 3-dimensional method for analyzing the morphology of patients with maxillofacial deformities. *American Journal of Orthodontics and Dentofacial Orthopedics*, 2009. **136**(6): p. 857-867.
- [10]. Song, W.-W., et al., Maxillary yaw as the primary predictor of maxillary dental midline deviation: 3D analysis using cone-beam computed tomography. *Journal of Oral and Maxillofacial Surgery*, 2013. **71**(4): p. 752-762.
- [11]. Cheung, L.K., et al., Three-dimensional cephalometric norms of Chinese adults in Hong Kong with balanced facial profile. *Oral Surgery, Oral Medicine, Oral Pathology, Oral Radiology, and Endodontology*, 2011. **112**(2): p. e56-e73.
- [12]. Damstra, J., et al., Reliability and the smallest detectable difference of measurements on 3-dimensional cone-beam computed tomography images. *American journal of orthodontics and dentofacial orthopedics*, 2011. **140**(3): p. e107-e114.
- [13]. Wong, R., A. Chau, and U. Hägg, 3D CBCT McNamara's cephalometric analysis in an adult southern Chinese population. *International journal of oral and maxillofacial surgery*, 2011. **40**(9): p. 920-925.
- [14]. Elbeialy, A.R.R., Landmark identical on 3-dimensional radiographic volume for craniometric measurements. 2012.
- [15]. Targownik, R., The dimensional relationships between the cranial base, body height, and the facial complex. 2001, National Library of Canada= Bibliothèque nationale du Canada.

Nashwa Abdel Mohsen "Reliability Of Different Frankfurt Reference Planes For ThreeDimensional Cephalometric Analysis: "An Observational Study" "IOSR Journal of Dental and Medical Sciences (IOSR-JDMS), vol. 17, no.5, 2018, pp 41-52