

## A Study of Relationship between Great Saphenous Vein and Superficial External Pudendal Artery and Duplication of Great Saphenous Vein in South Indian Population [Original Article]

Dr. P.Ramalingam<sup>1</sup>; Dr. K.Rajeswari<sup>2</sup>

<sup>1</sup>M.B.B.S; M.S; Associate Professor, Dept of Surgery, Karpagam Faculty of Medical Sciences and Research, Coimbatore, India

<sup>2</sup>M.B.B.S; M.S; Associate Professor, Dept of Anatomy, Government Medical College and ESIC Hospital, Coimbatore, India

Corresponding Author: Dr. P.Ramalingam<sup>1</sup>

---

**Abstract:** The varicose veins are a relatively common condition of the lower limb for which surgery is the main modality of treatment. An anomaly of the Sapheno femoral junction should always be taken into consideration in order to minimize surgical complications of varicose veins. Knowledge of anatomical location of superficial external pudendal artery and its relationship with the great saphenous vein is very important while exploring the sapheno femoral junction. Precise knowledge about these variations will definitely help to avoid inadvertent injury to superficial external pudendal artery and ensuing complications.

**Aim:** Our purpose was to study the anatomical variations in the relationship of the great saphenous vein with the superficial external pudendal artery and to find the incidence of duplicated great saphenous vein in South Indian population.

**Material and methods:** The study material consisted of 50 adult lower limb specimens from 25 adult cadavers (18 males and 7 females) of age group between 50 to 80 years allotted for dissection to the 1<sup>st</sup> MBBS students and 6 foetal lower limb specimens. The method of study was by direct dissection method.

**Results-** The relationship of superficial external pudendal artery with great saphenous vein was recorded in 50 specimens. In 8 cases (16%) the superficial external pudendal artery was not visualised at the sapheno femoral junction. In 26 cases (52%) the superficial external pudendal artery was found posterior to great saphenous vein. In 16 cases (32%) the superficial external pudendal artery was found anterior to great saphenous vein. In all 6 foetal specimens the superficial external pudendal artery was found posterior to the great saphenous vein. In only one lower limb the duplication of great saphenous vein was noted [2%].

**Conclusion-** Presence of rare and clinically essential variant form of great saphenous vein and its duplication should be known to clinicians, radiologists, and phlebomotomists. Familiarity with anatomical sapheno femoral junction variations is imperative to ensure operative success and recurrence reduction.

**Keywords-** great saphenous vein; duplication; superficial external pudendal artery.

---

Date of Submission: 26-03-2018

Date of acceptance: 14-04-2018

---

### I. Introduction

The varicose veins are one of the most common venous diseases of lower limb. Large varicosities require surgical treatment. The great saphenous vein is ligated at the sapheno femoral junction before it joins the femoral vein. At this juncture, the superficial external pudendal artery is variably related to the great saphenous vein. Sound knowledge of these variable positions is of utmost importance for successful outcome of surgery. Duplication of great saphenous vein is a reason behind recurrence of varicose veins, nevertheless it makes extraction easier for procedures like coronary bypass grafting. So the aim of our study was to establish palpable anatomical markers for its exploration and surgical approach.

The great saphenous vein starts distally as a continuation of medial marginal vein of foot and ends in the femoral vein a short distance distal to the inguinal ligament. The vein is often duplicated especially below the knee. The superficial external pudendal artery arises medially from the femoral artery, passes medially usually deep to the long saphenous vein. [1]

### II. Aims And Objectives

1. To study the anatomical variations in the relationship of the great saphenous vein and the superficial external pudendal artery.
2. To find out the incidence of duplicated great saphenous vein in the South Indian population.

3. To help the surgeons and clinicians to prevent complications after varicose vein surgery due to duplication of great saphenous vein

### **III. Materials And Methods**

The study material consisted of 50 adult lower limb specimens from 25 adult cadavers (18 males and 7 females) of age group between 50 to 80 years allotted for dissection to the I MBBS students in the Institute of Anatomy, Madras Medical College, Chennai and 6 foetal lower limb specimens from 3 unclaimed foetal cadavers from the Institute of Obstetrics and Gynaecology Egmore, all from 28 to 36 weeks of gestational age, after getting consent from concerned parents or relatives. The method adopted for study was direct dissection method. A horizontal incision was made from anterior superior iliac spine to pubic tubercle. A vertical incision was made from pubic tubercle to medial malleolus. The skin and superficial fascia were reflected. By a peculiar darkness or blueness showing through the fat, the vein was isolated and separated from the surrounding tissue from its entry into femoral vein at fossa ovalis till the medial malleolus. The presence of duplication of the great saphenous vein was looked for and recorded.

### **IV. Observation**

The relationship of superficial external pudendal artery to great saphenous vein was recorded in 50 specimens. In 16 cases (32%) the superficial external pudendal artery was found anterior to great saphenous vein .[Figure-1]. In 26 cases (52%) the superficial external pudendal artery was found posterior to great saphenous vein .[Figure-2].In 8 cases (16%) the superficial external pudendal artery was not visualised at the sapheno femoral junction. [Figure-3]

In all 6 foetal specimens the superficial external pudendal artery was found posterior to the great saphenous vein. [Figure-4]

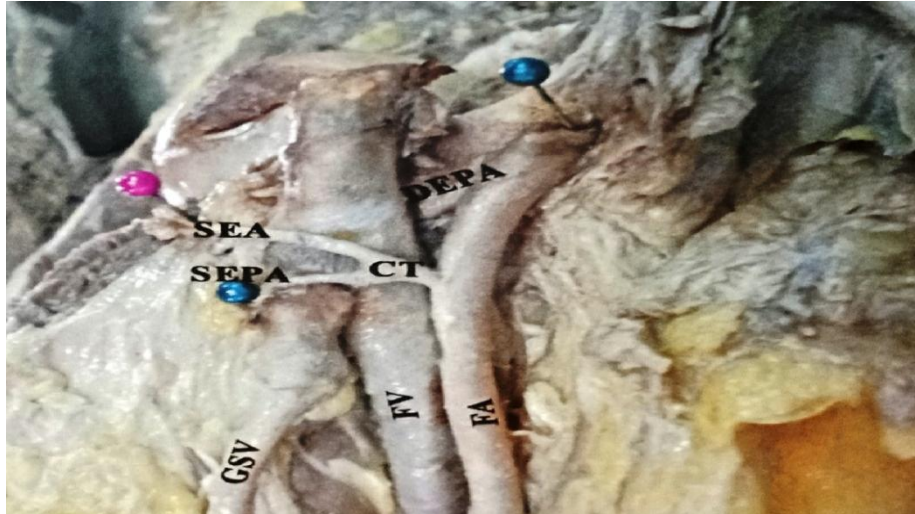
In only one lower limb the duplication of great saphenous vein was noted.[2%],[Figure-5] We found a duplication of great saphenous vein in one limb in the thigh. The second vein was arising from the original great saphenous vein just above the knee and was running parallel to the original one in the whole length of the thigh and joined the original vein to form one vein just before draining into the femoral vein in the right limb of a female cadaver.

### **V. Discussion**

#### **[i] Relationship of great saphenous vein to superficial external pudendal artery.**

Donnelley et al recorded the anatomy of the sapheno femoral junction diagrammatically in 2089 consecutive groin dissections performed to treat primary varicose veins and found that the external pudendal artery crossed anterior to 16.8% of great saphenous vein. In 4-6% it passed posterior to one large tributary or trunk of the vein.[2] Ass Ndiaye et al dissected 54 inguino femoral regions of fresh, black African corpses. They found that the external pudendal artery crossed beneath the arch of the great saphenous vein in 56% of cases and previously in 44% of cases. [3] Preethi Ramya recorded the relationship of external pudendal artery to great saphenous vein in 50 specimens. In 37 cases (74%) the external pudendal artery was not visualised at the sapheno femoral junction. In 8 cases (16%) the external pudendal artery was found to be posterior to the great saphenous vein. In 5 cases (10%) the external pudendal artery was anterior to the great saphenous vein.[4] Hemmathi et al studied 228 patients with varicose veins who underwent surgery. The external pudendal artery was identified during all the surgical explorations. It crossed anterior to the sapheno femoral junction in 39.5% and was posterior in 60.5%. [5] Manerikar et al studied 50 patients who underwent Trendelenburg's operation with stripping of great saphenous vein . They noticed that Superficial external pudendal artery was not visualized in two (4%) patients whereas, it was identifiable in rest 48 (96%) patients. They found that superficial external pudendal artery was crossing anterior to saphenofemoral junction in 20 (40%) patients whereas it was crossing posterior to saphenofemoral junction in 28 (56%) patients. [6]. Souroullas et al studied the anatomy of sapheno femoral junction in a consecutive series of 172 patients undergoing unilateral, primary sapheno femoral junction ligation. The external pudendal artery was identified in 150 cases (87.2%) and was superficial to the great saphenous vein in 36 cases .(20.9%) [7].

In the present study in 8 cases (16%) the superficial external pudendal artery was not visualised at the sapheno femoral junction. In 26 cases (52%) the superficial external pudendal artery was found posterior to great saphenous vein . In 16 cases (32%) the superficial external pudendal artery was found anterior to great saphenous vein.



**Figure.1** Superficial External Pudendal artery anterior to Great Saphenous Vein.




**Figure.2** Superficial External Pudendal artery posterior to Great Saphenous Vein.

GSV-Great saphenous vein; SEPA-superficial external pudendal artery; FV- femoral vein; FA- femoral artery; SEA-superficial epigastric artery.



**Figure-3.** Superficial external pudendal artery not visualised at sapheno femoral junction.



**Figure -4.** Superficial external pudendal artery posterior to great saphenous vein in foetus.

GSV-Great saphenous vein; SEPA-superficial external pudendal artery; FV- femoral vein; FA-femoral artery; FN-femoral nerve. SEPA-Superficial external pudendal artery; GSV- Great saphenous vein; SFJ-Sapheno femoral junction

Therefore the superficial external pudendal artery is anterior to great saphenous vein in 16.8%; 44%; 10%; 39.5% 40%; 20.9% according to Donnelly; Ass ndiadye; Preethiramya ; Hemmathi et al ; Manerikar et al and Souroullas respectively. In the present study superficial external pudendal artery is anterior to great saphenous vein in 32% of cases which is closer to the study of Hemmathi et al and Manerikar.

**Table.no.1.**Relationship of Superficial External Pudendal Artery and Great Saphenous Vein

Authors	SEPA ANTERIOR TO GSV	SEPA POSTERIOR TO GSV	SEPA NOT VISUALISED AT SFJ
Donnelly	16.8%	4.6%	
Ass ndaidye	44%	56%	
Preethiramya	10%	16%	74%
Hemmathi et al	39.5%	60.5%	
Manerikar	40%	56%	4%
Souroullas	20.9%		
Present study	32%	52%	16%

The superficial external pudendal artery is posterior to great saphenous vein in 4.6%; 56%; 16%; 60.5%; 56% according to Donnelly; Ass ndiadye; Preethiramya ; Hemmathi et al ;and Manerikar et al respectively. In the present study the superficial external pudendal artery is posterior to great saphenous vein in 52% of cases which is closer to the study of Ass Ndaide and Manerikar.The superficial external pudendal artery is not visualised at the sapheno femoral junction in 74% and 4% cases according to Preethiramya and Manerikar respectively. In the present study the superficial external pudendal artery is not visualised at the sapheno femoral junction in 16% of cases and this varies with the study of PreethiRamya and Manerikar.

**[ii] Duplication of great saphenous vein**

The great saphenous vein plays a significant part as an autograft for arterial bypass operation; as a result its anatomical variations, including duplication receive great attention.[8] Duplication of great saphenous vein needs to be stressed upon in view of increased incidence of varicosity and cardiovascular diseases and consecutive operative intervention. Embryologically, angiogenesis means sprouting from existing vessels. It is mediated by the vascular endothelial growth factor [VEGF] which stimulates the proliferation of endothelial cells at points where new vessels are to be formed from existing. The duplicated vein in our study may be due to angiogenesis in the posteromedial aspect of the thigh leading to the formation of additional vein.[9].

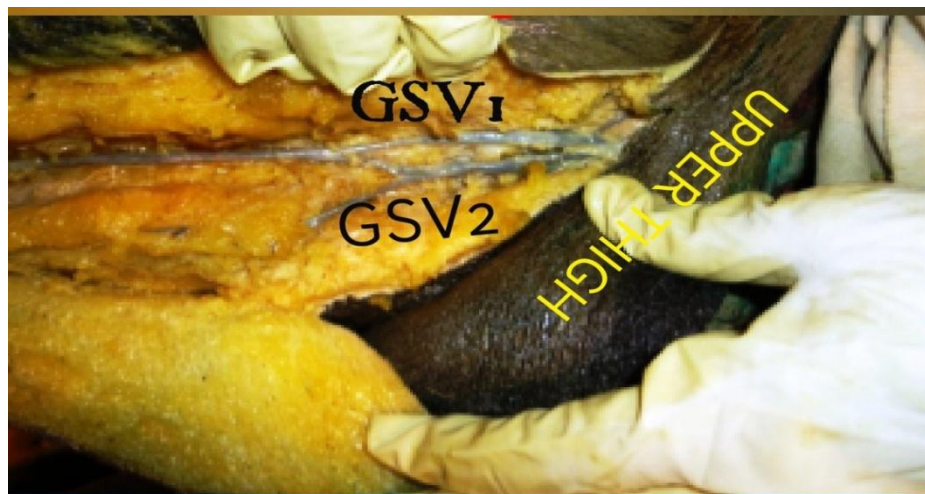
Vinay kumar et all reported unilateral duplication of great saphenous vein in a 62 year old male cadaver.[10].Padavinangadi et al observed a case of double Great saphenous vein on the right lower limb in a male cadaver aged about 60 years during routine cadaveric dissection for undergraduate medical students.[11] .

Kaiser et al (1993) found a double system in 25% of great saphenous veins.[12]Ruoff et al (1987) found a duplicate system in one of the 15 patients [13] Buchbinder et al found a duplicate system in one of the

15 patients.[14].Kupinski et al (1993) found a branching double system in 8% of 1400 limbs[15].Head et al (1995) demonstrated a duplicated system in 11 of 100 patients [16].Van Dijk et al(1996) demonstrated a duplication of the great saphenous vein in 20% of 44 patients [17]. Ricci et al (1999) found a true duplication in 1% of 610 patients [18]. Klitfod and Baekgaard (2003) found a duplication of the great saphenous vein in four of 44 patients [19]. Kockaert et al(2012) stated that now duplex is regarded as the criterion standard for accurate detection of the veins. True duplication of the great saphenous vein is less common than the previous literature has suggested namely 1.6-2%. [20] Corrales et al (2002) found 49% duplications out of 103 phlebographies and only one patient with a true duplication in the thigh and another patient with duplication in the calf. [21].Glasser et al found duplicated great saphenous veins in 3% [22]; Weseem al talalwah et al during routine undergraduate dissection of lower limb found a unilateral double great saphenous vein in the left lower limb of the male cadaver. The incidence of this variation is 1.3 % of all specimens.[23]

**Table.no.2.** Percentage of duplication of great saphenous vein reported by various authors

s.no	Authors	Percentage of duplication of great saphenous vein reported
1	Kaiser et al	25%
2.	Ruoff et al	18%
3.	Kupinski et al	8%
4.	Van djik et al	20%
5.	Ricci et al	1%
6.	Kockaert et al	1.6-2%
7.	Corralles et al	49%
8.	Glasser et al	3%
9.	Waseem al talawah	1.3%
10.	Haytheem [24]	20%
11.	Chen and Prasad [25]	1%
12.	Motwani et al [26]	8-9%
13.	Surekha et al [27]	32%
14.	Present study	2%



**Figure.5.** Duplication of Great Saphenous vein.

In the present we found out the duplication of great saphenous vein in only 1 specimen out of 50 lower limbs dissected . ie 2%. Therefore the present study coincides with the findings of Ricci et al 1%; Glasser et al 3% and Waseem al talalwah et al 1.3%, Chen and Prasad 1% .

According to Kaiser et al, Rouff et al, Kupinski et al, Van Dijk et al, Corrales et al and Surekha et al the incidence of duplication of great saphenous vein is 25%; 18%; 8% 20% 49% and 32% respectively.. As per the present study, the incidence of duplicated great saphenous vein is 2%. Therefore the present study differs with the findings of above said scientists. Duplicated Great saphenous vein can be found below or above the knee. Presence of rare and clinically essential variant form of Great saphenous vein and its duplication should be known to clinicians, radiologists, and phlebotomists.[11]. Haythem et al (2009) found duplicated great saphenous vein in 20% of cases, 10% in the calf and 10%in the thigh. [24]. Neha rai et al dissected 30 formalin fixed cadavers and found maximum frequency of duplication is present in ankle region followed by sapheno femoral junction in thigh region and least in knee region.[28]. Corralles et al studied 103 saphenograms and found duplications of great saphenous vein in 49% of the sapheno grams. Most duplications were present in the thigh [88%]. In the present study there was duplication of the great saphenous vein in the thigh. The second vein

was arising from the original great saphenous vein just above the knee and was running parallel to the original one in whole of the thigh, joined to form one vein and drained into femoral vein. Therefore the present study coincides with Haythem et al and Coralles et al.

## VI. Conclusion

The great saphenous vein is the conduit of choice as a graft in femoro distal and coronary artery bypass operations. The vein is also used for mitral annuloplasty. Great saphenous vein obtained from cadavers and preserved by lyophilisation are an alternative source of venous allografts for arterial reconstructions. Varicosity is one of the most significant clinical problem of superficial veins of the lower limb, its recurrence even after stripping or sclerotherapy procedure warrants the need for meticulously looking for the presence of double GSV. Presence of rare and clinically essential variant form of GSV and its duplication should be known to clinicians, radiologists, and phlebologists. Familiarity with anatomical saphenofemoral junction variations is indispensable for successful varicose venous surgery.

## References

- [1]. Standing S, Borley NR, Collins P et al. Gray's Anatomy 40th ed. Spain: Churchill Livingstone; 2008 pelvic girdle and lower limb-great saphenous vein: 1397 and 1381
- [2]. Donnelly M, Tierney S, Feeley M. Anatomical variation at the saphenous junction. *Br J Surg* 2005;92:322-5.
- [3]. Ndiaye A, Ndiaye A, Ndiaye JM, Diarra O, Diop M, Dia A, et al. The arch of the great saphenous vein: Anatomical bases for failures and recurrences after surgical treatment of varices in the pelvic limb. About 54 dissections. *Surg Radiol Anat* 2006;28:18-24.
- [4]. Preethiramy-a study on the great saphenous vein including its surgical and radiological implications. 2008
- [5]. Hemmati et al. Anatomical variations of the saphenofemoral junction in patients with varicose veins *Acta Medica Iranica*, Vol.50, No.8 (2012).552-555
- [6]. Manerijar.k. et al. Risk factors and Saphenofemoral junction in varicose veins. *Indian J Vasc Endovasc Surg* 2015;2 :134-8.
- [7]. Panos Souroullas et al. the classic saphenofemoral junction and its anatomical variations:: *Phlebology: The journal of venous disease*. Feb 27, 2016
- [8]. Chandni Gupta et al. a morphometric study of arch of the great saphenous vein and its clinical significance; *Journal of Dr. NTR University of Health Sciences* 2016, 5(2).
- [9]. Santulli G [2013]-angiogenesis insights from a systematic overview (USA; New York; Nova Science) ISBN-978-1-62618-114-4.
- [10]. N.Vinay Kumar et al *Indian Journal of Medical Case Reports*, 2017 Vol.6 (4) October-December,
- [11]. Abhinitha Padavinangad et al. .Duplicated Great Saphenous vein and its clinical significance-Anatomical Variation *Journal of Cardiovascular Echography*, 2015 Oct-Dec: 25(4); 116-118
- [12]. Kaiser A, Duff C, Scherrer C, Enzler M, et al. Proximo-distal course of the diameter of the great saphenous vein and distribution of the number of side branches as an inherent difficulty in intra-inguinal arterial in situ by-pass. *Helv Chir Acta* 1993;59:893-6.
- [13]. Ruoff BA, Cranley JJ, Hannan LA, Chang BB, et al. Real time duplex ultrasound mapping of the greater saphenous vein before in situ infrainguinal revascularization. *J Vasc Surg* 1987;8:107-13.
- [14]. Buchbinder D, Semrow C, Friedell ML, Ryan T, et al. B-mode ultrasonic imaging in the preoperative evaluation of saphenous vein. *Am Surg* 1987;53:368-7219.
- [15]. Kupinski AM, Evans SM, Khan AM, Zorn TJ, et al. Ultrasonic characterization of the saphenous vein. *Cardiovasc Surg* 1993;1:513-7.
- [16]. Head HD, Brown MF. Preoperative vein mapping for coronary artery bypass operations. *Ann Thorac Surg* 1995;59:144-8.
- [17]. VanDijk LC, Wittens CHA, Pieterman H, van Urk H. The value of preoperative ultrasound mapping of the greater saphenous vein prior to closed in situ bypass operations. *Eur J of Radiol* 1996;23:235-7.
- [18]. Ricci S, Caggiati A. Does a double long saphenous vein exist? *Phlebology* 1999;14:59-64.
- [19]. Klitfod L, Backgaard N. Treatment of recurrent varices in the region of the long saphenous vein. A follow up study. *Ugeskr Laeger* 2003;165:3013-5.
- [20]. Kockaert M, de Roos KP, van Dijk L, Nijsten T, Neumann M. Duplication of the great saphenous vein: A definition problem and implications for therapy. *Dermatol Surg* 2012;38:77-82. †
- [21]. N.E. Corrales, A. Irvine, C.I. McGuinness, R. Dourado and K.G. Burnand: Incidence and pattern of long saphenous vein duplication and its possible implications for recurrence after varicose vein surgery: *British Journal of Surgery* 2002, 89, 323-326
- [22]. Glasser ST. Variations of the tributaries of the saphena magna at the sapheno-femoral junction: abstract of demonstration. *Anat rec* 1942;82:289-95.
- [23]. Waseem Al Talalwah, Roger Soames: A Duplicated Great Saphenous Vein and clinical significance for varicosity. *Rev Arg de Anat Clin*; 2014, 6 (1); 43-46
- [24]. Haythem A, Al-Sayigh. The incidence of double great saphenous vein among Iraqi people a: case series study. *Med J Babylon*. 2014;6:2
- [25]. Suzi Su, Hsin Chen, Prasad SK. Long Saphenous vein and its anatomical variations. *AJUM* 2009;12(1):28-31 [chen and Prasad]
- [26]. Motwani R, Jain P. Duplication of Great Saphenous vein-anatomical description and its clinical implications. *Int J Biological Med Res* 2013;(3):3372-4.
- [27]. Surekha et al Study of Variation of Great Saphenous Veins and Its Surgical Significance (Original Study) : *IOSR-JDMS VOLUME 17, ISSUE 2, Ver:10:February 2018*
- [28]. Neha Rai, Sheema Nair, Naresh Thanduri, Rajeev Joshi. Variations of great saphenous vein: a cadaveric study in central Indian population : *International Journal of Research in Medical Sciences* 2017 Jul;5(7): 2883-2886.