

Retrieval of Fractured Endodontic Instrument from Root Canal of Mandibular Molar Using Ultrasonic Technique: A Case Report

Dr. Kriti Sharma¹, Dr. Sonal Singh¹, Dr. Manish Agarwal¹, Dr. Rizwan Qureshi²,
Dr. Abhishek Mishra¹

¹(Department Of Conservative Dentistry And Endodontics, Peoples College Of Dental Sciences And Research Centre/ Peoples University, India)

²(Department Of Conservative Dentistry And Endodontics, Bhabha College Of Dental Science, Bhopal, India)

Corresponding Author: Dr. Kriti Sharma

Abstract During Endodontic Treatment, Clinicians May Face Endodontic Procedural Mishaps Such As Broken Instruments. This Condition Is Associated With Potential Risk Of Contamination, Which Compromises The Healing Process. Management Of A Separated Instrument Is Difficult And Time Consuming And Requires Creativity As Well As Clinical Knowledge And Skills. Different Devices And Techniques Have Been Developed To Retrieve Fractured Instrument During The Endodontic Procedure But None Are Consistently Successful. Using Dental Magnification Like Dental Loupes Or Dental Operating Microscopes Makes The Procedure More Successful. This Case Report Describes The Management Of A Broken Instrument In Mesio Buccal Canal And Retreatment Of First Molar Using Ultrasonic Tips.

Keywords – Retrieval, Stainless-Steel File, Ultrasonic, Retreatment

Date Of Submission: 26-03-2018

Date Of Acceptance: 09-04-2018

I. INTRODUCTION

Successful Root Canal Treatment Depends On A Sequence Of Procedures. Sufficient Cleaning And Shaping Of The Root Canal System Is Essential¹. However, Unpleasant Accidents Or Mishaps Such As Fracture Of Endodontic Instruments May Occur During This Step. One Of The Most Important Factors Is Root Canal Anatomy. The Rate Of File Fractures Increases As The Radius Of The Root Canal Curvature Decreases²⁻⁴. Removal Of The Endodontic Instruments Becomes Time Consuming, Risky And Without Surety Of Success⁵.

Rotary Nickel Titanium (Niti) Files Are Extensively Used For Cleaning And Shaping Of The Root Canals Because Of Their Higher Flexibility Compared To Stainless Steel Files. Despite The Superior Qualities There Is Always A Potential Risk Of Breakage Without Visible Warning. Niti Rotary Files Fracture Because Of Excessive Cyclic Fatigue, Torsional Failure Or A Combination Of Both While Most Of Stainless Steel Instruments Fracture Due To Excessive Torque⁶. Various Factors That Predispose The Files To Fracture Are Instrument Design, Dynamics Of Instrument Use, Manufacturing Process, Canal Configuration, Sterilization Process, And Frequency Of Usage Of Instrument⁷. Fractured Fragments Do Not Necessarily Lead To The Failure Of Endodontic Treatment. Study Shows That There Is No Adverse Effect Of The Broken Fragment Retained In The Root Canal System On Healing Of Endodontically Treated Teeth⁸.

Many Techniques, Devices, Instruments And Methods Have Been Used In The Last Several Decades. The Ultrasonic Technique Involves Generating Ultrasonic Vibrations That Are Transmitted To The Fractured Fragment To Loosen It And Then Move It Out Of The Canal⁹⁻¹⁰. Hand Files Or Spreader Were Initially Used To Transmit The Vibration To The Fractured Instrument¹¹⁻¹⁴. However Specially Designed Ultrasonic Tips Are Currently Used. It Is One Of The Most Common Techniques, Like Other Technique, It May Be Associated With Undesired Complications, Particularly If It Is Not Used Carefully¹⁵⁻¹⁷. Studies Have Shown That The Combination Of Ultrasonics With Magnification Provided By A Dental Operating Microscope Has Made The Removal Of Fractured Instruments More Predictable¹⁸⁻¹⁹.

The Aim Of This Case Report Was To Describe The Management Of A Complicated Clinical Case Of Fractured Instrument In Mandibular Molar Using Ultrasonic Vibration Technique.

II. CASE REPORT

A 25 Year Old Male Patient Reported To The Endodontic Department Of Peoples College Of Dental Sciences And Research Center With A Chief Complain Of Pain In Lower Right Back Tooth Region. A Clinical Examination Revealed Dislodged Restoration There Was No Associated Swelling But Tooth Was Tender On

Percussion. Intra Oral Radiographs Were Taken And It Revealed Incomplete Obturation And Opened Access Cavity With Dislodged Restoration Along With Widening Of Periodontal Space In Mesial Root, Small Radiolucency At The Apical End Of Distal Root And Separated Instrument In Mesio Buccal Canal.

Non Surgical Instrument Retrieval Was Planned To Perform Using Dental Loops As An Adjunct. Isolation Was Done With Rubber Dam. Access Cavity Was Modified Using A Safe End Fissure Bur (Dentsply, Maillefer, Ballaigues, Switzerland) To Obtain A Straight Line Access To The Canals. Gates Glidden Drills Were Modified By Cutting The Burs Perpendicular To Their Long Axis At The Maximum Cross Sectional Diameter. These Were Used To Prepare A Staging Platform Coronal To The Fractured Instrument In Mesio Buccal Canal. This Allowed The Use Of Ultrasonic Tips To Trepine Dentine Circumferentially Around The Fragment. Using Dental Loops , An Et25 Tip Of Endo Success™ Retreatment Kit Was Attached To The Ultrasonic Device And Activated Without Coolant At A Low Power Setting For About One Minute To Trepine Dentine Around The Fragment In Mesio Buccal Canal. After Each Activation The Canal Was Irrigated With Sodium Hypochlorite To Cool The Operating Field And Flush Dentine Debris Out Of Canal. After Approximately 12 Min, The Fragment Loosened And Came Out. The Retrieval File Fragment Was 14 Mm Long. Using The Same Tip Gutta Percha Was Removed From The Distal And Mesio Lingual Canal And Radiograph Was Taken And Retrieval Of Fractured Instrument And Gutta Percha Was Ensured.

After Instrument Retrieval Working Length Was Determined Using An Apex Locator And Radiographs. The Root Canals Were Cleaned And Shaped In A Crown Down Manner Using Rotary Niti Files Protaper Gold(Dentsply Maillefer, Ballaigues, Switzerland). Next 2.5% Sodium Hypochlorite And 2% Chlorhexidene Were Used For Irrigating The Root Canal And Calcium Hydroxide (Calcicur, Voco, Cuxhaven, Germany) As An Intracanal Medicament Was Placed. In The Second Visit, Obturation Was Carried Out By Lateral Compaction Technique Using Gutta Percha Points (Protaper, Dentsply,Maillefer, Ballaigues, Switzerland) And Ah Plus Sealer (Dentsply,Maillefer, Ballaigues, Switzerland). The Access Cavity Was Restored With Gic. The Tooth Had Normal Function One Year After The Endodontic Treatment.

III. DISCUSSION

Many Factors May Contribute To Fracture Of Endodontic Instruments²⁻⁴. The Pre Operative X –Ray Of The Current Case Showed Reduced Space In The Pulp Chamber And Narrow Canals, Which Predispose Instruments To Fracture. This Necessitated A Proper Access Cavity, Straight Line Access And Glide Path Preparation, And These Factors Might Not Have Been Fully Considered By The Previous Dentist. Another Possible Reason For Fracture Is The Presence Of Pre-Use Defects Resulting From The Manufacturing Process⁴. Therefore A Single Use Policy Has Been Highly Recommended.

Management Of The Fractured Endodontic Instruments Is A Delicate And Challenging Process That Is Influenced By Several Factors, Such As The Strategic Importance Of The Tooth, The Presence/ Absence Of Periapical Diseases, The Operator's Experience, The Available Armamentaria, Tooth Factors, Patient's Factors, And The Methods, Instruments And Techniques Used²⁰. In Addition, Each Management Procedure May Be Associated With Complications That May Jeopardize The Prognosis Of The Tooth. Consequently The Clinician Should Constantly Reassess The Progress Of Management Procedures And Consider Alternative Treatment Options When Necessary.

Material Type Of The Fractured Instrument Is Also Important Factors To Be Considered During Its Removal. The Stainless Steel Files Do Not Fracture Upon Removal With Ultrasonic, While Niti Instruments May Undergo Further Fracture Due To Heat Buildup When Ultrasonic Devices Are Used For Their Removal. The Stainless Steel Fragments Will Show Early Movement As They Absorb The Ultrasonic Energy Bodily, While In Case Of Niti Fragments, Only The Point Of Contact With The Tip Absorbs The Energy. A Recent Study Reported That Temperature Increases Induced On Niti Fragment's Surface As A Result Of Ultrasonic Activation Were Significantly Greater Than Those Induced On Stainless Steel Fragments. Therefore, Lower Power Settings And Shorter Application Times Were Recommended While Removing Niti Fragments Compared With Those Recommended For Stainless Steel Fragment.

Several Methods And Instrument Retrieval Systems Have Been Proposed For Retrieval Of Broken Instruments From The Root Canals. However None Of Them Can Guarantee 100% Success Or Can Be Considered The Gold Standard For Instrument Retrieval. Due To The Various Advantages Of Ultrasonics In Instrument Retrieval Such As Minimal Dentin Damage And Compatible Tip Designs , Which Can Reach The Apical Third Of The Canal, Ultrasonic Retrieval Was Attempted On Our Case. However, One Must Consider That With The Advent Of Rotary Niti Files, The Occurrence Of Broken Instruments Has Increased Especially In The Hands Of Inexperienced Clinician. Magnification Provided By The Surgical Dental Microscope And Loupes Also Contribute To The Successful Ultrasonic Removal Of Fractured Instrument. Dental Microscope Magnification Increased The Success Rates Of Ultrasonic Removal From The 67% Reported By Nagai Et Al To 88% And 95% In More Recent Reports.

Figures

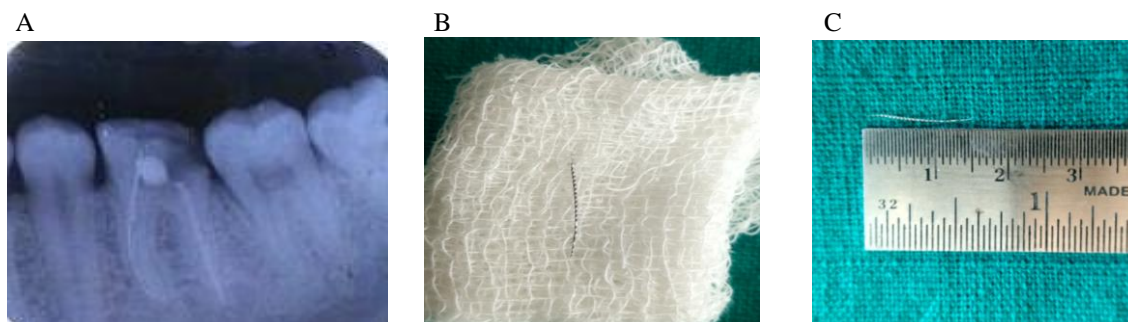


Fig 1 A: Preoperative Iopa Radiograph With 46, B: Retrieved Stainless Steel File, C: 14mm Fractured Fragment Retrieved

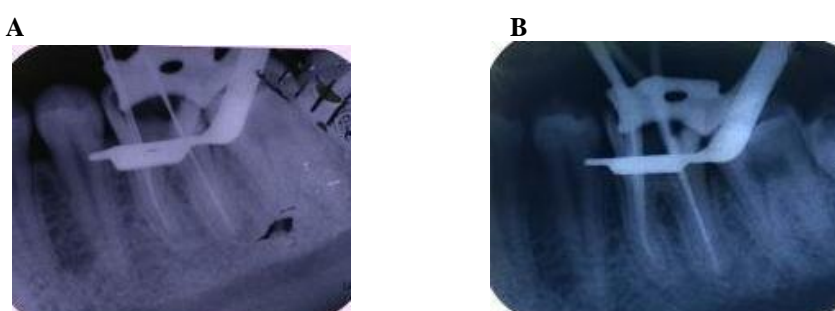
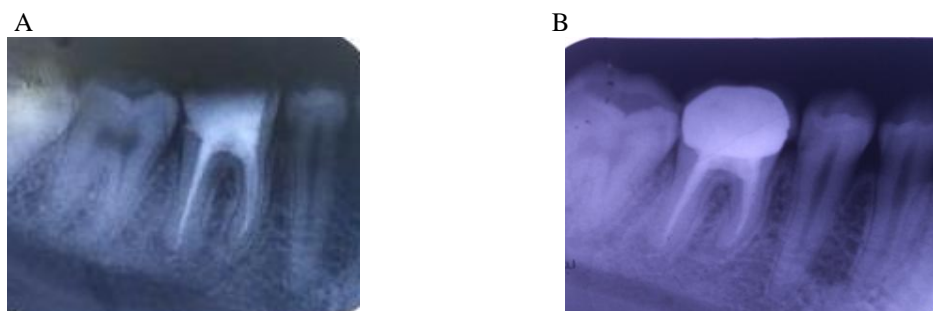


Fig 2 A : Working Length Determination Radiograph Of 46 B: Master Cone Radiograph Of 46



eFig 3 A: Obturation Radiograph Of 46 B: 6 Month Follow Up Radiograph

IV. CONCLUSION

Within The Condition Of The Current Case Report, The Following Can Be Concluded:

- Working Under Stress May Result In Secondary Procedural Errors.
- Clinicians Need To Identify Their Limitations And Consider Referring Cases That Are Beyond Their Ability And Experience.
- Although Dealing With Fractured Instruments Is A Challenging Process, Good Experience As Well As Sufficient Armamentarium Enable Good Management
- The Ultrasonic Technique And The Magnification Contribute To Successful Management Of Fractured Instruments.

REFERENCES

- [1]. W.T. Johnson, W.C. Noblett Isolation, Endodontic Access, And Length Determination M. Torabinejad, R.E. Walton (Eds.), Endodontics Principles And Practice (4th Ed.), Saunders, An Imprint Of Elsevier Inc (2009), Pp. 230-257
- [2]. P. Parashos, H.H.J. Messer Rotary Niti Instrument Fracture And Its Consequences J Endod, 32 (2006), Pp. 1031-1043
- [3]. P.M. Di Fiore A Dozen Ways To Prevent Nickel-Titanium Rotary Instrument Fracture J Am Dent Assoc, 138 (2007), Pp. 196-201
- [4]. A.A. Madarati, D.C. Watts, A.J. Qualtrough Factors Contributing To The Separation Of Endodontic Files Br Dent J, 204 (2008), Pp. 241-245

Retrieval Of Fractured Endodontic Instrument From Root Canal Of Mandibular Molar Using

- [5]. Terauchi Y, O'leary L, Suda H. 2006 Removal Of Separated Files From Root Canals With A New File Removal System. Case Report J Endod 32:789-97
- [6]. Sattapan B, Nervo GJ, Palamara JE, Messer HH. D Effects In Rotary Nickel- Titanium Files After Clinical Use. J Endod. 2000 Mar;26(3):161-5.
- [7]. Parashos P, Messer HH. Rotary Niti Instrument Fracture And Its Consequences. J Endod. 2006 Nov;32(11):1031-43.
- [8]. Spili P, Parashos P, Messer HH. The Impact Of Instrument Fracture On Outcome Of Endodontic Treatment. J Endod. 2005 Dec;31(12):845-50.
- [9]. J.L. Gaffney, J.W. Lehman, M.J. Miles Expanded Use Of The Ultrasonic Scaler J Endod, 7 (1981), Pp. 228-229
- [10]. O. Nagai, N. Tani, Y. Kayaba, S. Kodama, T. Osada Ultrasonic Removal Of Broken Instruments In Root Canals Int Endod J, 19 (1986), Pp. 298-304
- [11]. K.V. Krell, M.W. Fuller, G.L. Scott The Conservative Retrieval Of Silver Cones In Difficult Cases J Endod, 10 (1984), Pp. 269-273
- [12]. L.C. Souyave, A.T. Inglis, M. Alcalay Removal Of Fractured Endodontic Instruments Using Ultrasonics Br Dent J, 159 (1985), Pp. 251-253
- [13]. W. Nehme A New Approach For The Retrieval Of Broken Instruments J Endod, 25 (1999), Pp. 633-635
- [14]. C. D'arcangelo, G. Varvara, P. De Fazio Broken Instrument Removal—Two Cases J Endod, 26 (2000), Pp. 368-370
- [15]. C.J. Ruddle Nonsurgical Retreatment J Endod, 30 (2004), Pp. 827-845
- [16]. G. Plotino, C.H. Pameijer, N.M. Grande, F. Somma Ultrasonics In Endodontics: A Review Of The Literature J Endod, 33 (2007), Pp. 81-95
- [17]. J.R. Ward, P. Parashos, H.H. Messer Evaluation Of An Ultrasonic Technique To Remove Fractured Rotary Nickel-Titanium Endodontic Instruments From Root Canals: An Experimental Study J Endod, 29 (2003), Pp. 756-763
- [18]. N.J. Souter, H.H. Messer Complications Associated With Fractured File Removal Using An Ultrasonic Technique J Endod, 31 (2005), Pp. 450-452
- [19]. A.A. Madarati, A.J. Qualtrough, D.C. Watts Factors Affecting Temperature Rise On The External Root Surface During Ultrasonic Retrieval Of Intracanal Separated Files J Endod, 34 (2008), Pp. 1089-1092
- [20]. A.A. Madarati, M.J. Hunter, P.M. Dummer Management Of Intracanal Separated Instruments J Endod, 39 (2013), Pp. 569-581

Dr. Kriti Sharma "Retrieval Of Fractured Endodontic Instrument From Root Canal Of Mandibular Molar Using Ultrasonic Technique: A Case Report IOSR Journal of Dental and Medical Sciences (IOSR-JDMS), vol. 17, no. 4, 2018, pp 37-40.