

Efficacy of Retrograde Urethrography and Sonourethrography in the characterisation of male urethral strictures - A comparative study.

Dr.Susan Veronica John¹, Dr.Regis George A N², Dr.Harris Paul C³

¹(Department of Radiodiagnosis, Jubilee Mission Medical College and Research Institute, Thrissur, Kerala, India)

²(Department of Radiodiagnosis, Jubilee Mission Medical College and Research Institute, Thrissur, Kerala, India)

³(Department of Urology, Jubilee Mission Medical College and Research Institute, Thrissur, Kerala, India)

Correspondence to: Dr.Susan Veronica John

Abstract: Urethral strictures are a major cause of voiding difficulty in adult males and a common complaint faced by the Urologists. The male urethra is classically imaged by Retrograde Urethrography in combination with Voiding Cystourethrography. Although Retrograde Urethrography is the gold standard investigation for male urethral strictures, it has disadvantages including radiation exposure, limited information on periurethral structures, extravasation of contrast etc. In comparison, Sonourethrography provides an accurate, simple, dynamic, rapid and cost effective imaging of the urethra and periurethral structures which can be repeated without the harmful effects of radiation. Sonourethrography also has the potential to be a valuable preoperative investigation. Nevertheless, it is not yet widely used and this study aims to compare the efficacy of Retrograde urethrography and Sonourethrography in the evaluation of male urethral strictures. Imaging of the male urethra was done by both Retrograde Urethrography and Sonourethrography and findings were correlated. Sonourethrography detected all anterior urethral strictures and pathologies detected by Retrograde Urethrography and also additional periurethral findings, most important of which was spongiofibrosis. However, it was not useful in evaluating posterior urethral strictures. Sonourethrography is an equally efficacious technique for evaluation of anterior urethral strictures with the potential to provide complementary imaging information for surgical planning with the advantage of being free from radiation exposure and contrast reactions.

Date of Submission: 27-03-2018

Date of acceptance: 09-04-2018

I. Introduction

Urethral strictures are a major cause of poor urinary stream and one of the important causes of bladder outflow obstruction¹. It is especially common in elderly and causes a great deal of patient morbidity and hospital expenditure. Various causes include trauma, iatrogenic, infection, inflammation, neoplastic or congenital². An urethral stricture is an abnormal segment of narrowed lumen with irregularity and thickening of the wall due to fibrosis and scarring³. Fibrous scar in the corpus spongiosum is known as spongiofibrosis⁴.

The male urethra is radiographically imaged by Retrograde Urethrography (RGU) and Voiding Cystourethrography (VCUG). Retrograde urethrography which was first popularized by Cunningham in 1910⁵ has been the gold standard for the evaluation of male urethral strictures and the best initial imaging investigation of the urethra. For the evaluation of posterior urethra RGU is not adequate, and combination with VCUG is more superior^{4,6}.

Although it is routinely done, easily available, and the images can be easily interpreted, it has disadvantages. Both of the above techniques provide a static two dimensional image⁷. Appearance of strictures may vary with patient position, urethral distension and degree of penile stretch⁸. Other limitations include exposure to radiation, limited information on periurethral structures, extravasation of contrast into systemic circulation². Reflex contraction of the pelvic muscle due to forceful injection of contrast, can lead to a false diagnosis of stricture².

Characteristics of the stricture and the degree of spongiofibrosis are important factors for selecting the most optimal surgical procedure to avoid recurrence. Most often, RGU tends to underestimate the stricture

length and cannot evaluate periurethral fibrosis. Although MRI has superior soft tissue resolution, it is very costly and not easily available.

Availability of superficial high frequency transducers and high resolution ultrasound, has led to a better imaging of the urethra and periurethral structures⁹. Use of ultrasound to image urethra was first introduced by *McAninch et al*^{5,8}. Sonourethrography (SU), provides a simple, dynamic, rapid and cost effective study which can be repeated without harmful effects of radiation. In contrast to RGU where X-Ray beam is often obliquely aligned, in ultrasound the long axis of the probe can be aligned with axis of the urethra and therefore it is possible to image the urethra in longitudinal and transverse planes, thereby accurately defining the length of stricture^{7,10,11}. Since it has no risk of radiation, it is useful in pediatric strictures. The main limitations are related to inability to visualize the posterior urethral strictures, false positives due to inadequately distended urethra etc¹².

There was no prior experience with Sonourethrography at our hospital and hence, this study was undertaken to compare the effectiveness of both RGU and SU in the evaluation of male urethral strictures.

II. Materials & Methods

This was a descriptive observational study conducted over a period of 2yrs from October 2015 to October 2017 in a tertiary care hospital. A total of 75 patients aged 18 years and above who were referred for RGU suspecting strictures were evaluated. Patients with past history of allergy to contrast media, acute urinary tract infections, and patients not willing to be part of the study were excluded. Relevant clinical details were entered into the proforma.

Study Design: Descriptive observational study

Study Location: This was a tertiary care teaching hospital based study done in the Department of Radiodiagnosis, Jubilee Mission Medical College & Research Institute, Thrissur, Kerala.

Study Duration: October 2015 to October 2017.

Sample size: 75 patients.

Sample size calculation: Sample size was calculated based on pilot study and previous similar studies in literature on the comparison of retrograde urethrography and sonourethrography. A total number of 75 cases were evaluated.

Subjects & selection method: All patients aged ≥ 18 years, visiting the Urology department with difficulty in voiding and clinically suspected to have urethral strictures, referred for Retrograde urethrography during the study period. Only patients fitting into the inclusion criteria were included.

To perform RGU, an initial plain radiograph was taken. Then patient was placed in the right oblique position with the right leg abducted, partially flexed, and left leg stretched above it. Under aseptic precautions, appropriate size Foley's catheter was introduced, and the bulb inflated at fossa navicularis with 1-2 ml of saline. Fluoroscopic imaging was done while slowly injecting 10-20ml of iodinated water soluble nonionic contrast through the catheter. Spot images were obtained when required. Moderate amount traction was exerted on the penis.

With patient in supine position Sonourethrography was performed, using high frequency linear transducer probe. About 20-100ml of Normal saline was continuously instilled with a syringe through the catheter and scanning was done simultaneously. Transducer was placed on the ventral penile surface to visualize the penile urethra upto penoscrotal junction and transscrotally to visualize proximal penile and distal bulbar urethra. Transperineal view was useful for proximal bulbar urethra. Real time images were obtained in both longitudinal and transverse planes.

Findings were correlated considering RGU as gold standard. Strictures were classified based on site. Length of stricture was recorded as either short segment strictures (<2.5cm) or long segment strictures (>2.5cm). Spongiofibrosis was classified as mild (less than one third of corpus spongiosum thickness), moderate (one third to a half), and severe (more than one half). Data collected was entered into Microsoft Excel and analysis was done using statistical software IBM SPSS 20 and epiinfo7. To obtain the comparison between RGU and SU

appropriate statistical methods(sensitivity, specificity, positive predictive value, negative predictive value, kappa)were used.

III. Results and Observations

Total 75 patients suspected to have urethral strictures were evaluated by both techniques, and observations were as follows.Age group of patients varied from 18 to 84 years. Mean age was 49. Lowest age of a patient with a stricture was 24yrs and maximum age of a patient with a stricture was 84yrs.Largest number of the patients,18 patients (24%) belonged to the age group 51-60 yrs (Fig.1). The largest number of strictures were in the age group 61-70 years,22 strictures (32.84%) (Fig.2).

Figure 1: Age distribution of study population

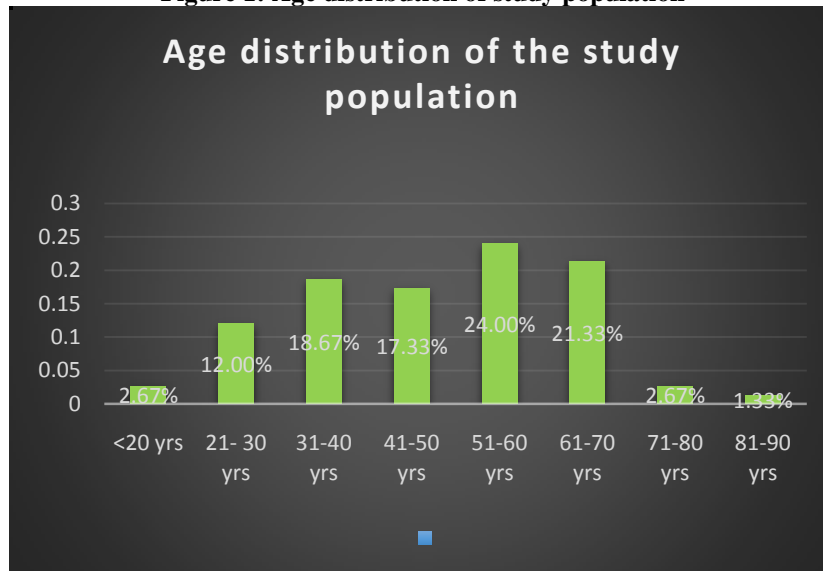
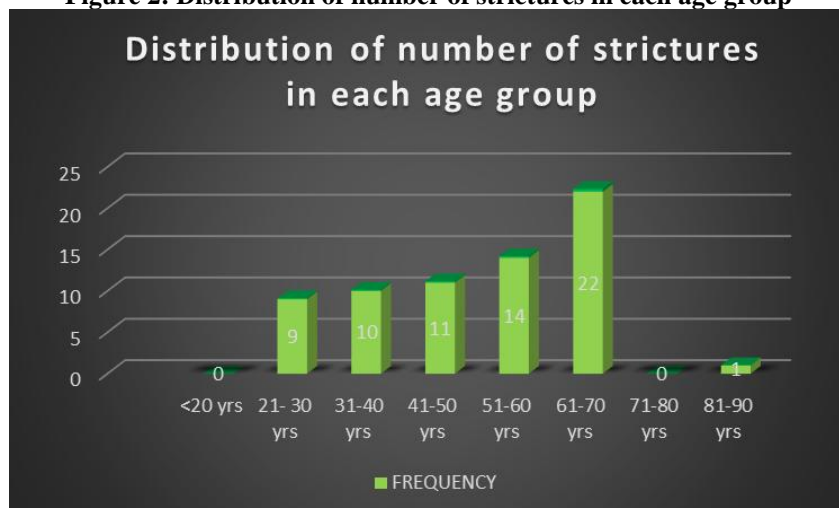


Figure 2: Distribution of number of strictures in each age group



Most common symptoms were poor urinary stream (78.67%), incomplete voiding (34.67%) and straining to micturate(32.00%).The most common etiology was idiopathic (43.75%), followed by iatrogenic (37.50%), infectious (12.50%) and traumatic (6.25%). Total number of patients with strictures were 48(Table 1).One penile stricture was missed by RGU and detected on SU (Case no:6, Fig:11). Single strictures were more common than multiple strictures (Table 2,3). Total number of strictures detected were 67.Of these, 62 were anterior and 5 were posterior urethral strictures.Distribution of location of strictures as in Fig. 3.

Table 1: Distribution of the number of patients with strictures

STUDY	NO:OF PATIENTS WITH STRICTURES	PERCENTAGE OF PATIENTS WITH STRICTURES	NORMAL	PERCENTAGE OF NORMAL	TOTAL
RGU	48	64.00%	27	36.00%	75
SU	43	57.33%	32	42.67%	75

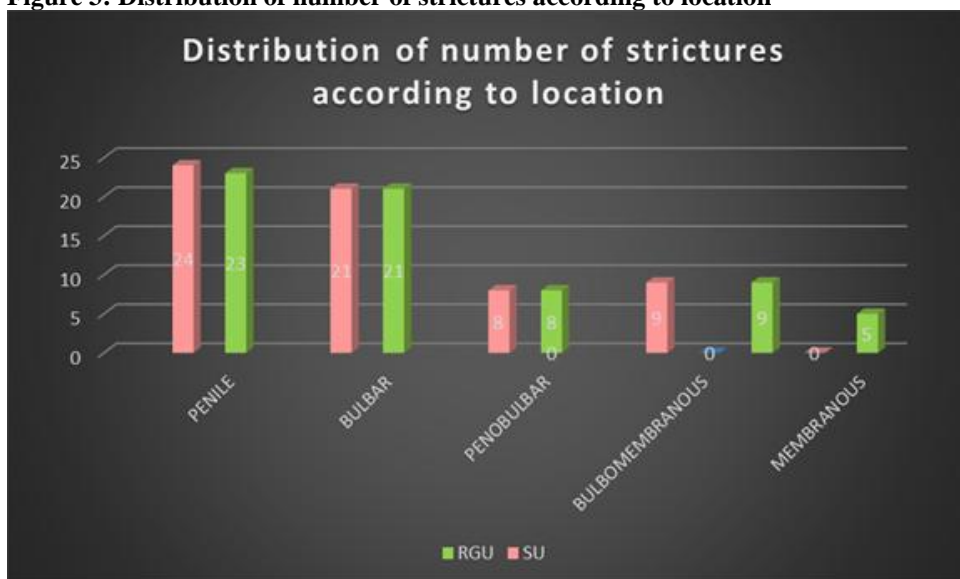
Table 2: Frequency distribution of number of patients with anterior urethral strictures showing single and multiple strictures on RGU

NO:OF PATIENTS WITH ANTERIOR URETHRAL STRICTURES ON RGU	FREQUENCY	PERCENT
NORMAL	32	42.67%
SINGLE STRICTURE	28	37.33%
MULTIPLE STRICTURE	15	20.00%
TOTAL	75	100.00%

Table 3: Frequency distribution of number of patients with anterior urethral strictures showing single and multiple strictures on SU

NO:OF PATIENTS WITH ANTERIOR URETHRAL STRICTURES ON SU	FREQUENCY	PERCENT
NORMAL	32	42.67%
SINGLE STRICTURE	27	36.00%
MULTIPLE STRICTURE	16	21.33%
TOTAL	75	100.00%

Figure 3: Distribution of number of strictures according to location



The length of strictures were more on SU compared to RGU except in bulbomembranous junction in which entire length could not be evaluated with SU. The mean length of strictures on RGU was 1.0186cm and with SU was 1.4297cm. Long segment strictures were detected more on SU (Table 4).

Table 4: Distribution of short and long strictures

STUDY	SHORT SEGMENT STRICTURES(<2.5CM)		LONG SEGMENT STRICTURES(>2.5CM)		TOTAL NO:OF ANTERIOR URETHRAL STRICTURES
	Number	Percentage	Number	Percentage	
RGU	46	75.41%	15	24.59%	61
SU	44	70.97%	18	29.03%	62

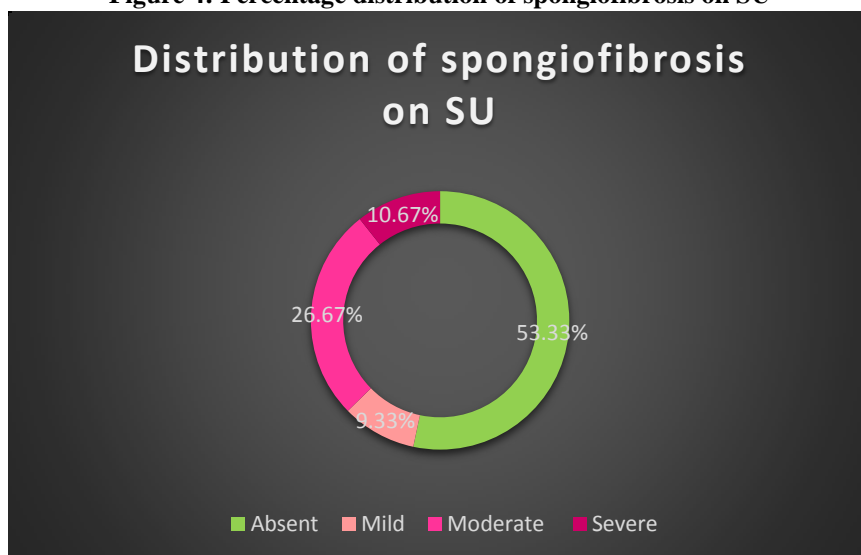
Additional findings in SU like spongiofibrosis, diverticulum and thin septae were not detected by RGU (Table5).

Table 5: Distribution of Additional findings

ADDITIONAL FINDINGS	NO:OF PATIENTS ON RGU	NO:OF PATIENTS ON SU
MUCOSAL IRREGULARITY	18	28
SPONGIOFIBROSIS	0	35
DIVERTICULUM	0	3
THIN SEPTA	0	4
MUCOSAL FOLD	1	1
FALSE TRACT	1	1
LICHEN SCLEROSIS	5	5

Total 35 patients were detected to have spongiofibrosis and majority had moderate spongiofibrosis.(Fig.4)

Figure 4: Percentage distribution of spongiofibrosis on SU



The sensitivity, specificity, positive predictive value and negative predictive value of SU in comparison with the gold standard RGU in detecting number of anterior strictures were 100%,96%,98% and 100% respectively.

p-value was 1.000, Kappa= 0.974. (95% CI:0.92-1.00). The strength of agreement was considered to be very good.The sensitivity, specificity, positive predictive value and negative predictive value of SU in detecting penile strictures were 100%,98%,95.8% and 100% respectively. p-value was 1.000, Kappa= 0.969.(95% CI:0.90-1.00).The strength of agreement was considered to be very good.

In all other locations (except for membranous urethra which cannot be evaluated by SU), the sensitivity, specificity, positive predictive value and negative predictive value of SU in comparison with the gold standard RGU was 100%,100%,100%and 100% respectively.

IV. Cases

Case 1:54 yr old male who presented with poor stream of urine.

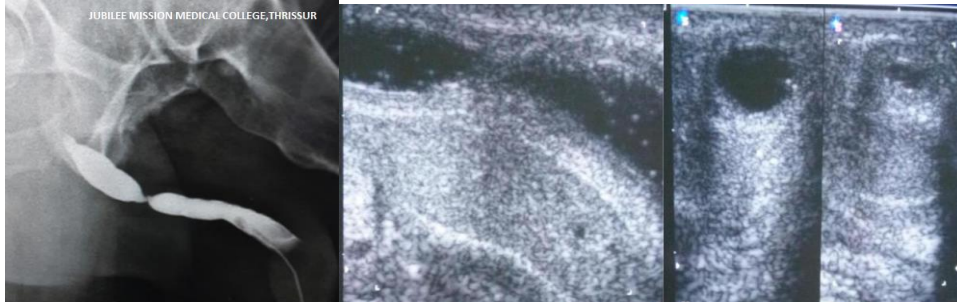


Fig 5: RGU showing a short stricture at penobulbar area. Corresponding SU images : longitudinal view showing short stricture with mucosal thickening and spongiofibrosis and transverse view on the right hand side shows the cross section of the area of stricture and spongiofibrosis.

Case 2:30yr old male,a case of recurrent bulbar strictures.

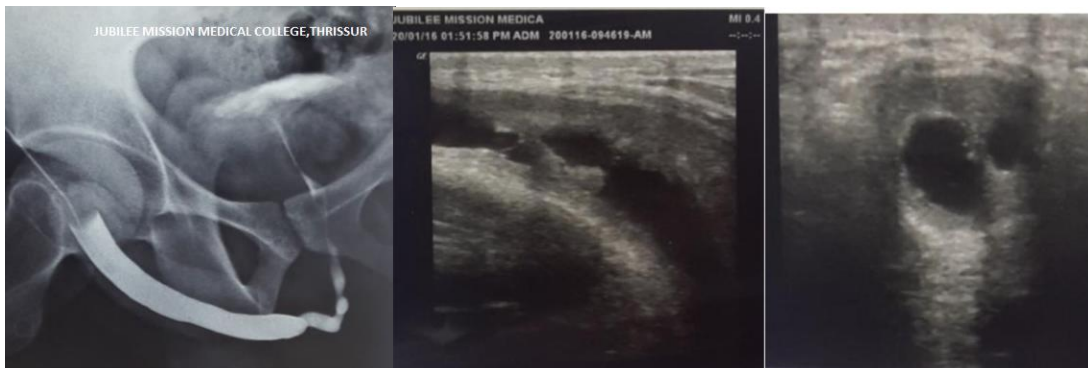

Fig 6: RGU showing multiple short strictures of the bulbar area. Corresponding SU images:longitudinal view showing significant mucosal thickening, irregularity and moderate amount of spongiofibrosis and few thin septae. Transverse view showing the presence of diverticulum which was an additional finding compared to RGU.

Case 3: 35yr old male with poor urinary stream.Past history of urethral catheterisation present.

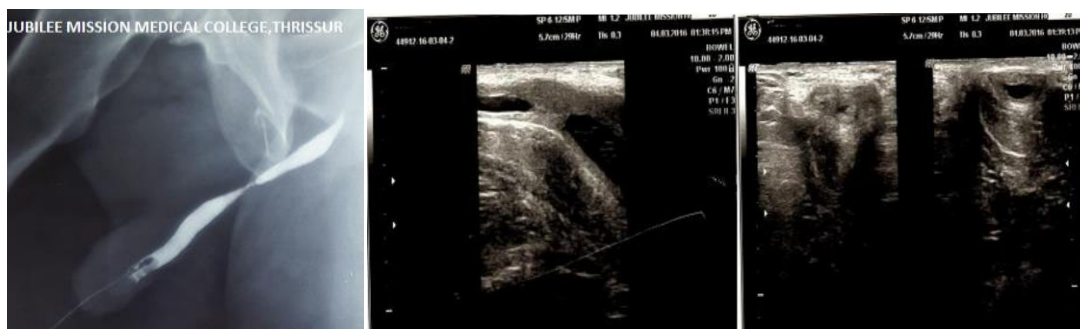

Fig 7: RGU showing a short stricture at penile urethra. Corresponding SU images: Longitudinal view showing a short stricture at the penile urethra with severe luminal narrowing and severe spongiofibrosis. Transverse view on the left hand side showing irregular mucosal thickening and severe luminal narrowing at the site of the stricture.

Case 4: 66 year old male with voiding difficulty. A case of a long segment recurrent stricture. Patient had undergone a buccal mucosal graft for a long stricture extending from the urethral meatus to the bulbar urethra.

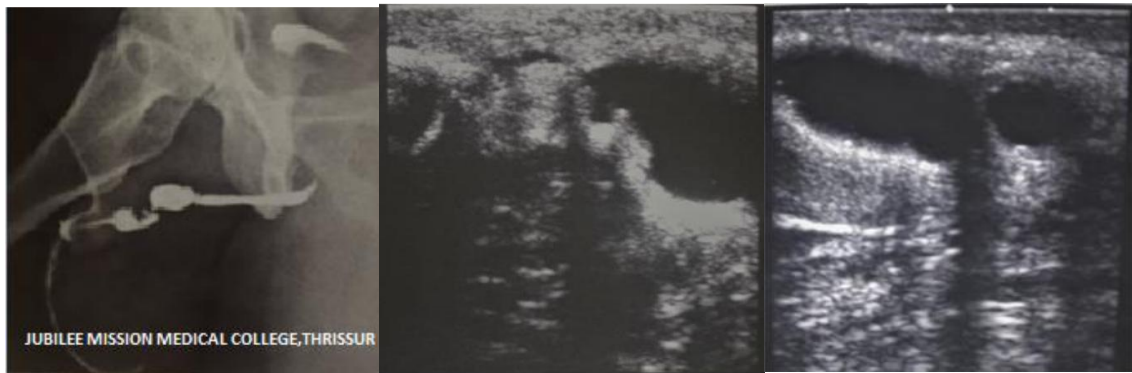

Fig 8: RGU showing showing multiple stricture segments along the mid and lower penile urethra. Severe mucosal irregularity, stenotic and dilated segments with irregular luminal opacification of the urethra with narrowing of distal urethra. Corresponding SU images showing multiple stricture segments along the mid and lower penile urethra. Longitudinal view showing findings similar to RGU. The distal urethra is poorly distensible. Adjacent post stenotic irregularly dilated segment noted with severe spongiofibrosis. Another stricture segment with mucosal irregularity and spongiofibrosis.

Case 5: 64 year old male who presented with poor stream of urine

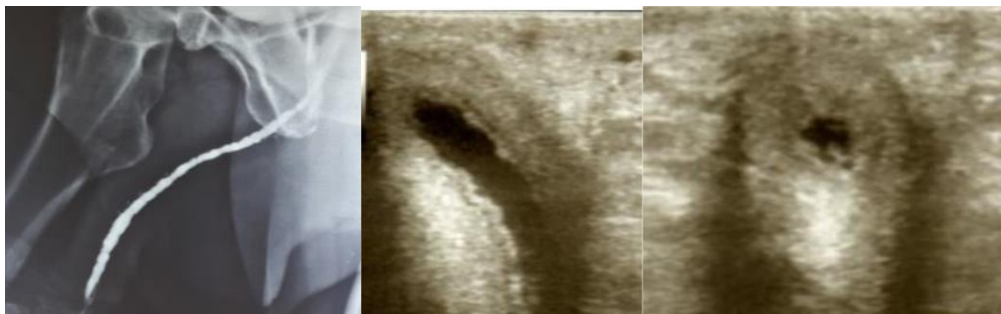

Fig 9: RGU showing poorly distensible irregular urethral lumen. Contrast seen in the periurethral Littre glands. A case of Lichen sclerosis. Corresponding SU images: Sonourethrogram showing findings of Lichen sclerosis similar to RGU. Mucosal thickening, irregularity and spongiofibrosis are seen.

Case 6: 24 year old male with voiding difficulty.

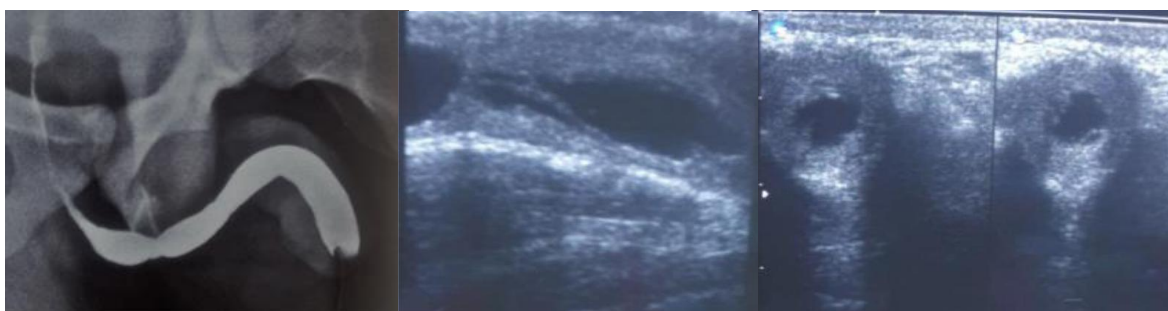


Fig 10: RGU showing a short stricture at the bulbar area. A very subtle mucosal irregularity in the penile region which was initially overlooked was found to be a stricture on sonourethrogram. Corresponding SU images: Longitudinal and transverse views showing bulbar stricture. Note the mucosal thickening, irregularity and spongiofibrosis evident on sonourethrogram.

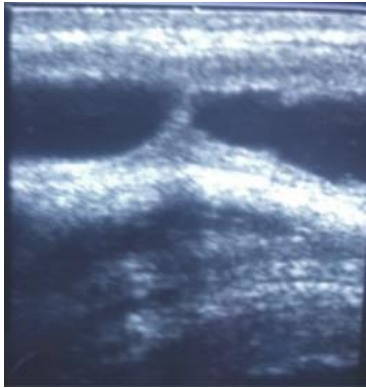


Fig 11: Longitudinal view showing penile stricture on sonourethrogram. This short stricture was overlooked on RGU.

V. Discussion

Urethral strictures are a challenging condition to manage due to a great deal of patient morbidity, in terms of physical and psychological stress and hospital expenditure. Even with expert surgical skills and detailed preoperative evaluation, recurrence can occur.

Although RGU is the gold standard, it may not be adequate in all cases as it tends to underestimate the stricture length and cannot evaluate periurethral pathology. High resolution ultrasound has been reported to be very useful in evaluating the pathologies of the anterior urethra in males owing to its superficial location.

The age group of patients varied from 18 to 84 years with the mean age being 49 years and largest number of the patients belonging to the 51-60 yrs. The largest number of strictures were in the age group 61-70 years. *Santucci et al.*¹³ found that urethral stricture disease increases with age.

The commonest symptoms were poor urinary stream, incomplete voiding and straining to micturate. The most common etiology in the present study was idiopathic followed by iatrogenic, infectious and traumatic. *Alwaal et al.*¹⁴ reported that most urethral strictures were either due to iatrogenic or idiopathic causes.

In our study, recurrent urethral infections were reported in 12.5% of the sample. With effective antibiotic control, infectious urethritis currently accounts for only a small proportion of cases unlike in the past.

10 patients (13.33%) with strictures, had history of urethral catheterization, and 8 patients (10.67%) had history of surgery for urethral strictures. Prolonged catheterization leads to urethral inflammation and ischemia, ultimately leading to stricture formation. 3 patients (4%) with history of trauma had strictures localized to the bulbomembranous region. *Mathur et al.*¹⁵ reported that post traumatic strictures were short, occurring exclusively in the bulbar and membranous urethra.

RGU was able to detect both anterior and posterior urethral strictures while posterior strictures could not be evaluated with SU. No additional pathology was detected by Sonourethrography in those cases which were normal on RGU. One penile stricture was overlooked on RGU and was easily obvious on SU.

The presence of more than one stricture was considered to be multiple. In our study population, single strictures were more common. Similar studies have found single strictures to be more common than multiple strictures^{1,16}. The most number of strictures in the current study were in the penile region followed by the bulbar region. *Alam et al.*¹ also reported a higher frequency of penile strictures compared to bulbar stricture. Other authors like *Priyadarshi et al.*¹⁷ and *Fenton and Morey*¹⁸, reported that bulbar involvement was the most common.

The stricture length was categorized as short strictures less than 2.5 cm in length and long strictures, more than 2.5 cm in length. Most of the strictures in our study were short segment strictures. Long segment strictures were detected more on SU. The length of strictures were more on SU compared to RGU except in bulbomembranous junction in which the entire length could not be evaluated with SU. The mean length of strictures on RGU was 1.0186cm and with SU was 1.4297cm. Several authors have reported that RGU consistently underestimated the stricture length.^{2,6}

Priyadarshi *et al.*¹⁸ opined that SU shows better overall sensitivity and accuracy in predicting stricture and the mean stricture length calculated on SU was found closer to peroperative findings. Additional findings on RGU included mucosal irregularity, false tract and mucosal folds, all of which were detected by SU. SU detected mucosal irregularity in more number of patients compared to RGU. Additional findings on SU that were not detected on RGU included, diverticulum, thin septae and most importantly spongiofibrosis.

A total of 35 patients were detected to have spongiofibrosis. Most of the patients had a moderate degree of spongiofibrosis. Alam *et al.*¹ also reported similar findings and in addition found that sonographic evaluation of fibrosis correlated well with operative findings of fibrosis.

The sensitivity, specificity, positive predictive value and negative predictive value of SU in comparison with the gold standard RGU in detecting number of anterior strictures were 100%, 96%, 98% and 100% respectively. p-value=1.000, Kappa=0.974(95%CI:0.92-1.00). The strength of agreement was considered to be very good. The sensitivity, specificity, positive predictive value and negative predictive value of SU in detecting penile strictures were 100%, 98%, 95.8% and 100% respectively. p-value =1.000, Kappa=0.969(95%CI:0.90-1.00). The strength of agreement was considered to be very good.

In all other locations (except for membranous urethra which cannot be evaluated by SU), the sensitivity, specificity, positive predictive value and negative predictive value of SU in comparison with the gold standard RGU was 100% each.

Mcaninch *et al.*¹⁹ who pioneered the technique of sonourethrography found that sonourethrography was more accurate than RGU. According to Ravikumar *et al.*⁶ Sonourethrography was 100% sensitive and 100% specific, in identifying anterior urethral strictures, with positive and negative predictive values being 100% each. However, the accuracy of sonourethrography decreased drastically in evaluating posterior urethral strictures. Hatgoankar⁸ reported an overall sensitivity of ultrasound in evaluation of stricture to be 97.73% and specificity to be 93.75%. The positive predictive value in their study was 97.73% and negative predictive value was 93.75%.

VI. Conclusion

Sonourethrography proved to be sensitive, specific, and accurate in diagnosis of anterior urethral strictures. When compared with retrograde urethrography, sonourethrography provided a simple, dynamic, cost effective study, which could be repeated without adverse effects of radiation exposure and contrast reactions. Sonourethrography offers important advantages compared with RGU in further characterization of strictures with good sensitivity and specificity.

Modern high frequency ultrasound transducers with good spatial resolution produce excellent longitudinal and transverse images useful for the urologist. The visualization of the degree of periurethral spongiofibrosis which is a critical determinant of appropriate therapy and recurrence rates was an important advantage of urethral ultrasound. As there is no risk of radiation, repeated imaging or follow up scans can be done pre and postoperatively with sonourethrogram. Based on this perspective, we hope it may be of help to the pediatric population also. The main drawback with sonourethrography is that it is not ideal for the evaluating posterior strictures.

In conclusion, sonourethrography in skilled hands proves to be a highly effective imaging modality for diagnosis of anterior urethral strictures. However, it cannot replace retrograde urethrography in the complete evaluation of the male urethra, including posterior urethral strictures, but it can be used as a decisive adjunct in the evaluation of anterior urethral stricture disease.

References:

- [1]. Alam, A. K. M. K., Hossain, M. S., Faruque, M. S., Siddique, F. H., Hossain, M. M., Amanullah, A. T. M., ... & Kibria, S. A. M. G. (2012). Sono-urethrography in the evaluation of male anterior urethral strictures. *Bangladesh Journal of Urology*, 13(2), 51-56.
- [2]. Mandal, S. K., Bhattacharyya, S. K., Mandal, A., Deoghuria, D., & Mandal, P. K. (2012). Sonourethrography in the evaluation of anterior urethral stricture: correlation with retrograde urethrography in male. *Int J Pharm Biomed Res*, 3(2), 77-80.
- [3]. Pushkarna, R., Bhargava, S. K., & Jain, M. (2000). Ultrasonographic evaluation of abnormalities of the male anterior urethra. *Indian journal of Radiology and Imaging*, 10(2), 89.
- [4]. Kawashima, A., Sandler, C. M., Wasserman, N. F., LeRoy, A. J., King Jr, B. F., & Goldman, S. M. (2004). Imaging of urethral disease: a pictorial review. *Radiographics*, 24(suppl_1), S195-S216.
- [5]. Gallentine, M. L., & Morey, A. F. (2002). Imaging of the male urethra for stricture disease. *Urologic Clinics of North America*, 29(2), 361-372.
- [6]. BR, R., Tejus, C., KM, M., & Prashant, D. (2015). A comparative study of ascending urethrogram and sono-urethrogram in the evaluation of stricture urethra. *International braz j urol*, 41(2), 388-392.

- [7]. Ani, C., Akpayak, I., Dakum, N., Ramyil, V., & Shuaibu, S. (2012). Sonourethrography in the evaluation of anterior urethral stricture. *Journal of the West African College of Surgeons*, 2(1), 1-13.
- [8]. Hatgaonkar, A. (2014). A Comparative Study of Sonourethrography and Retrograde Urethrography in Evaluation of Anterior Male Urethral Strictures. *Int J Sci Stud*, 2(2), 5-12.
- [9]. Rauniyar, R. K., Agrawal, C. S., Gupta, M. K., Ahmad, K., Gupta, A., & Baboo, S. (2013). Comparative Study of Sonourethrography and Radiographic Urethrography in Urethral Lesions. *Nepalese Journal of Radiology*, 3(1), 33-39.
- [10]. Shaida, N., & Berman, L. H. (2012). Ultrasound of the male anterior urethra. *The British journal of radiology*, 85(special_issue_1), S94-S101.
- [11]. Khan, N., Modishi, H. M., Tsatsi, L. D. R., & Segone, A. (2004). Comparison of sonourethrography and retrograde urethrography in the evaluation of anterior urethral strictures. *SA Journal of Radiology*, 8(4).
- [12]. Gupta, N., Dubey, D., Mandhani, A., Srivastava, A., Kapoor, R., & Kumar, A. (2006). Urethral stricture assessment: a prospective study evaluating urethral ultrasonography and conventional radiological studies. *BJU international*, 98(1), 149-153.
- [13]. Santucci, R. A., Joyce, G. F., & Wise, M. (2007). Male urethral stricture disease. *The Journal of urology*, 177(5), 1667-1674.
- [14]. Alwaal, A., Blaschko, S. D., McAninch, J. W., & Breyer, B. N. (2014). Epidemiology of urethral strictures. *Translational andrology and urology*, 3(2), 209.
- [15]. Mathur, R., Aggarwal, G., Satsangi, B., Khan, F., & Odiya, S. (2011). Comprehensive analysis of etiology on the prognosis of urethral strictures. *International braz j urol*, 37(3), 362-370.
- [16]. Hatgaonkar, A., & Pendharkar, P. (2014). Sonourethrography in evaluation of abnormalities of anterior male urethra. *IOSR-JDMS*, 13, 53-9.
- [17]. Fenton, A. S., Morey, A. F., Aviles, R., & Garcia, C. R. (2005). Anterior urethral strictures: etiology and characteristics. *Urology*, 65(6), 1055-1058.
- [18]. Priyadarshi, V., Singh, M., Kumar, V., Tiwari, R., Gupta, S. K., & Sehgal, N. (2012). The Role of Sonourethrography In the Evaluation of Anterior Urethral Strictures: A Correlation with Retrograde Urethrography. *UroToday International Journal*, 05(05).
- [19]. Mcaninch, J. W., Laing, F. C., & Jeffrey, R. B. (1988). Sonourethrography in the evaluation of urethral strictures: a preliminary report. *The Journal of urology*, 139(2), 294-297.

Dr.Susan Veronica John "Efficacy of Retrograde Urethrography and Sonourethrography in the characterisation of male urethral strictures - A comparative study." *IOSR Journal of Dental and Medical Sciences (IOSR-JDMS)*, vol. 17, no. 4, 2018, pp 01-10.