

Gastric Actinomycosis – A Rare Case Report

Dr.C. Suganthi, Dr.R.Narmadha, Dr.Barathi Vidhya Jayanthi
Institute of pathology, Madras medical college, Chennai
Corresponding Author: Dr.R.Narmadha

Abstract:

INTRODUCTION:

Actinomycosis of upper gastrointestinal tract especially gastric region is extremely rare accounting for only 24 cases upto date in the literature^(1,2,3). In gastrointestinal tract it commonly occurs in appendix and ileocecal region. Herein, we report a case of primary actinomycosis of gastric region in subtotal gastrectomy specimen.

CASE PRESENTATION:

A 55 year old male came with complaints of vomiting for one month, with no history of fever or abdominal trauma. On Upper gastrointestinal scopy there is a reflux ulcer in the oesophagus 30 cm from incisor teeth. Pylorus is thickened, ulcerated, edematous and narrowed impression given as pyloric stenosis with gastric outlet obstruction. UGI scopy biopsy was done from gastric ulcer and histopathological examination shows ulcer with non-specific inflammation. On Computed tomography imaging, there is irregular wall thickening of pylorus. Patient was clinically diagnosed as case of carcinoma stomach and subtotal gastrectomy was done.

CONCLUSION:

Even though primary gastric actinomycosis has a rare incidence, it should be kept in mind in the differential diagnosis of patient presenting with diffuse wall thickening and infiltration of bowel wall on gastroscopic and imaging studies especially in patients having previous history of abdominal surgery and trauma.

KEY WORDS:

Actinomycosis,

Date of Submission: 16-04-2018

Date of acceptance: 04-05-2018

I Introduction

Actinomycosis is caused by anaerobic, filamentous, gram positive bacteria of actinomyces species, among them common causative agent is actinomyces Israeli. Common sites affected are cervicofacial (31%-65%), abdominopelvic (20%-36%) and thoracic (15%-30%)⁽⁴⁾. Among abdominopelvic actinomycosis common sites affected are appendix and ileocaecal region. It commonly presents with atypical symptoms so they are often misdiagnosed as neoplasms. It is characterized by epigastric pain, abdominal distension, abscess formation, upper GI bleed, tissue fibrosis, draining sinuses^(5,6). Herein, we report a case of primary actinomycosis of gastric region in distal gastrectomy specimen.

II Case Presentation:

A 55 year old male hypertensive patient on medications and known case of cerebro vascular accident with right hemiparesis 15 years back, presented with complaints of vomiting on and off for one month non projectile in nature. History of loss of weight and loss of appetite present for one month. No history of fever. There is no previous history of abdominal trauma. History of previous appendicectomy done in a private nursing home before 15 years. Upper gastrointestinal scopy was performed which shows reflux ulcer in oesophagus 30cm from incisor teeth, fundus body, greater and lesser curvature and antrum of stomach appears normal where as pylorus appears edematous, ulcerated and narrowed. Biopsy was taken from pyloroduodenal orifice ulcer and histopathological examination was done which showed features of ulcer with non specific inflammation. Computed tomography was taken which showed irregular wall thickening of pylorus wall was noted and clinically patient was diagnosed as a case of carcinoma of stomach and subtotal gastrectomy was done.

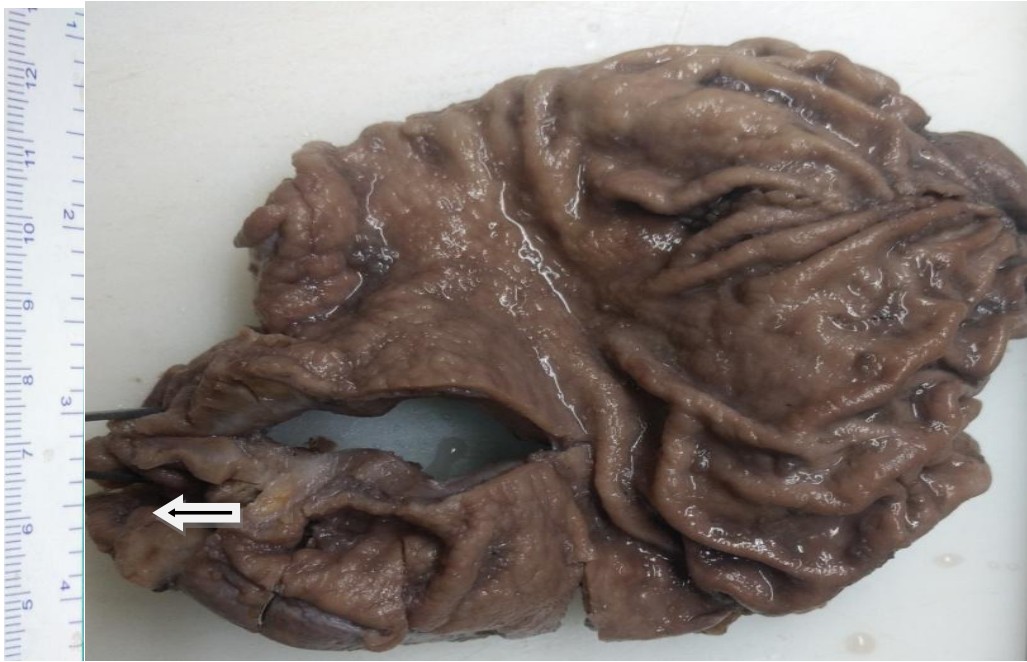

Fig.1. arrow head showing diffuse thickening of pyloric region

Grossly received subtotal gastrectomy specimen measuring 14 cm along greater curvature and 8 cm along lesser curvature. Cut surface shows diffuse thickening of the wall of pyloric region.

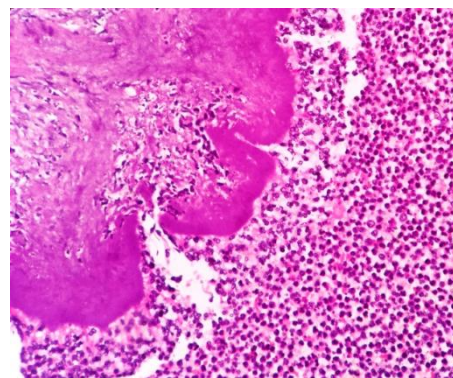
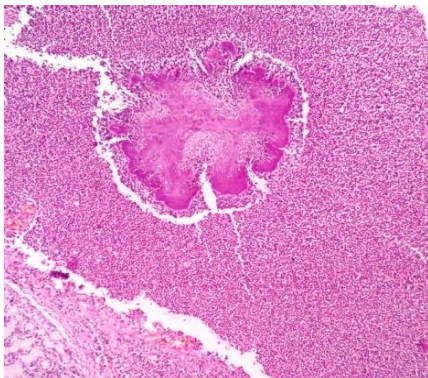


Fig.2. 100x showing gastric mucosa with underlying actinomycotic colony Fig.3. 400x showing splendore hoeppli phenomenon

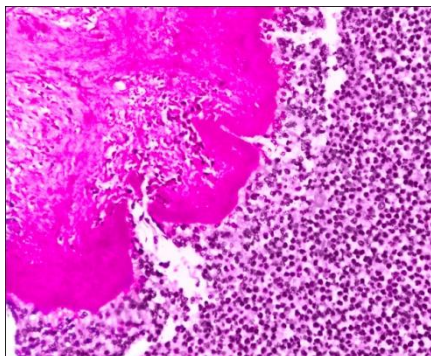


Fig.4. 400x of PAS stain




Fig.5. 100x showing GMS stain

Microscopic examination of sections studied shows gastric mucosa with ulceration, lamina propria shows dense inflammatory cell infiltrate composed of neutrophils, lymphocytes, plasma cells and histiocytes. One foci shows basophilic radiating actinomycotic filaments with splendore hoeppli phenomenon. lymphoid

aggregates and lymphoid follicle formation also seen. PAS (periodic acid Schiff) and GMS (Gomori methanamine silver stain) show positivity in actinomycotic colonies.

III Discussion

Actinomyces often found as normal commensals in oral cavity, gastrointestinal tract and female genital tract. Predisposing conditions like surgery, trauma and immunosuppression due to conditions like leukemia, lymphoma, malignancies leads to destruction of mucosal barrier in turn leading to penetration of these organisms. In most of the cases of gastric actinomycosis the mechanism of route of entry remains unclear.⁽⁷⁾ Primary gastric actinomycosis is extremely rare due to the presence of high luminal acidity of stomach, clinically it presents with low grade fever, epigastric pain, weight loss, upper GI bleeding and sometimes presents with symptoms of gastric outlet obstruction.

Radiological and endoscopic appearances are not specific for gastric actinomycosis. CT may demonstrate an infiltrative lesion with diffuse gastric wall thickening. In our case also CT shows diffuse pyloric region thickening. Gastroscopic biopsy usually present as non specific inflammatory change because it mostly presents as submucosal localization of inflammatory process, so sometimes it may be mistaken as malignancy radiologically. The possibility of gastric actinomycosis can be suspected if endoscopy shows brownish iron negative pigment in the fibrinopurulent exudates it can be confirmed by histopathological examination and demonstrating actinomyces by special stains like PAS, Grocott's and gram stain showing rod like and filamentous bacteria. Nearly 50% of actinomycosis shows presence of sulphur granules, but its presence is not pathognomonic for the disease. In the case under study, histopathology clearly demonstrates the presence of basophilic filaments of actinomycosis with splendore hoeppli phenomenon.

Conclusion:

Primary gastric actinomycosis is an extremely rare disease, it should be kept in mind as differential diagnosis while dealing with gastrointestinal wall thickening because it is commonly misdiagnosed as malignancy radiologically. It is an indolent infection if it is identified, antibiotic treatment is effective and have good prognosis.

References

- [1]. Isik B, Aydin E, Sogutlu G, Ara C, Yilmaz S, Kirimlioglu V. Abdominal actinomycosis simulating malignancy of the right colon. *Dig Dis Sci.* 2005;50:1312–4.
- [2]. Lee YM, Law WL, Chu KW. Abdominal actinomycosis. *Aust N Z J Surg.* 2001;71:261–3.
- [3]. Oksüz M, Sandikçi S, Culhaci A, Egesel T, Tuncer I. Primary gastric actinomycosis: a case report. *Turk J Gastroenterol.* 2007;18:44–6.
- [4]. Choi MM, Beak JH, Lee JN, Park S, Lee WS. Clinical features of abdominopelvic actinomycosis: report of twenty cases and literature review. *Yonsei Med J.* 2009;50:555–9.
- [5]. Lee CM, Ng SH, Wan YL, Tsai CH. Gastric actinomycosis. *J Formos Med Assoc.*, 1996;95:66–68.
- [6]. Khaleel Al-Obaidy, Fatimah Alruwaili, Areej Al Nemer, Raed Alsulaiman, Zainab Alruwaili, Mohamed A Shawarby. Primary gastric actinomycosis: report of a case diagnosed in a gastroscopic biopsy. *BMC Clin Pathol.*, 2015; 15: 2
- [7]. Brown JR. Human actinomycosis: a study of 181 subjects. *Hum Pathol.* 1973;4:319–30.

Dr.C. Suganthi, " Gastric Actinomycosis – A Rare Case Report." *IOSR Journal of Dental and Medical Sciences (IOSR-JDMS)*, vol. 17, no. 4, 2018, pp 42-44.