

## Anchovy Intake To Increase Alveolar Bone Density Of The Mandibles In White Wistar Rats (*Rattus norvegicus*)

Ika Astrina<sup>1</sup>, Ameta Primasari<sup>2</sup>, Dina Keumalasari<sup>3</sup>

<sup>1</sup>Master of Dentistry, Faculty of Dentistry,

<sup>2</sup>Department of Oral Biology, Faculty of Dentistry,

<sup>3</sup>Department of Nutrition, Faculty of Medicine,

Universitas Sumatera Utara, Jalan Dokter Mansyur No. 9 Padang Bulan, Medan, Indonesia, 20155

Corresponding Author: Ika Astrina

**Abstract: Background:** Anchovy (*Stolephorus* Sp.) Is One Of The Best Calcium Resources. Calcium Plays An Important Role In The Formation And Stabilization Of Alveolar Bone So That Its Function And Use Are Optimal. Anchovies Can Be Recommended To Be Consumed As It Is Useful For Bone And Tooth Growth And Capable Of Preventing Osteoporosis. Bone Is Living Tissues Consisting Of Calcium Intracellular Material Such As Bone Matrix And Three Kinds Of Cells, Namely Osteocyte, Osteoblast And Osteoclast. Osteocyte Is The Osteoblast Buried In Lacuna And Mineralized In Bone Matrix By Stellate Morphology. **Method:** This Is A Laboratorial Experimental Research. The Samples Consisted Of Twenty Four White Wistar Rats (*Rattus Norvegicus*) Classified Into Four Groups Consisting Of Six Rats Each. The Groups Were P1 With Feeding Standard Food And 0.3 ml Of Anchovies, P2 With Standard Food And 0.5 ml Of Anchovies, P3 With Feeding Standard Food And 0.7 ml Of Anchovies, And K (Control Group) With Feeding Only Given Standard Food To The White Wistar Rats (*Rattus Norvegicus*). This Research Was Conducted For 30 Days. **Results:** Anchovy Influenced The Amount Of Osteocyte And Alveolar Bone Density Of The Male Wistar Rats' Mandibles. Feeding Anchovies For 30 Days Had A Significant Influence On The Amount Of Osteocyte In Alveolar Bone Of The Wistar Rats' Mandibles Compared To Standard Food, With P Value = 0.01 ( $P < 0.05$ ). **Conclusion:** Feeding Anchovies Increased The Amount Of Osteocyte And Alveolar Bone Density.

**Keywords:** Anchovy, Calcium, Osteocyte, Bone Density.

Date of Submission: 03-03-2018

Date of acceptance: 20-03-2018

### I. Introduction

Bone is the hardest part of the body that occupies approximately one-sixth of the body weight with the two main constituent elements of calcium and phosphate, which are bound in a hexagonal apatite crystal plate in the form of an hydroxyapatite bond with the chemical formula  $[\text{Ca}_{10}(\text{PO}_4)_6(\text{OH})_2]$ . The incorporation of bone marrow hydroxyapatite with bone collagen tissue forms bone hardness and elasticity so that the hardness obtained is not rigid and brittle (Ratih et al., 2013).

Bone is a living tissue consisting of calcareous intercellular material, the bone matrix and three cell types: osteocytes, osteoblasts, and osteoclasts (Junqueira, 2007). Osteocytes and osteoblasts are known to have calcium phosphate binding to proteins or glycoproteins, an indication of the ability to perform matrix calcification. Osteocytes are cells located within the bone matrix, derived from mesenchymal stem cells through osteoblast differentiation. During the differentiation of osteoblasts into adult osteocytes, cells lose most of their cellular organelles. The cell process is packaged with microfilaments and involves morphological changes such as the size of cell diameter, increased intracellular processes, and changes in intracellular organelles (Djuwita et al., 2012).

Bone tissue is dynamic because it is constantly undergoing remodeling. Bone remodeling is intended for homeostatic calcium regulation, repairing tissue damaged by physical movement, minor damage due to stress factors and skeletal formation during growth (Hill, 1998; Fernandez et al., 2006). The imbalance between resorption and bone formation in bone remodeling processes can result in reduced bone density that may lead to bone metabolic disease (Seeman, 2003; Djikstra-Appelman, 2015). Reduced bone cell density can result from reduced osteocytes or lack of mineral content, but both can lead to bone fragility (Manolagas, 2000).

Mandible is where the teeth are attached. Inside the mandible there is a structure that acts as a dental support buffer, one of which is the alveolar bone. The stability of alveolar bone is necessary in the field of dentistry because it affects the success of dental treatment. Bone quality needs to be improved to maintain and maintain alveolar bone stability and reduce the risk of resorption, by maintaining bone mineral content, eg calcium for the calcification process (Madhavan, 2014). Calcification is the process of hardening of organic

tissue due to precipitation, including calcium and phosphorus, in the osteoid tissue to form bone. Calcium plays a very important role in the formation and stability of alveolar bone so that the function and benefits of alveolar bone become optimal (Omami, 2016).

Calcium is the most abundant mineral in the body. Approximately 99 percent of total calcium in the body is found in hard tissues especially in the form of hydroxyapatite, but only a small part is present in the plasma of extravascular fluid (Bolland et al, 2015). Calcium plays an important role in the body, in the formation of bones and teeth; in the regulation of cell function in extracellular and intracellular fluids for nerve transmission, muscle contraction, blood clotting, and maintain cell membrane permeability. The availability of calcium in the body comes from some of the ingredients that are consumed as the source. Furthermore, this calcium element is stored in a network of bone sponges (Hoenderop et al, 2005). The calcium needs of each individual are different in each age. Less calcium intake than requirement can lead to decreased bone density (Chen et al, 2002; Rose et al., 2011).

Bone density or density is the mineral content of bone in an area of bone with units of gram form percent of square bone (Prasetyastuti, 2010). In addition to the intake of mineral nutrients such as calcium, there are several factors that can affect bone density, intrinsic and extrinsic factors. Intrinsic factors are influenced by sex, genetics and hormones, while extrinsic factors are caused by vitamin D and physical activity (Wilkins, 2007; Rittwegger, 2006).

Calcium is not only contained in milk, but other foods such as bone soup, green vegetables such as spinach, fruits, nuts, salmon, and anchovies. Anchovy is a good source of calcium food (Shankar, 2013). Green vegetables, beans, tofu and tempeh are good sources of calcium as well, but they contain many substances that can inhibit the absorption of calcium such as fiber, phytic acid and oxalic acid (Hardinsyah et al. 2008).

Anchovy occupies an important position among 55 fish species that have economic value after fish overpass, bloating, lemuru, tembang and tongkol. Data of fishery director general shows that there is an increase of anchovy production by 11.73% during 1990-1993 (Directorate General of Fishery, 1995). Anchovy suppliers or distributors are from Belawan, Tanjung Balai, Asahan, Ledong Batu Bara and Sibolga areas.

Anchovy (*Stolephorus* sp.) Is an anchovy typical of Medan city with some chemical content that contains high enough calcium, protein, minerals, vitamins and other nutrients that are very beneficial for health and intelligence. Protein fish anchovy contains several kinds of essential amino acids. Anchovy is one of the best sources of calcium. Calcium in anchovies is useful to prevent bone loss, bone and tooth growth. Calcium anchovy can smooth the relationship between the declining cells during a person suffering from stress and depression and controlling blood pressure. The advantage of anchovy compared to other fish is its small body shape so it is easy and practically consumed by all ages. Anchovy rice is one of the favorite fish because it starts from the head, meat until the bones can be consumed directly. Anchovy rice (*Stolephorus* sp.) In addition to easily obtained and consumed by the community also contains bone-supporting minerals. Therefore, further study is needed on the effect of anchovy consumption on the number of osteocytes and the density of the lower alveolar bone in white Wistar rats.

## II. Materials And Methods

Twenty four white male white Wistar strains were divided randomly into four groups: P0 (control), P1 (treatment 1), P2 (Treatment 2), P3 (Treatment 3), six white Wistar rats in each group. The control group (P0) was a standard fed rodent for 30 days while the 1st treatment group (P1) of mice fed standard and added with anchovies made in infusa form 0.3 ml, the treatment group 2 (P2) which was fed standard and added with anchovy made in infusa form 0.5 ml, treatment group 3 (P3) mice fed standard and added with anchovy made in liquid form of 0.7 ml. Everyday observations were made on the weight of white Wistar rats and their health conditions during the study.

Anchovy is given orally for 30 days. The first step begins with suctioning anchovy infusa using a sonde made of rubber. Sonde is inserted through the mouth slowly until it reaches the stomach. Then the liquid anchovy is sprayed. Giving of anchovy is done twice daily in the morning at 08.00 - 09.00 WIB then afternoon at 15.00-16.00 WIB. On the 30th day after Feeding anchovy in white Wistar rats then the rats will be euthanized by using ketamine-xylazine with doses of 75-100 mg / kg + 5-10 mg / kg intraperitoneally with duration of 10-30 minute. Rats fixed on the work table and then carried out the bone tissue of the mandible with a scalpel then placed in a closed container containing a bufferformalin 10% and sent to the laboratory for microscopic preparations and then measured the number of osteocytes in the lower alveolar bone using the Olympus CX22 microscope connected to the computer that has the Software Image Raster.

### III. Results

Results of a white Wistar alveolar bone study of white Wistar rats (*Rattus norvegicus*) fed anchovies and standard feeds showed a higher osteocyte count compared to a standardized Wistar white mandibular alveolar bone (*Rattus norvegicus*).

**Table 1.** Average number of osteocyte of mandible alveolar bone in 5 large field view (LPB) in groups P1, P2, P3 and control

Subject	Average Number of Bone Alveolar Bone Osteocytes In 5 Large Field / LPB (units)			
	(P1)	(P2)	(P3)	(K)
1	13,4	13,4	26,4	6,6
2	12,6	12,2	17,4	6,4
3	7,2	9,6	21,2	4,6
4	15	20,8	19	4
5	14,4	15,4	19,8	5,4
6	35	22	17,6	5,4

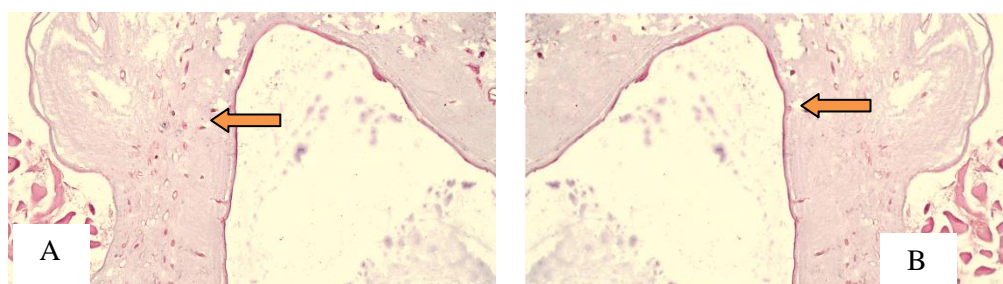


Figure A. Number of osteocytes in the mandibular alveolar bone of a standard white Wistar rat fed with anchovy infusa, and B. The number of osteocytes in the mandibular alveolar bone of a standard Wistar white rat.

**Table 2** Average and standard deviations of osteocyte of mandibular alveolar bone of white Wistar rat with standard feeding (K) and 0.3 ml (P1), 05 ml (P2), and 0.7ml (P3) (p <0.05)

Group	Average osteocyte	P
K	5,40	0,01
P1	16,27	
P2	15,57	
P3	20,23	

Table 2 above is the standard and standard deviation of the osteocyte count and the density of the lower alveolar bone of a white Wistar rat (*Rattus norvegicus*) with standard feeding (K) and standard feeding plus 0.3 ml (P1) 05 ml (P2), and 0.7ml (P3). The highest number of osteocytes in the P3 group was  $20.23 \pm 13.29$  and the lowest osteocytes in the control group were  $5.40 \pm 2.01$ . The value of  $p = 0.01$  is less than 0.05, meaning that there is a significant difference between the number of osteocytes of the white Wistar bone alveolar osteocytes treated with the control group.

The results of a white wistar alveolar bone study of white Wistar rats (*Rattus norvegicus*) fed on anchovy infusa as much as 0.5 ml (P2) and 0.7 ml (P3) showed greater bone density than the mandible alveolar bone of Wistar rat white (*Rattus norvegicus*) fed standard (K) and 0.3ml (P1).

### IV. Discussion

The number of osteocytes in the group of white Wistar mice fed the standard feed plus the feeding of anchovy as a treatment and standard feed only as control showed varying values that was in the group of white Wistar mice fed standard and highest anchovy in group P1 on the subject the sixth is 35 and the lowest is in the P2 group on the third subject of 9.6, whereas in the group with only the highest standardized feed (K) is found in the control group in the first subject is 6.6 and the lowest is in the control group on the fourth subject ie 4, this is probably because prior to the study do not do counting the number of osteocytes. This difference in osteocyte count may also be due to stress levels in mice that affect hormones and physical activity. Physical activity will affect the increase of bone mass and Optimization The greater the physical activity the bone density will increase. The amount of osteocytes and reduced mineral content will result in reduced cell density (Djuwita et

al, 2000). Hormones that are influential in the increasing number of bone-forming cells in this study are calcitonin and Parathyroid Hormone (PTH).

Table 1 shows the number of osteocytes in the group of rats fed anchovies and the standard feed (P1; P2; P3) was higher than the control group (K). This is because anchovy is a type of anchovy that contains a lot of calcium. The content of fresh anchovy includes 77 kcal of energy; protein 16g; fat 1.0 g; calcium 500 mg; phosphorus 500 mg; iron 1.0 mg; Vit A RE 47; and Vit B 0.1 mg (Djuhanda, 1981). Calcium content in fresh anchovy, dry fresh and salted dried per 100 grams, are 500, 2,381, and 2,000 mg, respectively, while their phosphorus levels are 500, 1,500, and 300 mg / 100 g (Astawan, 2008 ). In previous research, anchovy was reportedly used as a therapeutic agent in white mice with fibrous osteodystrophy. According to Nursifah (2012), fresh anchovy with CA: P ratio of 1: 1.5 for 5 weeks can increase the level of calcium in the blood and followed by bone repair on the microscopic picture of the femoral bone undergoing fibrous osteodystrophy.

Table 2 shows the mean and standard deviation values of each group. It is seen that the number of osteocytes of the lower alveolar bone of white Wistar rats with 0.3 ml (P1), 05 ml (P2), and 0.7ml (P3) of the anchovies is greater than the control group (K)  $<0.05$ . The mean and standard deviation of osteocytes in the P1 group was  $16.27 \pm 12.85$ ; P2 is  $15.57 \pm 7.1$ ; P3 is  $20.23 \pm 13.29$  while in the control group is  $5.40 \pm 2.01$ . The amount of alveolar bone osteocytes in the treatment and control group obtained varied where there was too high data and there was too low data from the average, as can be seen from the Homogeneity of Variance, showing the data not normally distributed and unequal variant values, so as to ensure p value is done Kruskal-Wallis test.

Anova and Kruskal-Wallis results showed that at  $\alpha = 0.05$  the total osteocyte of the lower alveolar bone of the Wistar white rats treated group (P1, P2, and P3) and the control group differed significantly ( $p < 0.05$ ). At the 5% significance level the average treatment and control group differed. The results of statistical tests of this study indicate that there is an effect of anchovy to the amount of osteocytes of alveolar bone of white Wistar rat. Increased bone density of mandibles of white Wistar rats consuming fishthe anchovy is possible because of the components contained in the anchovy. Calcium content obtained from anchovies can increase osteoblasts into osteocytes so bone formation can occur quickly and it is expected that bone density will also increase so as to help bone metabolism, among others, protein and various minerals (calcium, and phosphorus).

Protein in anchovy is digested in the stomach by pepsin and then absorbed in the form of amino acids and delivered to the blood so that all amino acid molecules into the cell then the amino acids combine with each other with peptide bond to form collagen cell protein. The main nutrients in anchovy that have an important role in density formation are calcium and phosphorus because this mineral is the main constituent of hydroxyapatite crystals ( $\text{Ca}_{10}(\text{PO}_4)_6(\text{OH})_2$ ) bone. The hydroxyapatite crystals are an important element in bone density The combination of bone hydroxyapatite with bone collagen tissue forms violence and flexibility so that the hardness is not rigid and brittle (Ratih et al., 2013).

Calcium and phosphorus in anchovy are thought to increase bone density because supplemental calcium increases the concentration of the extracellular calcium that can trigger mobilization and proliferation of osteocytes as bone-forming cells. This increase increases the synthesis of bone matrix. Based on this study, an additional diet of anchovy may increase the number of osteocytes and bone density of the lower jaw in white male Wistar rats. Thus, the anchovy may be used as a good food for bones, especially the bones of children who are needed during growth, further research is needed to create an anchovy-based food.

## V. Conclusions And Recommendations

### Conclusion

1. Anchovy raises the amount of osteocyte of the lower alveolar bone of a white Wistar rat (*Rattus norvegicus*). There was a higher osteocyte count in the white Wistar group of rats fed anchovy in both P1, P2 and P3 was significantly different with mice fed standard (K) with  $p = 0.01$  ( $p < 0.05$ )
2. Anchovy raises the density of the lower alveolar bone of a white Wistar rat (*Rattus norvegicus*).

### Suggestion

1. Research is needed with longer research time due to calcium-induced effects in increasing alveolar bone density.
2. Need to do further research by looking at Growth Factor because the process of proliferation and differentiation of osteoblasts into osteocytes is influenced by Growth Factor.

## References

- [1] Alexander GR, Alesha BC, Charles HT, 2006. Biomechanical and molecular regulation of bone remodelling. *Annu Rev Biomed Eng*;8:455-98.
- [2] Allen M.R., Burr, D.B, 2013. Techniques in Histomorphometry. In : Burr, D.B.,Allen, M.R., editors. *Basic and Applied Bone Biology*. 1st Ed. London.Elsevier Science and Technology Books. p. 135 – 7.
- [3] Applemen-Djikstra NM, Papapoulos SE, 2015. Modulating bone resorption and bone formation in opposite directions in the treatment of postmenopausal osteoporosis. *Drugs*;75(10):1049-58.

- [4] Aryati EE, Dharmayanti AWS, 2014. Manfaat ikan teri segar (*Stolephorus sp.*) terhadap pertumbuhan tulang dan gigi. ODONTO Dental journal;1(2):52-6.
- [5] Balasch J, 2003. Sex steroids and bone: current perspectives. Human Reproduction Update.;9(3):207-22.
- [6] Bellido T, 2012. Osteocytes-driven bone remodeling. Calcif Issue Int;94(1):25-34.
- [7] Bolland dkk, 2015. Calcium intake and risk of fracture: systematic review. BMJ ;351:4580.
- [8] Bonewald LF, 2011. The amazing osteocyte. Journal of bone and mineral research;26(2):229-38.
- [9] Bozzini E C, Graciela C, Rosa M A, Clarissa B. Bone mineral density and bone strength from mandible of chronically protein restricted rat. Acto odontol latinoam 2011, 24 (3): 223-28.
- [10] Capulli M, Paone R, Rucci R, 2014. Osteoblast and osteocyte: Games without frontier. Arch. Biochem Biophys;1-10.
- [11] Chen dkk. 2002. Effect of low or high dietary calcium on the morphology of the rat femur. Histol Histopathol;17:1129-35.
- [12] Cole, R.E. 2008. Improving Clinical Decisions for Women at Risk of Osteoporosis: Dual-Femur Bone Mineral Density Testing. JAOA. 108(6) :289 - 95.
- [13] Creedon A. and Cashman K.D. (2001). The effect of calcium intake on bone composition and bone resorption in the young growing rat. Br.J. Nutr. 86, 453-459.
- [14] Cullinane DM, 2002. The role of osteocytes in bone regulation: Mineral homeostasis versus mechanoreception. J Musculoskeletal Neuron Interact;2(3):242-4
- [15] Dallas SL, Bonewald LF, 2010. Dynamic of the transition from osteoblast to osteocyte;1192:437-43
- [16] Davey RA, Findlay DM, 2013. Calcitonin: Physiology or fantasy? JBMR;28(5):973-9
- [17] Djuwita I, Pratiwi IA, Winarto A, Sabri M, 2012. Proliferasi dan diferensiasi sel tulang tikus dalam medium kultur *In Vitro* mengandung ekstrak batang *Cissus quadrangula* Salisb. *Extract. Jurnal Ked.Hewan* ;6(2):75-80.
- [18] Fernandez I., M.A.A.A. Gracia, M.C Pingarron, and L.B. Jerez, 2006. Physiological bases of bone regeneration II. The Remodelling process. Med Oral Patol Cir Bucal;11:151-7.
- [19] Forstein, D.A., Bernardini, C., Cole, R.E., Harris, S.T., Singer A. 2013. Before the Breaking Point: Reducing the Risk of Osteoporotic Fracture. JAOA. 113(2) (Suppl. 1) : S5 - S24.
- [20] Franz-Odenaal T, Hall B.K, 2005. How Osteoblast become osteocytes. Development dynamic J;235:176-90.
- [21] Gosink J, 2015. Parathyroid hormone, calcitonin and vitamin D testing in calcium and bone metabolic disorders; Medlab Magazine ;2:26-8.
- [22] Hamrun N, Hatta M, 2011. Polimorfisme gen vitamin D reseptor pada penderita periodontitis kronis. JST Kesehatan ;1(2):165-72.
- [23] Heino T.J, Hentuntn T.A. 2008. Differentiation of Osteoblast and osteocytes from mesenchymal stem cells. Current stem cell research & therapy ;3:131-45.
- [24] Hertiningsih, Nitsuwirjo, Wiryastuty. 2013. Respon tulang, ginjal dan kelenjar paratiroid tikus Wistar putih yang mengkonsumsi pakan mengandung fosfor bervariasi. Jurnal Sain Veteriner :110-9.
- [25] Hill, PA and M. Orth. 1998. Bone Remodelling. British Journal of Orthodontics 25:
- [26] Hoenderop J.G.J, Nilius B, Bindels R.J.M. 2005. Calcium Absorption across epithelia. Physiol Rev 85:373-422.
- [27] Indah DE, 2013. Minyak ikan lemuru menurunkan apoptosis osteoblas pada tulang alveolaris tikus Wistar putih. Dental Jurnal;46(4):185-9.
- [28] Junqueira, L.C., Carneiro, J, 2007. *Histologi Dasar : Teks & Atlas*. (Tambayong, J., Pentj) Ed 10, 134 - 6.
- [29] Kawiya S. IK. 2009. Osteoporosis pathogenesis diagnosis dan penanganan terkini. J Peny Dalam;10(2):157-70
- [30] Kumar R, Thompson JR, 2011. The regulation of parathyroid hormone secretion and synthesis. J Am Soc Nephrol;22:216-224.
- [31] Liu P dkk, 2014. Effect of calcitonin on anastrozole-induced bone pain during aromatase inhibitor therapy for breast cancer. Genetic and Molecular Research;13(3):
- [32] Manolagas, S.C, S.Kousteni and R.L Jilka. 2002. Sex steroid and bone. Recent Prog. Horm. Res;57:385-409.
- [33] Murphy E Williams. 2009. Hypocalcemia. Medicine;37(9):465-8.
- [34] Masyitha, D. 2006. Struktur Mikroskopik Tulang Mandibula pada Tikus Ovariectomi dan Pemberian Pakan Rasio Fosfat / Kalsium Tinggi. *Media Kedokteran Hewan*. 22(2) : 112 - 7
- [35] National Library of Medicine. 2011. *Bone Density*. Available from: <http://www.nlm.nih.gov/medlineplus/bonedensity.html>.
- [36] Opatowsky S, 2002. Dietary calcium intake, fractional calcium absorption, urinary calcium excretion, and levels of calcitropic hormones and bone markers in young, healthy Chinese-American and Caucasian women. Doris duke medical students journal;1:44-50
- [37] Peacock M, 2010. Calcium metabolism in health and disease. CJASN ;5(1):23-30.
- [38] Prasetyastuti, 2010. Pengaruh polymorfisme PVUIII gen reseptor estrogen alfa terhadap kadar kalsium dan phosphate serum pada wanita postmenopause. Berita Kedokteran Masyarakat ;26(1):29-32.
- [39] Pratomo, F.A., Padaga, M.C., Pramana, A.W.M. 2012. Efek Pemberian Tepung Tulang Ikan Tuna Madidihang (*Thunus albacares*) pada Tikus Putih (*Rattus norvegicus*) Model Ovariectomi Berdasarkan Histopatologis Tulang Femur dan Ekspresi TNF- $\alpha$  (*skripsi*). Malang : Universitas Brawijaya.
- [40] Pravina P, Sayaji D, Avinash M, 2013. Calcium and its role in human body. International Journal of Research in Pharmaceutical and Biomedical Sciences;4(2):659-68.
- [41] Qin M dkk. 1998. The effect of calcium supplement given with mixture of calcium carbonate and calcium citrate on the mandibular alveolar bone of pubertal rats. Journal of Bone and Mineral Metabolism.
- [42] Rattanukul C, Rattanamongkonkul S, 2011. Effect of calcitonin on bone formation and resorption: Mathematical modeling approach. International Journal of Mathematical models and methods
- [43] Ross AC dkk. Review dietary references intakes for calcium and vitamin D. 2011. Washington DC: National Academies Press.
- [44] Ratih PH, Pramestri SL, Herawati D. 2013. Pengaruh penambahan *platelet-rich* plasma pada cangkok tulang terhadap kadar osteocalcin cairan sulkus gingival pada terapi poket infraboni. Jurnal PDGI;62(3):75-82.
- [45] Rittweger, J. Can exercise prevent osteoporosis? J Musculoskeletal Neuronal Interact., Vol. 6, No. 2, June 2006, pp. 162-66
- [46] Sankar T.V dkk, 2013. Chemical composition and nutritional value of Anchovy (*Stolephorus commersonii*) caught from Kerala coast, India. J.Exp.Bio; 3(1):85-9 in applied sciences; 8(5):1363-71.
- [47] Sarvraj KS, Virinder KS, 2011. Role of RANKL-RANK/Osteoprotegerin molecular complex in bone remodeling and its immunopathologic implications. Indian J endocrinol Metab; 15(3):175-81.
- [48] Seeman, E. 2003. The structural and biochemical basis of the gain and loss of bone strength in woman and Men. Endocrinol. Mrtab. Clin. Orth. Am;32:25-38
- [49] Setyorini A, 2009. Pencegahan osteoporosis dengan suplementasi kalsium dan vitamin D pada penggunaan kortikosteroid jangka panjang. Sari Pediatri;11(1):32-8

- [50] Tahir A M, 2009. Peran polimorfisme gen collagen type 1 alpha 1 (COL 1 $\alpha$ 1) terhadap penurunan drastis mineral tulang vertebral lumbal akseptor KB suntik DMPA. Maj obstet Ginekol Indones;33(3):176-84.
- [51] Watted N dkk, 2014. Parathyroid hormone: is it really the cause for increased tooth mobility after orthognathic surgery?.Open Journal of stomatology;4:424-33.
- [52] Wilkins CH.2007. Osteoporosis screening and risk management. Clin Interv Aging. 2007 Sep; 2(3): 389–394
- [53] Xiong J, Charles A, 2013. Osteocyte RANKL:New Insights into the contro of bone remodeling. J Bone Miner Res;27(3):499-505.

Ika Astrina "Anchovy Intake To Increase Alveolar Bone Density Of The Mandibles In White Wistar Rats (*Rattus norvegicus*)."*IOSR Journal of Dental and Medical Sciences (IOSR-JDMS)*, vol. 17, no. 3, 2018, pp 28-33.