

A Clinico-laboratory study on Lower Lung field Tuberculosis

Vaddadi Sailendra^{1*}, VVL Srividya¹

^{1*}(Associate Professor, Dept of Chest & TB, GVP IHC & MT, AP, India)

¹(Professor, Dept. of Pathology, GVP IHC & MT, AP, India)

Corresponding Address: VaddadiSailendra

Abstract: An atypical presentation of Pulmonary Tuberculosis is Lower lung field Tuberculosis. This usually causes enormous confusion in the diagnosis, wherein early diagnosis & treatment leads to prevention of complications. A proper understanding of Clinical, Radiological and Bacteriological presentations are vital in the treatment. In this regard, a study was conducted in the teaching Institute, Gayatri Vidya Parishad Medical College, Visakhapatnam, India, in order to study the clinical presentations of Lower lung field Tuberculosis. From June 2016 to May 2017, 42 cases of Lower lung field Tuberculosis, admitted in Medical wards were studied. 26 were females (61.9%), age 21-40 yr, had respiratory symptoms Cough with scanty expectoration 41 (97.6%), mild to moderate fever 30 (71.4%), Anorexia & Loss of weight 20 (47.6%), Pleuritic pain chest 4 (10%), scanty haemoptysis 6 (15%). Unilateral disease was more common with a slight preponderance to Right lung (58%). Main radiological presentations were cavitation (55%) and nodular opacities (84%). Predisposing conditions found were Diabetes 14 (33.3%), HIV 2 (4.7%), end stage Renal disease 16 (38%), and Patients using corticosteroids on a long term 8 (19%), Past history of Tuberculosis 10 (23.8%). Conclusion: Diagnosis of LLFTB requires a high index of suspicion. Diabetes mellitus, HIV, pulmonary malignancy and pregnancy increase the risk of lower lung field tuberculosis. Fiberoptic flexible bronchoscopy helps in diagnosis in sputum negative cases. Clinical presentation is similar to that of classical upper lung field tuberculosis and short course chemotherapy is equally effective as in classical upper zonal disease.

Keywords: Lower lung field tuberculosis, Pulmonary tuberculosis, Pulmonary malignancy, Diabetes, HIV, Fiberoptic flexible Bronchoscopy

Date of Submission: 15-03-2018

Date of acceptance: 03-04-2018

I. Introduction

India is the country with the highest burden of TB. According to the WHO statistics for India in 2016, an estimated incidence of an agonizing figure of 2.79 million was revealed⁽¹⁾ Since Laennec's era, lower lung field TB was considered a rarity. In fact, Laennec himself opined that TB hardly ever developed in middle or lower lobes of the lungs⁽²⁾ In 1866, Kidd stated that "apex of lower lobe is very prone to tubercular disease and may be attacked before the apex of the upper lobe"⁽³⁾. Fowler stated that "the upper and posterior part of the lower lobe is a spot only second in point of vulnerability to the apex itself"⁽⁴⁾. Post-primary Tuberculosis, a leading killer disease seen in adults is located predominantly in the upper lobes. Though the disease commonly affects the upper lung fields, lower lung field tuberculosis is also not uncommon. It leads to a great amount of confusion in the diagnosis. It often masquerades as pneumonia, bronchiectasis, or bronchogenic carcinoma thus delaying the correct diagnosis. In the current AIDS/HIV epidemic, there are increased incidences of middle and lower lung field tuberculosis.

DEFINITION: Lower lung field tuberculosis is defined as "Tuberculous disease found below an imaginary line traced across the hila and including the parahilar regions on a standard posterior-anterior chest x-ray without concomitant involvement of upper lobe"⁽⁵⁾. Anatomically, this includes the right middle lobe and lingula, in addition to the lower lobes.

II. Methodology

This study was conducted at the Department of Pulmonary Medicine, Gayatri Vidya Parishad Medical College, Visakhapatnam, India. It is a tertiary care teaching hospital. It was the prospective study conducted during the time span of 12 months from June 2016 to May 2017. Ethical clearance was taken from the ethical committee of the college. All the patients of Lower Lung Field Pulmonary Tuberculosis were included in the study. Consent from the patients was taken before inclusion in the study.

History was taken in full detail regarding particulars of the patient and complaints including cough, weight loss, fever, hemoptysis, and anorexia, and history of contact with tuberculosis and history of any other systemic illness, diabetes mellitus, chronic liver diseases, asthma, chronic renal failure, and HIV were noted as

well. Any relevant past history and personal history including dietary habits, smoking, alcohol, and other addictions were also taken. Diagnosis of tuberculosis was made by sputum for AFB examination by Ziehl-Neelsen technique. Those negative for sputum for AFB on two separate occasions were diagnosed as a case of sputum negative pulmonary tuberculosis on the basis of suggestive clinical and radiological findings. In selected patients with high suspicion of Tuberculosis, not improving with antibiotic therapy, Fiber-optic Bronchoscopy was conducted with Bronchial washings, BAL & brushings done. Material sent for microbiological and cytological evaluation. Record of the radiological reading in terms of consolidation, nodular opacity, and cavitation was also noted.

Patients with the following characteristics were excluded from the study:

(1) Patients less than 12 years of age were excluded. (2) Patients with upper lobe tuberculosis along with lower lobe involvement were not considered as the case of lower lobe tuberculosis. (3) Patients with pleural effusion without parenchymal involvement were excluded. Diagnosis of diabetes was made according to WHO guidelines, that is, fasting plasma glucose ≥ 7.0 mmol/L (126 mg/dL) or 2 h plasma glucose ≥ 11.1 mmol/L (200 mg/dL). Strict control of sugar level was made during the treatment period. Patients were tested for HIV1 and HIV2 according to NACO guidelines [4]. Prolonged steroid intake was defined as steroid intake for more than three months.

All patients were treated with Directly Observed Treatment Short (DOTS) course for tuberculosis, according to Revised National Tuberculosis Control Program (RNTCP) for India⁽⁵⁾.

III. Results

42 consecutive cases of lower lung tuberculosis were included for the study randomly of which 26 were females (61.9%), 16 were males (38.1%).

Various risk factors noted in the study were Diabetes seen in 14 (33.3%) of patients, Predisposing conditions *viz.*, Diabetes 14 (33.3%), HIV 2 (4.7%), end stage Renal disease 16 (38%), and Patients using corticosteroids on a long term 4 (9.5%), Past history of Tuberculosis 10 (23.8%).

7 (17.5%) were alcoholics, 4 (10%) had previous history of pulmonary tuberculosis and 2 (5%) were HIV positive cases (Fig. 1). Four patients in LLFTB group were on more than 10 mg/day of steroid intake.

26 females (61.9%), 16 males (38.1%). age 21-40 yrs, 41 patients (97.6%) had respiratory symptoms in the form of cough and scanty expectoration, 30 (71.4%) had mild to moderate grade fever, 20 (47.6%) had significant weight loss, 4 (10%) had pleuritic pain, 6 (15%) had scanty hemoptysis (Fig. 2).

Sputum smears were positive for AFB in 26 (61.9%) cases. In 6 (14.3%) cases, BAL was positive for AFB. CT findings were suggestive of TB in 7 (16.6%) patients and 3 (7.1%) were sputum negative who presented with unresolving pneumonia which improved on treatment.

Response to treatment was good in all cases & no deaths are recorded.

IV. Discussion

Most of the previous studies done on Lower lung field Tuberculosis showed a female pre-ponderance. In 1886, Kidd first reported the case of Lower lung field tuberculosis^(6,7,8,9). All studies, including our study, except a few, showed female predominance^[7,8,9]. The probable explanation being that female's have costal type of respiration resulting in poor ventilation and hence higher chances of tuberculosis^(10,11). In present study, majority of the patients 16 (64%) were in the age group of 16-40 years⁽¹²⁾. This was also documented in other studies^(13,14,15). There is a higher incidence in females than in males (1.58:1) similar to the study conducted by Vidyasagar et al.^[16]. Most of the patients in this study, presented with the predominant symptom of cough (97.6%) followed by fever, hemoptysis, weight loss and chest pain. This finding is in conformity with other Indian and abroad studies^[17,18,19]. Weight loss was prominent in HIV patients. Sputum smears were positive for AFB in 26 (61.9%) cases. Flexible Fiberoptic Bronchoscopy showed a higher recovery of acid-fast bacilli, by revealing them in 12 (28.57%) sputum negative cases. Microscopic examinations of bronchoscopic specimens were found positive for acid fast bacilli in 42% to 65%. Bronchial washes increased the diagnostic yield as seen in the study of Wongthim^[20]

All the specimens which are sent for cytological evaluation are negative for malignancy.

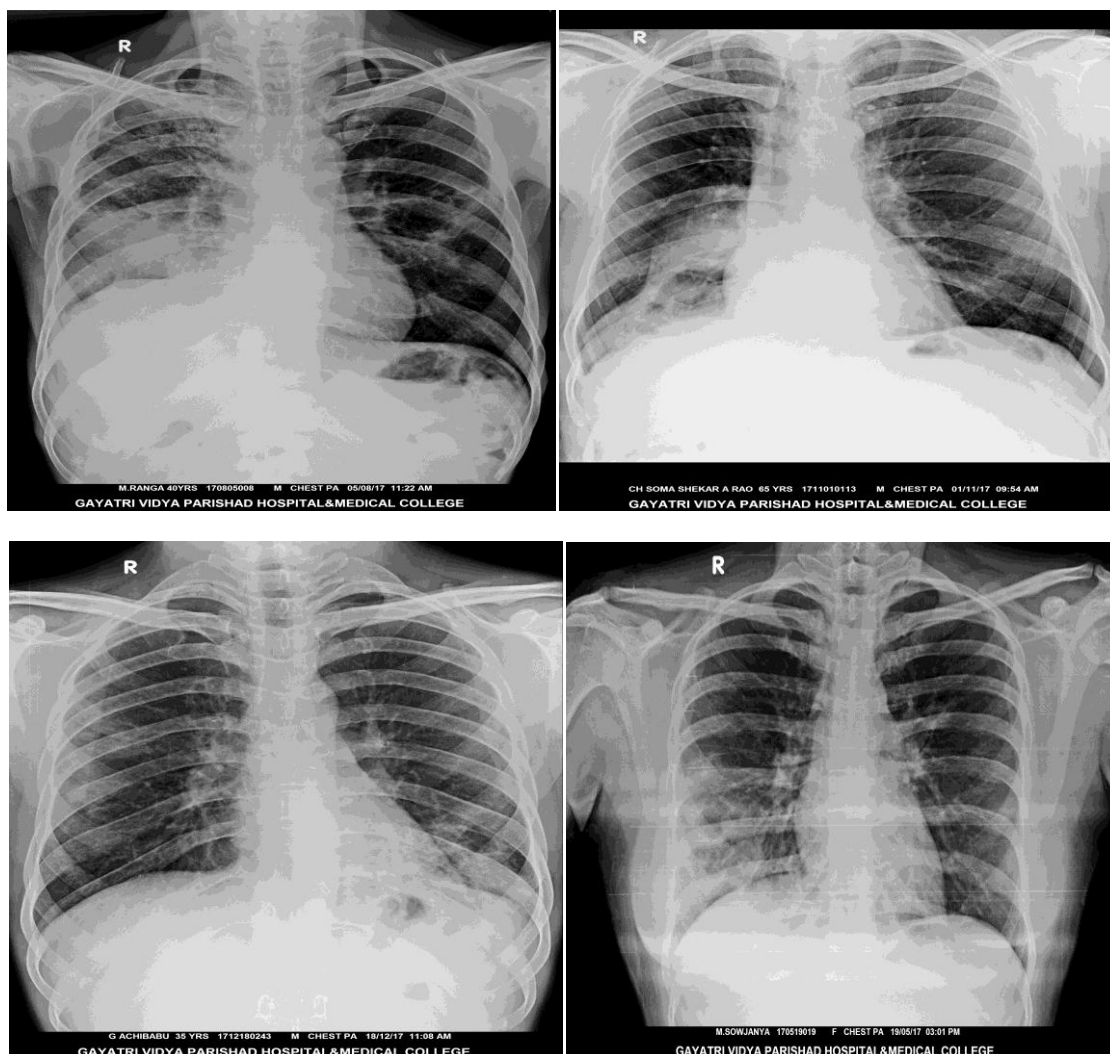
V. Conclusion

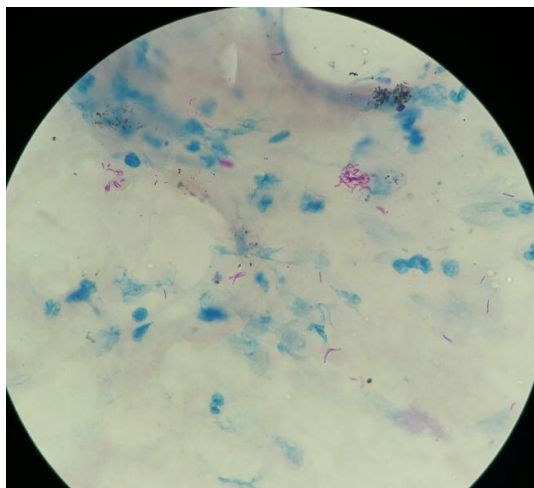
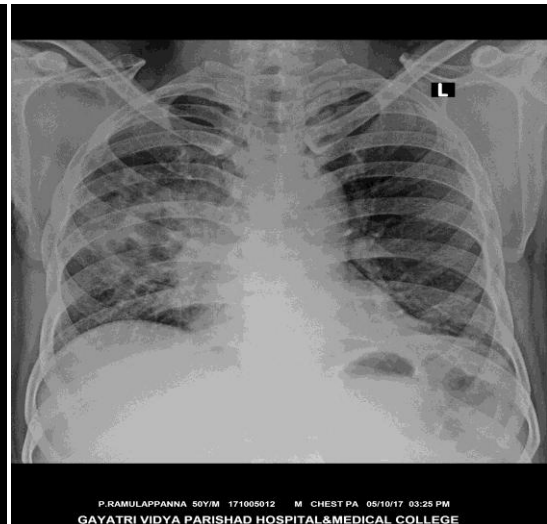
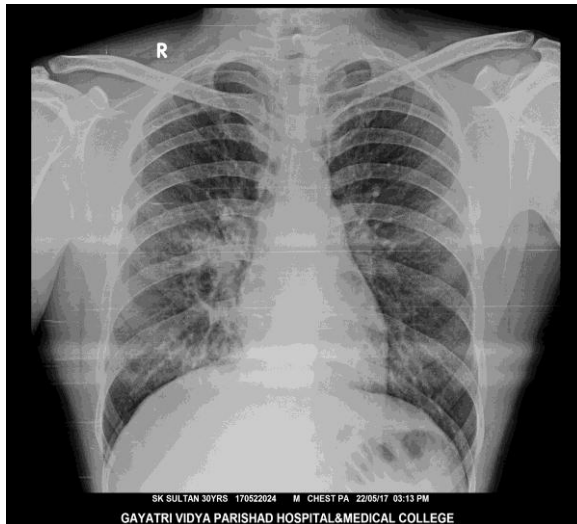
Lower lung field tuberculosis is not a rare or uncommon etiology in clinical practice. This particular entity is frequently seen in an HIV infected persons, diabetics, pregnancy, pulmonary malignancy and in young women having lower lung field lesions. Absence of upper-lobe involvement cannot rule out tuberculosis, and Lower-lung field Tuberculosis has to be evaluated to identify the etiology of pulmonary infiltration. Likewise, lack of symptoms, initial negative sputum smears and culture for acid-fast bacilli and/or a negative initial tuberculin skin test do not entirely rule out the possibility of tuberculosis. The flexible fiberoptic bronchoscope

has been a useful instrument not only in obtaining secretions and tissue specimens for definite diagnosis, but also in assessing the severity of the endobronchial lesions and a guide for early surgical intervention. Prognosis in lower lobe tuberculosis is similar to those cases of upper lobe involvement.

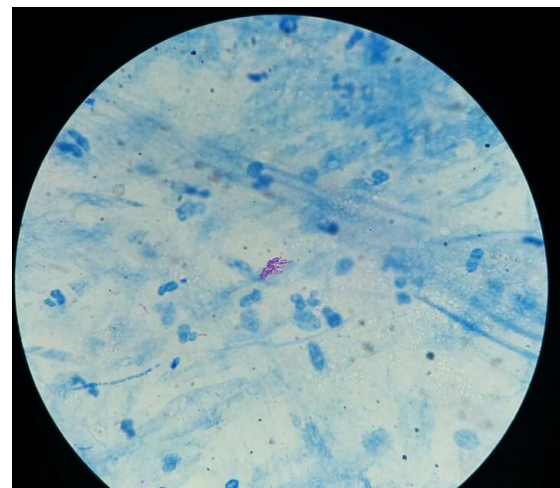
References

- [1]. TB India 2017. Revised National TB Control Programme Annual Status Report, New Delhi.
- [2]. Laennec RH. Treatise on the diagnosis and treatment of the diseases of the chest. New York. Hafner Publishing; 1962.
- [3]. Kidd P. Basic tuberculosis phthisis. Lancet 1886;2:616.
- [4]. Fowler JK. The localization of lesions of phthisis. London: J and A Churchill; 1888.
- [5]. Herbert W. Berger, Margarito G. Gramdo. Lower lung field tuberculosis. Chest 1974;65:522-6.
- [6]. Kidd P; Basic tuberculous phthisis. Lancet 1886;
- [7]. Mathur KC, Tanwar KL, Razdan JN; Lower lung fieldtuberculosis. Ind J Chest Dis 1974; 16:31-41.
- [8]. Parmar MS. Lower lung field tuberculosis. Am Rev Respir Dis 1967; 95: 310-2.
- [9]. Ramachandra, Jithendranath, Agarwal GN, Srivastava VK, Mukerji PK; Lower lung field tuberculosis. Ind J Tub 1982;29:158-72.
- [10]. Vishwanathan R; Tuberculosis of the lower lobe. Brit Med J1936;2:1300.
- [11]. (11)Pandya L, Al-Sharif N, Maracey MA. Lower lung fieldtuberculosis in Saudi Arabia. An Saud Med 1990;4:374-7.
- [12]. (12)Segarra F, Sherman DS, Rodriguez-Aguero J; lower lung fieldtuberculosis. Am Rev Respir Dis 1963; 87: 37-40.
- [13]. (13) Segarra F, Sherman DS, Rodriguez-Aguero J; lower lung fieldtuberculosis. Am Rev Respir Dis 1963; 87: 37-40.
- [14]. (14) Chang SC, Pui-Yuen L, Perng RP; Lower lung fieldtuberculosis. Chest 1987;91:230-2.
- [15]. (15) Ramachandra, Jithendranath, Agarwal GN, Srivastava VK, Mukerji PK; Lower lung field tuberculosis. Ind J Tub 1982;29:158-72.
- [16]. (16) Vidyasagar B, Venkatesh V, Ajith Kumar; A clinical study oflower lung field tuberculosis. Lung India 1996;3:125-7
- [17]. (17)Hamilton CE, Fredd H; Lower lobe tuberculosis: A review. JAMA 1935;
- [18]. (18)Tripathy S, Nanda CN; Lower lung field tuberculosis in adults.JAPI 1970;18:999-1001.
- [19]. (19)Parmar MS. Lower lung field tuberculosis. Am Rev Respir Dis 1967; 95: 310-2.
- [20]. (20) Wongthim S, Limthongkul S, Udompanich J, et al. Fiberoptic bronchoscopy in diagnosis of patients with suspected activepulmonary tuberculosis. J Med Assoc Thai 1989;72:154- 59.





MICROPHOTOGRAPH-1
AFB 3+ POSITIVE IN BAL FLUID



MICROPHOTOGRAPH -2
AFB 2+ POSITIVE IN SPUTUM

VaddadiSailendra. "A Clinico- laboratory Study on Lower Lung Field Tuberculosis." IOSR Journal of Dental and Medical Sciences (IOSR-JDMS) 17.3 (2018): 46-50.