

Cone Beam Computed Tomography (CBCT) As A Diagnostic Aid In A Case Of Unicystic Ameloblastoma: A Case Report

Dr. Rucha Supare¹, Dr. R. Krishna Kumar², Dr. Rashmi Sapkal³, Dr. Husna Patel⁴

¹(Post graduate student, Department of Oral Medicine and Radiology, M A Rangoonwala Dental college, Pune)

²(Head of the Department, Department of Oral Medicine and Radiology, M A Rangoonwala Dental college, Pune)

³(Reader, Department of Oral Medicine and Radiology, M A Rangoonwala Dental college, Pune)

⁴(Post graduate student, Department of Oral Medicine and Radiology, M A Rangoonwala Dental college, Pune)

Corresponding Author: Rucha Supare

Abstract: Ameloblastoma is a rare, benign epithelial odontogenic tumor. This odontogenic neoplasm was first detailed and described by Falkson in 1879. Most common site of origin is posterior mandibular body ramus region. It resembles the cells of the enamel-forming organ. We present a case which demonstrates use of cone beam computed tomography in the diagnosis of large unicystic ameloblastoma in a 35 year-old female patient.

Key Words: Unicystic ameloblastoma, Odontogenic tumors, Mandible.

Date of Submission: 12-03-2018

Date of acceptance: 28-03-2018

I. Introduction

Ameloblastoma (from the English word amel, meaning enamel, and the Greek word blastos, meaning germ), represents 1% of all oral ectodermal tumors and 9% of odontogenic tumors. [1] Swellings arising from mandible can be of odontogenic and non odontogenic in origin. Ameloblastoma forms the commonest variety of odontogenic neoplasm. Ameloblastoma arises from dental tissues under development or epithelium. Solid or multicystic types form the common variants, ranging up to more than 80 percent of the cases. Whereas unicystic type is a less common but important variant, clinicopathologically. Unicystic ameloblastoma, along with peripheral ameloblastoma form 20 percent of cases. [2] Unicystic ameloblastoma exhibits a characteristic difference in clinicoradiological and histopathological findings. Clinical as well as radiological findings are suggestive of odontogenic cyst but tissue diagnosis reveals a peculiar ameloblastous lining of cyst cavity. [3] Anterior, posterior, lateral, panoramic views of radiography cannot give a clear understanding of actual 3 dimensional extent of the lesion. In this regard, cone beam computed tomography (CBCT) enables the clinician to get exact nature and extent of cyst tissue. Extra osseous spread of the cyst can be detected by (Contrast Enhanced Computed Tomography) CECT scan and contrast (Magnetic Resonance Imaging) MRI [4]

II. Case Report

A 35 year old housewife visited as an outpatient to Department of Oral Medicine and Radiology with the chief complaint of swelling in the right side of face since 3 years. Swelling was initially accompanied with pain and small in size but later it increased to present size without any pain. Patient visited a dentist for the same complaint 2 years back where the dentist performed extraction of impacted 18 and suggested to have antibiotic regime. He further advised extraction of 48 after few weeks without doing any radiographic investigations. After the extraction and medicines the swelling still persisted. Patient experienced numbness of the same side since 6 months. Later patient did not pay attention to the swelling. She continued with some home remedies for the same such as hot fermentation.

Patient sought homeopathic treatment and claims to have been symptom free until 6 months ago when she started developing mild pain in the region of the swelling. Pain was intermittent, aggravating on chewing, relieving by itself and is non radiating type. From past 3-4 months she started experiencing occasional numbness along the right side of the tongue.

There was no discharge of pus or blood from the swelling, no history of trauma to the region of swelling. There was no history of weight loss, or similar swellings anywhere in the body. Past medical history, family history was not significant. General was essentially normal.

On extra oral examination a diffuse swelling was seen involving the middle and lower third of the face on the right side extending superiorly about 1cm below the zygomatic arch, inferiorly till the lower border of the mandible and anteriorly from 1cm posterior to the angle of the mouth to posteriorly till about 4cms anterior to

the tragus (Fig 1). Overlying skin and surrounding area was normal. There were no sinus tract /ulceration noted. On palpation, all findings of inspection were confirmed. Consistency of the swelling was stony hard.

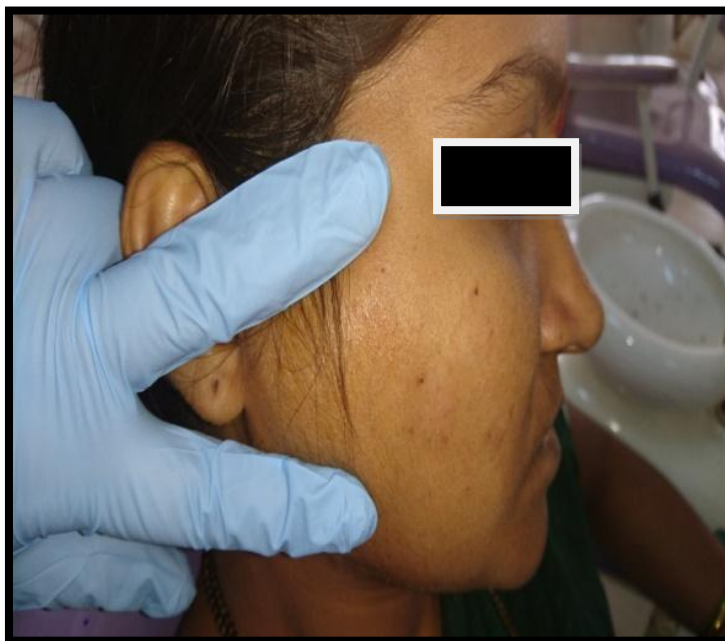

Fig 1: Extra oral view of extent of swelling

On intraoral examination, a diffuse swelling was seen on right side of the mandible extending in the buccal mucosa from the retromolar area and alveolar ridge 46, 47,48 (Fig 2). Surface of the swelling appeared smooth. Surrounding area was normal. No discharge or ulcerations were noted. On palpation, inspeactory findings were confirmed. Local temperature was not raised. Crackling or crepitations were elicited on palpation. Mild tenderness was present. Swelling was soft to firm in consistency all over except along the inferior aspect where it was stony hard. Expansion of buccal and lingual cortical plates was present.

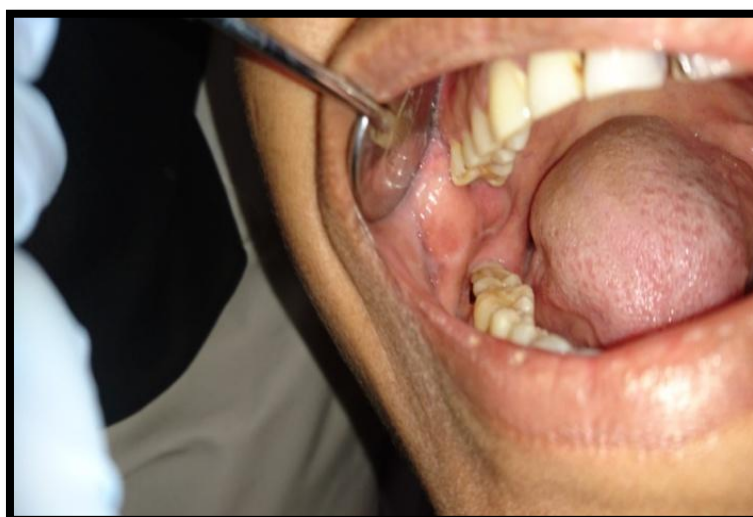

Fig 2: Intraoral View of the swelling

Based on the presentation and clinical examination, a provisional diagnosis of Dentigerous cyst was given.

DIFFERENTIAL DIAGNOSIS: Ameloblastoma, Calcifying epithelial odontogenic tumor (CEOT), Keratocystic odontogenic tumor (KCOT), Central giant cell granuloma (CGCG), Odontogenic myxoma were considered in the differential diagnosis for our case but features like old age, multilocularity of ameloblastoma were less favourable in this case. In CEOT focal areas of calcifications are seen, but in our case we see

unilocular radiolucency without any radio opaque flecks. Linear expansion of KCOT through medullary spaces without any buccolingual expansion ruled out its diagnosis. Lesions like CGCG and odontogenic myxoma were also ruled out based on their clinical and radiological features.

INVESTIGATIONS: Baseline hemogram was normal. Patient was advised lateral oblique view radiograph of body ramus and OPG. Radiograph lateral oblique of body-ramus revealed presence of areas with multiple locules with a well defined sclerotic border. Cropped view of OPG revealed a well defined multilocular (soap bubble) radiolucency seen at the periapical area extending from distal aspect of 45 involving 46,47 ,48 to superior border (sigmoid notch).

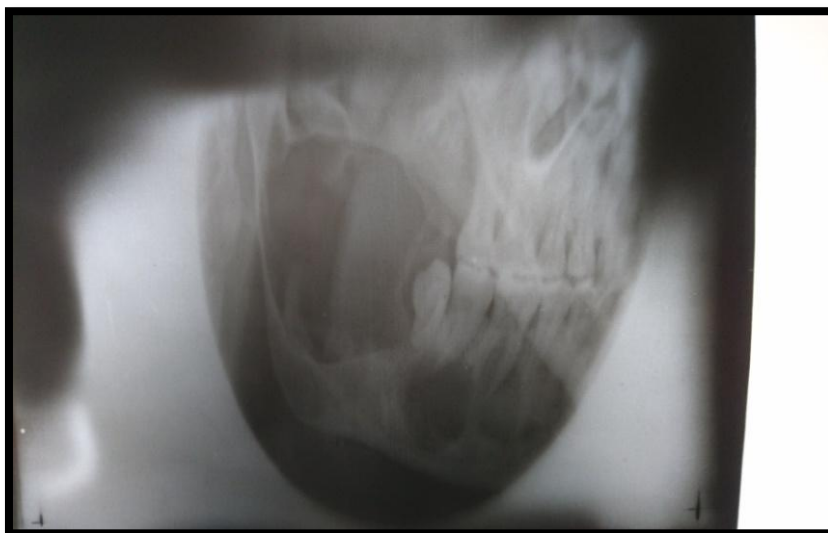

Fig 3: Radiograph lateral oblique of body-ramus demonstrating presence of areas with multiple locules with a well defined sclerotic border

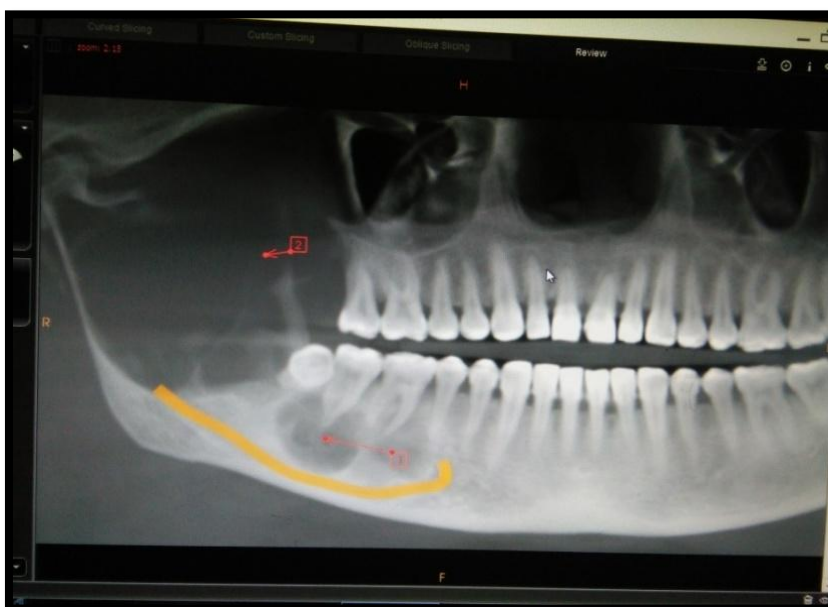


Fig 4: Cropped view of OPG showing well defined multilocular (soap bubble) radiolucency seen at the periapical area extending from distal aspect of 45 involving 46,47 ,48 to superior border (sigmoid notch)

For further details and information of the pathology, patient was advised CBCT imaging with right side of jaw. A 3 D reconstruction views obtained (Fig 5). CBCT imaging revealed well-defined multilocular radiolucency with septae and Buccolingual expansion with perforation of buccal plate, on axial section cropped view (Fig 6) . Sagittal section revealed the extent of radioluscent lesion (Fig 7) and coronal view revealed mesioangular impaction with 48 and radiolucency displacing the inferior alveolar nerve canal (Fig 8).

Radiological differential diagnoses of Ameloblastoma, Odontogenic keratocyst and Central giant cell granuloma; were made.

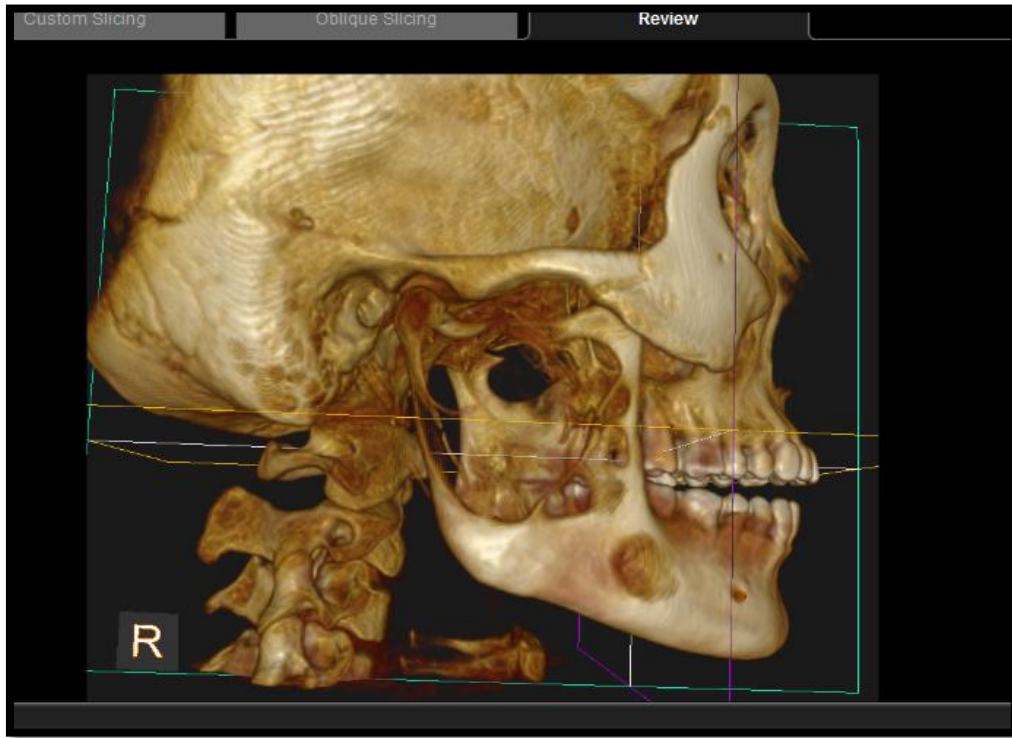


Fig5: 3-D Reconstruction view

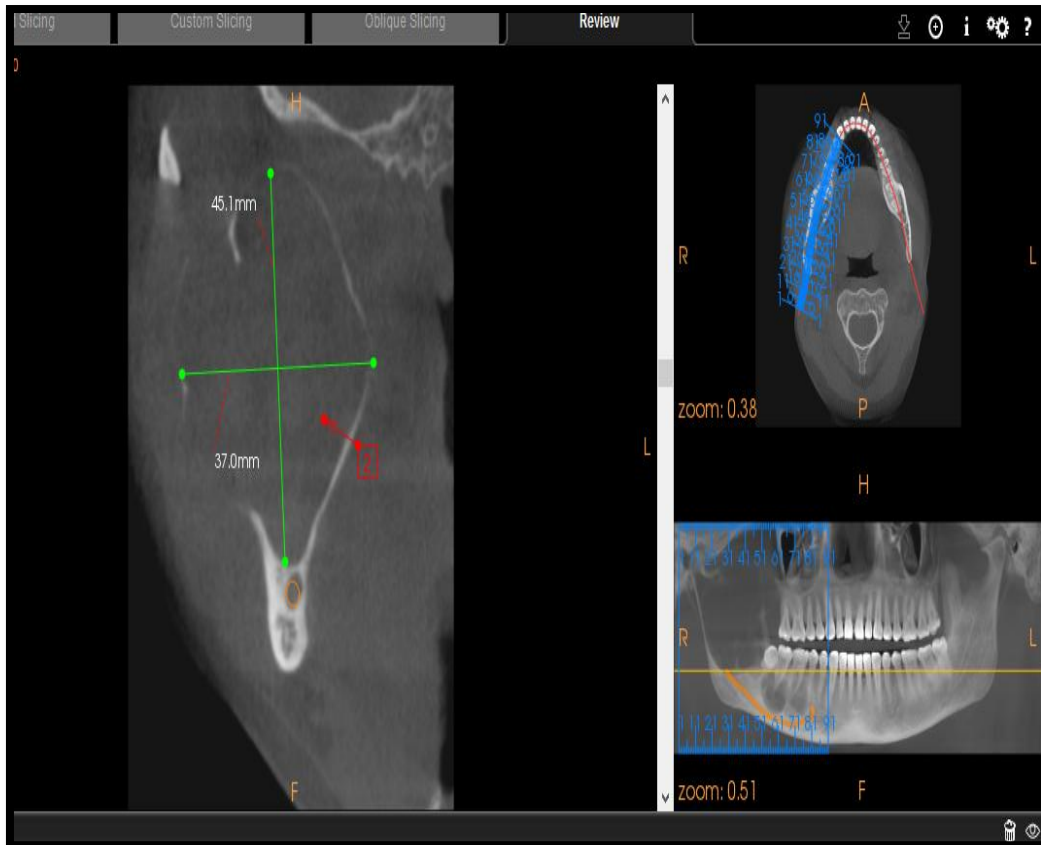


Fig 6: Axial section cropped view CBCT image

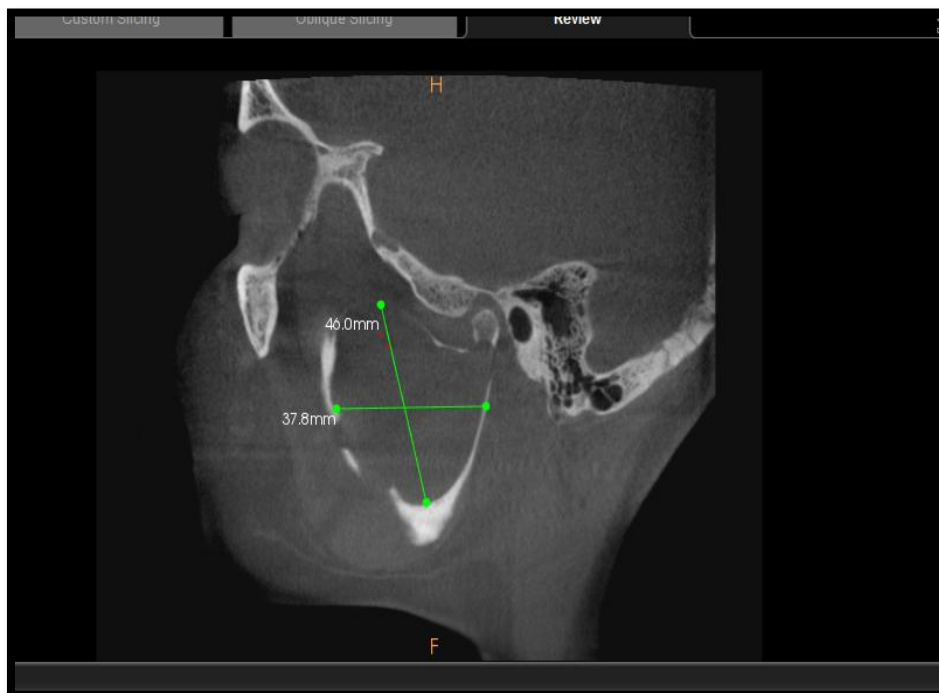


Fig 7: Sagittal view CBCT image

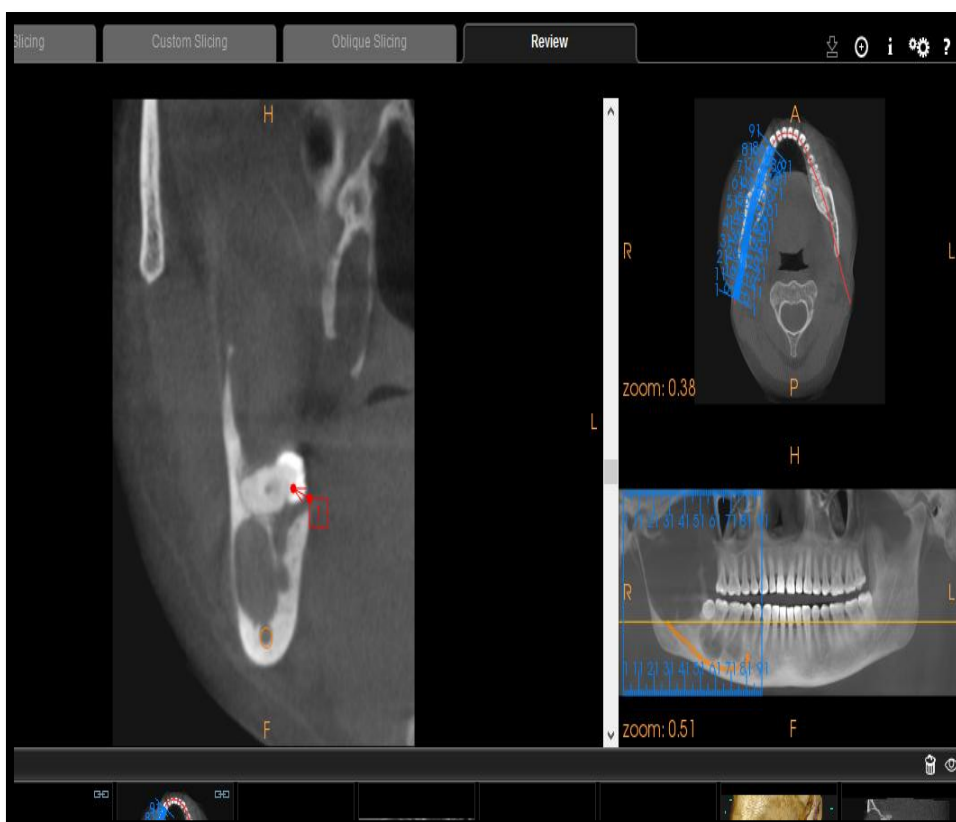
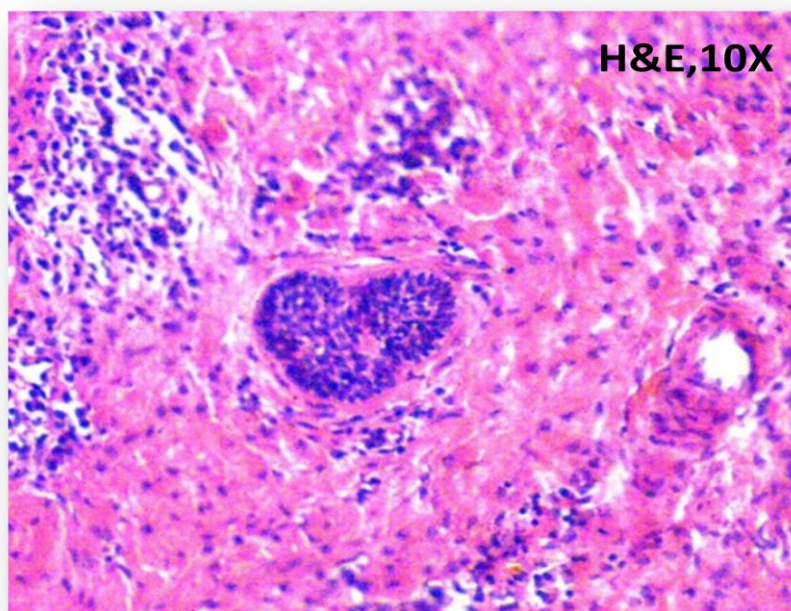


Fig 8: Coronal view CBCT image

HISTOPATHOLOGY: H & E stained section revealed cystic lumen lined by tall columnar cells showing reverse of polarity of nucleus with areas of stellate reticulum projections in to the lumen and also into the connective tissue. The CT capsule was composed of dense bundles of collagen fibers with areas of odontogenic islands and also odontogenic follicles showing squamous metaplasia and cystic degeneration (Fig 8).



A treatment plan of Segmental resection of the mandible and extraction of 46,47 and 48. Oral prophylaxis and Prosthetic rehabilitation comprised of essential part post surgical treatment Periodic follow up are necessary as the lesion has a high rate of recurrence.

III. Discussion

Ameloblastoma was first recognized in 1827, by Cusack. This type of odontogenic neoplasm was designated as 'Adamantinoma' in 1885 by the French physician Louis-Charles Malassez [5]. The term ameloblastoma was coined by Ivey and Churchill in 1930. It is considered as a true neoplasm and, as the name implies, it resembles the cells of the enamel-forming organ. All unicystic ameloblastomas in the series reported earlier, by Robinson and Martinez [6] showed an increased predilection for occurrence in the mandible. HM Worth described four radiological types of Ameloblstoma.

- Unicystic type: This type appears as a unilocular radiolucency resembling a cyst. However, unlike cyst, it causes a break or discontinuity in the peripheral cortex and may even show trabeculae within the lumen.
- Spider-web pattern: This is the most common appearance, where the lesion is seen as a large radiolucent area with scalloped borders. From the center of the lumen coarse strands of trabeculae radiate peripherally, giving rise to a gross caricature of a spider.
- Soap-bubble pattern: This lesion is seen as a multilocular radiolucency with large compartments of varying sizes, giving rise to the soap-bubble appearance, or a multi-chambered or multi-cystic 'bunch of grapes' appearance.
- Honeycomb or solid pattern: This is also called a beehive pattern. These are tumors that have not undergone cystic degeneration. Hence, multiple small radiolucencies are seen surrounded by hexagonal or polygonal thick-walled bony cortices, giving rise to a honeycomb appearance [7].

Radiographically, unicystic ameloblastomas have been divided into 2 main patterns: Unilocular and Multilocular. Unicystic variety has clear preponderance for the unilocular pattern which shows similar features as seen in our case [8]. Three dimensional image capture and analysis was introduced in dentistry in 1998 by Mozzo et al. None of other imaging modalities made as great an impact on dental procedures as cone beam computed tomography. [9]. Jingjing Luo et al reviewed 7 cases of ameloblastoma radiologically on CBCT. They concluded that typical intralesional structure with honeycomb appearance and the dominant buccal/labial cortical expansion with perforation could be proposed as the characteristic features of ameloblastoma on CBCT images. CBCT can provide more information for preoperative radiologic assessment of Ameloblastoma compared with panoramic radiography [10]. After the course of diagnosis and prior to planning the treatment of such lesions, accurate tissue diagnosis should be obtained by histopathological examination [11].

IV. Conclusion

CBCT is advantageous in perceiving the borders, internal structure, cortical expansion, and relationship with surrounding structures of Ameloblastoma. A typical intralesional structure of honeycomb/ soap bubble appearance and the dominant labial/buccal expansion with cortical erosion on CBCT images, as well as the common finding of nerve displacement due to radiolucency, may be considered as a trend of features most likely diagnostic of Ameloblastoma along with the clinical history given by the patient.

References

- [1] Shafer's Oral Pathology
- [2] H. P. Philipsen and P. A. Reichart, —Unicystic ameloblastoma. A review of 193 cases from the literature, *Oral Oncology* 1998 ; 34 (5) : 317–325
- [3] T. J. Li, Y. T. Wu, S. F. Yu, and G. Y. Yu, —Unicystic ameloblastoma: a clinicopathologic study of 33 Chinese patients, *American Journal of Surgical Pathology*, 2000 ; 24 (10) :1385–1392
- [4] Dunfee BL, Sakai O, Pistey R, Gohel A, Radiologic and pathologic characteristics of benign and malignant lesions of the mandible. *Radiographics* 2006 ; 26: 1751-1768.
- [5] Textbook of Oral and Maxillofacial Surgery By Nilima Mallik
- [6] Robinson L, Martinez MG. Unicystic ameloblastoma: A prognostically distinct entity. *Cancer* 1977;40:2278.
- [7] Worth H. Principles and practice of Oral Radiographic Interpretation. Year Book Medical Publishers Copyright; 1963. p. 476-88
- [8] Cone Beam Computed Tomographic (CBCT) Features in a Case of Unicystic Ameloblastoma- A case report; Archana M, Shraddha Bahirwani, Jigna V Raja, Anupama; *International journal of health sciences and research*; Vol.4; Issue: 4; April 2014
- [9] Mozzo P, Procacci C, Tacconi A, et al., —A new volumetric CT machine for dental imaging based on the cone-beam technique: preliminary results, *Eur Radiol* (1998);8: 1,558–1,564.
- [10] Jingjing Luo et al; Cone beam computed tomography signs of desmoplastic ameloblastoma: review of 7 cases; *Oral Surgery Oral Medicine Oral Pathology Oral Radiology*; Issue Oct 2014, Volume 118, Issue 4, Pages e126–e133
- [11] Chandramani More et al ; Radiographic analysis of ameloblastoma: A retrospective study; *Indian Journal of Dental Research*; Year : 2012, Volume : 23, Issue : 5, Page : 698
- [12] S. C. White and M. J. Pharoah, *Oral Radiology: Principles and Interpretation*, Mosby, St. Louis, Mo, USA, 5th edition, 2004

Rucha Supare "Cone Beam Computed Tomography (Cacti) As A Diagnostic Aid In A Case Of Unicystic Ameloblastoma: A Case Report." *IOSR Journal of Dental and Medical Sciences (IOSR-JDMS)*, vol. 17, no. 3, 2018, pp 29-35.