

## Erythroplasia of Queyrat With Zoon's Balanitis: A Diagnostic Dilemma

Ravinder Kumar<sup>1</sup>, Sanjeev Parshad<sup>2</sup>, R. K. Karwasra<sup>3</sup>, Bhavinder Arora<sup>2</sup>

Junior Resident<sup>1</sup>Department of General Surgery Pt. B.D. Sharma P.G.I.M.S. Rohtak-124001

Professor<sup>2</sup>Department of General Surgery Pt. B.D. Sharma P.G.I.M.S. Rohtak-124001

Sr Professor<sup>3</sup>Department of General Surgery Pt. B.D. Sharma P.G.I.M.S. Rohtak-124001

Corresponding Author: Ravinder Kumar

---

**Abstract:** Chronic erythematous lesions of the penis may result from a variety of underlying causes that form a part of differential diagnosis. They are difficult to diagnose only upon clinical examination and may necessitate performing a biopsy to confirm the diagnosis and also identify the coexisting disease. We report a case of erythroplasia of Queyrat (EQ) with Zoon's balanitis and discuss the classification of the lesion through the analysis of overlapping histological features. A middle-aged uncircumcised man presented with two long-standing erythematous prepucial penile lesions unresponsive to antibiotics. Biopsy performed to establish the diagnosis revealed non-invasive severe dysplastic changes in the epithelium that is typical of EQ.

---

Date of Submission: 03-03-2018

Date of acceptance: 23-03-2018

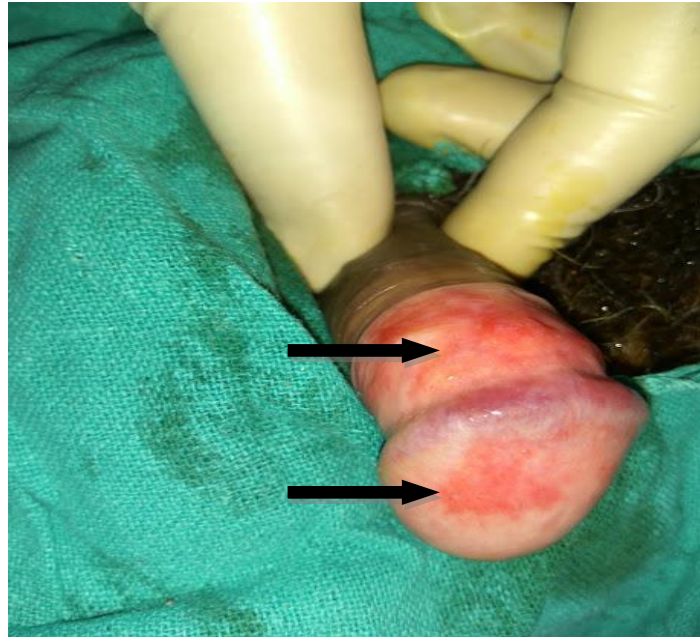
---

### I. Introduction

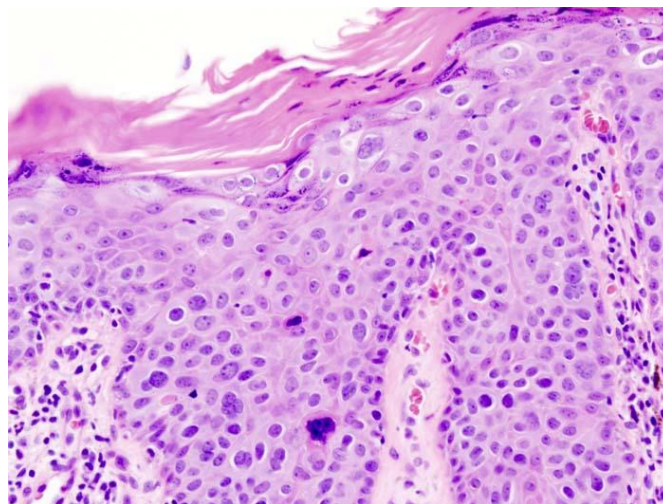
Erythroplasia of Queyrat (EQ) originally described by Tarnovsky in 1891 represents one of the precancerous conditions accepted as a distinct entity.<sup>1</sup> This condition is uncommon in our population. Identification of this condition is important owing to the risk of invasive cancer and to institute timely appropriate treatment.<sup>1,2</sup> The presentation of EQ may mimic other dermatological conditions that affect the penis. One such condition that closely resembles the presentation of EQ is Zoon's balanitis circumscriptaplasmacellularis (BCP), which is an idiopathic benign dermatosis. Both the conditions are seen in middle age and elderly uncircumcised men.<sup>3,4</sup> They appear as solitary or multiple erythematous plaques involving the glans penis and prepuce. Histopathology of the lesion is essential in making a diagnosis. However, the pathological findings although distinct for EQ, may vary in Zoon's BCP.<sup>5</sup> The occurrence of EQ with coexistent Zoon's BCP is rare and there are very few cases reported in the literature.<sup>6</sup>

### II. Case Report

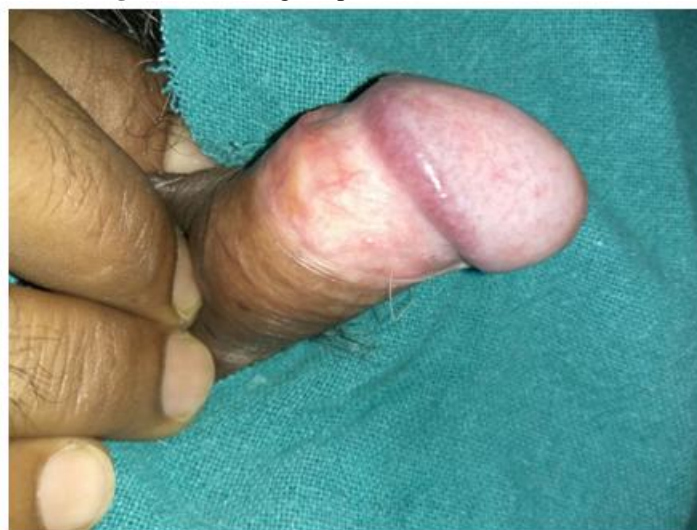A 50year old uncircumcised man presented with a 1 year history of an asymptomatic enlarging red area on the glans penis. A well demarcated moist erythematous plaque was present on the glans and shaft of penis on examination(Fig. 1).Patient had already taken oral and topical antibiotics from many practitioners but the lesion was not tending to decrease rather slowly increasing in size.Biopsy was taken from the glans and histopathological report showed non-specific inflammatory infiltrates comprising of lymphocytes, neutrophils, eosinophils, mast cells with plasma cells which was similar to Zoon's balanitis. There was reactive atypia but no evidence of malignancy (Fig. 2). He was also treated by dermatologist with fluticasone (topical cream 0.05% w/w) and tacrolimus ( 0.03% gel) for two months but there was no major change in lesion except mild decrease in redness of lesion. Patient was referred to surgery department for biopsy. Clinically this was consistent with Zoon's balanitis. Viral markers (HIV, HbsAg, HCV and VDRL) were non-reactive.Repeat biopsy was taken from same lesion which shows features suggestive of squamous cell carcinoma. The patient was treated with topical 5-fluorouracil 5% applied to the glans twice daily for 2 weeks. Clinically the erythematouslesion starts regressing with clear margins. Patient took treatment for five months and lesion was completely cleared. Patient was followed for next six months but there was no recurrence of erythroplasia of Queyrat and circumcision of patient was done on follow up (Fig. 3).



**Figure 1.** A well demarcated moist erythematous plaque was present on the glans and shaft of penis (black arrows)



**Figure 2.** Histological picture of Zoon's balanitis



**Figure 3.** Five months after application of 5-fluorouracil ointment

### III. Discussion

Zoon's balanitis is generally regarded as a benign condition. Association between it and pre-malignant lesion is rarely reported. There are two other case reports: one of erythroplasia of Queyrat<sup>2</sup> and the other of carcinoma of the penis<sup>3</sup> arising in patients with Zoon's balanitis. Our patient developed erythroplasia of Queyrat on a background of biopsy proven Zoon's balanitis, which was probably present for a number of months. The aetiology of Zoon's balanitis remains unclear; however, it is primarily a disease of older uncircumcised men<sup>4</sup> and thought to be a chronic reactive mucositis secondary to the retention of irritants by a dysfunctional foreskin.<sup>5</sup> Pre-existing inflammatory or neoplastic penile conditions may contribute to foreskin dysfunction, and Zoon's balanitis may therefore occur as a reaction to these skin diseases upon which it is superimposed, and may even mask the underlying original pathology. Erythroplasia of Queyrat was not evident in the initial histology from our patient; however, when this later did become evident and was treated with topical 5-fluorouracil the Zoon's balanitis almost cleared completely. To this end one could speculate that the Zoon's balanitis improved as the erythroplasia of Queyrat responded to 5-fluorouracil because this was the pre-existing underlying process to which the Zoon's balanitis was reacting. Pre-existing erythroplasia of Queyrat may have been masked and/or not sampled initially. Atypia, seen on initial histology, is not a usual feature of Zoon's balanitis, and was perhaps a clue to the underlying process. Our patient was treated with topical pimecrolimus for two months, just prior to the development of clinically evident erythroplasia of Queyrat. There has been some concern in the literature regarding a relationship between topical calcineurin inhibitors and carcinogenesis.<sup>7,8</sup> There are case reports of squamous cell carcinoma arising after the short term (weeks) use of topical tacrolimus for balanoposthitis,<sup>9</sup> oral lichen planus,<sup>10</sup> and the use of pimecrolimus for vulval lichen sclerosus.<sup>11</sup> Whether pimecrolimus contributed to the development of erythroplasia of Queyrat in our patient by accelerating an existing process, by stimulating its de novo development, or was purely coincidental is unknown.

### IV. Conclusion

This case highlights the importance of close follow up for persistent penile lesions. It is possible Zoon's balanitis may be a reaction to an underlying process such as neoplasia, and patients should be carefully evaluated for second pathology. The role, if any, of the topical calcineurin inhibitor in the development of erythroplasia of Queyrat in our patient is unknown; however, we would advise caution with its use in Zoon's balanitis as the complete diagnosis may not be evident.

### References

- [1] Mikhail GR. Cancers, precancers, and pseudocancers on the male genitalia. *J. Dermatol. Surg. Oncol.* 1980; 6: 1027–35.
- [2] Davis-Daneshfar A, Trüeb RM. Bowen's disease of the glans penis (Erythroplasia of Queyrat) in plasma cell balanitis. *Cutis* 2000; 65: 395–8.
- [3] Joshi UY. Carcinoma of the penis preceded by Zoon's balanitis. *Int. J. STD AIDS* 1999; 10: 823–5.
- [4] Mallon E, Hawkins D, Dineen M, Francis N, Fearfield L, Newson R, Bunker C. Circumcision and genital dermatoses. *Arch. Dermatol.* 2000; 136: 350–4.
- [5] Bunker CB. Topics in penile dermatology. *Clin. Exp. Dermatol.* 2001; 26: 469–79.
- [6] Weyers W, Ende Y, Schalla W, Diaz-Cascajo C. Balanitis of Zoon. A clinicopathological study of 45 cases. *Am. J. Dermatopathol.* 2002; 24: 459–67.
- [7] Niwa Y, Terashima T, Sumi H. Topical application of the immunosuppressant tacrolimus accelerates carcinogenesis in mouse skin. *Br. J. Dermatol.* 2003; 149: 960–7.
- [8] Bunker CB, Neill S, Staughton RCD. Topical tacrolimus, genital lichen sclerosus, and risk of squamous cell carcinoma. *Arch. Dermatol.* 2004; 140: 1169.
- [9] Langelane T, Engh V. Topical use of tacrolimus and squamous cell carcinoma on the penis. *Br. J. Dermatol.* 2005; 152: 183–5.
- [10] Becker JC, Houben R, Vetter CS, Brocker EB. The carcinogenic potential of tacrolimus ointment beyond immune suppression: a hypothesis creating case report. *BMC Cancer* 2006; 6: 7.
- [11] Fischer G, Bradford J. Topical immunosuppressants, genital lichen sclerosus and the risk of squamous cell carcinoma: a case report. *J. Reprod. Med.* 2007; 52: 329–31.

Ravinder Kumar "Erythroplasia of Queyrat With Zoon's Balanitis: A Diagnostic Dilemma.  
IOSR Journal of Dental and Medical Sciences (IOSR-JDMS), vol. 17, no. 3, 2018, pp 87-89.