

Study on the Biopsy of Lymph Nodes with Inconclusive/Non-Specific Fancy Results

Dr. Nidhin Mathew¹, Dr. Sunil Kumar Shetty², Dr. Yogesh Kumar³

¹(Junior Resident, Department of General Surgery, Kasturba Medical College Mangalore, Manipal University, India)

²(Associate Professor, Department of General Surgery, Kasturba Medical College Mangalore, Manipal University, India)

³(Professor and Unit Head, Department of General Surgery, Kasturba Medical College Mangalore, Manipal University, India)

Corresponding author: Dr. Nidhin Mathew

Abstract: Introduction : Fine needle aspiration cytology (FNAC) is a safe, quick, minimally invasive, economic and effective diagnostic technique in lymphadenopathy cases. The sensitivity and specificity of FNAC was around more than 95%. Although open biopsy followed by cytological examination still remains the standard practice for diagnosing lymph node neoplasia, yet FNAC does constitute one of the most common diagnostic technique for metastatic lymphadenopathy.

Objectives: The aim of this study is to evaluate the reliability and diagnostic accuracy of fine needle aspiration cytology (FNAC) of enlarged lymph nodes with an emphasis on discordant cases between the cytology and the histopathology and to prove that it is a primary method of diagnosis in case of lymph node disease.

Materials & Methods: Prospective study on 102 patients with lymphadenopathy admitted at Kasturba medical college hospitals Mangalore. Patients were subjected to FNAC and histopathology following adequate clinical examination. We estimated the correlation of histology reports of inconclusive or nonspecific FNAC results.

Results: Out of 102 patients with inconclusive FNAC report 25(24.5%) had a definitive diagnosis after biopsy. Out of total 102 patients 87(85.3%) had benign and 15(14.7%) were suffering from malignant lymphadenopathy. The commonest site of the involved cervical lymphadenopathy was the upper deep cervical lymph nodes constituting 48 cases (47.1%) followed by involvement of the supraclavicular lymph nodes in 7 cases (6.9%). **Conclusion:** FNAC is a rapid, safe, easy and cost effective diagnostic technique which can be used for initial diagnosis of lymphadenopathy. FNAC is a very effective investigation with high accuracy rate to differentiate benign conditions from malignant ones and avoids unwanted operations. But caution is mandatory in cases of inconclusive or negative cytology report. If there is a strong clinical suspicion, negative FNAC report is to be disregarded and excision biopsy should be carried out. Analysis shows that HPE is gold standard for evaluation of lymph node enlargement in metastatic lymphadenopathy and also to confirm secondaries where primary tumor is evident and to assess the response to treatment.

Keywords: Block Dissection, Excision Biopsy, FNAC, Lymph Node, Lymphadenopathy

Date of Submission: 20-02-2018

Date of acceptance: 05-03-2018

I. Introduction

Lymph nodes are one of the most compact and closely arranged aggregates of lymphoid tissues in the human body [1]. Lymphadenopathy is a common feature of various benign and malignant disorder that affect both children and adults. The clinical examination may be inaccurate in differentiating benign from neoplastic enlargement of the lymph node. Although surgical excision of a palpable peripheral lymph node is relatively simple, it does require anaesthesia, strict sterility and theatre time and it leaves behind a scar. The commonest causes for cervical lymphadenopathy are tuberculous lymphadenitis which is a common manifestation of extrapulmonary tuberculosis, secondaries in the cervical lymph nodes, lymphomas and nonspecific lymphadenitis [2]. Fine needle aspiration cytology is simple, safe and inexpensive method for diagnosis of neck swellings [3]. FNAC can differentiate inflammatory and neoplastic lesions so effectively that it obviates the need for surgical intervention [3,4]. The common pathological lymph node lesions encountered in the neck are lymphadenitis, metastatic carcinoma, lymphoma [5]. Fine needle aspiration cytology is mostly using nowadays for diagnosis of non-neoplastic and neoplastic lymph node lesions. FNAC offers the advantages of an immediate, although not always specific diagnosis with little cost and trauma. The primary purpose of fine needle aspiration biopsy of an abnormal peripheral lymph node is to decide on further course of treatment whether medical, surgical or observation [5]. Core needle biopsy is adequate for the diagnosis of metastatic

carcinoma [6]. Although not preferred for the evaluation of primary lymphoid disorders, core biopsies are increasingly used nowadays. Compression artifact is very common in core biopsies, with the cells appearing smaller and the nuclei appearing darker compared with those seen in excisional biopsies [7]. Other well established techniques that are used for diagnostic purposes are immunohistopathology, cytogenetics, flow cytometry, electron microscopy, bacterial and viral cultures. Of all the investigations FNAC has emerged an important tool that is more sensitive and conservative [8]. Although the most common techniques for performing an FNAC of a palpable mass are applicable to all superficial sites, there are nuances in method some idiosyncratic that depend on geographic or institutional custom and/or previous training and experience. Even for individual pathologists, details learned in training are often modified in practice by factors such as height, handedness, hand size, and finger strength.

II. Aims and Objectives

2.1. Aims

To evaluate the reliability and diagnostic accuracy of fine needle aspiration cytology (FNAC) of enlarged lymph nodes with an emphasis on discordant cases between the cytology and the histopathology and to prove that it is a primary method of diagnosis in case of lymph node disease.

2.2. Objectives

- a) To confirm the nonspecific/inconclusive FNAC results with final histopathological diagnosis
- b) To compare the diagnostic efficacy of FNAC with excision biopsy in lymphnode disease.
- c) To evaluate the cause of enlarged lymph nodes in patients

III. Materials and Methods

This two year prospective observational study is a time bound study including 102 cases and the sampling technique used was non random (non probability) . Patients with enlarged lymph nodes in whom FNAC and excision biopsy is planned in the study period between October 2015 to August 2017 , attending Kasturba Medical College Hospital Attavar, Kasturba Medical College Hospital Ambedkar Circle & Government Wenlock Hospital, Mangalore will be enrolled for the study after obtaining a written informed consent.

Study Design: Two year prospective observational study.

Sample size and sample technique: The study is a time bound study including 102 cases and the sampling technique used was non random (non probability)

Study Period: From October 2015 to August 2017

Study Centre:

- 1) Kasturba Medical College Hospital, Attavar
- 2) Kasturba Medical College Hospital, Ambedkar Circle
- 3) Government Wenlock Hospital, Mangalore

Study Population: Study on patients of ages above 15 and both sex, with clinical diagnosis of lymphadenopathy in whom both FNAC followed by histopathological examination was done were included in the study.

Inclusion criteria:

Patients of ages above 15 and both sexes, attending Kasturba Medical College Hospital, Attavar ,Kasturba Medical College Hospital, Ambedkar Circle &Government Wenlock Hospital,Mangalore whose lymph node FNAC shows nonspecific /inconclusive findings and eligible for lymph node biopsy

Exclusion criteria:

- 1) Incomplete data.
- 2) In individuals where only FNAC was done without excision biopsy.

Method of Study:

All patients with enlarged lymph nodes in whom FNAC and excision biopsy is planned in the study period, attending Kasturba Medical College Hospital Attavar , Kasturba Medical College Hospital Ambedkar Circle & Government Wenlock Hospital, Mangalore will be enrolled for the study after obtaining a written

informed consent. Each patient with nonspecific/inconclusive FNAC report will be subjected to lymph node excision biopsy. The cytology slides were prepared after aspiration and fixed in 10% alcohol. After fixation the slides were stained by H&E. The surgically biopsied lymph nodes were fixed in 10% buffered formalin. After gross examination, entire or representative sections were taken followed by paraffin embedding, cutting and slide preparation and finally stained with H&E. Both histopathology and FNAC slides were examined under light microscope. A final diagnosis was recorded and evaluate the diagnostic accuracy of FNAC using histology as the gold standard.

Statistical package:

SPSS for windows, version 17.0 was used to do analysis.

IV. Results and Observations

In the total of 102 cases under study, those had underwent FNAC, 44 (43.1%) were females and 58 (56.9%) were males. Cervical lymph nodes was the commonest site included in study and in which, upper deep cervical lymph nodes constituting 48 cases (47.1%) followed by involvement of the supraclavicular lymph nodes in 7 cases (6.9%). Among the remaining cases, 25 cases (24.5%) was axillary lymph nodes and 22 cases (21.5%) was inguinal lymph nodes. Among the inconclusive / nonspecific FNAC reports, 95 cases (93.1%) were reactive lymphadenitis and 7 reported as inadequate for opinion (6.9%). On analysing cytopathological diagnosis in patients with inconclusive/ nonspecific FNAC reports, 25 cases (24.5%) was found to be positive (have a definitive diagnosis) and 77 cases (75.5%) was found to be negative(reactive lymphadenitis).Out of 93 excision biopsy cases,23 cases found to have definitive diagnosis which are 6 was reported as NHL ,3 cases as hodgkins lymphoma and 4 were diagnosed as metastatic carcinoma,6 cases as tuberculosis, one as toxoplasmosis s, one as cat scratch diseases, another one as histoplasmosis and other as histiocytic necrotizing lymphadenitis. Rest of 70 cases were reactive lymphadenitis(negative). Out of 95 cases that cytologically detected as reactive lymphadenitis, 11 cases were diagnosed to be malignant on histopathology. Out of the 7 cases that were diagnosed cytologically as inadequate for opinion ,4 cases were diagnosed histopathologically as malignant. In 5 cases metastatic carcinoma to the lymph nodes was diagnosed in biopsy, 3 was reported as reactive lymphadenitis and 2 was reported to be inadequate for opinion in cytology. Out of 6 aspirates was diagnostic of non Hodgkin lymphoma , 5 cases reported as benign reactive lymphoid hyperplasia and 1 case as inadequate for opinion in cytology. Out of 3 diagnostic cases of hodgkins lymphoma ,2 was reported to be reactive hyperplasia and one to be inadequate sample. Also one case of papillary carcinoma was reported as reactive lymphadenitis in FNAC. These cases was considered as a minor discordant case with minor clinical relevance, as regard the typing of the malignant tumor. The biopsy results were then compared with the cytological results of the corresponding lymph nodes. Among the 95 cytologically benign cases, 76 cases (80%) were proved histopathologically to be negative, and 19 cases (20%) were diagnosed histopathologically positive cases. 6 cases (85.7%) out of the 7 cytologically reported inadequate sample were proved histopathologically to be positive. In total out of 102 nonspecific/inconclusive FNAC reports, 25 cases (24.5%) was found to be positive and 77 cases (75.5%) was found to be negativIt was found that, of the 95 cases that were cytologically diagnosed as reactive lymphoid hyperplasia only 11 cases were turned out to be malignant on histological examination and rest 84 cases was found to be benign itself. Out of 7 cases that were inadequate for opinion in FNAC, 4 cases were found to be malignant on histology and rest to be benign.

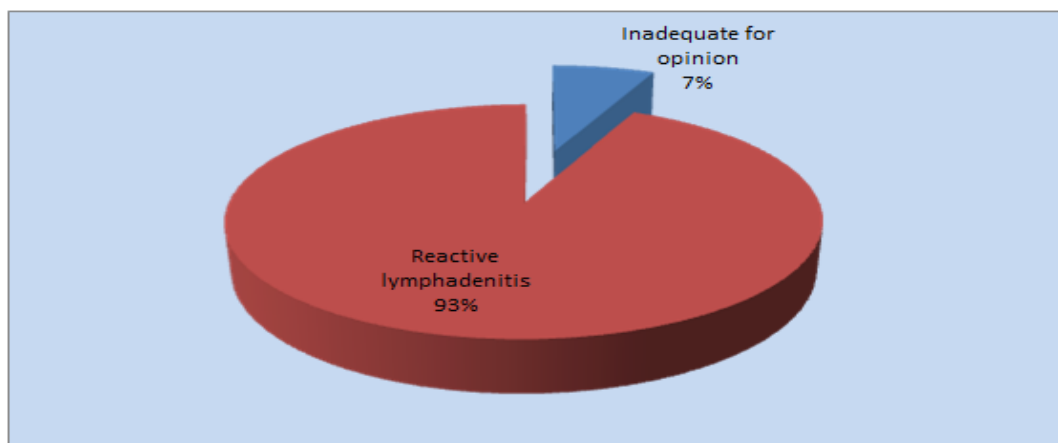


Fig 1: Analysis of FNAC reports of patients with lymphadenopathy




Fig 2. Analysis of Cytopathological diagnosis in patients with inconclusive/ nonspecific FNAC reports

Table.1: Comparison of detailed cytopathological diagnoses with the corresponding detailed histopathological diagnoses in patients with lymphadenopathy

		BIOPSY		Total
		Positive	Negative	
FNAC	Inadequate for opinion	6 85.7% 24.0%	1 14.3% 1.3%	7 100.0% 6.9%
	Reactive lymphadenitis	19 20.0% 76.0%	76 80.0% 98.7%	95 100.0% 93.1%
Total		25 24.5% 100.0%	77 75.5% 100.0%	102 100.0% 100.0%

Table.2: Analysing final diagnostic biopsy reports with corresponding FNAC reports

		BIOPSY		Total
		Malignant	Benign	
FNAC	Inadequate for opinion	4 57.1% 26.7%	3 42.9% 3.4%	7 100.0% 6.9%
	Reactive lymphadenitis	11 11.6% 73.3%	84 88.4% 96.6%	95 100.0% 93.1%
Total		15 14.7% 100.0%	87 85.3% 100.0%	102 100.0% 100.0%

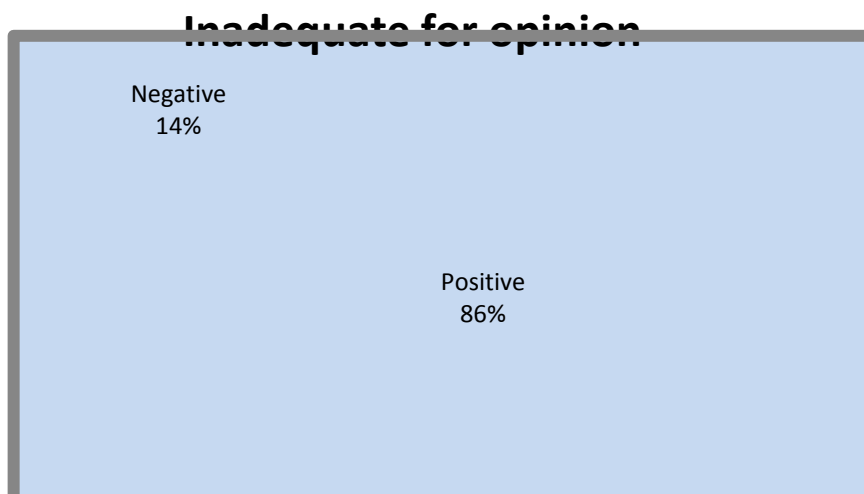


Fig.3: Cytopathological diagnoses of the histopathologic reporting of inadequate sampling

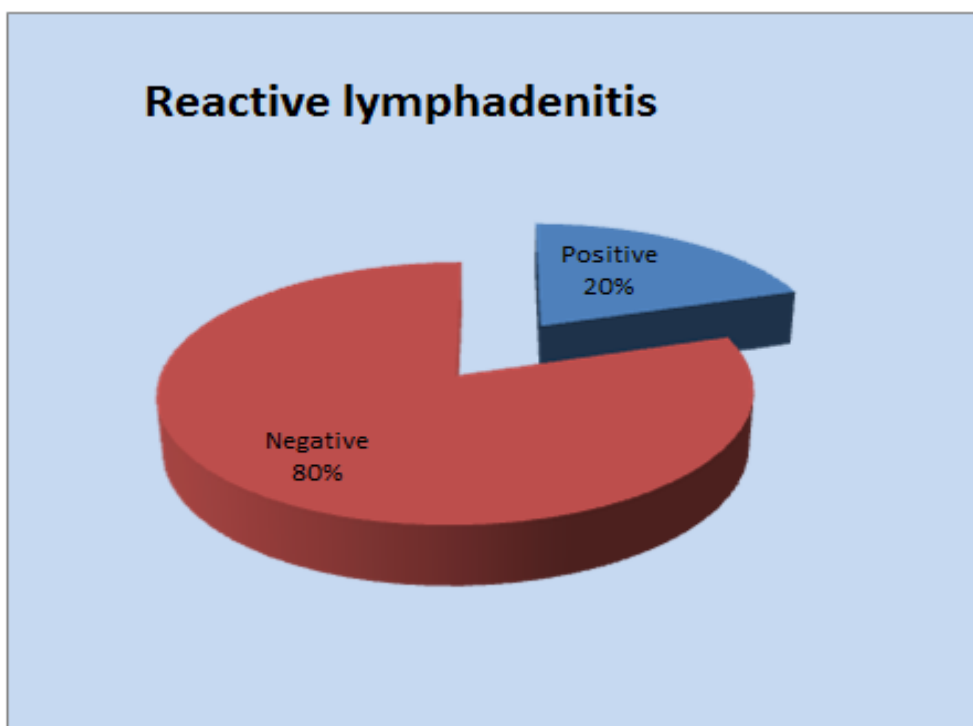


Fig.4: Cytopathological diagnoses of the histopathologic diagnosis of reactive lymphadenitis

V. Discussion

This is a prospective observational study conducted at Government Wenlock Hospital, KMC Hospital Attavar & KMC Hospital Ambedkar Circle from October 2015 to August 2017. Total of 102 subjects with lymphadenopathy who had nonspecific cytology reports were selected for the study. Fine needle aspiration cytology has decreased the need for excision or incision biopsy by reforming the diagnosis of lymph node diseases [9]. The sensitivity and specificity of FNAC for metastatic lymphadenopathy is high with few pitfalls. In the current study, most commonly encountered enlarged lymph nodes were the cervical lymph nodes. Several studies on lymphadenopathy like study by Chhotray and AcharyaD have shown that among all the peripheral nodes most commonly enlarged and biopsied ones are the cervical nodes [10]. This result can also be due to the fact that cervical lymph nodes are the ones most easily accessible for examination. However, in another study Ojo et al concluded that the most commonly enlarged lymph nodes are axillary lymph nodes and then cervical lymph nodes [11]. The inference from our study indicates that FNAC of enlarged lymph nodes in majority of cases will show benign lymphadenopathy. It shows that FNAC helps in differentiating benign and malignant types of

lymphadenopathy and also gives an idea about the nature of the benign enlargement. Hence, in this study 85.3% cases were benign enlargements and among that majority was reactive lymphadenitis (75.5%). These results are similar with reports in the literature[12] Even though diagnostic standard is lymph node excision biopsy , it often needs admission and general anaesthesia. Previously it is reported that the prognosis may be affected adversely if lymph node excision biopsy is done before definitive surgery in case of squamous cell carcinoma of head and neck [4]. Most of FNAC and biopsy reports were similar(80%) and this suggests that FNAC can be utilised as primary diagnostic technique in lymphadenopathy. Several studies show similar observation [13,14] . Majority of the cases that was reported as non specific reactive lymphadenitis in cytology(n=95) , was later confirmed with biopsy(n=84 In our present study, Out of 102 nonspecific/inconclusive FNAC reports, 25 cases (24.5%) was found to be positive and 77 cases (75.5%) was found to be negative. Also out of 102 patients with inconclusive FNAC report 25(24.5%) had a definitive diagnosis after biopsy. Out of a total 102 studied cases, 15 cases (14.7%) were malignant and 87 cases (85.3%) were benign. This findings was comparable with various similar studies [14,15] that reported that the benign lesions were more frequent than the malignant lesions due to the high frequency of tuberculous and reactive hyperplasia cases. But out of 15 malignant cases, 5 cases of metastatic carcinoma was not detected in cytology which did not correlate well with most of other similar studies [14,16] .On cytology the false negative cases happens more due to sampling errors rather than diagnostic problems, like the Reed Sternberg cell may not be seen which is significant in Hodgkin's lymphoma diagnosis[17,18]. Another reason for false negative report is due acellular/ poorly cellular sample.In our study, blind FNAC was performed by different technicians without ultrasound guidance. 1 case of tuberculosis was initially missed out due to inadequate sampling. 5 cases of tubercular lymphadenitis was reported as non-specific reactive lymphadenitis. The cases of lymphoma, involved all lymph node groups. In 5 cases where initial FNAC report was reactive hyperplasia, histopathology came as non-Hodgkin's lymphoma. 2 cases of Hodgkins lymphoma was cytologically diagnosed as reactive lymphadenitis.Following FNAC of superficial lymph node no needle track metastasis have been reported. Only 12 cases are reported in the literature following FNAC. No case of needle track metastasis was found, in a large series study by Southan etal[19] even after up to 7 years of follow up. No needle track metastasis was found in our study in one year follow up after needle biopsy.

VI. Conclusion

In most cases FNAC is carried out as an outpatient procedure. It is a simple procedure which is acceptable to most of the patients. For FNAC, anesthesia is not required and an accurate diagnosis can be made. It is safe, time saving as well as cost-effective diagnostic tool. It is an investigation that gains high accuracy with greater experience and expertise. False negative reporting in malignant lymph node lesions may delay further investigation and treatment. So in such cases the sensitivity of test is much significant than its specificity. It was proven in other studies that, FNAC has lower sensitivity than accuracy[20]. Therefore it is much importance that a strong clue regarding possible diagnosis should be suspected prior to cytology, because negative cytology will not rule out lymphadenopathy due to any specific disease. So FNAC is always a part of work up and cannot be over emphasised as a final diagnostic tool, when the report is negative or inconclusive.

At the completion of the study, with the analysis of the results, the following conclusions can be drawn:

- Fine needle aspiration cytology is a very reliable investigation in the diagnosis of causes of lymphadenopathy.
- FNAC is a very effective investigation with high accuracy rate to differentiate benign conditions from malignant ones and avoids unwanted operations. But caution is mandatory in cases of inconclusive or negative cytology report. If there is a strong clinical suspicion, negative FNAC report is to be disregarded and excision biopsy should be carried out.
- The majority of the nodal lesion was reactive hyperplasia without malignant feature. Tuberculous lymphadenitis was the second common finding.
- Cervical lymph nodes are commonly involved in which upper deep groups followed by supraclavicular lymph nodes
- Biopsy is very useful in cases of lymphomas and metastatic tumors, which acts as the diagnostic tool. Also when FNAC report is inconclusive, in nonspecific lymphadenitis it is very much helpful to get an accurate diagnosis and aids in an appropriate management, hence it is the gold standard method.

References

- [1] Kumar, Vinay, Abbas, Abul K; Fausto, Nelson; Robbins, Stanley L (Stanley Leonard), Cotran, Ramzi S, 1932-2000 Robbins pathologic basis of disease. 8th ed 2012 ;6:189
- [2] Giles GR. Bailey and Love's Short Practice of Surgery. 19th Edition. London: HK Lewis & Co; 1985: 601, 610.
- [3] Kochhar AK, Duggal G, Singh K, Kochhar SK. Spectrum of cytological findings in patients with lymphadenopathy in rural population of southern Haryana, India - Experience In A Tertiary Care Hospital. IJPA. 2012;13(2):8.
- [4] Hag IA, Chiedozi LC, Reyees FA, Kollur SM. Fine needle aspiration cytology of head and neck masses. Seven years experience in a secondary care hospital. Acta Cytol.
- [5] Klijanienko J. Head and Neck and Salivary gland. In: Layfield LJ, [3]ed. Atlas of Fine Needle Aspiration Cytology, 1st ed. New Delhi, India: Jaypee Publishers. 2014:11
- [6] Townsend, C. M., & Sabiston, D. C. (2004). Sabiston textbook of surgery: The biological basis of modern surgical practice. Philadelphia: Saunders
- [7] Ahmed T, Naeem M, Ahmad S, Samad A, Nasir A. Fine needle [4]aspiration cytology (FNAC) and neck swellings in the surgical outpatient. J Ayub Med Coll Abbottabad. 2008; 20(3): 30-32.
- [8] Hafez NH, Tahoun NS. Reliability of fine needle aspiration cytology (FNAC) as a diagnostic tool in cases of cervical lymphadenopathy. Journal of the Egyptian National Cancer Institute 2011;23(3):105-14.
- [9] X. Llovet JM, Vilana R, Bru C, et al. Increased risk of tumor seeding after percutaneous radiofrequency ablation for single hepatocellular carcinoma. Hepatology. 2001;33(5):1124-1129
- [10] Chhotray GP, Acharya GS. Fine needle aspiration cytology in diagnosis of metastatic lymphadenopathies Indian J Med Res. 1987; (85): 685-688.
- [11] E. Ojo BA, Buhari MO, Malami SA, Abdul Rahaman MB. Sur- gical lymph node biopsies in University of Ilorin Teaching Hospital, Ilorin, Nigeria. Niger Postgrad Med J. 2005; (12): 299-230
- [12] Rosai J editor. Rosai and Ackermans Surgical Pathology. 10th ed. New Delhi: Elsevier, 2011.
- [13] Ahmad SS, Akhtar S, Akhtar K, Naseen S, Mansoor T. Study of fine needle aspiration cytology in lymphadenopathy with special reference to acid fast staining in cases of tuberculosis. J K Sci 2005;7(1):1-4.
- [14] Stani J. Cytologic diagnosis of reactive lymphadenopathy in fine needle aspiration biopsy specimens. Acta cytologica, 1987, 31:8-13.
- [15] Alash NI, AbdulMajeed BA, AlHashimi AS, Lymphadenopathy: histopathologic study of 1145 biopsies. Journal of the Faculty of Medicine, Baghdad University, Iraq, 1994, 36:171-9.
- [16] Hirachand S, Lakhey M, Akhter J, Thapa B. Evaluation of fine needle aspiration cytology of lymph nodes in Kathmandu Medical College, Teaching hospital. Kathmandu Univ Med J 2009;7(26):139-42
- [17] Lee RE et al. Lymph node examination by FNAC in patients with known or suspected malignancy. Acta cytological. 1987; (31):563-71.
- [18] Owen ER, Banerjee AK, Prichard AJ, Hudson EA, Kark AE. Role of ne-needle aspiration cytology and computed tomography in the diagnosis of parotid swellings. Br J Surg. 1989; (76):1273-1274.
- [19] Southam JC, Bradley PF, Musgrove BT. Fine needle cu ing biopsy of lesions of the head and neck. Br J Oral Maxillofac Surg. 1991;(29):219-222
- [20] Kleid S, Millar HS. e case against open neck biopsy. Aust N Z J Surg. 1993; (63):678-681.

Dr. Nidhin Mathew. "Study on the Biopsy of Lymph Nodes with Inconclusive/Non- Specific Fancy Results" IOSR Journal of Dental and Medical Sciences (IOSR-JDMS), vol. 17, no. 3, 2018, pp. 82-88.